

DELAYED BILIARY DUCT
OBSTRUCTION AFTER
ORTHOTOPIC LIVER
TRANSPLANTATION

G. MARTINEAU, M.D.

Denver, Colo.

K. A. PORTER, M.D.

London, England

J. CORMAN, M.D.

B. LAUNOIS, M.D.

G. T. SCHROTER, M.D.

W. PALMER, M.D.

C. W. PUTNAM, M.D.

C. G. GROTH, M.D.

C. G. HALGRIMSON, M.D.

I. PENN, M.D.

and

T. E. STARZL, M.D., PH.D.

Denver, Colo.

From the Departments of Surgery and Pediatrics, University of Colorado School of Medicine and the Veterans Administration Hospital, Denver, and the Department of Pathology, St. Mary's Hospital and Medical School, London

Reprinted from

SURGERY

St. Louis

Vol. 72, No. 4, pp. 604-610, October, 1972

(Copyright © 1972 by The C. V. Mosby Company)
(Printed in the U. S. A.)

Delayed biliary duct obstruction after orthotopic liver transplantation

G. Martineau, M.D., *Denver, Colo.*, K. A. Porter, M.D., *London, England*, J. Corman, M.D., B. Launois, M.D., G. T. Schroter, M.D., W. Palmer, M.D., C. W. Putnam, M.D., C. G. Groth, M.D., C. G. Halgrimson, M.D., I. Penn, M.D., and T. E. Starzl, M.D., Ph.D., *Denver, Colo.*

After orthotopic liver transplantation and biliary reconstruction by cholecystoduodenostomy, four of 40 patients developed delayed obstruction of the cystic duct. The recipients had the clinical syndrome of fulminating cholangitis with jaundice, fever, leukocytosis, toxemia, and bacteremia. All four patients died; of the four, two patients died despite late reoperation and re-establishment of bile drainage by choledochoenterostomy. In all four cases, a factor contributing to the biliary obstruction may have been infection of the extrahepatic biliary ducts with or without ulceration, and in three of the livers, there was evidence of infection of the ducts with CMV. If cholecystoduodenostomy is used in future cases, prompt re-exploration and conversion to choledochoenterostomy should be considered if the diagnosis of duct obstruction, cholangitis, and persistent bacteremia are made.

From the Departments of Surgery and Pediatrics, University of Colorado School of Medicine and the Veterans Administration Hospital, Denver, and the Department of Pathology, St. Mary's Hospital and Medical School, London

IN OUR institution, biliary duct reconstruction after orthotopic liver transplantation has usually been employed with cholecystoduodenostomy after ligation of the graft distal common duct.⁴ After this type of reconstruction, chronic survival of both experimental animals and man has been achieved. However, the present communication will present four examples of failure of cholecystoduodenostomy resulting from delayed obstruction of the cystic duct near its junc-

tion with the common duct. In each instance, the result was death. Evidence will be presented that cytomegalovirus (CMV) infection of the extrahepatic biliary duct system may have contributed to these complications.

METHODS

The four patients underwent the liver replacement operation depicted in Fig. 1, *A*, including cholecystoduodenostomy. They were all treated with a triple-drug regimen that included horse antilymphocyte globulin (ALG) and prednisone. The third agent for Patients 1 and 2 was azathioprine,⁴ and Patients 3 and 4 were treated instead with cyclophosphamide.⁵

The patients who developed cystic duct obstruction were aged 16 months, 14 years,

This work was supported by research grants from the Veterans Administration, by grants No. RR-00051 and RR-00069 from the General Clinical Research Centers Program of the Division of Research Resources, National Institutes of Health, by grants No. AI-10176-01, AI-AM-08898, AM-07772, and HE-09110 of the United States Public Health Service, and by a grant from St. Mary's Hospital Research Fund.

Accepted for publication April 3, 1972.

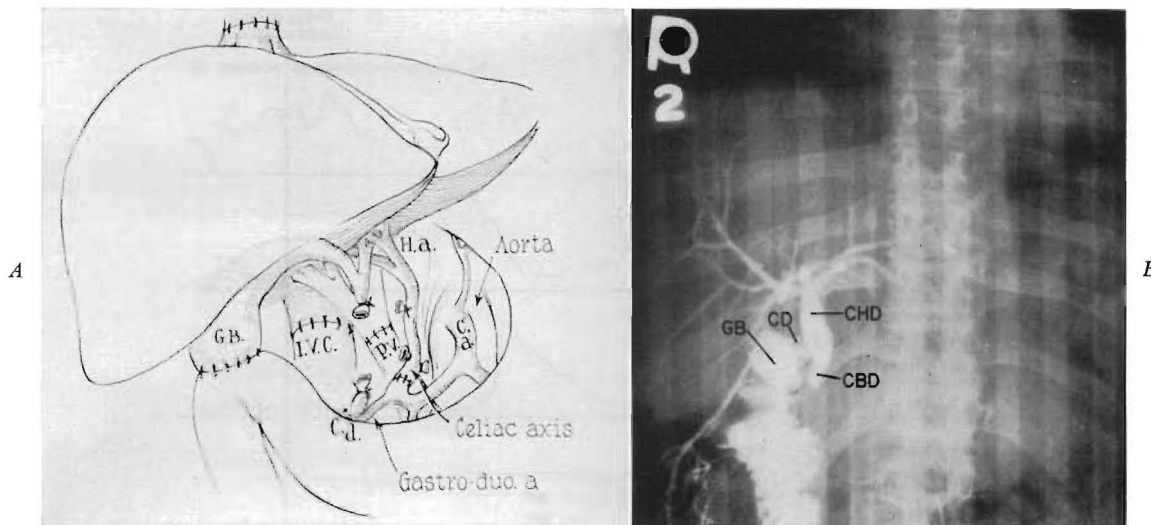


Fig. 1. Biliary duct reconstruction with cholecystoduodenostomy. A, Surgical technique. B, Operative cholangiogram in a patient who developed jaundice almost three months after orthotopic transplantation. In this case, obstruction was ruled out.

Table I. Clinical features of four patients with posttransplantation biliary obstruction

Case No.	Postoperative jaundice recurrence (days after transplantation)	Maximum secondary bilirubin rise (mg. %)	Remission of secondary jaundice	Bacteremia	Other infections	Postoperative survival (days)
1	3	22	to 3 mg. %	Aerobacter-Klebsiella; <i>E. coli</i>	Pneumonitis	105
2	22	21.5	to 6 mg. %	<i>E. coli</i>	Pneumonitis	63
3	15	18	to 2.5 mg. %	<i>E. coli</i>	None	46
4	5	14.5	None	<i>E. coli</i> ; <i>Clostridium perfringens</i>	None	31

16 years, and 11 years. Their primary diagnoses were biliary atresia (Patients 1 and 3) and chronic aggressive hepatitis (Patients 2 and 4).

RESULTS

Incidence of the complication. The four cystic duct obstructions occurred in the first 44 consecutive liver transplantations. Since cholecystoduodenostomy had been performed in only 40 of the 44 recipients, the corrected incidence was 10 percent.

The clinical syndrome. At the time of the original transplantation, all four homografts excreted bile which welled up in the gallbladder through the cystic duct. Good hepatic

function with clearing of pre-existing jaundice continued during the early convalescence (Fig. 2).

After 3 to 22 days, hyperbilirubinemia recurred, preceded by major increases in the alkaline phosphatase and accompanied by minor rises in the transaminases (Fig. 2). In each of the four cases, rejection was thought to be present and was treated with increased doses of prednisone (Fig. 2). In three of the four instances, there was some remission of the secondary jaundice (Fig. 2). This was initially interpreted as support for the diagnosis of rejection.

All of the patients became remittently febrile with the onset of liver function aber-

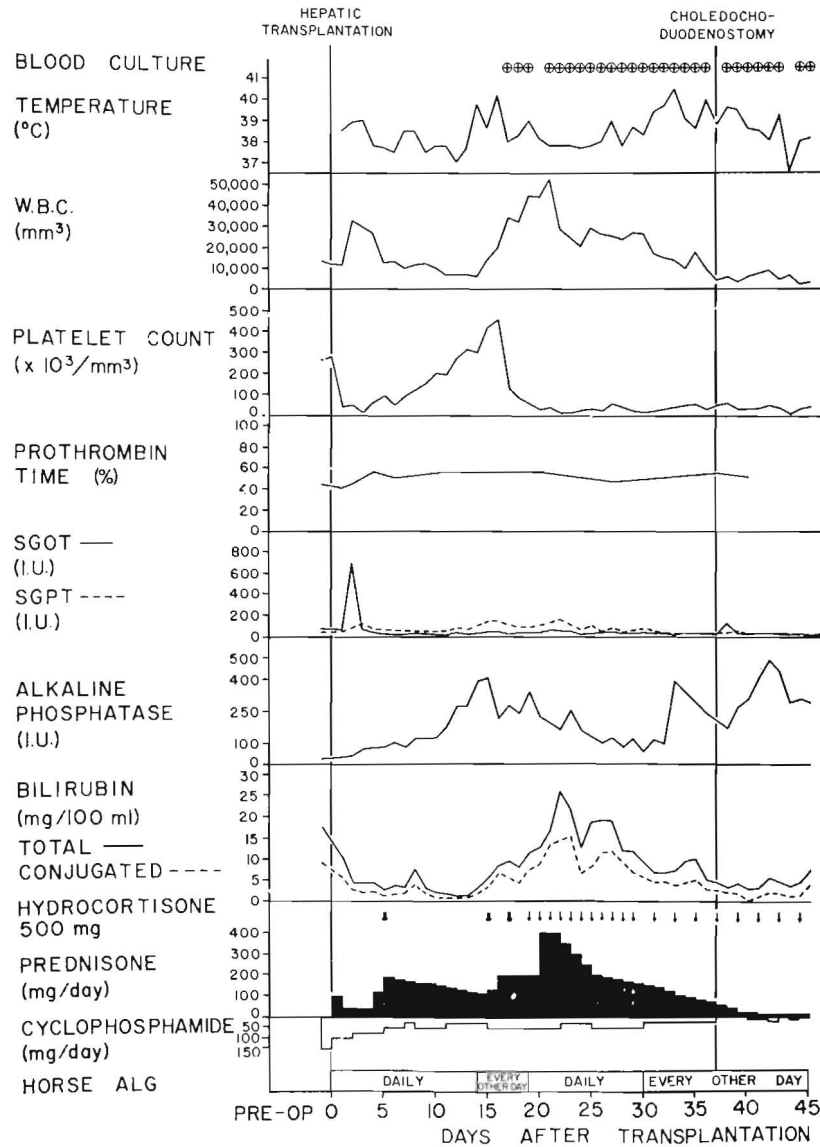


Fig. 2. The course of a 16-year-old recipient of a hepatic homograft (Patient 3). Although liver function was satisfactory initially, hyperbilirubinemia developed 15 days after operation, but receded slightly with intensification of immunosuppression. Systemic sepsis prompted re-exploration, at which time a cholangiogram (Fig. 3, C) was obtained and biliary diversion was converted to choledochoduodenostomy. However, the child died of uncontrolled sepsis 46 days after transplantation.

rations. Shortly after, bacteremia was detected in multiple blood cultures (Fig. 2). The microorganisms were those indigenous to the gastrointestinal tract, being predominantly gram-negative pathogens (Table I). Once the bacteria appeared in the bloodstream, blood cultures remained positive until death in spite of antimicrobial therapy. The

patients appeared toxic with marked tachycardia accompanying the fever spikes. Leukocytosis (as high as 50,000 per cubic millimeter) and thrombocytopenia (as low as 5,000 per cubic millimeter) were invariably noted (Fig. 2).

Each patient had several liver scans. In Patient 1, partial gangrene of the right he-

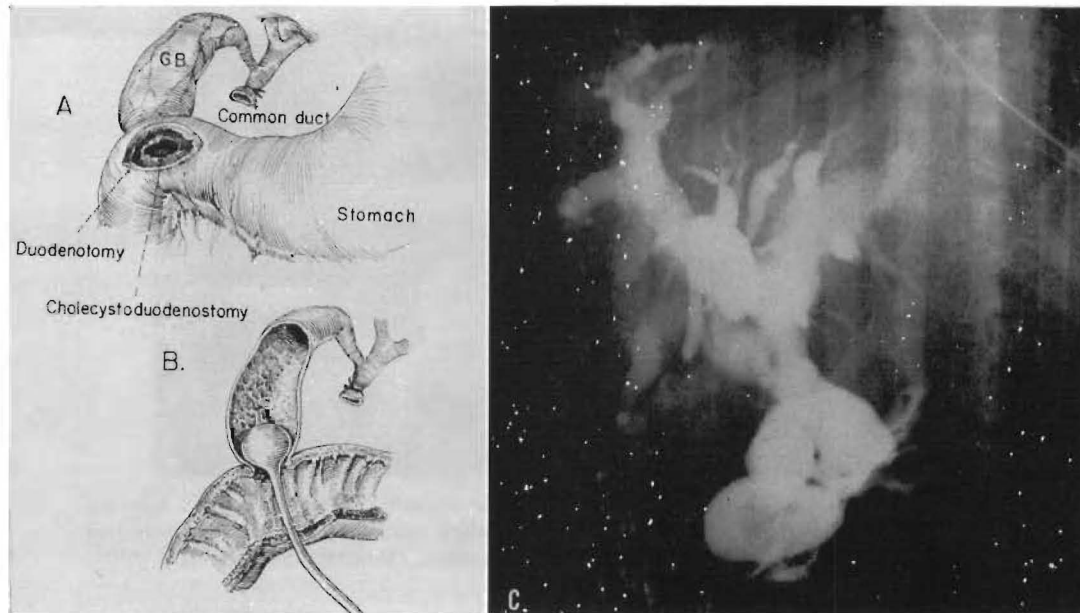


Fig. 3. Cholangiography of hepatic homograft. *A* and *B*, Technique of dye injection through a duodenotomy and the anastomosis. *C*, Obstructed duct system in Patient 3.

Table II. Pathological features of four obstructed hepatic homografts*

Case No.	Liver						Gallbladder and cystic duct	
	Hepatic duct dilatation	Intra-hepatic abscesses	Cholangitis	Cytomegaloviral lesions	Rejection	Vascular supply	Cholecystitis	Cytomegaloviral lesions
1	++++	-	±	-	±	Right hepatic artery thrombosed	+++	-
2	++++	+	±	+	-	Normal	±†	++†
3	++++	+	+++	±	-	Normal	+	†
4	++++	+	++	++	-	Normal	++++	+++

*Grading System: -, none; ±, minimal; +, mild; ++, moderate; +++, advanced; and +++++, severe.

†Specimens obtained at reoperation.

patic lobe occurred after thrombosis of the right hepatic artery; the necrotic area did not pick up the technetium isotope. The other three homografts had minor abnormalities but not in any distinctive pattern.

Efforts at surgical correction. In Patients 2 and 3, a re-exploratory operation was performed. By insertion of a balloon catheter into the gallbladder (Fig. 3, *A* and *B*), the duct system was re-evaluated. Although the gallbladder and cystic duct were collapsed, the common duct and the intrahepatic ducts were dilated (Fig. 3, *C*). The liver had multiple soft areas which proved upon aspiration to contain a bacteria-laden thin fluid. The

gallbladder was removed, and choledochoduodenostomy was performed. After operation, there were falls in the bilirubin (Fig. 2), but both patients died of uncontrolled sepsis.

Pathologic observations. At autopsy from 31 to 105 days after transplantation, there was a chalklike, crumbly debris which formed casts in some of the dilated intrahepatic ducts of all four livers (Table II). The cystic ducts were small in Patients 1 and 4, similar to the findings previously demonstrated at reoperation in Patients 2 and 3.

Patient 1 had a complete thrombosis of the right hepatic artery with consequent gan-

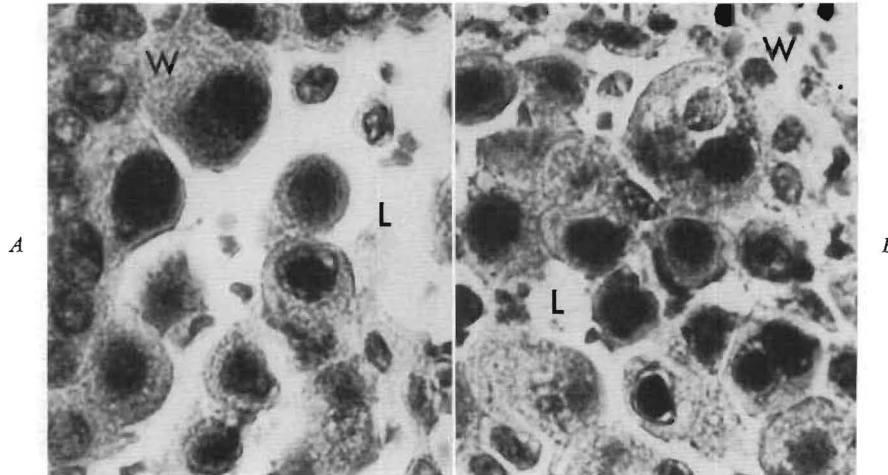


Fig. 4. Obstructed cystic ducts of hepatic allografts in Patients 2 (A) and 4 (B). The wall (W) of each duct is lined by swollen epithelial cells which contain cytomegaloviral inclusions. Some similar cells lie free in the lumen (L) of each duct. (Hematoxylin and eosin. $\times 900$.)

grene of the right lobe of the liver (Table II). In Patient 4, an abscess of the right hepatic lobe, which was in free communication with the dilated right main hepatic duct, had ruptured through the liver into the subphrenic space.

At the time of reoperation or at autopsy, bits of gallbladder were obtained. Histopathological evidence of chronic cholecystitis was found in three of the four gallbladders (Table II). There was widespread ulceration of the lining epithelium in Patients 1 and 4 and focal ulceration in Patient 3. These three gallbladders also showed infiltration of the submucosa by mononuclear cells and polymorphonuclear leukocytes and replacement of muscle by fibrous tissue. Intranuclear inclusions resembling those produced by cytomegalovirus (CMV) were present in many of the mucosal epithelial, submucosal endothelial, and connective tissue cells of the cystic ducts and gallbladders from Patients 2, 3, and 4 (Fig. 4). Groups of enlarged virus-infected cells that had been shed were present on the gallbladder and duct mucosal surfaces and in the lumens.

The liver homografts from Patients 1, 3, and 4 showed clear evidence of large biliary duct obstruction. The portal tracts were enlarged and were lightly infiltrated with mononuclear cells and polymorphonuclear leuko-

cytes. There was proliferation of small bile ducts and ductules. The ducts were dilated and some contained inspissated bile. Bile lakes were present in Patients 1 and 3. Centrilobular cholestasis was marked in Patient 1 and slight in Patients 2 and 3. There was marked chronic cholangitis in Patients 3 and 4. Cells with CMV-like intranuclear inclusions were present in the hepatic homografts of Patients 2, 3, and 4. None of the homografts showed clear evidence of past or active rejection, although IgM and Clq were present in some of the vein walls of the graft in Patient 1.

Many cytomegalic inclusion cells were present in the alveolar epithelium of the lungs of Patients 2, 3, and 4 at autopsy, and in some of the hepatocytes and bile duct epithelial cells of the liver removed at the time of hepatic transplantation from Patient 2.

Viral studies. CMV was isolated from the liver homografts, and several other tissues obtained at autopsy from Patients 2, 3, and 4. In Patient 2, the virus was also cultured from the patient's own liver which had been removed two months previously. Typical intranuclear and intracytoplasmic virus particles were found on electron microscopic study of cytomegalic cells from some of these tissues.

DISCUSSION

Extrahepatic biliary obstruction after orthotopic liver transplantation has been noted before, but it usually resulted from technical errors or from the recurrence of malignancy.⁴ Delayed cystic duct obstruction of the kind herein reported has been described⁴ in only one patient, the same child (OT 12) as Patient 1. Three more examples have now been encountered, giving an incidence of 10 percent in our series for this lethal complication.

In each of the four instances, bile drainage seemed satisfactory at the time of operation, and, furthermore, it was free enough to permit clearing of pre-existing hyperbilirubinemia during the initial convalescence. Then, 3 to 22 days postoperatively, jaundice deepened. Rejection was diagnosed and treated with increased doses of prednisone.

The diagnosis of rejection seemed supported in three of the four cases by the partial reversal of the secondary hyperbilirubinemia. Nevertheless, even these three patients continued to have low-grade jaundice. All four recipients became febrile and developed bacteremia and leukocytosis. The clinical picture of life-threatening cholangitis was now complete. All of the recipients eventually died from intrahepatic and systemic sepsis; two patients died in spite of reoperation and secondary construction of a choledochoduodenostomy. In the latter two patients, the provision of adequate biliary drainage was too late since multiple foci of infection within the liver were already well established. At either autopsy or reoperation, the intrahepatic ducts and common ducts of the four homografts had become remarkably dilated and filled with bile and a soft chalk-like debris. There was collapse of the cystic duct and gallbladder.

The etiology of the biliary obstruction probably involved other factors than simple positional distortion at or near the junction of the common and cystic ducts, since the mechanical arrangement in each case was initially satisfactory for bile drainage. It is possible that acute rejection played a precipitating role with swelling and consequent

occlusion of the cystic duct lumen particularly very early in convalescence. With partial reversal of the process, as seemed to have been achieved in three of the four patients by intensified immunosuppression, bile flow through the cholecystoduodenostomy could have resumed, although suboptimally. However, in the specimens examined at reoperation or autopsy, there was no real evidence to indict present or past rejection in the etiology of the delayed obstruction.

In contrast, the development of cholecystitis or viral inclusion disease in the homograft gallbladder could have been a factor particularly after the first few weeks. One or both lesions were present in the gallbladders of each of the four cases. In one patient, there was evidence that the cytomegalic disease was established before hepatic transplantation. The viral infection might have been particularly significant because, recently, it has been shown that infection with a Papovavirus of the epithelial cells lining a homograft ureter can produce obstruction.² The obstruction in cases of either renal or hepatic homografts could presumably be secondary to the kind of ulceration with or without healing that CMV can produce in the urinary or gastrointestinal tracts³ or by the shedding of swollen cells containing intranuclear viral inclusions which would contribute to the obstructing debris. Whatever the exact mechanism, the small cystic duct would be preferentially susceptible to the mechanical consequences of all these events.

One way to minimize biliary obstruction of the kind documented in this report would be to abandon cholecystoduodenostomy as the primary means of biliary reconstruction and, instead, to employ one of the standard techniques of common duct anastomosis combined with cholecystectomy. Unfortunately, the methods employing the common duct have also carried a high risk after liver transplantation, mainly because of anastomotic leak.^{1, 4} Moreover, a secondary operation to correct such a leak provides limited options, since the prior removal of the gallbladder eliminates the possibility of delayed cholecystoenterostomy. Finally, the use of the com-

mon duct for anastomosis would not preclude obstruction secondary to infestation by CMV. If this virus proved to have an important causal relationship to duct obstruction, a more sensible approach would be to consider antiviral treatment as, for example, with cytosine arabinoside. Under immunosuppression, it is known that a very high percentage of whole organ recipients are chronic carriers of CMV although until recently there has been little evidence that this virus causes important sequelae.

It is our present view that cholecystoduodenostomy is still the safest way to reconstruct the biliary system initially after liver transplantation, since the procedure can be done without internal stents or drainage and because it burns no anatomic bridges if reoperation becomes necessary. However, with cholecystoduodenostomy, there must be a firm commitment to perform a re-exploratory operation for very specific indications. These indications consist essentially of the clinical features of cholangitis, including evidence of obstruction, a septic course, and, above all, persistent bacteremia. The first two of these findings can be seen with simple rejection, but continuous bacteremia should raise the highest suspicion of a surgically correctible complication. At operation, the

cholecystoduodenostomy could then be converted to choledochenterostomy if warranted by the findings of transduodenal cholangiography. In two of the presently reported cases, the significance of the bacteremia was not appreciated until autopsy, and in the other two corrective surgery was delayed so long that all hope of success was lost.

We wish to thank Dr. Sylvia D. Gardner of the Virus Reference Laboratory, Central Public Health Laboratory, Colindale Ave., London, for kindly carrying out the virus isolation studies.

REFERENCES

1. Calne, R. Y.: Liver transplantation, *Transplant. Rev.* 2: 69, 1969.
2. Gardner, S. D., Field, A. M., Coleman, D. V., and Hulme, B.: New human Papovavirus (B.K.) isolated from urine after renal transplantation, *Lancet* 1: 1253, 1971.
3. Levine, R. S., Warner, N. E., and Johnson, C. F.: Cytomegalic inclusion disease in the gastrointestinal tract of adults, *Ann. Surg.* 159: 37, 1964.
4. Starzl, T. E., with the assistance of Putnam, C. W.: Experience in hepatic transplantation, Philadelphia, 1969, W. B. Saunders Company.
5. Starzl, T. E., Putnam, C. W., Halgrimson, C. G., Schroter, G. T., Martineau, G., Launois, B., Corman, J. L., Penn, I., Booth, A. S., Jr., Groth, C. G., and Porter, K. A.: Cyclophosphamide and whole organ transplantation in humans, *Surg. Gynecol. Obstet.* 133: 981, 1971.