

223

Clinical Heterotransplantation of the Liver

By GEOFFREY R. GILES, HANS J. BOEHMIG, HIROSHI AMEMIYA, CHARLES G. HALGRIMSON AND THOMAS E. STARZL

AT THE UNIVERSITY OF COLORADO there have been two attempts at orthotopic heterotransplantation of chimpanzee livers to pediatric recipients suffering from biliary atresia. The first of these cases has been fully reported,¹ for which reason the following remarks will be confined to observations about the second patient and his animal donor.

METHODS

The Recipient

The child was a 7-month-old male with extrahepatic biliary atresia that had been proved by previous operation. Blood type was AB+. In addition to small size at birth (2.5 Kg.), there had been a striking failure of growth and development. Just before transplantation, the patient's weight was 4.2 Kg. of which a significant fraction was ascites. During the 7 months of life there were recurrent respiratory infections. Pulmonary veno-arterial shunts had developed so that the PO₂ on room air was 59 mm. Hg.

The recipient was first examined at the age of 4 months. In the ensuing 12 weeks the bilirubin ranged from 13.6 to 18 mg. per cent, the alkaline phosphatase was 546-835 International units (normal < 260), and the SGOT consistently was in excess of 135 units. Between the ages of 4 and 7 months, there was deterioration of hepatic functions of synthesis with a reduction of the prothrombin time from 100 to 50 per cent, a decline in the total serum protein from 6.0 to 5.5 Gm. per cent, and a reduction in the serum albumin from 2.9 to 2.6 Gm. per cent. During this 3 months, a cadaveric donor could not be found.

When the child was 6 months old, the thymus gland was removed through a transverse anterior thoracic incision which transected the sternum.²

From the Department of Surgery, University of Colorado Medical Center, and Veterans Administration Hospital, Denver, Colo.

Supported by USPHS Grants AM-06344, AM-07772, RR-00051, AI-04152, RR-00069, AM-12148, AI-AM-08898 and HE-09110.

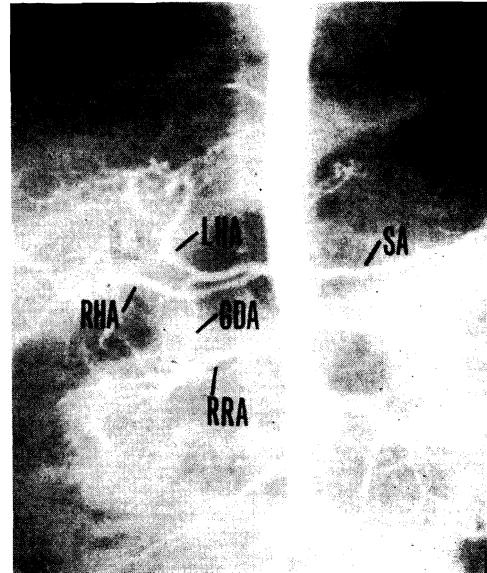


Fig. 1.—Aortogram performed on chimpanzee donor. Note anomalous hepatic arterial supply with right and left branches originating directly from celiac axis. Each kidney was supplied with single renal artery. LHA: Left Hepatic Artery; RHA: Right Hepatic Artery; GDA: Gastroduodenal Artery; RRA: Right Renal Artery; SA: Splenic Artery.

Recovery from the preliminary procedure was uncomplicated.

The Donor

Col. Robert I McIver of the Holloman Air Force Base primate colony permitted blood to be drawn from nine chimpanzees weighing 5 to 15 Kg. The specimens were used by Dr. Fritz Bach of the University of Wisconsin to determine the one-way stimulation they evoked in the child's cultured lymphocytes.⁴ Two of the donor candidates were found to be distinctly less antigenic in this system than the other seven. Furthermore, the mitomycin-treated lymphocytes from these two simian donors caused less pronounced reaction by the patient's lymphocytes than was produced by a panel of human cell lines that were simultaneously

tested as controls.⁴ The animal finally selected for donation weighed 6 Kg. It was A plus blood type. Before transplantation, an aortogram was performed which revealed two hepatic arteries originating from the celiac axis (Fig. 1) as well as two single renal arteries.

To perform the foregoing mixed lymphocyte culture examinations, nearly 50 ml. blood had to be taken from the child on two occasions, or an estimated 15 per cent of blood volume both times. The blood was replaced by two transfusions with possibly tragic consequences as will be discussed later.

Recipient Immunological Studies

The competence of the recipient peripheral lymphocytes was evaluated before and after thymectomy by their ability to undergo blast transformation when exposed in tissue culture to phytohemagglutinin,³ mitomycin-killed lymphocytes from nonrelated people and *Candida albicans* extracts.⁵ With each kind of test, normal responses were obtained.

Serum titers of heterohemagglutinins against the red cells of the actual chimpanzee donor were studied in the recipient before and after transplantation. Similarly, leukoagglutinins⁶ and lymphocytotoxins⁷ were measured against the peripheral white cells of the animal. In addition, whole complement and complement components 1, 3, 4 and 5 were quantitated.^{8,9} Direct Coomb's tests¹⁰ were performed on the recipient red cells with the aid of an antiserum raised in rabbits immunized by four injections of pooled whole chimpanzee serum.

Coagulation Studies

Before, during, and after transplantation repeated arterial samples were taken and analyzed for platelets, euglobulin lysis time, thrombin time, prothrombin time, partial thromboplastin time, fibrinogen, prothrombin, accelerator globulin, antihemophilic globulin, plasma thromboplastin component, and fibrin split products. The methodology of these determinations was the same as in two recent reports from our laboratories.^{11,12}

The Operation

The operation was performed on December 3, 1969, through a long bilateral subcostal incision. The spleen was mobilized and the splenic artery and vein skeletonized. Then, splenectomy was performed. Simultaneously, the left chimpanzee kidney was removed, infused through its artery with a special chilled electrolyte solution¹ to remove all blood, and its renal artery and vein anasto-

mosed end-to-end to the splenic artery and vein. The right chimpanzee kidney was excised 3 hours later and its artery anastomosed end-to-end to a branch of the hepatic artery in the hilum of the liver. The renal vein of the second heterograft was connected end-to-side to the recipient portal vein. Thus, venous outflow from both the renal heterografts was directed into the relatively high pressure splanchnic system (20–25 mm. Hg).

Using a standard orthotopic procedure,¹ the recipient liver was now excised and replaced with a heterograft approximately 5½ hours after the first exposure to the chimpanzee kidney. The ischemia time of the transplanted liver was 62 minutes including the period necessary to cool it by intra-portal infusion with the same kind of solution used earlier for the kidneys. Just before revascularization the recipient was given 3.4 mg./Kg. intravenous heparin. Biliary drainage was established with a cholecystoduodenostomy.

RESULTS

Clinical Observations

The first renal heterograft, which was anastomosed onto the splenic pedicle, became pink after revascularization and excreted a few drops of urine. However, within 5 minutes the organ turned cyanotic and remained so until it was removed 3 hours later. The second kidney, which was inserted high in the hepatic hilum, was pink for more than half an hour before suffering the same fate as the first organ. Even preceding this part of the operation and continuing throughout, the patient had a severe metabolic acidosis, requiring constant correction with sodium bicarbonate and THAM. Ultimately the consequence of this corrective therapy was severe hyponatremia (maximum serum Na 167 mEq./L.).

When the hepatic heterograft was rearterialized it seemed to have a very poor blood supply with the surface of the organ being distinctly cyanotic. However, after the subsequent restoration of the portal venous flow, the liver became homogeneously pink and was not perceptibly different than a good homograft at a similar stage of the procedure. Excretion of bile into the opened gall bladder was quite evident at this time.

For the next hour the child's hemodynamic condition was excellent despite the difficulty in control of metabolic acidosis described earlier. It seemed that a real test of the heterotransplantation was going to be possible until about an hour later when the blood pressure fell to 60 mm. Hg and the pupils became constricted. The abdominal incision was quickly closed. Despite efforts at resuscitation, it was never possible to restore a normal blood pressure. The child died 26 hours after the heterotransplantation without having awakened. During the entire postoperative period he was anuric.

After the transplantation, the total bilirubin fell to 2.3 mg. per cent. The SGOT was always below 144 International units but the alkaline phosphatase rose to 1060 International units. At autopsy, there was approximately 200 ml. of free blood in the peritoneal cavity. The liver had a normal color and the vascular anastomoses were all patent. Histologically, there was essentially no evidence of hepatocellular damage. A few pyroninophilic lymphocytes were in the portal tracts. In the extrahepatic organs, the most significant findings were severe edema of the brain and multiple pulmonary emboli (diagnosed by microscopy) scattered throughout both lungs.

Immunologic Studies

Six weeks before heterotransplantation, the recipient's serum did not contain antidonor lymphocytotoxins. By the time of operation, it was later shown that cytotoxins had appeared, possibly as a consequence of accidental sensitization by the two homologous transfusions that had been made necessary some weeks earlier by the withdrawal of large quantities of blood for testing. The level of the systemic lymphocytotoxins was not affected by transplantation of the first kidney. However, after revascularization of the second chimpanzee kidney and then the liver, all detectable lymphocytotoxic activity disappeared from

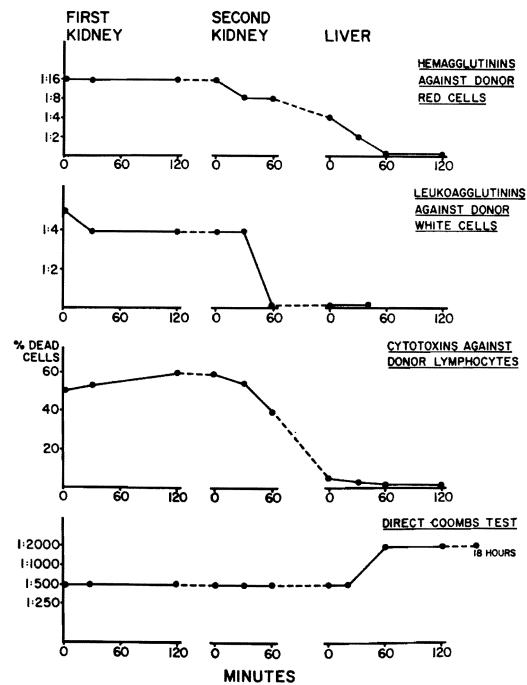


Fig. 2.—Antibodies in serum of recipient arterial blood before, during and after transplantation of two successive kidneys and liver from same chimpanzee donor.

the arterial blood (Fig. 2). Pre-existing antidonor leukoagglutinins and heteroagglutinins in the arterial blood were also reduced and finally eliminated either by the transplantation of the preliminary kidneys, or else after revascularization of the liver (Fig. 2).

Before operation, the rabbit antiserum raised against chimpanzee serum caused agglutination of recipient red cells at a titer of 1:500. This result was not changed by revascularization of the two preliminary renal heterografts but within an hour after revascularization of the liver the titer of the direct Coombs test rose to 1:2000 (Fig. 2). Conceivably the increase in titer may have been due to coating of the red cells with chimpanzee protein either synthesized by or alternatively washed out of the newly revascularized liver.

Complement levels in the systemic blood

Table 1.—Whole-serum Complement and Complement Components Measured During Revascularization of Chimpanzee Kidneys and Liver

	Whole-serum Complement CH50 units/ml.	C1q	Complement C4	Components C3	mg./ml. C5
Day prior to heterotransplantation	33	.137	.366	1.84	.087
2 minutes before first kidney vascularized	28	.127	.240	1.32	.084
90 minutes after first kidney	29	.148	.318	1.36	.076
2 minutes before second kidney	30	.167	.336	1.32	.084
60 minutes after second kidney	24	.118	.318	1.04	.059
2 minutes before liver vascularized	24	.118	.336	1.08	.065
60 minutes after liver vascularized	16	.125	.258	.90	.055
4 hours after liver vascularized	0	.046	.138	.42	.032
16 hours after liver vascularized	0	.049	.204	.42	.030

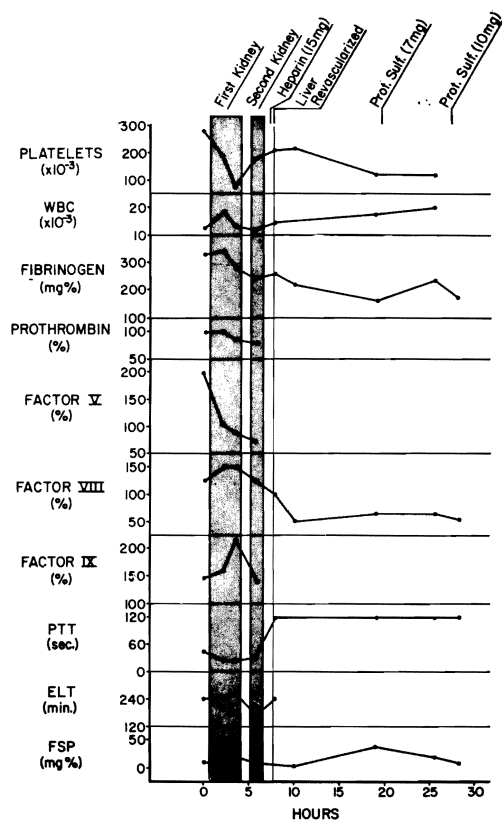


Fig. 3.—Measures of clotting factors, fibrinolytic indices and formed blood elements before and after transplantation of chimpanzee organs. Total body heparinization was carried out before liver transplantation, making impossible subsequent determination of prothrombin, factor V, factor IX and euglobulin lysis time.

were unaffected by the first kidney and showed moderate falls with the second. However, once the liver was vascularized, the level of whole complement fell so that at 4 hours, it was not detectable in the circulating blood and the four components tested were all considerably reduced (Table 1).

Coagulation Studies

At the outset, all of the clotting studies shown in Fig. 3 as well as the thrombin time and prothrombin time were normal or nearly normal. After revascularization of the first chimpanzee kidney, a striking series of transient changes occurred (Fig. 3). There were reductions in the arterial platelets, fibrinogen, prothrombin and accelerator globulin (V) as well as shortening of the euglobulin lysis time (ELT) and the appearance of fibrin split products. At about the same time, there was increased activity of antihemophilic globulin (VIII) and accompanied by marked shortening of the partial thromboplastin time. Taken together the foregoing findings were interpreted as indicating intravascular coagulation (probably triggered within the transplant) and hypercoagulability. The alterations were returning towards normal by the time of the second renal heterotransplantation and were not made worse with restoration of the blood supply of this kidney.

Before the liver was inserted, 3.4 mg./Kg.

heparin were given making further measurement impossible of several of the parameters (Fig. 3). Those which could be followed were not much affected by hepatic vascularization (Fig. 3). After the single dose of heparin, no clots could be obtained with the determinations of the thrombin, prothrombin, and partial thromboplastin time. The anticoagulant in the patient's plasma was thermostable and completely neutralizable in vitro with protamine sulfate (0.05 mg./ml.), one and 20 hours later. However, two intravenous doses of protamine sulfate 12 (7 mg.) and 19 hours (10 mg.) after the initial heparin dose failed to neutralize the heparin effect in the patient.

DISCUSSION

The circumstances under which this and the previous hepatic heterotransplantation¹ were performed were similar. In both cases, the condition of the recipients deteriorated markedly while a search was being conducted for cadaveric donors. Ultimately, the use of a chimpanzee organ was viewed as a desperate therapeutic effort. If heterografts can be made to work, their most urgent need in the future will probably be to replace organs such as the liver and heart, for which long term interim function cannot be provided by machines or instruments analogous to the artificial kidney.

The special feature of the heterotransplantation herein reported was the effort to deplete preformed heterospecific antibodies before arrival of the definitive hepatic graft. This was to be done by preliminary transplantation of the chimpanzee's kidneys. The rationale for such an approach was based upon the work of Clark,¹³ Linn,¹⁴ and ourselves¹⁵ with difficult species combinations including rabbit to dog, pig to dog, and dog to pig heterotransplantations and upon the work of Simpson¹¹ who employed this technique of antibody absorption for homotransplantation to sensitized canine recipients.

In the relatively easy chimpanzee-to-man species combination, it has not actually been established that such a preliminary "screening" procedure is useful. With the early experience of Reemstma and DeWitt and their associates,¹⁶ the only preformed heterospecific antibody that was ever demonstrated in patients was a heat labile hemagglutinin that did not seem to have much avidity, if any, for nucleated chimpanzee cells. Nevertheless, the protocol followed in our recipient assumed for reasons discussed elsewhere^{1,15} that such pre-existing antibodies were in fact significant.

Unfortunately, an additional potentially more serious cytotoxic antibody developed in the hepatic recipient of this report between the time when the simian donor was selected and the actual transplantation. It is probable that this lymphocytotoxin was induced by blood transfusion. If so, the situation was converted to the same exceptionally dangerous one as with homotransplantation to a presensitized recipient.^{11,12,17} Consequently, the case probably did not represent a fair test of the heterograft system being examined.

In fact, certain changes in the liver recipient were more consistent with observations made in both dogs¹¹ and humans^{12,17} who had preformed antidonor antibodies and whose renal homografts underwent rapid rejection than with what is known about the behavior of chimpanzee heterografts in man. For example, the preliminary renal heterografts appeared to be rejected in a hyperacute fashion that would not have been expected from the earlier reported experience of Reemstma.¹⁶ At this time there was evidence of absorption of several kinds of antibodies by the kidneys. Subsequently, the new liver continued this absorption along with complement depletion. There were also highly significant changes of various clotting measurements indicating intravascular coagulation. The role of coagulation in hyperacute rejection of both homografts^{11,12,17} and heterografts¹⁸ has been the

subject of several recent articles. It is conceivable that the thrombi distributed extensively throughout both lungs were the consequence of such an immunologically mediated coagulopathy.

In spite of the foregoing evidence, it cannot be stated with certainty that the tragic outcome in this case had a strictly immunologic etiology. It could be argued just as persuasively that the patient died from a preexisting and uncorrected metabolic abnormality consisting first of metabolic acidosis compounded later by hypernatremia. The sudden intraoperative vascular collapse and the subsequent neurologic deterioration could have been on this basis rather than because of a hyperacute hepatic rejection. Indirect evidence in favor of the nonimmunologic interpretation was the fact that a number of liver functions were well maintained postoperatively and that the graft had little evidence of injury at the time of autopsy one day later.

SUMMARY

A 7-month-old child with extrahepatic biliary atresia was treated by orthotopic transplantation of a chimpanzee liver after

preliminary revascularization in the recipient of both kidneys from the same animal donor for the purpose of depleting preformed heterospecific antibodies. Unfortunately, there was evidence that the child was presensitized to white cell antigens by preoperative blood transfusions with the consequent development of lymphocytotoxic antibodies that reacted with donor tissues. When the chimpanzee kidneys were revascularized in the recipient, they appeared to be hyperacutely rejected. The liver did not suffer the same fate but the child failed to awaken from anesthesia and died one day later. It was not possible to determine if the death was caused by metabolic complications that are common with this procedure even when homografts are used, if the employment of a chimpanzee liver had any specific role in the tragic outcome, or if a presensitized state was an important adverse factor.

ACKNOWLEDGMENT

Assays in Table 1 were kindly made by Peter Kohler, M.D., Department of Clinical Immunology, University of Colorado.

REFERENCES

1. Starzl, T. E.: Experience in Hepatic Transplantation. Philadelphia, Saunders, 1969.
2. Porter, K. A., Andres, G., Groth, C. G., Putnam, C. W., Penn, I., Halgrimson, C. G., Starckie, S. J., and Brettschneider, L.: Thymectomy and renal homotransplantation. *Clin. Exp. Immunol.* 6:803, 1970.
3. Bach, F. H., and Voynow, N. K.: One-way stimulation of mixed leukocyte cultures. *Science* 153:545, 1966.
4. Nowell, P. C.: Phytohemagglutinin: An initiator of mitosis in cultures of normal human leukocytes. *Cancer Res.* 20:462, 1960.
5. Shannon, D. C., Johnson, G., Rosen, F. S., and Austen, K. F.: Cellular reactivity to *Candida albicans* antigen. *New Eng. J. Med.* 275:692, 1966.
6. von Rood, J. J., and von Leuwen, A.: Leukocyte grouping. A method and its application. *J. Clin. Invest.* 42:1382, 1963.
7. Terasaki, P. I., and McClelland, J. D.: Microdroplet assay of human serum cytotoxins. *Nature (London)* 204:998, 1964.
8. Kabat, G. A., and Mayer, M. M.: *Experimental Immunochemistry* (ed. 2). Springfield, Ill., Charles C. Thomas, 1961.
9. Kohler, P. F., and Muller-Eberhard, H. J.: Immunochemistry quantitation of the third, fourth, and fifth components of human complement: concentrations in the serum of healthy adults. *J. Immunol.* 99:1211, 1967.
10. Coombs, R. R. A., Mowant, A. G., and Race, R. R.: A new test for detection of weak and incomplete Rh agglutinins. *Brit. J. Exp. Path.* 26:255, 1945.
11. Simpson, K., Bunch, D., Amemiya, H., Boehmig, H. J., Wilson, C. B., Dixon, F. J., Coburg, A. J., Hathaway, W. E., Giles, G. R., and Starzl, T. E.: Humoral antibodies and coagulation mechanisms in the accelerated or hyperacute rejection of renal homografts in sensitized canine recipients. *Surgery* 68:77, 1970.
12. Starzl, T. E., Boehmig, H. J., Amemiya, H., Wilson, C. B., Dixon, F. J., Giles, G. R., Simpson, K. M., and Halgrimson, C. G.: Clotting changes

including disseminated intravascular coagulation during rapid renal homograft rejection. *New Eng. J. Med.* 283:383, 1970.

13. Clark, D. S., Foker, J. E., Pickering, R., Good, R. A., and Varco, R. L.: Evidence for two platelet populations in xenograft rejection. *Surg. Forum* 17:264, 1966.

14. Linn, B. S., Jensen, J. A., Portal, P., and Snyder, G. B.: Renal xenograft prolongation by suppression of natural antibody. *J. Surg. Res.* 8:211, 1968.

15. Giles, G. R., Boehmig, H. J., Lilly, J., Amemiya, H., Takagi, H., Coburg, A. J., Hathaway, W. E., Wilson, C. B., Dixon, F. J., and Starzl, T. E.: Mechanism and modification of rejection of

heterograft between divergent species. *Transplantation Proc.* (in press).

16. Reemstma, K., McCracken, B. H., Schlegel, J. J., Pearl, M. A., Pearce, C. W., DeWitt, C. W., Smith, P. E., Hewitt, R. L., Flinner, R. L., and Creech, O., Jr.: Renal heterotransplantation in man. *Ann. Surg.* 160:384, 1964.

17. Starzl, T. E., Lerner, R. A., Dixon, F. J., Groth, C. G., Brettschneider, L., and Terasaki, P. I.: Shwartzman reaction after human renal transplantation. *New Eng. J. Med.* 278:642, 1968.

18. Rosenberg, J. C., Broersma, R. J., Bullemer, G., Mammen, E. F., Lenaghan, R., and Rosenberg, B. F.: Relationship of platelets, blood coagulation fibrinolysis to hyperacute rejection of renal xenografts. *Transplantation* 8:152, 1969.