

Clinical Liver Transplantation

THOMAS E. STARZL, LAWRENCE BRETTSCHEIDER,
ISRAEL PENN, GEOFFREY GILES, REGINALDO PICACHE
& CHARLES W. PUTNAM

During the last two years, there has been increasing evidence that liver transplantation will have an important role in the treatment of otherwise fatal human hepatic disease (Calne & Williams 1968, Calne *et al.* 1968, Starzl & Putnam 1969, Starzl *et al.* 1968, 1969a/b). The optimism that has infected workers in this field needs little other justification than the fact that 5 patients have already lived for more than a year after removal of their diseased liver and its replacement (orthotopic transplantation) with a cadaveric homograft (Starzl & Putnam 1969). At a symposium convened by Professor Roy Calne in early April, 1969, at Cambridge, England, it was noteworthy that survival of at least a month after this kind of operation was reported from seven different centers in widely separated cities of the world (Boston, Cambridge, Denver, Louvain, Minneapolis, New York, and Paris).

It will not be the purpose of the present communication to dwell upon such encouraging aspects of these clinical endeavors. Instead an attempt will be made to analyze the causes for the morbidity and mortality that have so far remained at an unacceptably high level. In so doing, the greatest attention will be focused upon problems encountered and observations made in our first 26 human recipients of orthotopic liver transplants who were treated between 1 March 1963 and 11 May 1969; the interested reader is also urged to consult Calne's important reports on the Cambridge series (Calne & Williams 1968, Calne *et al.* 1968). Additional comments will also be

Department of Surgery, University of Colorado School of Medicine, and the Veterans Administration Hospital, Denver, Colorado.

Supported by United States Public Health Service grants AM-06344, AM-07772, FR-00051, AI-04152, FR-00069, AM-12148, and AI-AM-08898.

made about the alternative procedure of auxiliary hepatic transplantation which involves the insertion of a second liver at an ectopic site without removal of the host's own organ.

ORTHOTOPIC LIVER TRANSPLANTATION

Both in the experimental laboratories and clinically, the best results have been obtained with liver replacement rather than with transplantation of an auxiliary organ. In our 26 clinical trials with the orthotopic procedure, the indication for operation was biliary atresia in 12 patients, hepatic cell carcinoma or cholangiocarcinoma in 12, and post-hepatic or alcoholic cirrhosis in the remaining 2.

Life Survival

The last recipient in the series is alive after 7 weeks. Because of her short follow-up, this patient will not be included in the statistics. The outcomes

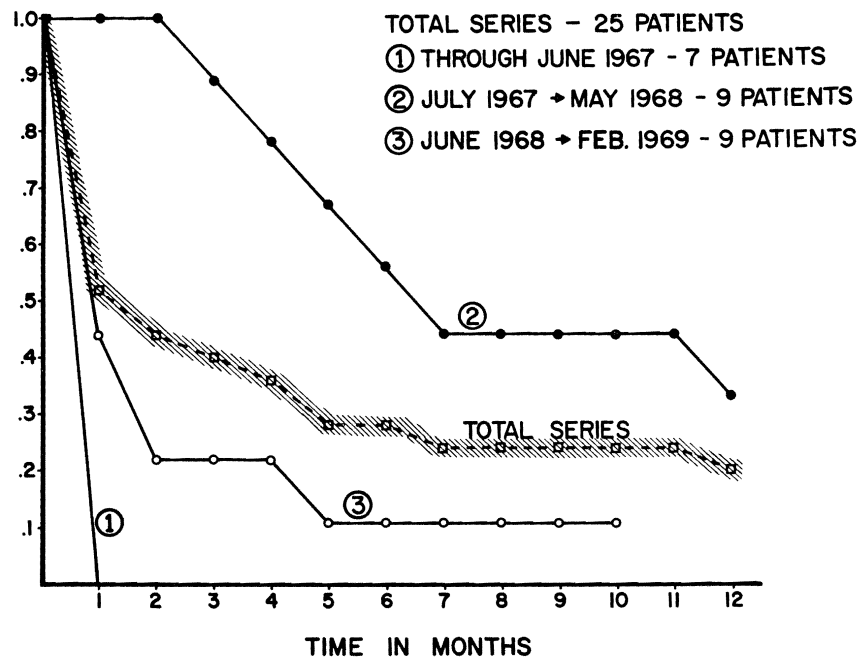


Figure 1. Life-survival curve of 25 patients treated at our institutions with orthotopic liver transplantation between March 1963 and February 1969. The shortest follow-up for recipients who are still alive in June 1969 is 12 months. Thus the curves may be considered complete to one year. The results have also been divided according to the first, second, and third intervals of our total experience.

in the 25 other cases are shown in Figure 1. Twelve of these 25 patients, including the first 7, did not live through the first postoperative month. As a consequence, the life-survival curve has a shape that is very similar to that of the first trials, 6 and 7 years ago, of renal homotransplantation between non-related individuals.

The reasons for the steep acute loss rate will be returned to below. Here it will be remarked only that all deaths within the first 2 postoperative months were the consequence of the use of badly damaged homografts or were caused by a technical surgical accident of one kind or other. The mortality subsequent to 2 months was either caused by partial gangrene of the liver or else was related directly or indirectly to the recurrence of the malignancy for which treatment was originally undertaken. At 3, 6, 9, and 12 months, there were 10, 7, 6, and 5 patients respectively still alive. Since the shortest follow-up of the living patients is now 12 months, the life-survival curve of the 25 recipients (Figure 1) is now complete for the first year.

The Technical Problems

As already emphasized, it is important to recognize how many of the early attempts at liver transplantation failed solely or at least partly because of factors which could collectively be termed 'technical'. Correction of these deficiencies in the procedure will be essential before the potential value of hepatic replacement can be realized. The errors made and the complications encountered in the past cases have been classified below.

The use of damaged organs. There are means by which dog livers can be protected from ischemic injury. From the simplest to the most complex, these include cooling by intravascular infusion of the homograft with chilled solutions (Fonkalsrud *et al.* 1967, Moore *et al.* 1960, Schalm 1968, Starzl *et al.* 1960), provision of a hypothermic post mortem circulation with a heart-lung machine (Marchioro *et al.* 1963, McKneally *et al.* 1965, Mikaeloff *et al.* 1965), and cold perfusion of the extirpated organ which is kept in a hyperbaric oxygen chamber (Brettschneider *et al.* 1968). Canine livers can be kept in good condition for at least 2 hours with cooling alone, an interval that can be extended by several hours with the heart-lung technique. Using the combination of cooling, perfusion, and hyperbaric oxygenation, homografts have been successfully stored for as long as 24 hours (Brettschneider *et al.* 1968). Satisfactory human livers have been obtained with each of the 3 foregoing methods of conservation.

Nevertheless, adequate liver function was not obtained after any of the first 9 orthotopic transplantations carried out between early 1963 and the spring of 1967. In our own 7 cases during that era (Starzl & Putnam 1969),

it is almost certain that an unwise choice of donors was responsible. They were generally in agonal condition with an ineffective circulation for many hours before a final cardiac arrest; moreover, all the adult donors were old (average 69 years). The abnormalities of homograft function in the recipients were evidently a reflection of the combined injury incurred in the terminal phases of donor life, during the normothermic post mortem 'dead time', and perhaps least importantly during the subsequent interval after active efforts had been instituted to cool and preserve the liver.

In spite of the transplantation of livers of unacceptable quality, 6 of our first 7 recipients survived transplantation and lived for 6.5 to 23 days. Intraoperatively, grave bleeding diatheses developed which were controlled with the greatest difficulty (Starzl *et al.* 1963, von Kaulla *et al.* 1966).

OT 7

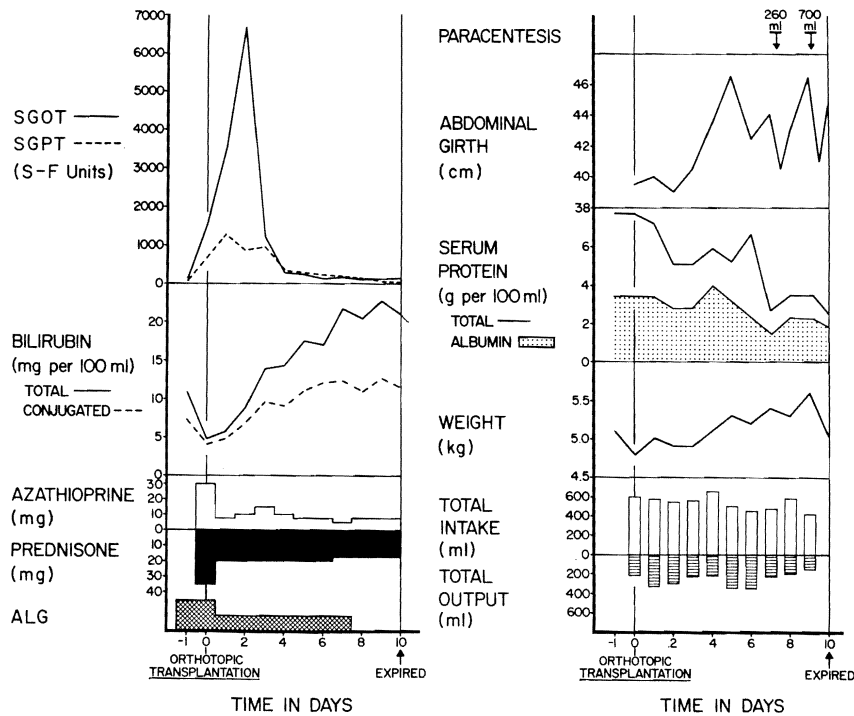


Figure 2. The course of an 11-month-old child with biliary atresia after orthotopic transplantation of an unsatisfactory liver. The hepatic function tests were markedly abnormal from the beginning. Fluid retention became a progressively severe problem. At autopsy, the homograft had massive necrosis. The numbers in the upper right corner refer to fluid removed by paracentesis.

Afterwards, other manifestations of major hepatic injury were promptly manifest in the standard liver function tests (Figure 2). Moreover, the patients developed a 'third space' syndrome. Ascites and anasarca appeared as striking falls were measured in the concentrations of the serum proteins (Figure 2). The patients were bedridden, consistently unable to eat, and extraordinarily prone to a variety of fulminating bacterial and fungus infections (Fulginiti *et al.* 1968). Several developed gastrointestinal hemorrhage in the postoperative period.

In subsequent cases, donor selection was far more discriminating and the methods of preservation were more effectively applied. Nevertheless,

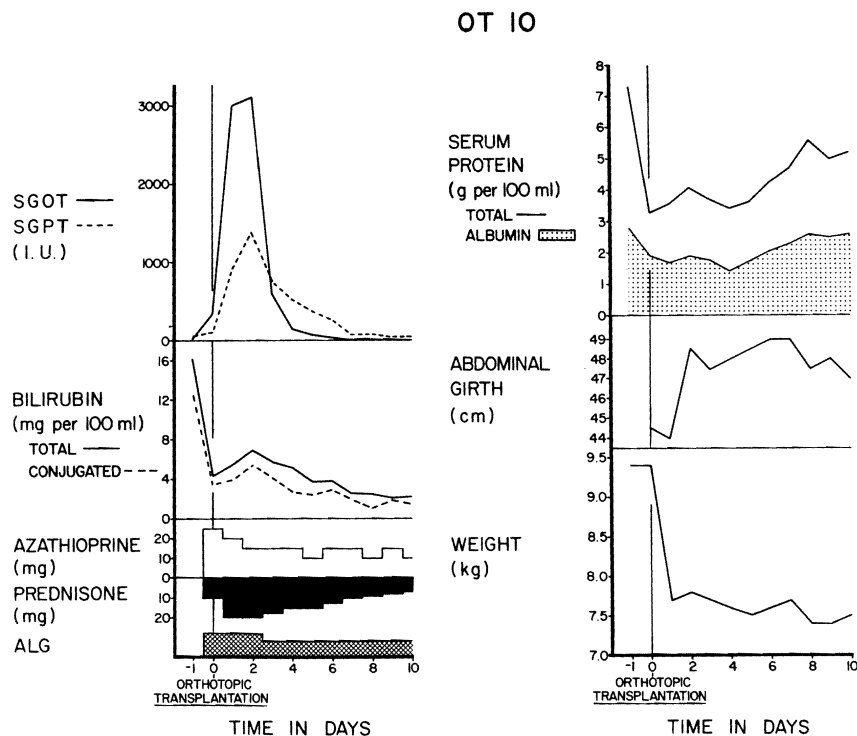


Figure 3. The early course of a patient after orthotopic hepatic transplantation. The liver was cooled by intraportal infusions 6 minutes after death was pronounced on the basis of cardiac arrest. The organ was then excised and placed in a hyperbaric conservation unit (Brettschneider *et al.* 1968). The time from death to homograft revascularization was 271 minutes. Although the liver sustained a highly significant ischemic injury, it provided adequate initial function and cleared the pre-existing hyperbilirubinemia. Nevertheless there was very pronounced hypoproteinemia. Ascites developed which resolved as the serum protein values subsequently improved. The child developed partial gangrene of the right liver lobe one month after operation and eventually died more than 6 months after the transplantation.

some of the same events were evident in the early postoperative period of the recipients even though bilirubin clearance and most other measures of liver function were excellent from the beginning. In particular, rapid declines in serum protein concentrations were almost invariably documented (Figure 3). However, recovery from this abnormality was prompt. The patients who did not suffer other kinds of complications were able to eat and to ambulate within a few days. The events of their subsequent convalescence were determined by factors other than initial malfunction of the transplanted organs.

Mechanical calamities. Imperfections in the operative procedure other than the transplantation of a badly damaged organ cost the lives of 7 more patients in the first 2 postoperative months. The most rapidly lethal complications were occlusions of the total hepatic arterial supply by thrombosis or kinking (3 cases) or thrombotic portal vein occlusion (1 case). The patients died in $\frac{1}{2}$ to 11 days. In all but one of these cases, the technique of vascular reconstruction had been made complex by anomalies of the hilar vessels of the host, of the homograft, or of both (Starzl & Putnam 1969, Starzl *et al.* 1969a). The need to deal with the abnormal anatomic situations might have been avoided if aortography had been performed preoperatively in the recipients and possibly in the donors as well.

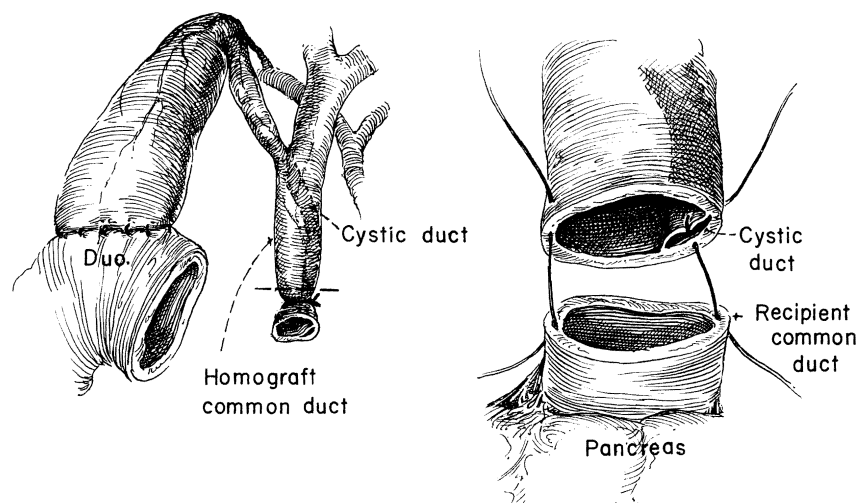


Figure 4. A homograft anomaly encountered during orthotopic transplantation. Left – The cystic duct passed posterior to the common duct and descended for almost 2 inches as one compartment of a double-barreled lumen. The distal ligature caused total biliary obstruction. Right – Three and a half days later the gall bladder was removed and biliary continuity restored with a choledochocholedochostomy.

Anomalies of the homograft extrahepatic biliary duct system were responsible for 2 potentially avoidable tragedies (Starzl & Putnam 1969). In both cases, the cystic duct descended as part of a double-barreled structure before finally entering the common duct at a very low level. Complete biliary obstruction was produced iatrogenically by the mechanism shown in Figure 4, left. The first patient died 10 days after the transplantation. The complication was recognized in the second recipient and corrected 3 days later by performance of a choledochocholedochostomy (Figure 4, right). The secondarily constructed bile duct anastomosis leaked, leading to death from peritonitis after 39 days.

The death of another patient, a 23-year-old woman, was indirectly ascribable to an unexpected accident at the original operation. In removing the host liver and the contiguous segment of inferior vena cava, it is necessary to sacrifice the right adrenal vein (Figure 5); this does not usually cause difficulty. However, her right adrenal gland underwent venous infarction and ruptured one day later resulting in a massive intra-abdominal hemorrhage. Right adrenalectomy was performed. She died 35 days post-

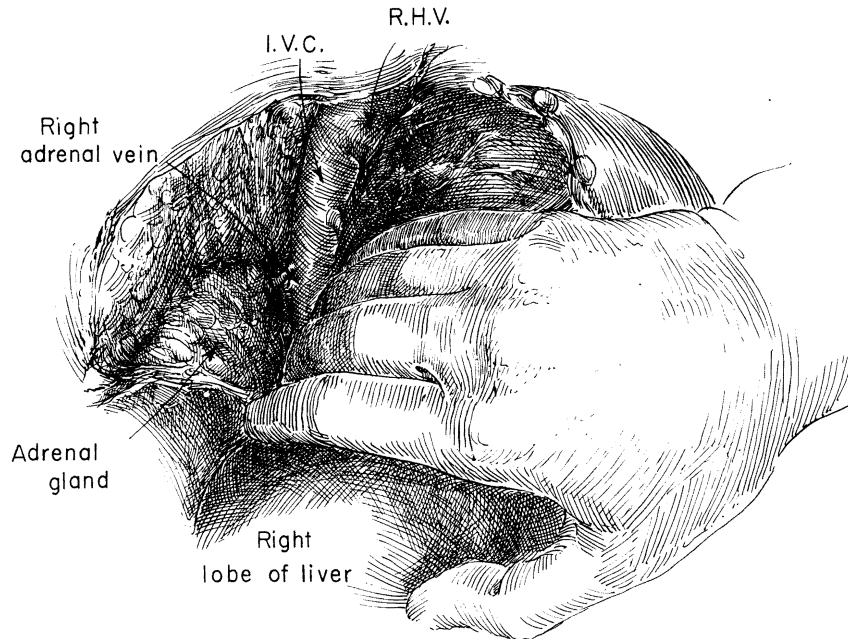


Figure 5. Retraction of the liver to the left. The bare area of the right hepatic lobe has been opened, exposing the adrenal gland. The right adrenal vein is ligated and divided. This is usually the only posterior tributary to the retrohepatic vena cava. At this stage of the dissection, the right hepatic vein (R.H.V.) can be identified.

operatively and was found to have subphrenic infections as well as pneumonitis.

Pulmonary embolization. As already mentioned, a vital factor in the deaths of the first 7 recipients in our series was poor early liver function. In addition, the first 3 of these patients who survived operation were found at autopsy from 6½ to 22 days later to have major pulmonary emboli. In these cases, external plastic bypasses connecting the femoral and jugular systems had been used to decompress the obstructed portal and/or the inferior vena caval systems during the anhepatic stage of the operation. Thrombi were later found in the iliac vein or inferior vena cava of 2 of the patients. It was suspected that the complication was related to the trauma caused by insertion of the temporary prosthesis (Starzl & Putnam 1969, Starzl *et al.* 1963, von Kaulla *et al.* 1966).

Subsequently it has become clear that this kind of venous decompression is unnecessary. In the human, both the portal vein and the suprarenal vena cava can be safely cross-clamped for long enough to remove the host liver and to replace it with a homograft. The abnormal venous collaterals that are usually present in patients with hepatic disease probably contribute to the safety with which this can be done. The same thing has been shown to be true in dogs submitted to bile duct ligation several weeks or months before the performance of orthotopic transplantation (Picache 1969).

Patterns of Acute Rejection (First 2 months)

In most of the patients described in the preceding section, it could not be accurately determined whether and to what extent rejection contributed to the recorded liver function abnormalities. However, this was possible in a number of other recipients who had good initial homograft performance. With these favorable circumstances, which were present in 13 instances, subsequent changes in the function or size of the transplanted livers were attributed to an immunologic etiology. The immunosuppressive treatment provided for all the patients to be discussed now consisted of azathioprine, prednisone, and horse antilymphocyte globulin (ALG). The ways in which

Figure 6. Antero-posterior liver scans performed with 99M-technetium in an orthotopic recipient. The transplantation was performed for extrahepatic biliary atresia. The days after operation are shown. Note the marked hepatomegaly during the third to fifth postoperative weeks at the time of an anicteric rejection; isotope concentrating ability was not perceptibly altered. Compare with Figure 7 and note that the organ swelling occurred coincident with rises in the serum enzymes. Much later in the course jaundice developed. At that time the liver scan did not show hepatomegaly, as exemplified by the 11-month examination.

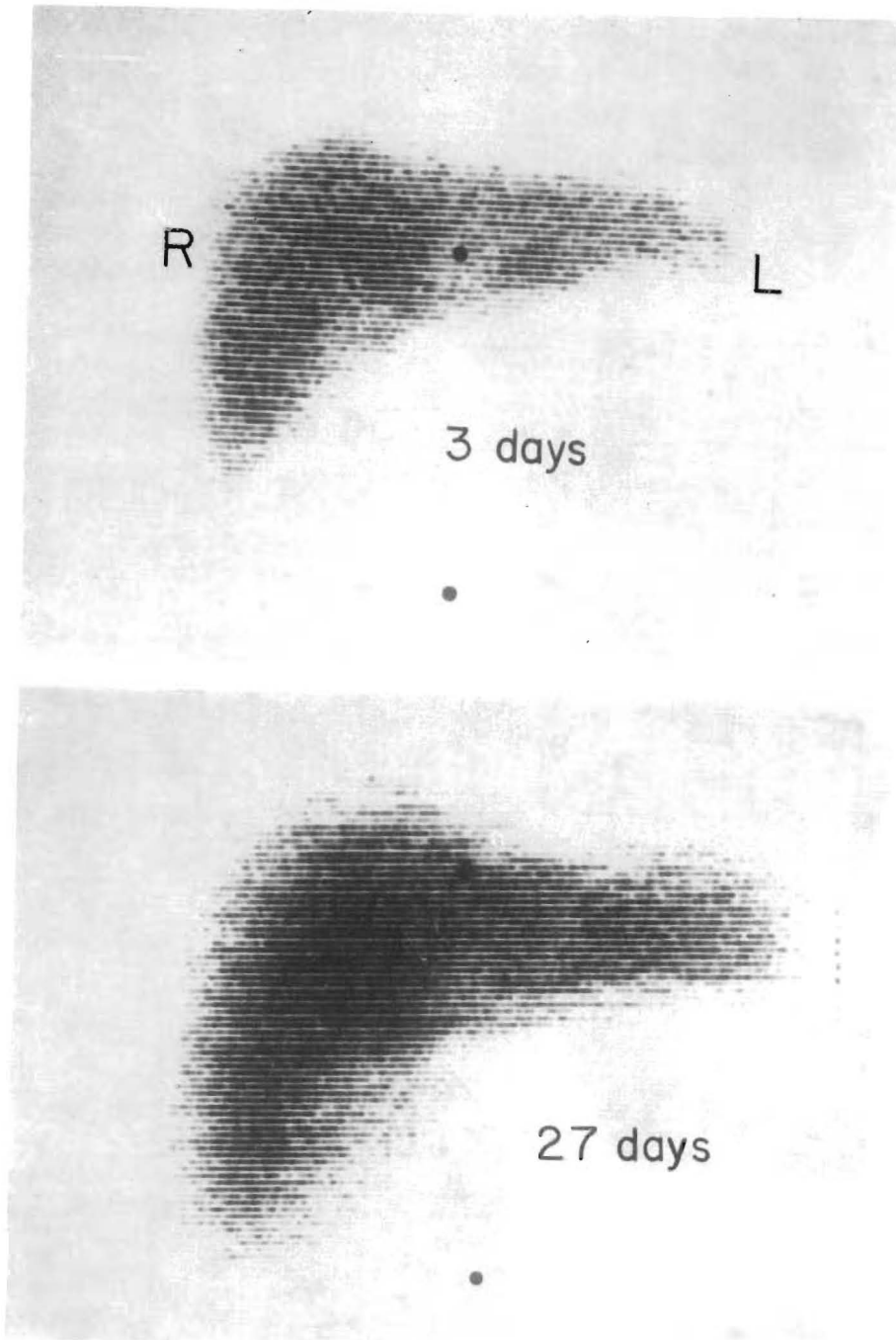


Figure 6 (text, see p. 10)

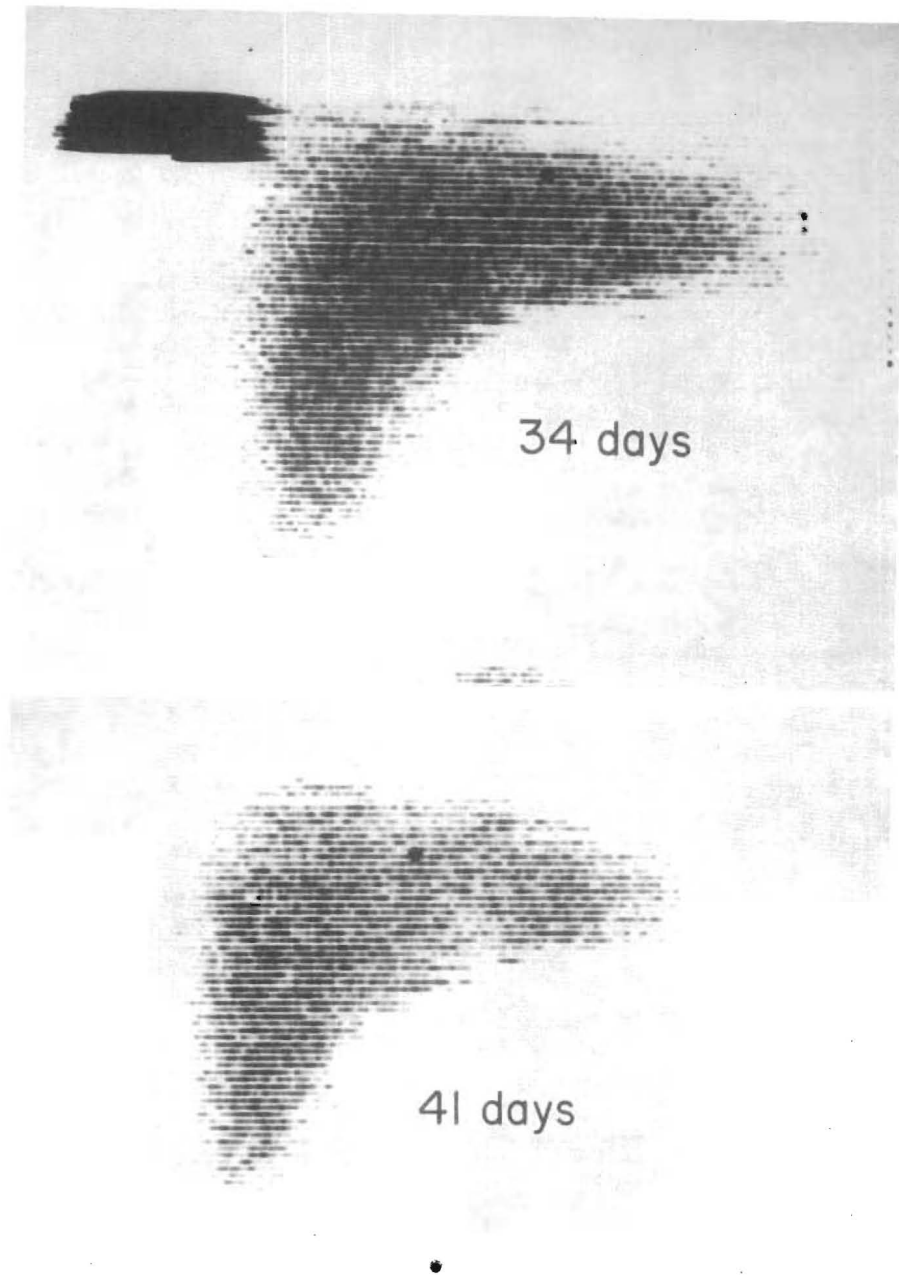


Figure 6 (text, see p. 10)

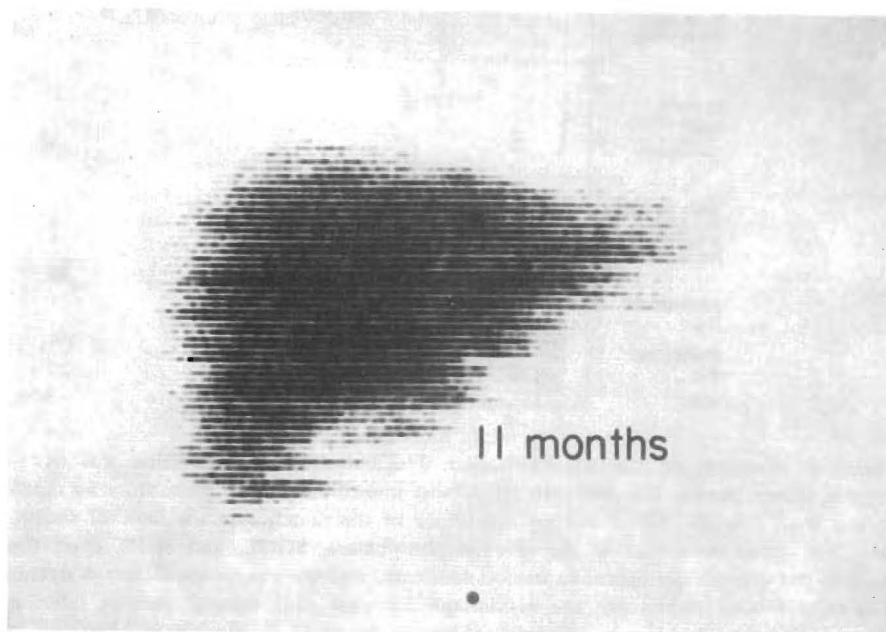
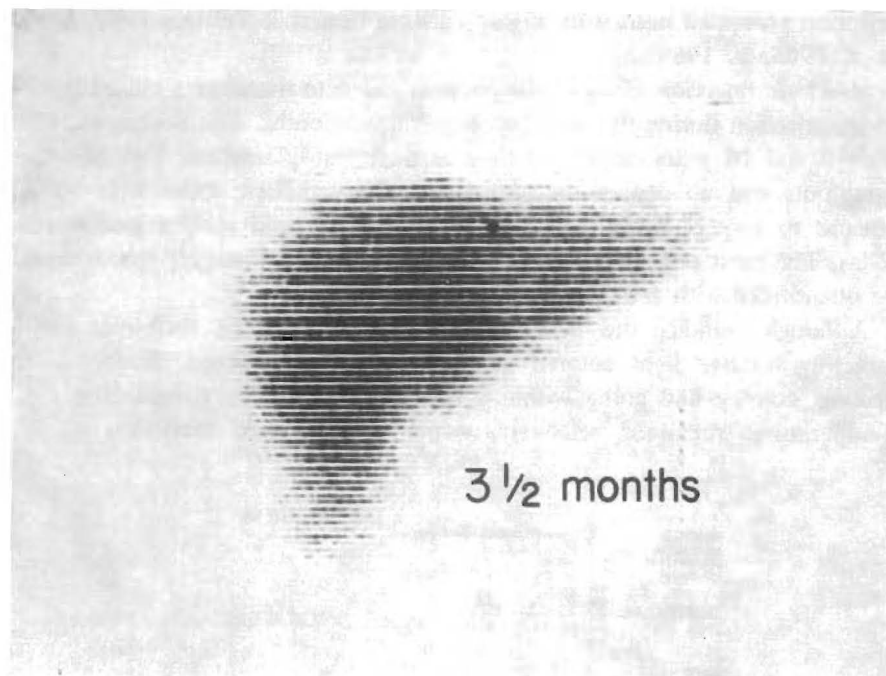
Figure 6 (text, see p. 10)

rejection presented itself were highly variable (Starzl & Putnam 1969, Starzl *et al.* 1968a/b, 1969a/b).

Anicteric rejection. Two of the patients failed to manifest a clinically obvious rejection during the first 2 postoperative months. The recipients, who were 2 and 16 years old at the time of their transplantation, had no overt symptoms and no depression of appetite. Nevertheless, there were sound reasons to suspect that they passed through very mild early rejection episodes. The most objective evidence was palpable hepatomegaly which could be quantitated with serial liver scans (Figure 6).

Although jaundice did not develop, the stools of the recipients intermittently became light colored and the urine dark. These changes were fleeting, coming and going within a few hours or in the course of a day. Temperatures remained relatively normal. There were variations in the

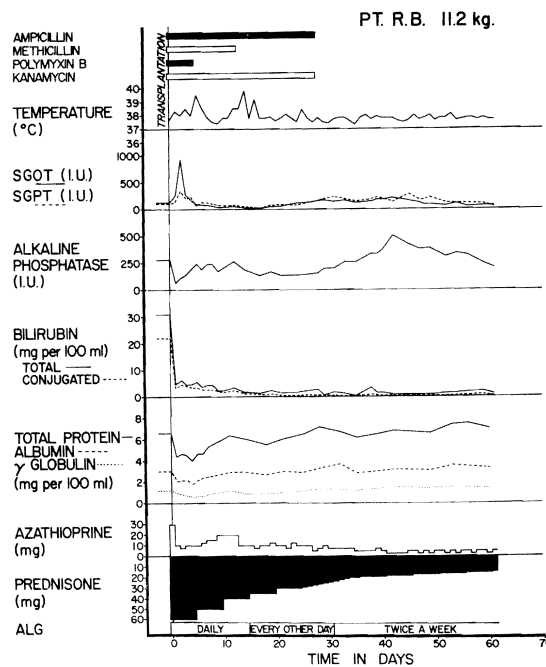


Figure 7. Example of subclinical rejection. The indication for operation was extrahepatic biliary atresia. The bilirubin fell almost immediately from more than 30 mg% to less than 5 mg%. There was no recurrence of the jaundice in the interval shown. However, there were rises in the alkaline phosphatase, SGOT, and SGPT from the third to the seventh postoperative weeks. Antibiotic therapy was stopped after 4 weeks. The temperatures shown are the maximums for each day. Several months later, a delayed rejection developed; the late course of the child is graphically depicted in Figure 27. (By permission of *Ann. Surg.* 168, 392, 1968.)

serum transaminase and the alkaline phosphatase (Figure 7). Other measures of liver function were not affected.

At the time these patients were followed it was not fully appreciated that a subclinical rejection was occurring. Major adjustments were not made in the doses of the immunosuppressive drugs and in fact the daily quantities of steroids which were already being reduced were slowly decreased even more. Fortunately, the various changes described above gradually returned toward although not completely to the pre-rejection state. The major swelling decreased (Figure 6) and the abnormalities in the enzyme determinations slowly improved (Figure 7).

Rejection crisis. There were 3 recipients who passed through rejections which evolved so suddenly that they have been termed crises. The onset came 6 to 29 days after operation. The process developed with extreme

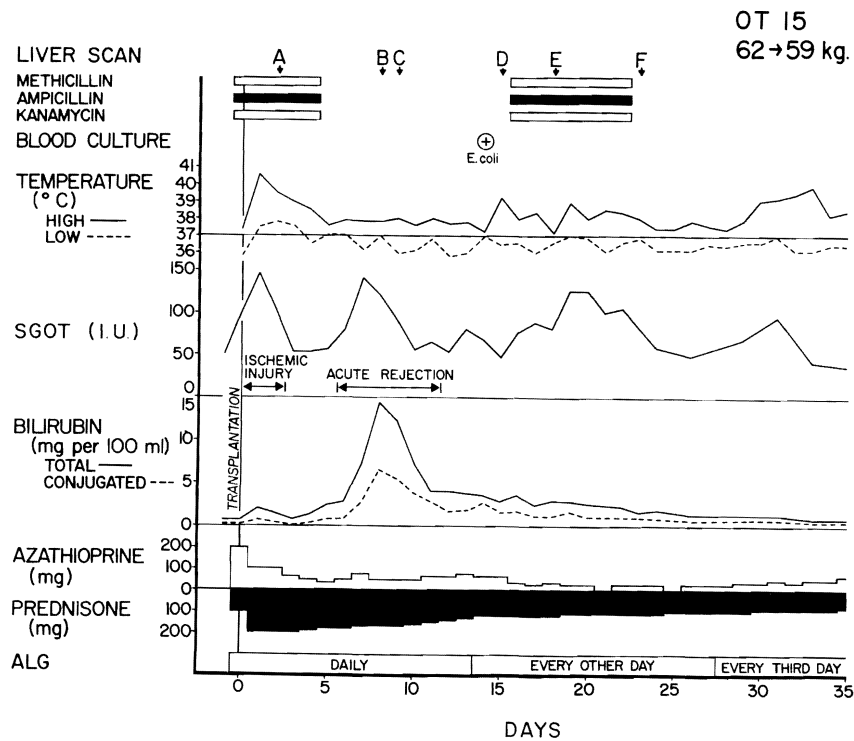


Figure 8. The postoperative events in a 42-year-old recipient of an orthotopic homograft. An explosive rejection began on the sixth day, reached a peak within 2 days, and receded promptly. Gram-negative bacteremia was diagnosed from a blood specimen obtained on post-transplantation day 14. The liver scans indicated by the letters A-F are shown in Figure 10. Note that the immunosuppressive therapy was actually lightened with the development and evolution of the rejection episode.

abruptness, reached a peak within a day or two, and then receded with surprising rapidity. Two of the 3 patients developed hyperpyrexia and became acutely ill.

The recipients were aged 42, 23, and 4 years. All 3, especially the 2 older ones, complained of pain in the center of the back which occurred intermittently, sometimes extended to the right flank or right upper quadrant,

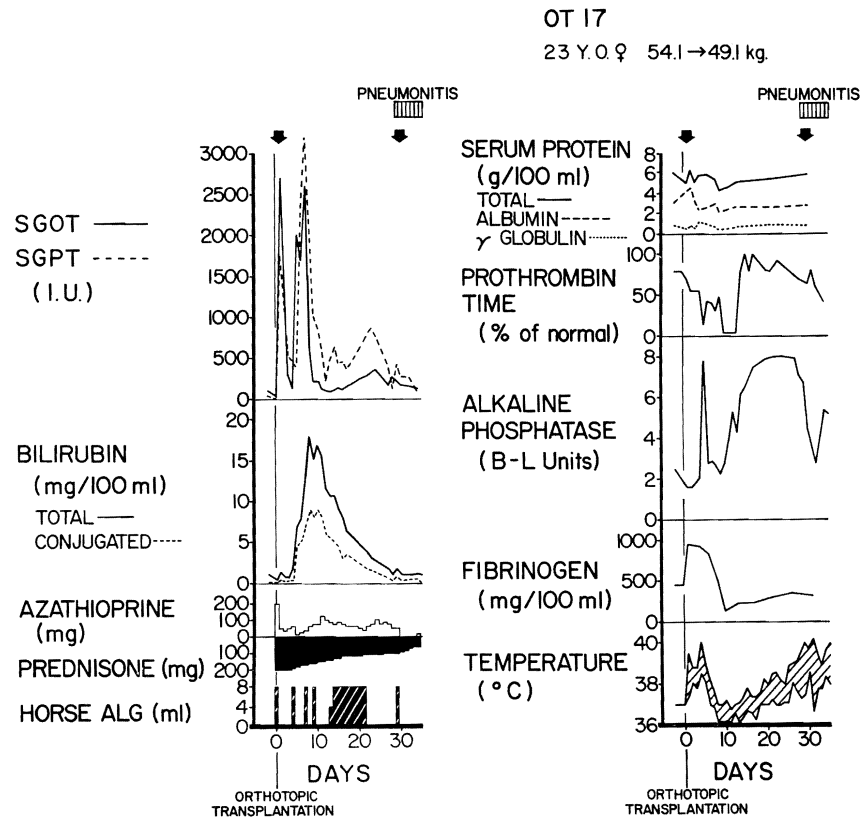


Figure 9. The course of a patient who underwent a violent rejection crisis after orthotopic liver transplantation. The first abdominal re-exploration (arrow) was for the control of bleeding. Even before the onset of jaundice, her course was markedly febrile. Note the drastic depression of prothrombin time on postoperative days 10 through 13. Recovery from the rejection crisis was prompt but the patient died of *Pseudomonas* pneumonia after 35 days. The radiographic changes in the lung were first thought to be the consequence of pulmonary emboli. Consequently, intravenous heparin therapy was started. This resulted in intra-abdominal hemorrhage, necessitating the second laparotomy (arrow). The alkaline phosphatase values are in Bessy-Lowry units (normal 1 to 3). Normals for the SGOT are less than 50 units.

and was relieved by mild analgesics. Extreme fatigability and anorexia were prominent complaints but there was no loss of mental acuity.

With the onset of rejection the stools became pale and the urine dark colored. The serum bilirubin concentrations rose from essentially normal to levels of 6, 14, and 18 mg% within a 24 to 48 hour period (Figures 8 and 9). About half the bilirubin was in the conjugated form. Associated with or slightly preceding the icterus were increases in the alkaline phosphatase. The SGOT and SGPT rose (Figure 8) but to alarming levels in only one case (Figure 9). Other determinations of hepatic function were variably affected. In the mildest example of abrupt rejection there were no changes at all in the concentration of total or fractional serum proteins or in the prothrombin times; the picture was not really distinguishable from that of very transient intra- or extrahepatic biliary obstruction.

In contrast, there was deterioration of every measured liver function in the patient with the most severe rejection crisis. The total serum protein and albumin concentrations began to fall within a few days (Figure 9). There were also life-threatening changes in the clotting factors. For example, the prothrombin times fell to essentially 0 per cent and remained there for almost a week.

The abnormalities of liver function in a third patient were between these two extremes (Figure 8). In this case, as in the others, hepatomegaly became evident by palpation. However, with liver scanning the transplanted organ actually appeared to have shrunk, presumably because of its reduced ability to take up the 99M-technetium isotope. Moreover, there appeared to be a regional loss of isotope concentration affecting mainly the left hepatic lobe (Figure 10). This portion of the homograft was well seen on the scan one day later but partially disappeared again 2 weeks postoperatively. On the latter occasion, gram-negative bacteria (*E. coli*) were cultured from the peripheral blood. Subsequently, the full dimensions of the transplant were restored as the patient made a full recovery (Figure 10).

Serial liver scanning in this case probably provided a crude means of obtaining the sort of information that has been sought in dogs with more direct techniques. Groth *et al.* (1968) showed striking reductions in hepatic blood flow at the time of canine liver rejection. It is not difficult to conclude that the same kinds of flow changes with remissions and exacerbations were present in the clinical cases to account for the bizarre and volatile abnormalities of the liver shadows as viewed by scanography.

The concept that drastic declines in hepatic blood flow were responsible for the 'disappearing liver' is consonant with the other findings at about the same time, including biochemical measures in the serum suggesting variable hepatocyte necrosis. The invasion of the ischemic homograft by micro-

organisms from the adjacent intestinal tract under these circumstances would not be surprising. This was apparently the pathogenesis (Figure 11) of the gram-negative septicemia.

The immunosuppressive treatment was not increased. This approach during episodes of hepatic rejection was different from that which is standard practice in our institution after renal transplantation. When renal homografts undergo deterioration, steroid doses are invariably increased and maintained at whatever levels are necessary to restore good kidney function. With the liver the assumption was made that return of hepatic function would occur without such heroic measures. The expectation that reversal of hepatic rejection would be less dependent on the intensification of treatment than is the case with the kidney was based on the results of animal investigations. In both the dog and pig, spontaneous resolution of hepatic rejection often occurs without any change in therapy or in some animals in the absence of any therapy at all (Starzl & Putnam 1969). It was hoped that the same thing would apply to humans.

This point of view received support from the prompt improvement of the 3 patients and in fact the rejections in each instance reversed with surprising rapidity. However, it might have been safer to have been more aggressive, particularly with the use of prednisone. In a group of patients to be described further on, it is almost certain that efforts to keep the steroid doses as small as possible contributed to eventual devitalization of large areas of the homografts (septic hepatic infarction).

The general care of the patients with rejection crisis included the provision of a strict antacid diet, vitamin supplementation (especially K), and bronchopulmonary care. Fluid intake was restricted if edema became detectable or in the event of excessive weight gain; with amelioration of the crisis there was a brisk diuresis. Because of the evidence that the transplanted organs were in danger of being invaded by intestinal bacteria, or that this had already happened in one case, intensive antibiotic treatment was maintained either continuously or intermittently (Figure 8) throughout the rejection episodes and for some time afterwards.

Figure 10. Antero-posterior liver scans obtained with ^{99m}Tc -technetium in the patient whose course is shown in Figure 8. Note the temporary disappearance of portions of the homograft in the eighth and fifteenth postoperative days; the first of these occasions was at the beginning of an explosive rejection crisis. At the time of the fifteenth-day scan, the patient had developed gram-negative septicemia, presumably from a hepatic focus. The remittent changes in the liver scans were thought to be due to variations in hepatic blood flow during the rejection crisis. The patient recovered completely from these episodes and was discharged from the hospital 65 days post-operatively. Correlate the scans with the clinical events shown in Figure 8.

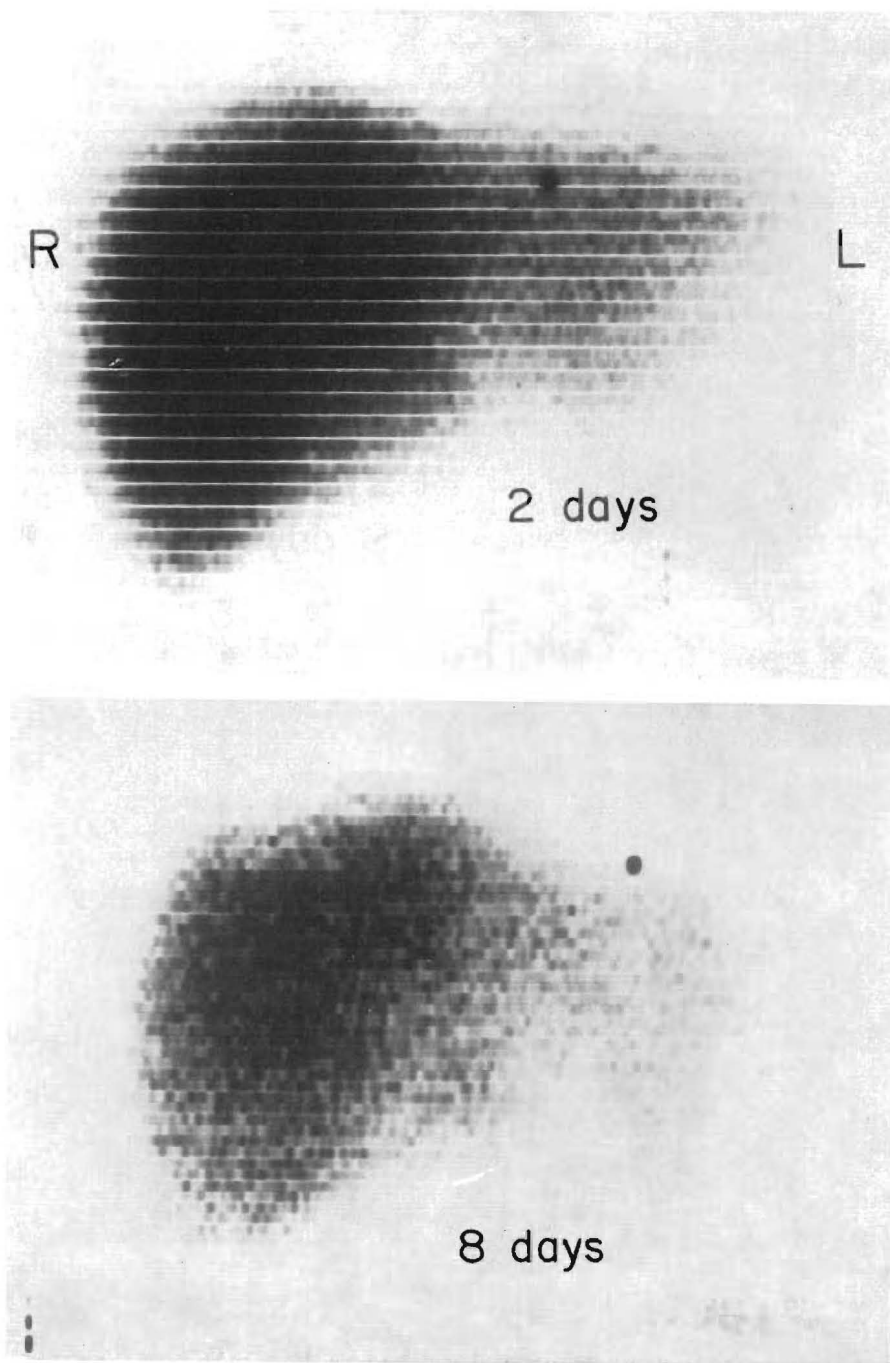


Figure 10 (text, see p. 18)

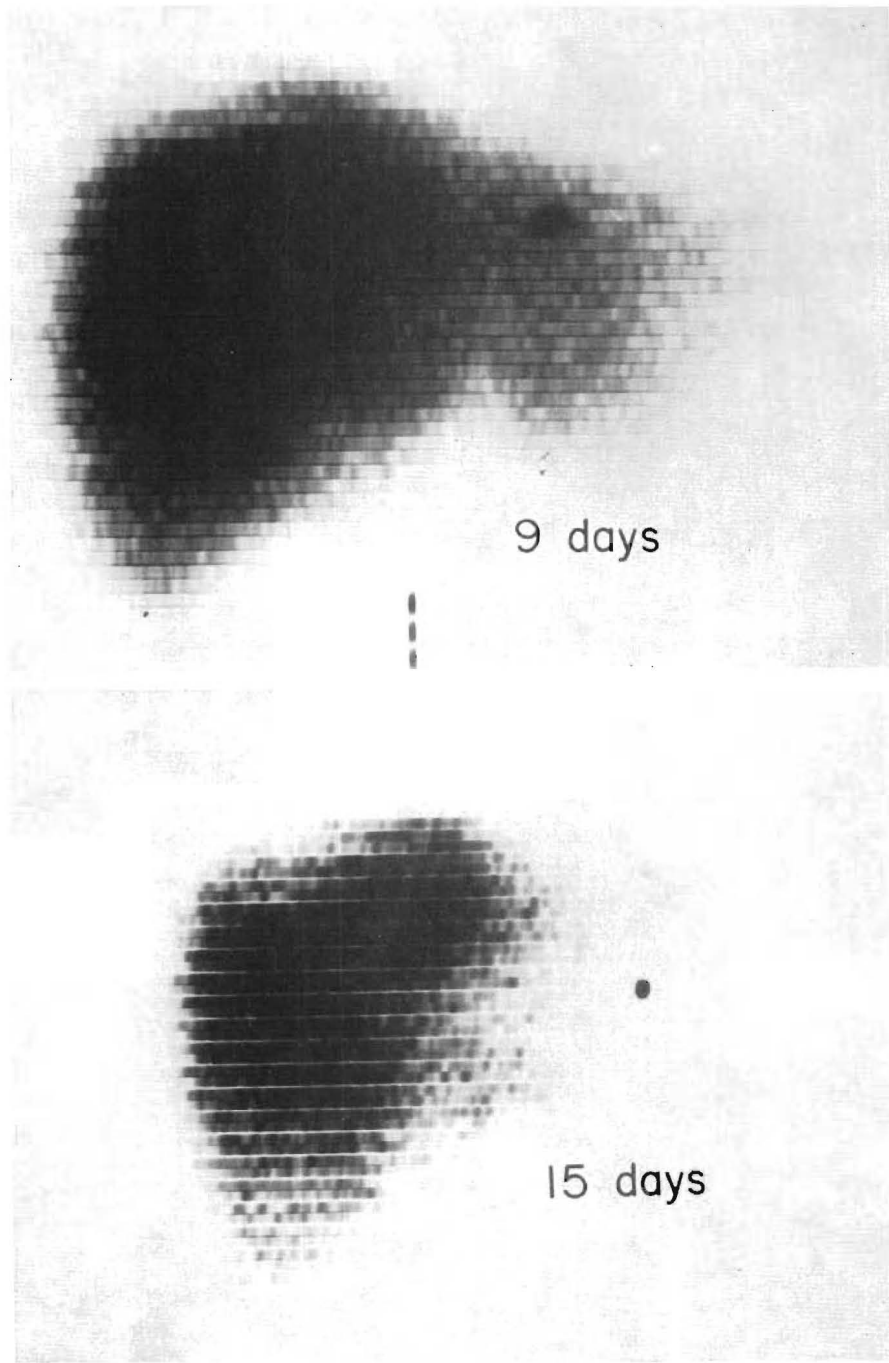


Figure 10 (text, see p. 18)

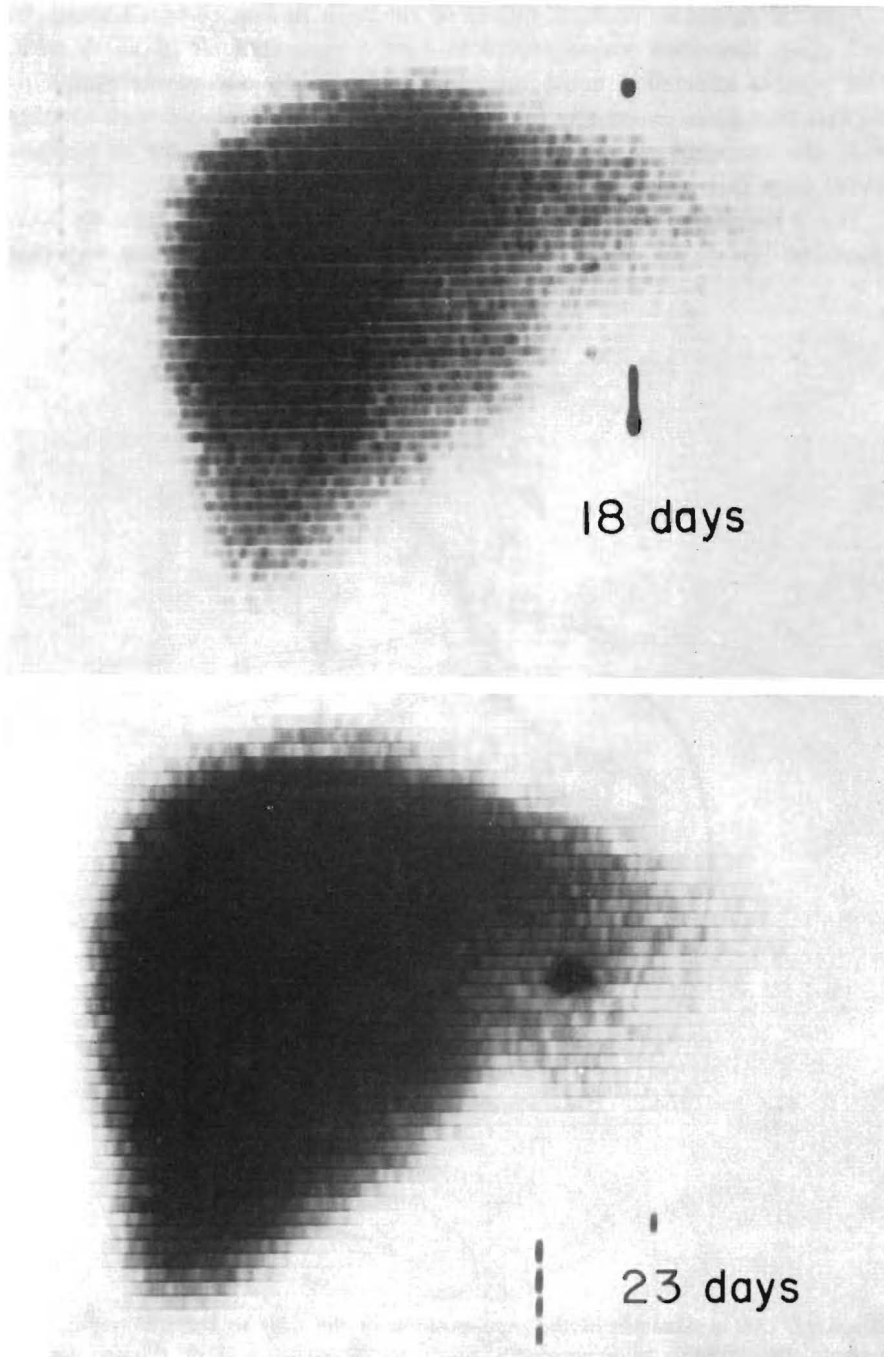


Figure 10 (text, see p. 18)

Indolent rejection. A third variety of rejection having certain features of both kinds described above proved to be the most difficult of all to treat. This process affected 3 homografts in 2 patients. In one of the recipients the first transplant eventually had to be removed and replaced with another graft; the immunologic attack on the second organ was similar to but less severe than that which had destroyed the first.

The 2 recipients were 16 and 2 years old. The rejections began on post-operative days 6, 13, and 32 and developed in a disarmingly slow way that

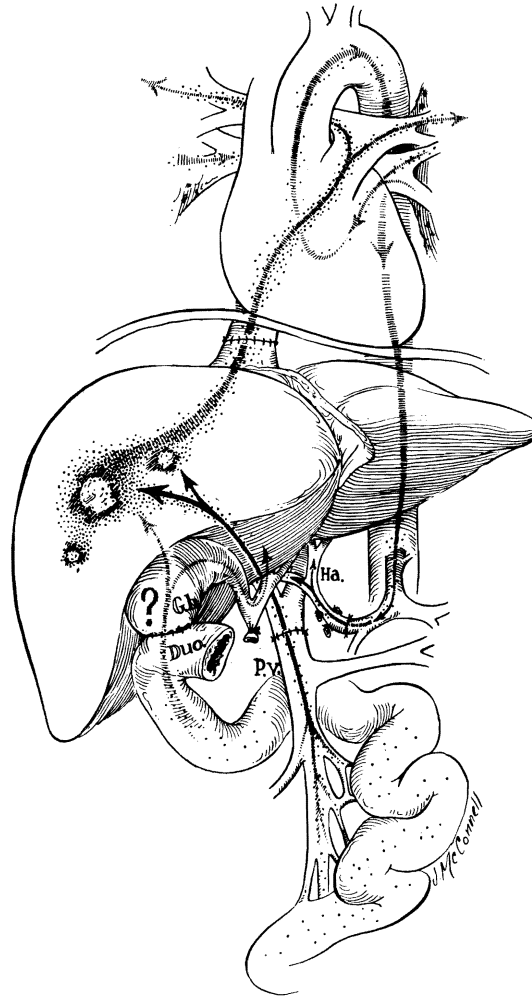


Figure 11. An explanation of the predisposition of the liver to bacterial sepsis. Presumably, the invading microorganisms enter via the portal vein or through the reconstructed biliary tract. (By permission of *Ann. Surg.* **168**, 392, 1968.)

required 4 to 7 weeks to reach a peak. The patients did not become clinically ill, at least at the outset. They retained a good appetite and were physically active. Eventually hepatomegaly became very prominent.

Initially the abnormalities in liver function were mainly those which are commonly found with incomplete biliary tract obstruction. The serum bilirubin, which rose slowly and irregularly over a period of many days, had an exceptionally high glucuronide fraction which was almost invariably 75 per cent of the total (Figure 12). Paralleling the insidiously deepening icterus were rises in the alkaline phosphatase. The SGOT and SGPT did not rise to very high levels. The complex functions of synthesis were usually well preserved for long periods (Figure 12).

Very heavy immunosuppressive treatment was used in an attempt to control the rejections. Unfortunately ALG had to be stopped after 18 days in

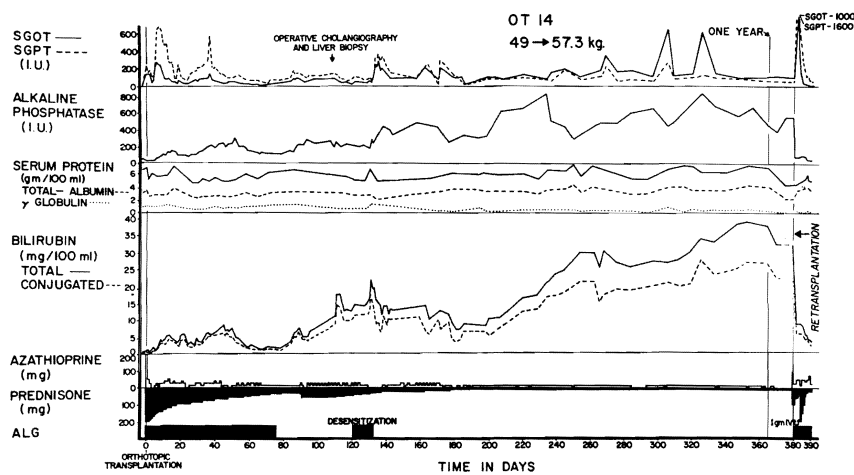


Figure 12. The course of a patient after 2 orthotopic liver transplantations. The second liver replacement was 380 days after the first. Throughout the period of follow-up, very small doses of azathioprine were given, usually 12.5 mg per day. Shortly after the discontinuance of the first course of ALG, a chronic rejection developed. An effort at desensitization to the horse globulin was not successful. Despite the deepening jaundice, the synthetic functions of the liver were well maintained for a long time. Note the low gamma globulins late in the course. At the time of retransplantation, local recurrence of hepatoma was demonstrated but there was very little tumor in the liver to account for its functional deterioration. However, the hepatic artery of the discarded homograft was completely occluded by old thrombosis. The patient died 50 days after the second transplantation. The liver function tests were performed with microchemical techniques. With these methods, the normal ranges in International Units (I.U.) of alkaline phosphatase, SGOT, and SGPT respectively are 60 to 260, 0 to 65, and 0 to 55.

one case because of severe reactions at the injection sites (Figure 13). It was almost immediately after this that the indolent rejection began its inexorable course which eventually necessitated retransplantation after 68 days. About a month after the second transplantation, when rejection of the new homograft was just starting, rabbit ALG was added to the pre-existing therapy of azathioprine and prednisone. The rejection was not reversed but homograft function has been relatively stable for almost a year (Figure 13).

In the other patient, the indolent rejection was eventually reversed after about 2 months. ALG was finally stopped after 73 days because of a suspected anaphylactic reaction. Within 2 weeks, the jaundice began to return (Figure 12). Nevertheless, the homograft supported life for more than a year before it was finally removed and replaced with a second organ.

Septic hepatic infarction. In the foregoing descriptions of the kinds of hepatic rejection, it was suggested that homografts could sometimes be threatened by an immunologically mediated reduction of their blood flow and that the most affected portions of the organs could become differentially

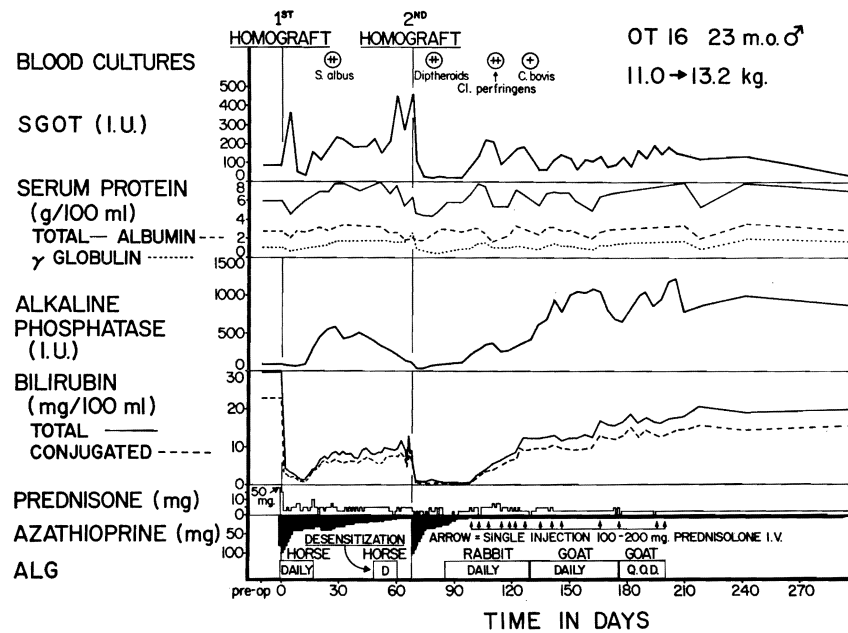


Figure 13. The course of a 23-month-old child with biliary atresia who received 2 orthotopic liver transplantations. A severe indolent rejection was encountered on both occasions, but the function of the second homograft eventually became relatively stable. The patient is now more than one year postoperative.

susceptible to invasion by bacteria from the gastrointestinal tract. It is not hard to imagine the dire sequelae that would have followed if the process that initiated the changes shown in Figure 10 had not spontaneously abated.

Now an extension of these events will be described as they were observed in 5 consecutive earlier cases in which orthotopic hepatic homografts actually did undergo regional necrosis. The 5 recipients were the first humans to have extended survival after this kind of operation (Starzl & Putnam 1969, Starzl *et al.* 1968a/b), and the reasons for the complication were

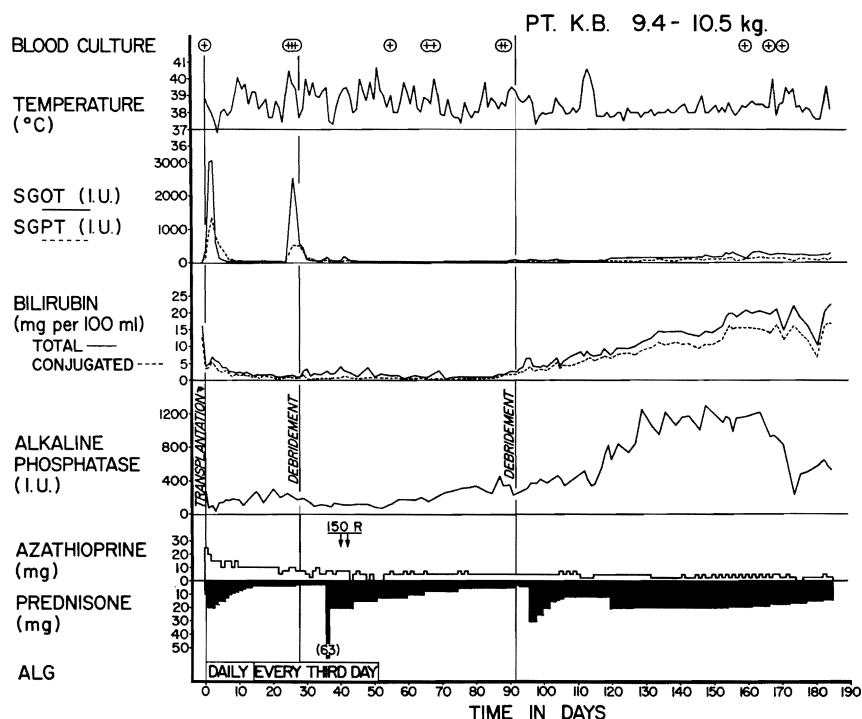


Figure 14. The course of a patient after orthotopic liver transplantation for extra-hepatic biliary atresia. Homograft function prior to the onset of a septic hepatic infarction on the twenty-fifth day was excellent; the only consistent abnormality was an elevated alkaline phosphatase. Even after the infarctions destroyed large portions of the central and right lobar liver tissue, function remained good until the end of the third postoperative month. Thereafter, liver failure was progressive. Note the late parallel increases in alkaline phosphatase and bilirubin. The immediate cause of death was intraperitoneal rupture of an undrained residual abscess of the left lobe. Survival was 186 days. Liver irradiation was with 150 R depth dose at each arrow. The temperatures were the daily maximums. At autopsy the right hepatic artery was the site of a completely occlusive old thrombosis. (By permission of *Ann. Surg.* **168**, 392, 1968.)

anything but clear at that time. Later it was concluded, partly because of the greater insight provided by the subsequent experience documented in the preceding sections, that a primary element in the pathogenesis had been incompletely controlled rejection. In addition, evidence was uncovered that contributory mechanical factors determined at least in part the localization of the gangrene.

The consequences of septic hepatic infarction were characteristic and resulted in 3 clinical or laboratory findings that were absolutely diagnostic. The 3 components of the triad were gram-negative septicemia, evidence from transaminase determinations of massive liver necrosis, and the development on serial liver scans of large areas of persistently absent isotope concentration in the homograft.

The complication of regional hepatic gangrene occurred in children who were 13 to 20½ months old at the time of transplantation. The diagnosis was made from 2 to 104 days after operation. Before the onset of hepatic necrosis the patients had generally been in good condition although fevers usually preceded the calamities by several days. The bacteria that were eventually found in the peripheral blood were all of the gram-negative variety normally found in the gastrointestinal tract. These included *Aerobacter-klebsiella*, *Bacteroides fragilis*, and *Escherichia coli*.

From the beginning it was suspected that incomplete control of rejection must have been one responsible factor in the development of septic hepatic infarction, but evidence in support of this contention from several indices of liver function was initially thought to be weak. In 2 of the 5 recipients, there had only been very minor preceding increases in the alkaline phosphatase (Figure 14). In 2 others, indolent and persistent rejection had been present for some time before the onset of liver necrosis but the resulting jaundice was actually slowly receding (Figure 15).

In retrospect, such an equivocating position need no longer be taken since there is no question but that all the homografts that underwent regional necrosis were contemporaneously under immunologic attack. Tissues removed at re-operation at about this time had histopathologic signs of rejection (Starzl & Putnam 1969, Starzl *et al.* 1968a, Porter 1969a). Moreover, a review of the liver scans throughout the early postoperative period showed that there had been an extraordinary swelling of the transplanted organs beginning days or weeks before their partial devascularization (Figure 16). Failure to recognize the significance of these findings at the time the patients were being cared for, led to the error of minimizing immunosuppression in several of the cases at precisely the moment when therapy should have been increased. When tissue devitalization finally occurred there were very dramatic and sudden increases in the SGOT and

SGPT as relatively dissociated biochemical findings (Figures 14 and 15). Jaundice did not promptly deepen and the serum proteins and prothrombin times remained more or less stable.

The retention of generally good function in spite of the evidence of major hepatic necrosis was explained by the localized nature of the process as seen on the liver scans (Figure 16). Isotope uptake was retained in most parts of the homografts although the concentration was usually somewhat reduced. In contrast, the afflicted areas, which were predominantly in the right lobe, had almost no specific activity at all. In some cases the size of the devitalized region tended to remain constant but in other instances it extended rapidly.

Removal or drainage of the infarcted area was undertaken in each case shortly after the diagnosis was made. The operations ranged from simple debridement to a formal hepatic resection. Two of the patients died a short time after these procedures. At autopsy, the right hepatic arteries of their homografts were found to be thrombosed.

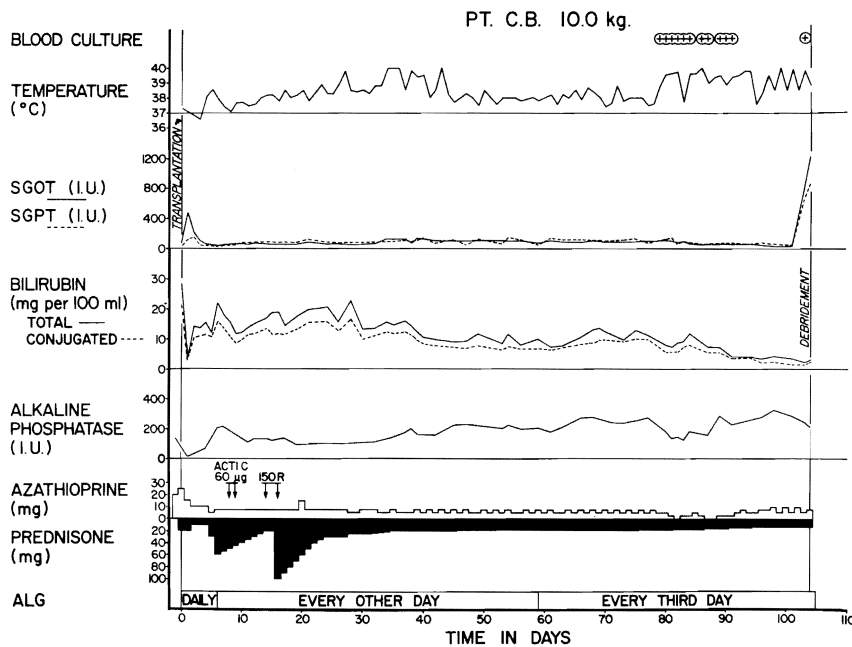


Figure 15. Course of a patient after orthotopic liver transplantation for extrahepatic biliary atresia. A vigorous and protracted rejection began within a few days post-operatively which was not reversed for 10 weeks. Function was improving when persistent gram-negative septicemia presaged liver sepsis. Complete right lobar infarction finally occurred causing death within a few hours. At autopsy, the right hepatic artery was thrombosed. Acti C-intravenous actinomycin C in micrograms, 150 R - homograft irradiation. (By permission of *Ann. Surg.* 168, 392, 1968.)

Two others were temporarily rescued but died of chronic liver failure (Figure 14) 4½ and 6 months after transplantation. In both, sepsis in the right subphrenic space and the contiguous liver tissue persisted until the time of death. The infected and draining serpiginous intrahepatic tracts were irrigated twice a day. Fragments of dead tissue were repeatedly removed from the exposed hepatic parenchyma. Failure to keep the wound meticulously clean seemed to predispose to septicemia (Figure 14), often although not always with the same bacteria then present in the depths of the wound. At first there was evidence of liver regeneration but eventually the organs began to shrink. The 2 patients died after 133 and 186 days. Old thromboses of the homograft right hepatic arteries were found at autopsy.

Only one recipient recovered relatively fully from the complication of septic hepatic infarction. After extensive debridement, the defect slowly filled in, apparently by hepatic regeneration. The process required 8 months to become almost complete. Until the time of her death from carcinomatosis more than a year later, a sinus tract to the right subphrenic area required daily irrigation.

As already stated, it is our present belief that rejection played a crucial role in the genesis of the hepatic infarctions. Presumably, the portions of the liver subjected to the most severe ischemia would be the ones to undergo necrosis. It follows that a number of non-immunologic conditions could also contribute to regional devascularization. One such factor is illustrated in Figure 17, as it was studied in a recently deceased 5-year-old child. An angiogram was made of the hepatic artery. Then, the restraining ligaments of the liver were cut, the vascular structures entering and leaving the liver were skeletonized, and the head of the X-ray table was elevated to 60° to simulate an erect posture. The right lobe could be seen to rotate down and medially causing an incompletely occlusive kink of the right

Figure 16. Postoperative technetium scans of the liver of the patient whose course is shown in Figure 13.

- 2 days – The small homograft is normal.
- 10 days – An increase in size is evident although the general configuration of the organ is still normal.
- 20 days – No further change is noted.
- 25 days – The examination was conducted as an emergency when the child developed gram-negative septicemia and very high increases in the transaminases (see Figure 13). Areas of decreased isotope uptake are obvious in the right lobe and the central part of the liver.
- 27 days – A striking extension of the process can be seen less than 48 hours later. A debridement procedure was carried out the same evening.
- 31 days – Four days after debridement the radiographic appearance remains about the same.

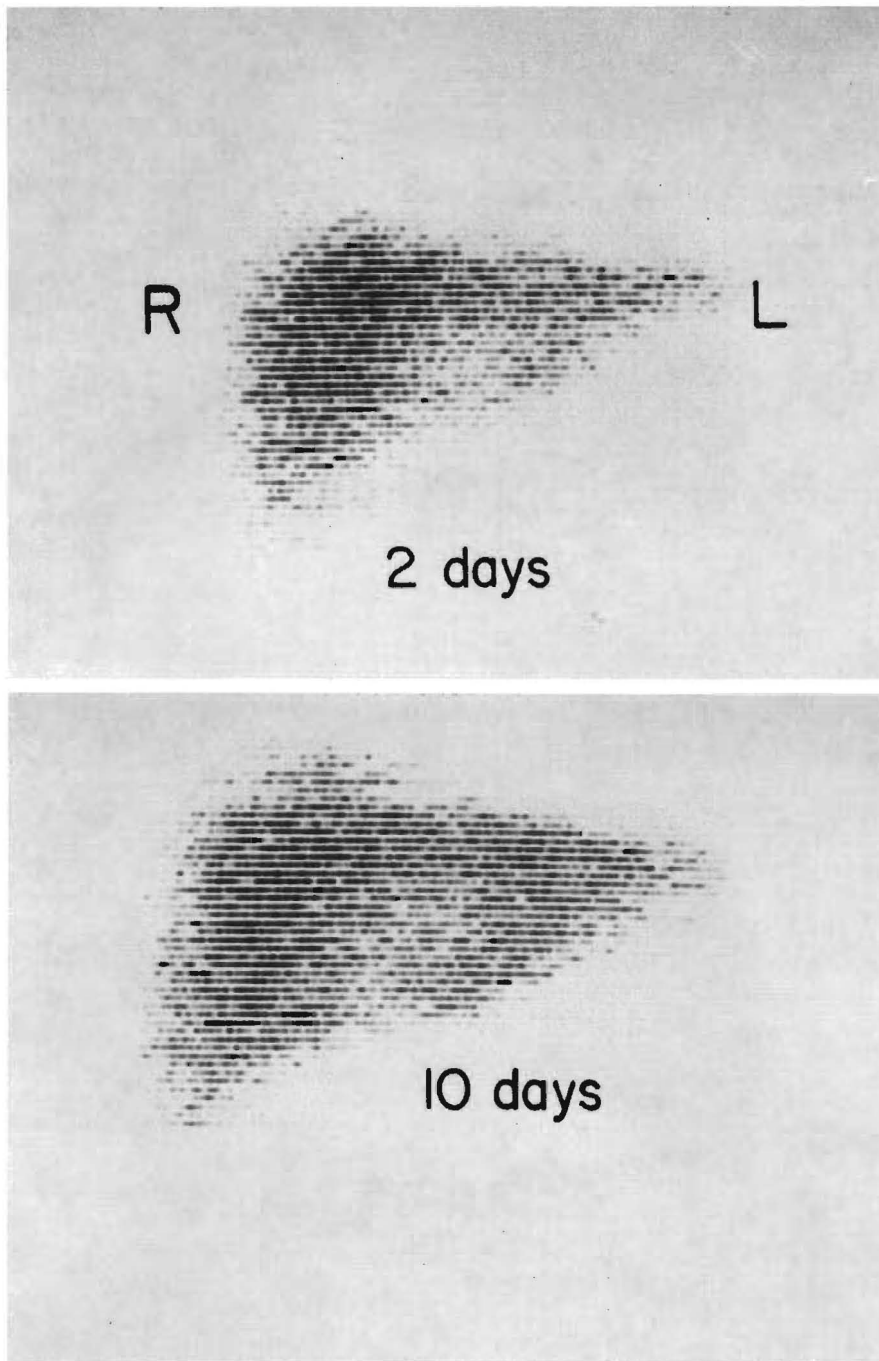


Figure 16 (text, see p. 28)

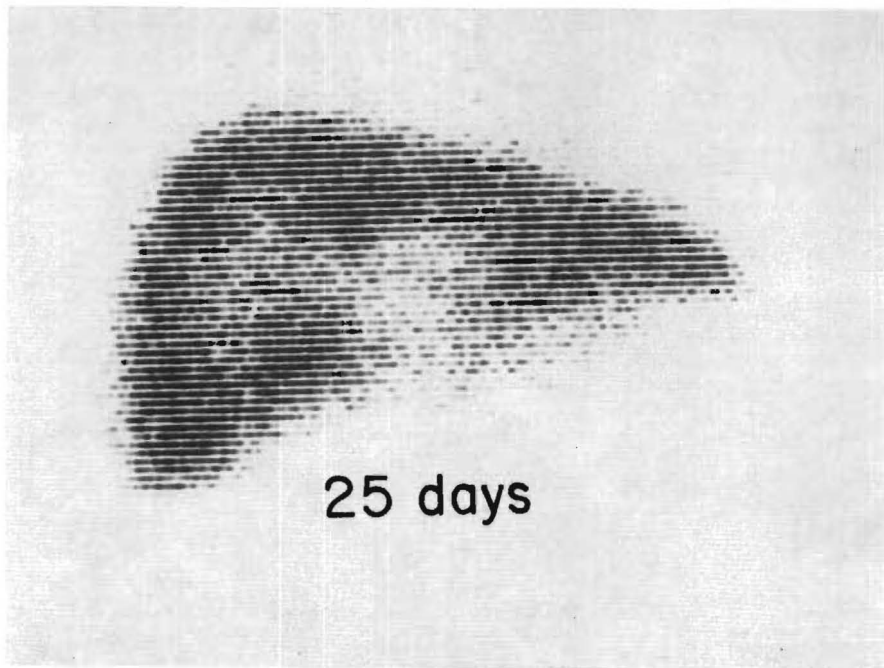
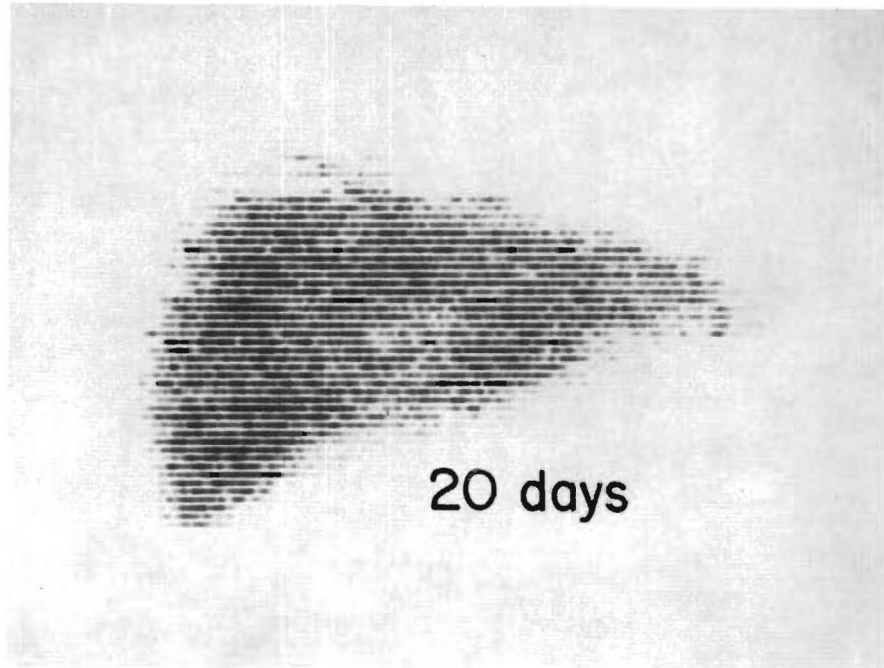


Figure 16 (text, see p. 28)

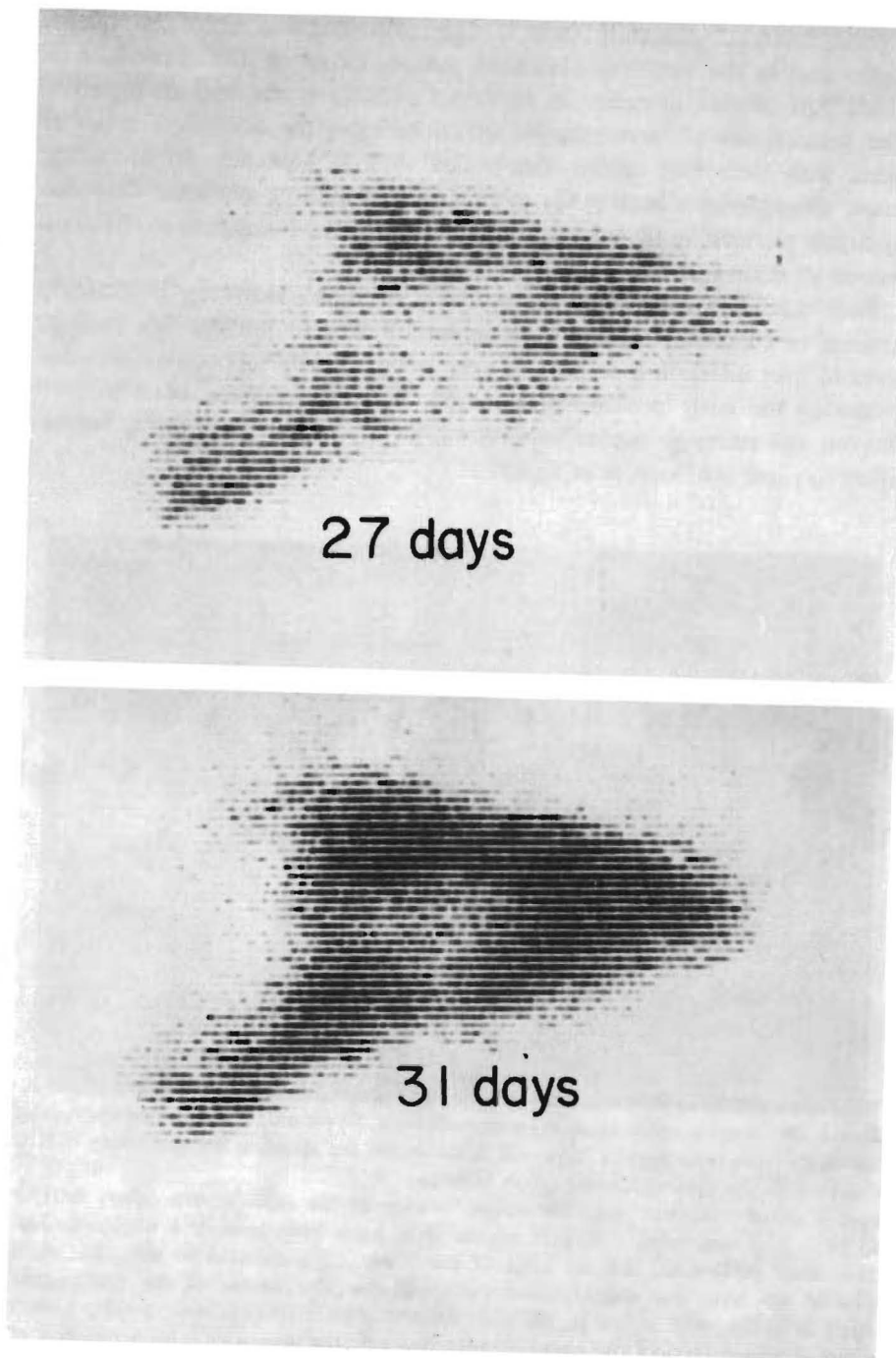


Figure 16 (text, see p. 28)

hepatic artery. Presumably such a dangerous situation could be further aggravated in the post-transplantation period, either by the diminution in blood flow alluded to earlier or by organ swelling at the time of rejection. The constellation of circumstances would be especially hazardous in infant livers with their fine caliber thin-walled arterial branches. In all recent cases, attempts have been made to prevent this kind of anatomic distortion by firmly reattaching the suspensory ligaments of the homograft to the companion structures in the recipient (Figure 18).

Such mechanical measures are probably of value. However, it is almost ironical to conclude that the most important way to prevent this peculiar form of liver infection is to provide very heavy immunosuppression especially during the early postoperative period. Since the policies of homograft fixation and stringent immunosuppression have been followed, septic hepatic infarction has not been seen again.

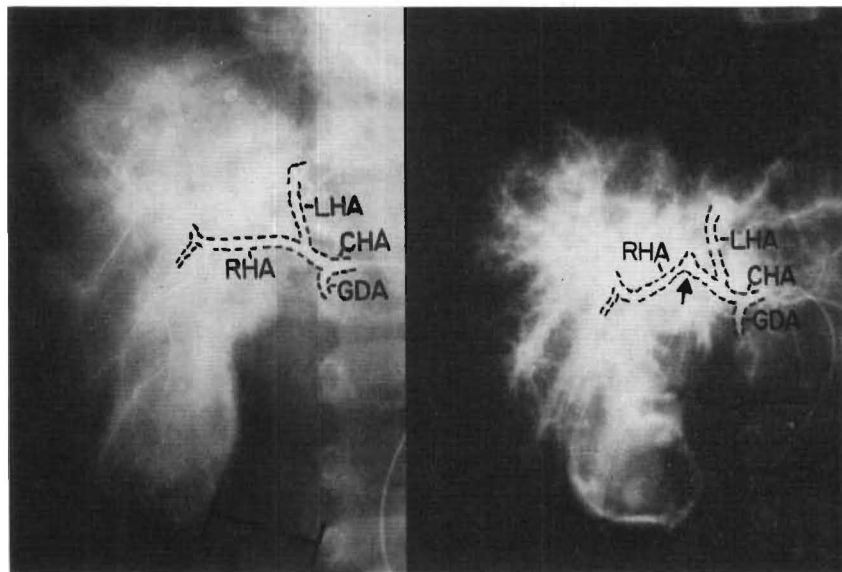


Figure 17. Angiographic studies performed in a 5-year-old child immediately after her death from head injuries. Dye was injected into the common hepatic artery (CHA) proximal to the gastroduodenal artery (GDA).

Left - Initial injection. Note the smooth course of the right hepatic artery (RHA). Right - The restraining ligaments of the liver have been incised, a cholecystoduodenostomy performed, and the head of the X-ray table elevated to 60°. The right lobe of the liver has rotated down and medially. The course of the left hepatic artery is undisturbed. However, the right hepatic artery (RHA) is now severely kinked where it passed beneath the common duct. See text for discussion. (By permission of *Ann. Surg.* **168**, 392, 1968.)

Late Homograft Deterioration (After 2 months)

In our series, there were 11 recipients of 12 homografts who survived for at least 2 months after operation. With a single possible exception, the subsequent events could not be said to have been influenced by earlier technical surgical complications. When delayed deterioration of liver function occurred in these cases, it was always due either to late rejection of the homografts or alternatively to invasion of the transplanted organ by recurrence of the malignancy for which treatment was initially undertaken.

Tumor recurrence. Four of the patients with hepatoma lived through the immediate effects of the operation and became available for longer-term studies. All eventually died after 143, 339, 400, and 430 days.

Malignant disease was directly responsible for the deaths of the first 3 of these recipients. They developed disseminated metastases which had a predilection for the lungs (Figure 19) but which also were distributed in many other tissues including in 2 instances the brain (Table I). Respiratory insufficiency was the terminal event in 2 of the 3 cases.

Hepatic function was adversely affected by the tumor recurrences in the 3 patients who lived for 143 to 400 days. In the case with the shortest survival, hepatic metastases became evident by liver scanning in the third postoperative month (Figure 20) at about the same time as the development of jaundice (Figure 21). By the time of death at 143 days, an estimated 95 per cent of the homograft had been replaced with neoplasm of the same

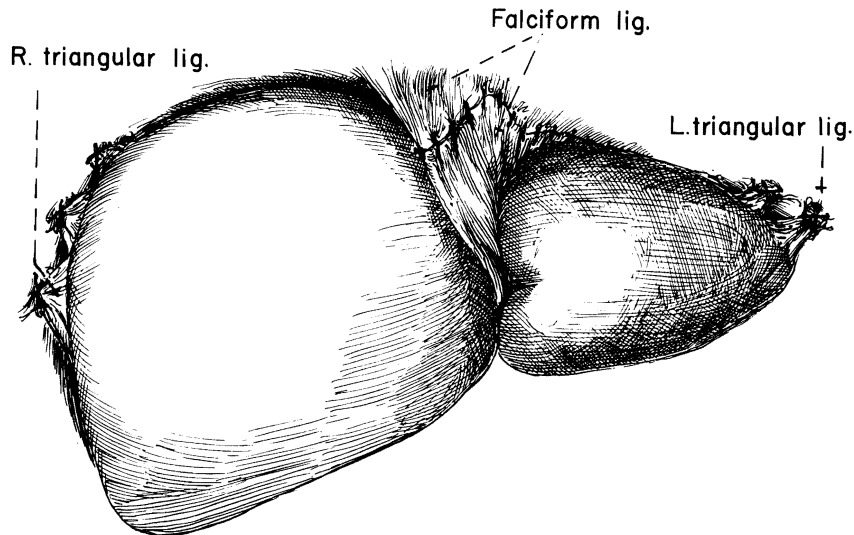


Figure 18. Resuture of the suspensory ligaments of the transplanted liver.

TABLE I

The fate of 4 recipients who received liver replacement for the indication of hepatoma and who lived long enough after operation to permit observations about the course of the malignancy

Case no.	Metastases first detected (days postop)	Location first metastases	Treatment of metastases	Meta-stases to homo-graft	Organs ultimately involved	Cause of death & time
8	90	Lungs	Vincristin sulphate; surgical excision of intra-abdominal masses	Yes	Brains, lungs, liver, other abdominal organs	Carcinomatosis 400 days
14	380	Diaphragm, liver, retro-peritoneal space	—	Yes	Diaphragm, retro-peritoneal space, ribs, liver, pancreas, pouch of Douglas, tracheal & bronchial lymph nodes, pericardium	Retransplantation 380 days; died 430 days of peritonitis
15	60	Lungs	—	Yes	Lungs, liver, diaphragm	Carcinomatosis 339 days
23	29	Lungs	—	Yes	Brain, lungs, liver, retroperitoneal space	Carcinomatosis 143 days

cell type as that of the original hepatoma. The only tissue that resembled hepatic parenchyma grossly was in the central portion (Figure 22).

Figure 19. The extremely rapid development of pulmonary metastases in a 15-year-old recipient of an orthotopic liver homograft for the indication of hepatoma.

- A – The chest is clear 6 days after liver replacement.
 B – Twenty-nine days postoperative. Two metastases are visible in the left lower lung (arrows).
 C – Five days later the tumor deposits previously seen have grown in size (horizontal arrows) and a third focus is now present in the right upper lobe (vertical arrow).
 D – Forty-four days. Only 10 days have elapsed since the last examination. Metastatic growths are scattered throughout the lungs (arrows).
 E – Seventy-four days postoperative.
 F – Four months after operation. Transient dyspnea was first noticed a few days later. The patient died of pulmonary insufficiency 143 days after transplantation.

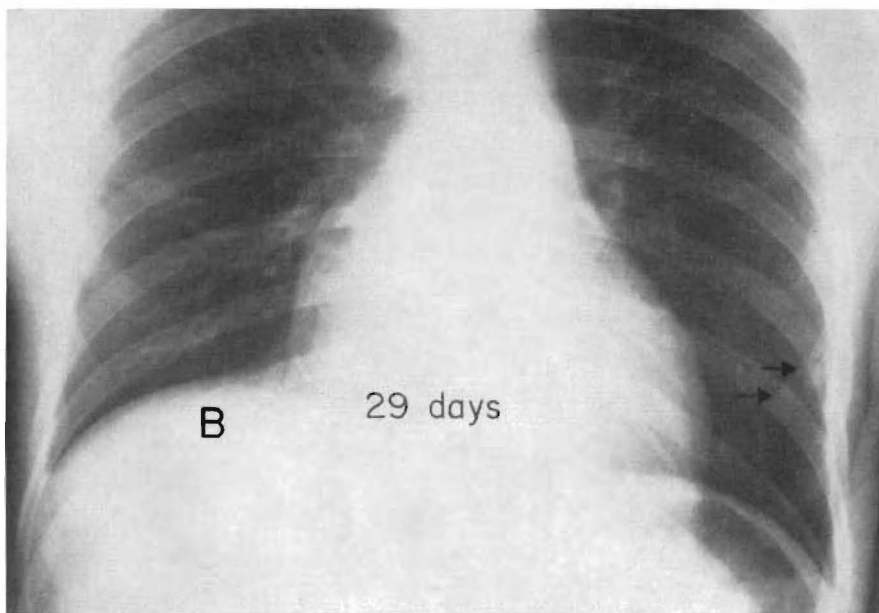
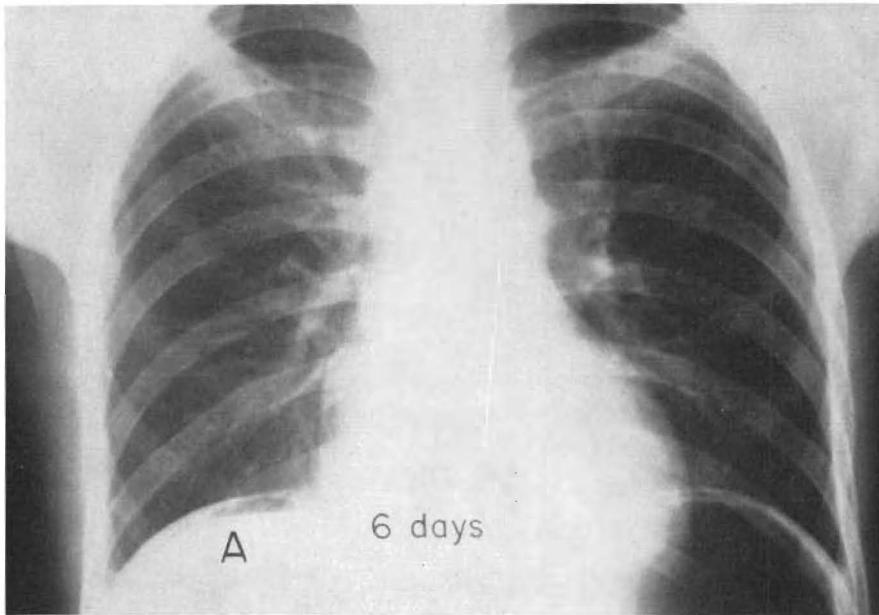


Figure 19 (text, see p. 34)

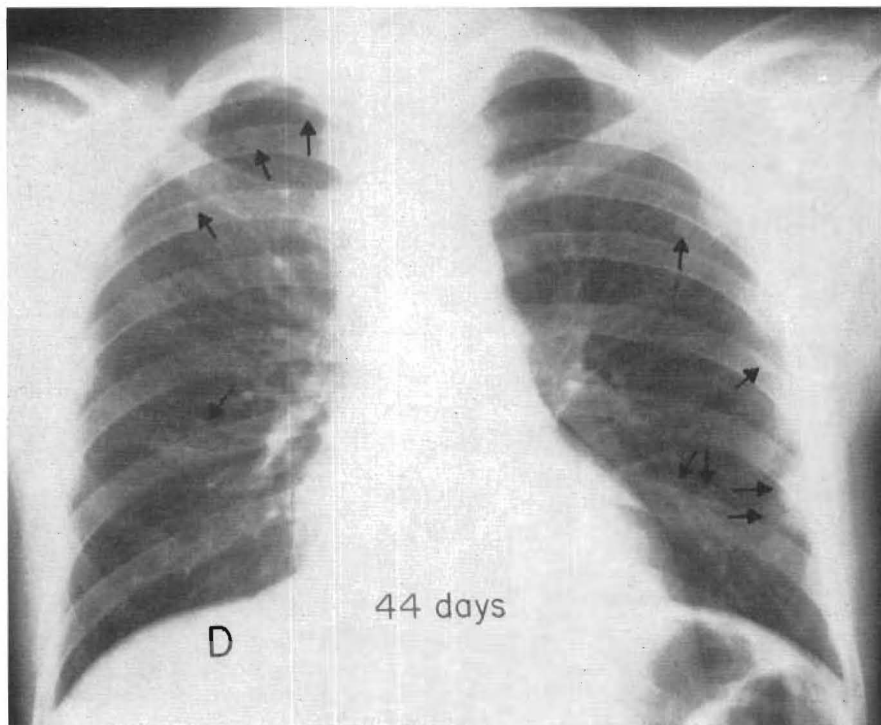
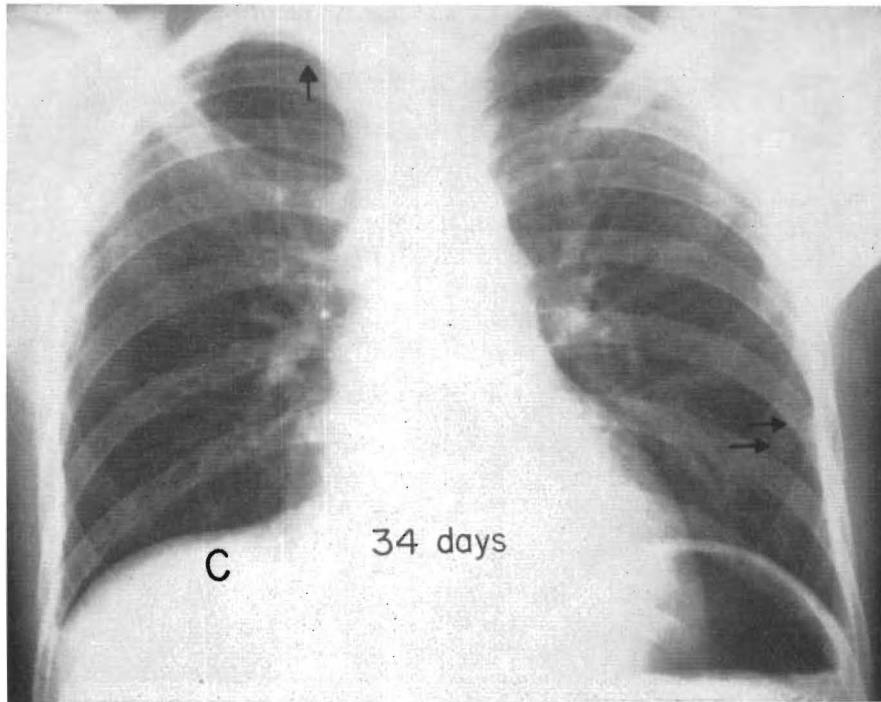


Figure 19 (text, see p. 34)

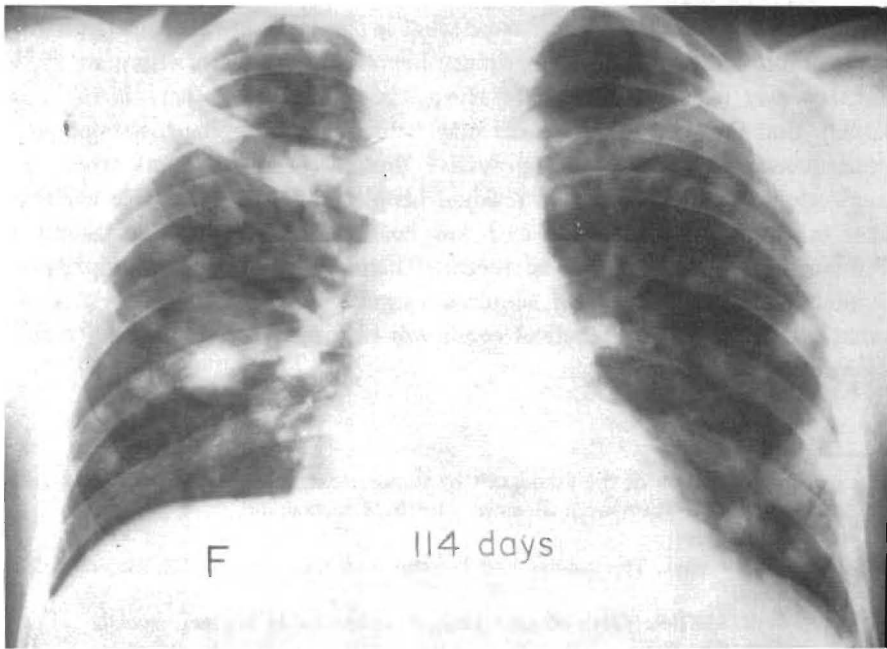
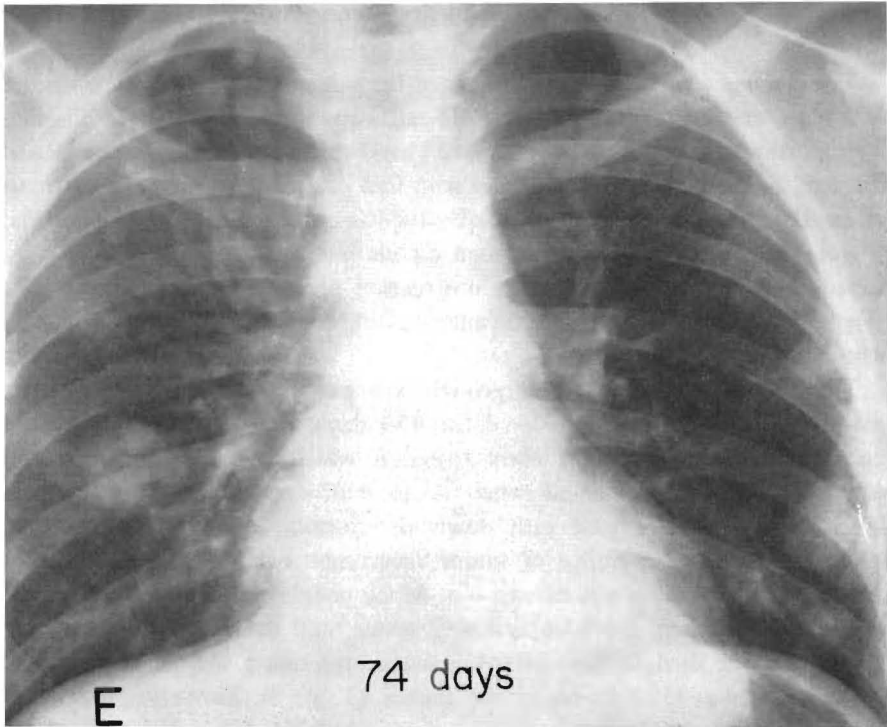


Figure 19 (text, see p. 34)

The homograft biliary duct systems of the patients who lived for 339 and 400 days were obstructed by intra- or extrahepatic metastases. The findings were particularly clear in the older (42 years) of these recipients who passed through an early rejection crisis but who had perfect liver function for most of the next 9 postoperative months. He then became intermittently jaundiced (Figure 23). A mass which was seen on his liver scan (Figure 24) had invaded the common hepatic duct, obstructing and eventually perforating it (Figure 25). A similar chain of events was observed in the 2-year-old child who lived for 400 days.

The rate of recurrent tumor growth was exceptionally rapid in all the patients except the one who lived for 430 days, the 16-year-old girl who passed through an indolent early rejection which was first reversed and which promptly re-presented when ALG was stopped (Figure 12). She lived for more than a year with slowly deteriorating hepatic function, during which time no evidence of tumor recurrence could be found. At 380 days, retransplantation was carried out. Many neoplastic deposits were found within the abdomen, the retroperitoneal space, and the chronically rejecting homograft. She died 50 days after the second operation. At autopsy, several other metastases were found in the thorax (Table I). However, the direct cause of death was disruption of the cholecystoduodenostomy.

It might be argued that the frequency and seriousness of the recurrences were approximately predictable from what is already known about the highly unfavorable natural history of primary hepatic malignancies (Berman 1959, Lawrence *et al.* 1966, Patton & Horn 1964). However, there is the possibility that the metastatic growth may actually have been accelerated as a consequence of the immunosuppressive therapy in the patients who were evidently unknowingly left with residual neoplasm. The considerable evidence that this may have been the case has been reviewed elsewhere (Starzl & Putnam 1969) and will not be repeated here. What should be emphasized is that the experience so far acquired suggests that if the neoplasm is not completely excised, the practical result will be a progressive downhill course from carcinomatosis.

Figure 20. Destruction of the homograft by tumor recurrence. The posttransplantation PA and lateral liver scans were obtained with 99M technetium.

- A - Sixty-eight days.
- B - Ninety-four days. The patient had become jaundiced (Figure 21). Hepatomegaly is evident.
- C - 101 days. Multiple areas of poor isotope concentration are now visible.
- D - 111 days. The process has continued its rapid progression. By the time of death one month later, the homograft was almost completely replaced with carcinoma.

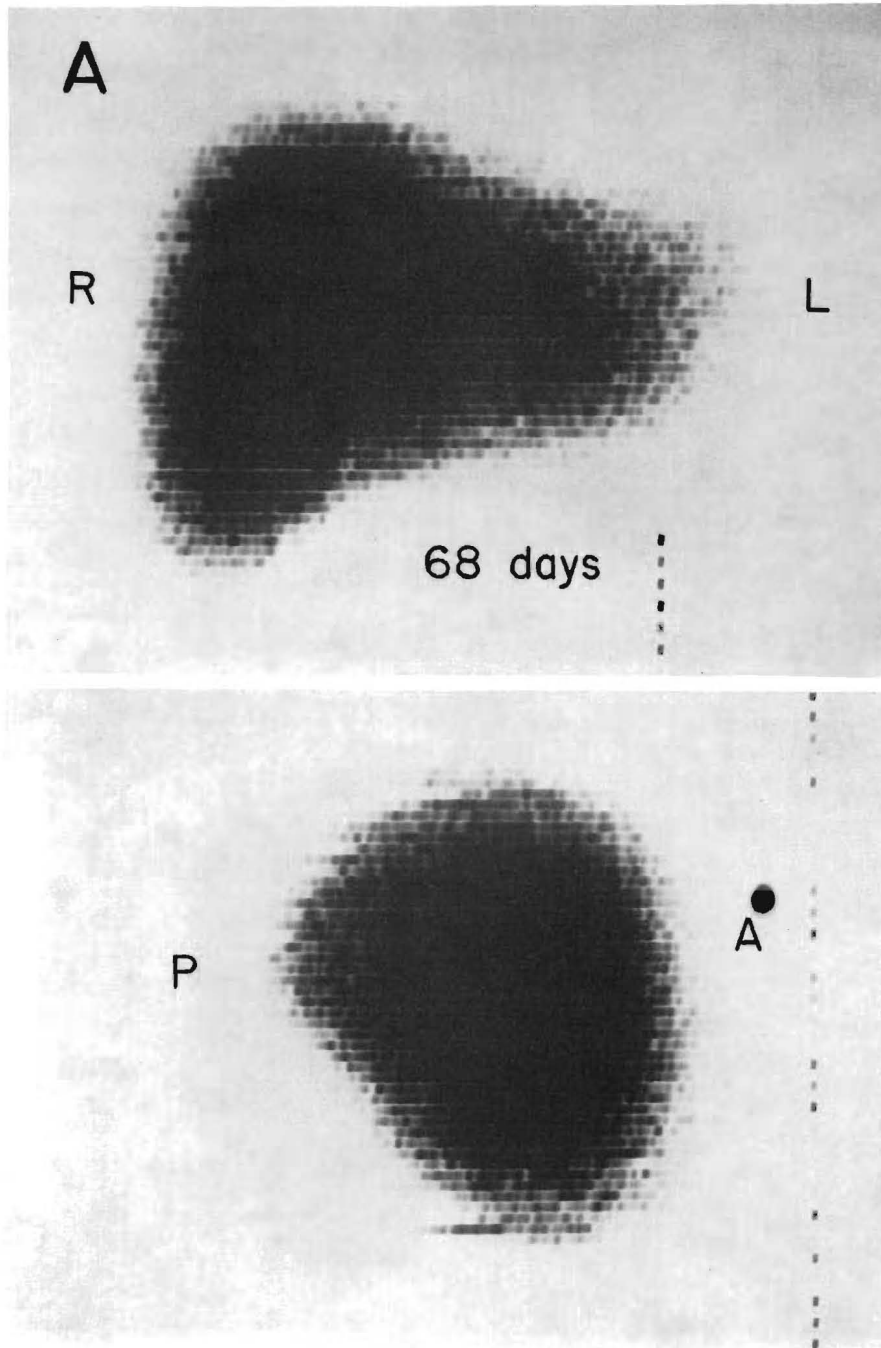


Figure 20 (text, see p. 38)

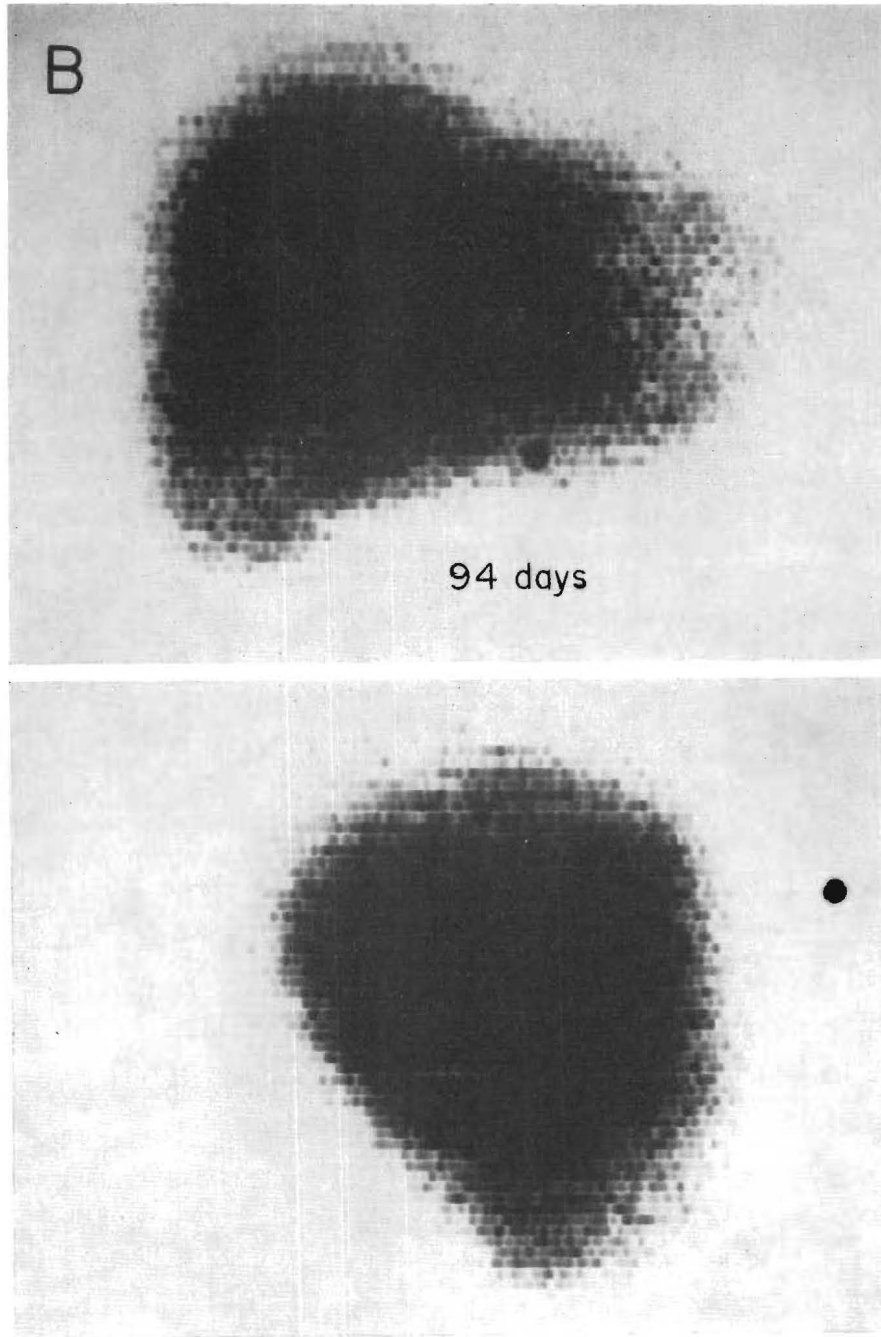


Figure 20 (text, see p. 38)

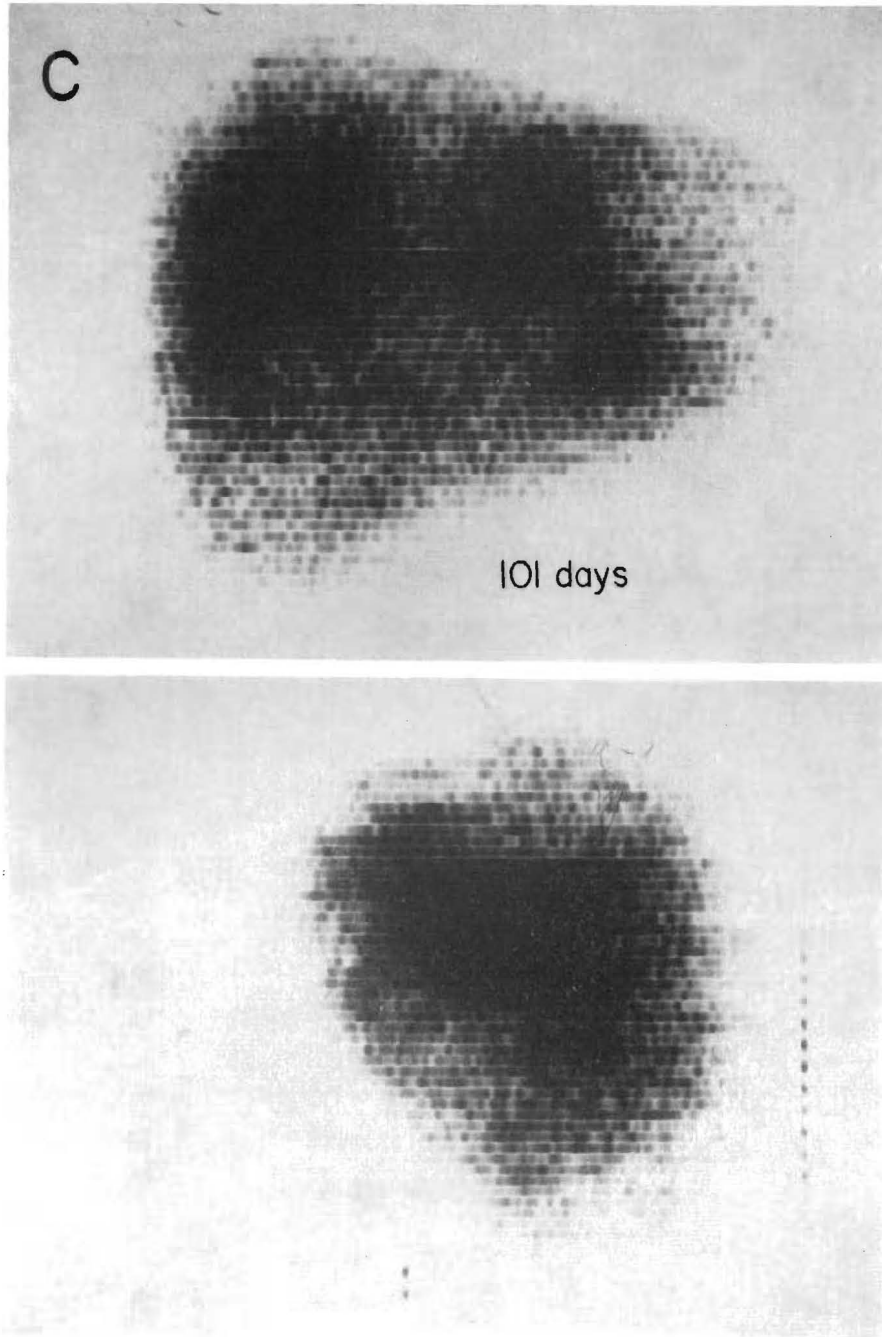


Figure 20 (text, see p. 38)

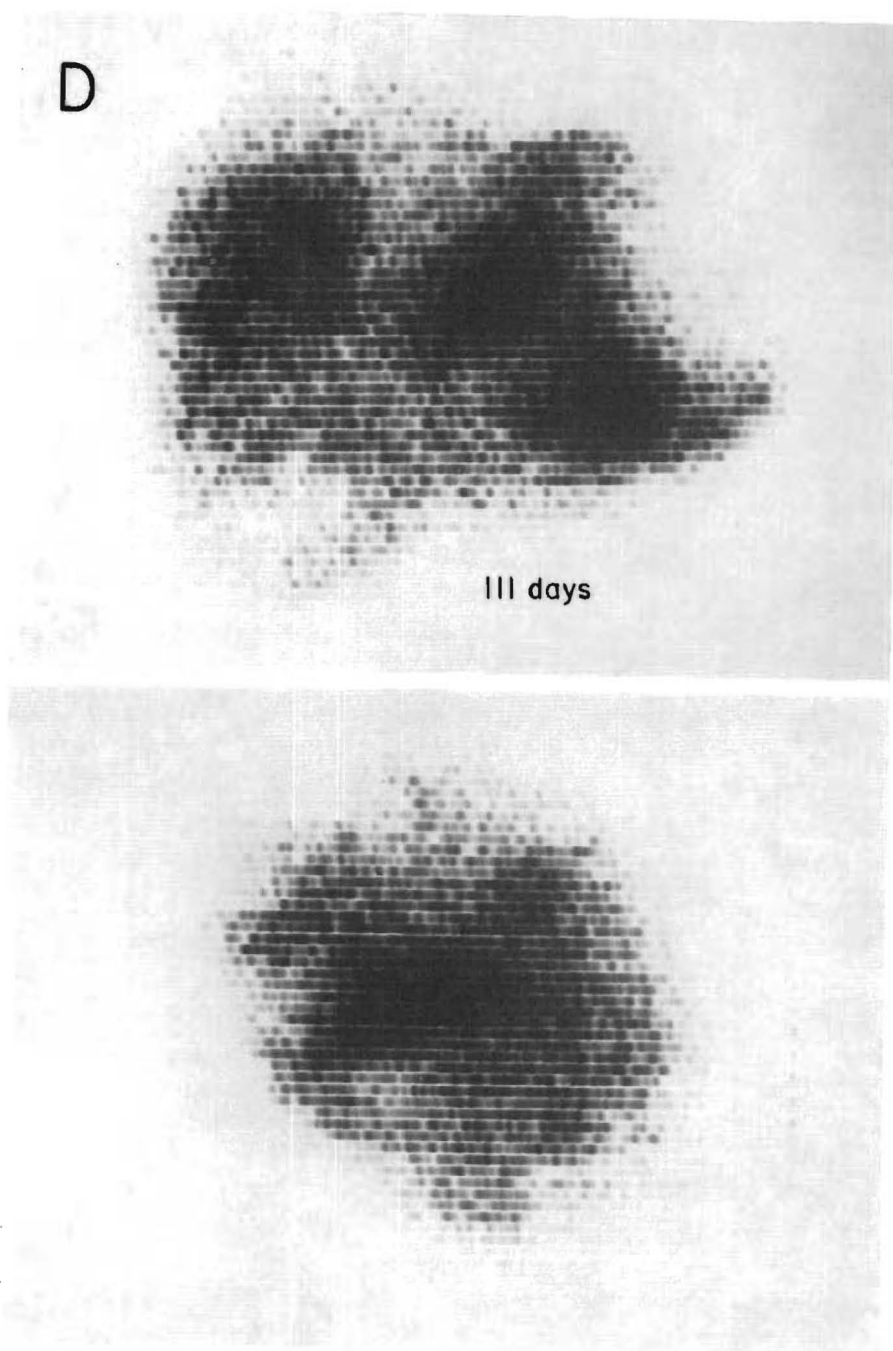


Figure 20 (text, see p. 38)

This does not mean that an occasional cure of hepatoma is thereby precluded, nor that there is yet justification to conclude that selected primary liver malignancies should not be treated with transplantation. However, in a historic perspective, the experience with hepatomas will probably be viewed as significant principally because the efforts at therapy were responsible for demonstrating that the operation of liver replacement could be successfully performed in man.

Late rejection. For the reasons just described, a complete and decisive assessment of the potential value of liver transplantation was not possible in patients with hepatoma. Fortunately, there were a number of opportunities to study chronically surviving patients without the complicating factor of serious injury to their homografts by recurrent malignancy. In the first 25 cases in our series, there were 7 recipients with an original diagnosis of biliary atresia who lived for 2 months or longer. The courses of 2 of these patients were alluded to earlier; they died after 61 and 105 days of septic

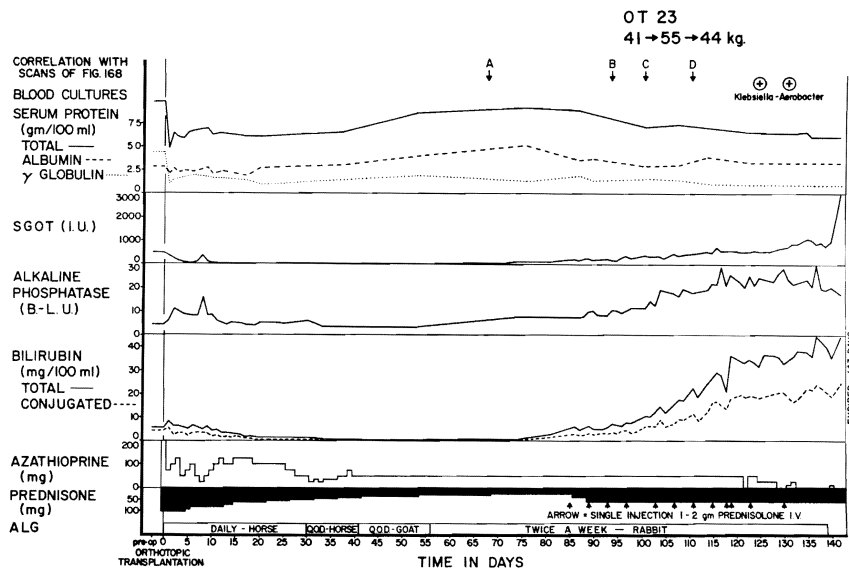


Figure 21. The manifestations of the invasion and nearly complete destruction of an orthotopic liver homograft by recurrent hepatoma (see Figure 20). The sporadic large doses of intravenous prednisolone were given because of the possibility that the deteriorating liver function was due to delayed rejection. At autopsy, almost all of the transplanted hepatic tissue was replaced by tumor (Figure 22). Note that the patient had hypergammaglobulinemia before transplantation and that this finding persisted during most of the postoperative period. The normal range for Bessey-Lowry (B-L) alkaline phosphatase units is 1 to 3. The normals for the SGOT and SPGT units at this age are 60 to 100 and 5 to 35 respectively.

hepatic infarction. The other 5 patients contributed to a delineation of the problem to be discussed now.

In these cases, delayed homograft repudiation was diagnosed from 63 to 175 days after transplantation. Earlier, all the patients had undergone some kind of an acute rejection ranging from the anicteric through the indolent variety; included were 2 recipients who had survived septic hepatic infarctions.

A striking observation in these cases was that of an apparent long-term dependence on ALG therapy. In each instance, globulin treatment was started on the day of or the day before operation in conjunction with azathioprine and prednisone. Afterwards, globulin injections were continued indefinitely for only one recipient. That patient is now one year post-operative and has perfect liver function despite the fact that he had histocompatibility mismatches with his donor in HL-A groups 2, 3, and 7. A minor delayed rejection at the beginning of the third postoperative month subsided promptly without major adjustments in immunosuppressive treatment (Figure 26).

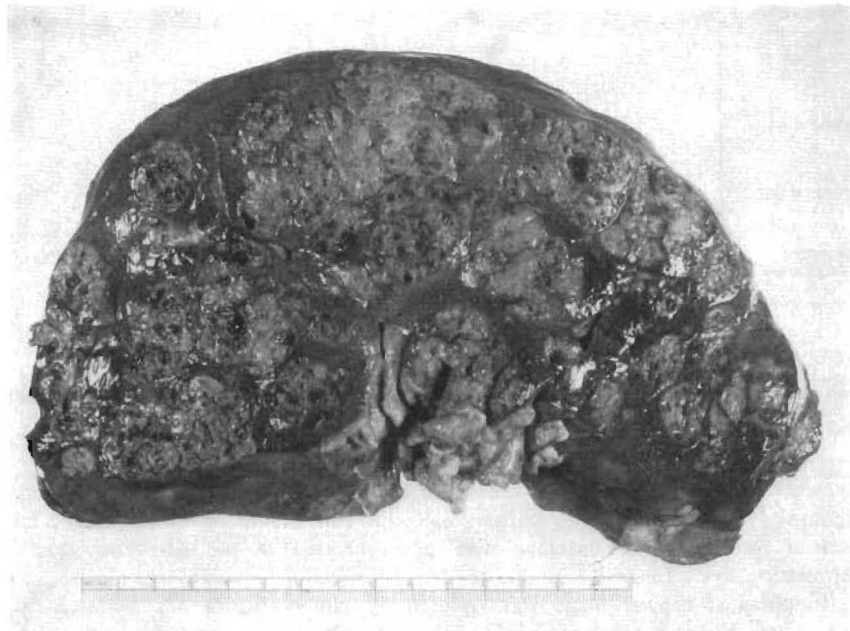


Figure 22. Metastases in a patient 143 days after orthotopic liver transplantation for hepatoma. The liver homograft has been replaced by tumor except for a very small residual area of hepatic parenchyma. The case is the same one as in Figures 18–20.

The other patients had the ALG injections stopped from 18 days to about 4 months after transplantation. Within a few days to 2 months, a progressive deterioration became detectable. It was particularly disquieting to have this happen in one patient whose course had been excellent and quite stable for several preceding months (Figure 27).

The pace of late rejection was characteristically very slow with biochemical changes that became progressively abnormal over a period of many weeks or months. The abnormalities were primarily those of complete or nearly complete biliary obstruction. Bile disappeared from the stools and appeared

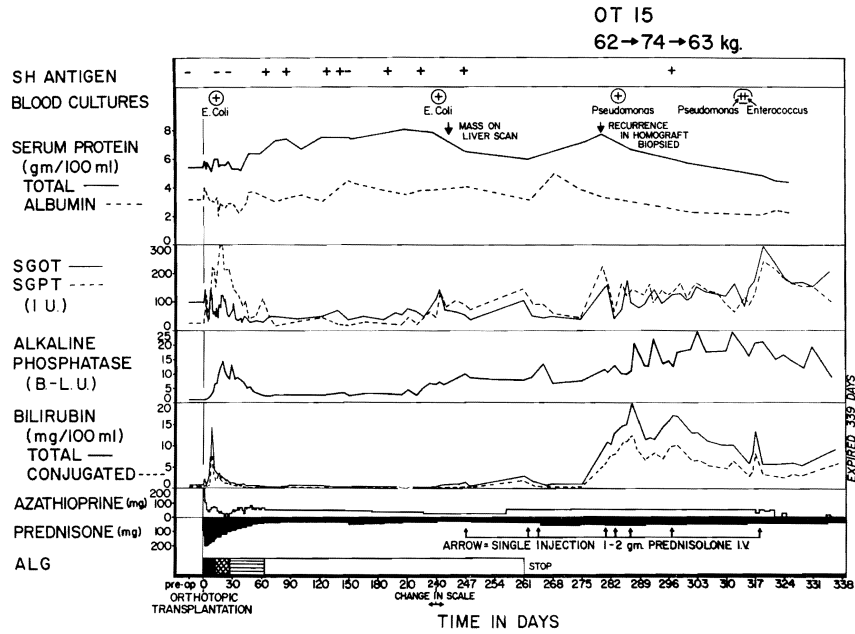


Figure 23. The course of a patient who died of recurrent hepatoma despite total hepatectomy and orthotopic liver transplantation. He passed through an early and vigorous rejection crisis but then had normal liver function for many months. Note that a condensed scale has been used for the first 240 postoperative days; the details of the early portion of the convalescence are shown in Figure 8. The recurrent tumor was first diagnosed with the liver scan about 8 months after transplantation (see Figure 24) and biopsy confirmation was obtained more than a month later. The episodic septicemia and deterioration of liver function were probably the consequence of invasion by tumor of the extrahepatic ducts (Figure 25). The intermittent large steroid doses were given on the chance that rejection was also occurring. From left to right, the different shadings in the ALG bar indicate that the injections were daily, every other day, every 3 days, and twice a week. The normal alkaline phosphatase range in Bessey-Lowry units is 1 to 3. For the SGOT and SPGT the normal ranges are 60 to 100 and 5 to 35 units respectively.

in the urine. The hyperbilirubinemia consisted predominantly of the glucuronide (direct) fraction; increases were seen in the alkaline phosphatase either coincident with or before the deepening icterus (Figure 27).

As the months went by, it was paradoxical to find so few serious effects upon other tests of hepatic function. The day-to-day tests of serum transaminases were not alarming. For a long time, total serum protein and albumin concentrations were depressed very little if at all (Figure 27). As long as vitamin K was given parenterally or orally in a water-soluble form, the prothrombin times remained at or near 100 per cent. Failure to give the vitamin led to marked prolongation of the prothrombin times within a few days.

At one time or other, various tests were performed to rule out the possibility of mechanical obstruction of the homograft extrahepatic duct system. These have been described elsewhere (Starzl & Putnam 1969). The final diagnosis in each case was considered to be intrahepatic cholestasis. Possible explanations for the obstructive jaundice are considered in the article by Porter (1969a) in this volume on the basis of his pathologic analyses.

None of the patients immediately became seriously ill as a consequence of the late rejections. The 2 recipients who had pre-existing septic hepatic infarctions died after 133 and 186 days but the outcome was due at least as much to chronic upper abdominal infections as to hepatic failure. The others supported the effects of chronic hepatic dysfunction so well that serious questions have been raised about when late re-transplantation should be undertaken.

For example, the 2 longest survivors in our series whose original indication for operation was biliary atresia have now been followed for 17½ and 14 months. The first of these recipients has been jaundiced (Figure 27) but relatively healthy for a year. The second patient, who received re-transplantation after 68 days because of profound toxicity from an irreversible early rejection, has been icteric for most of the second post-transplantation period (Figure 13). When the jaundice first reappeared in these 2 cases, it was

Figure 24. The progression of recurrent hepatoma in a transplanted orthotopic liver. The clinical course is shown in Figure 22.

3 months – The examination is essentially normal.

6 months – There has been no significant change.

8 months – A notch in the hilum is now visible.

8½ mths. – Two weeks later the defect has become much more evident. Moreover, the liver has increased in size.

9 months – Further progression.

9½ mths. – At the time of this scan, jaundice appeared. The patient eventually died 339 days after transplantation.

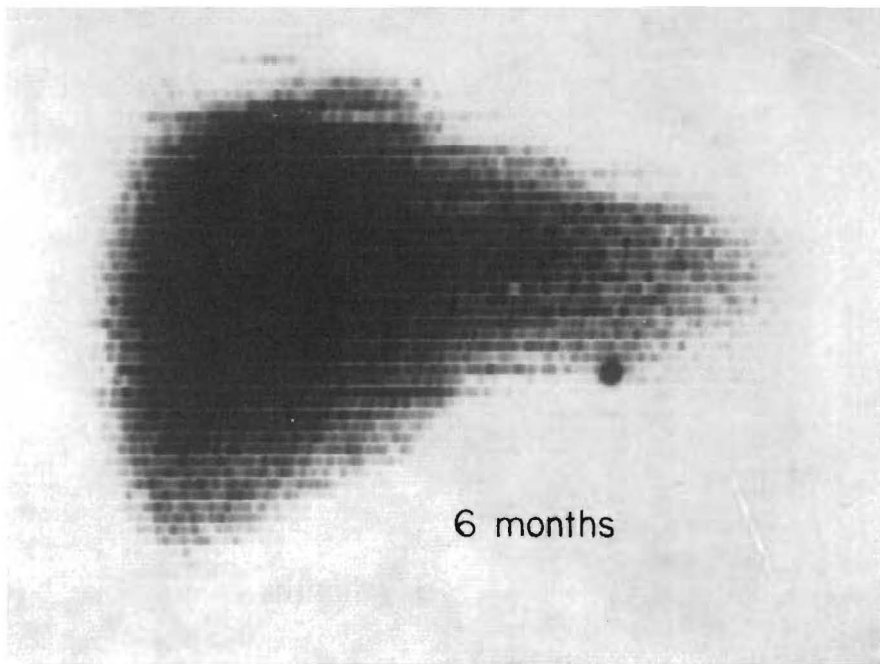
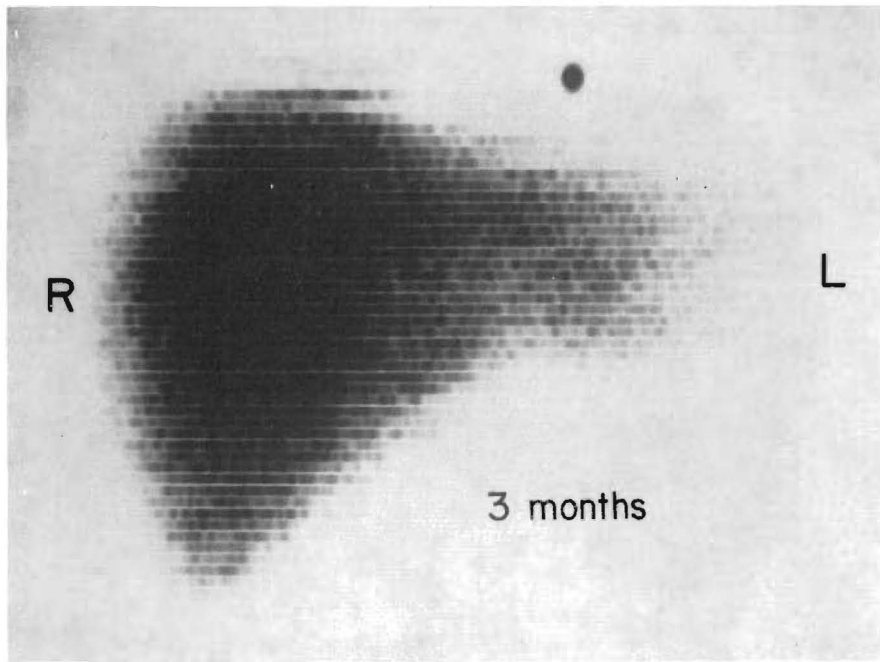


Figure 24 (text, see p. 46)

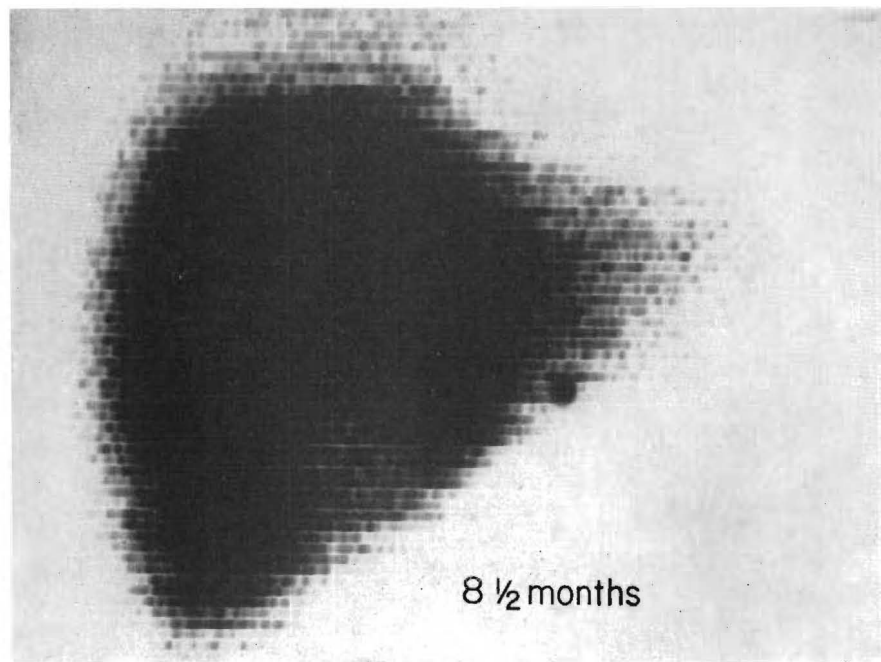
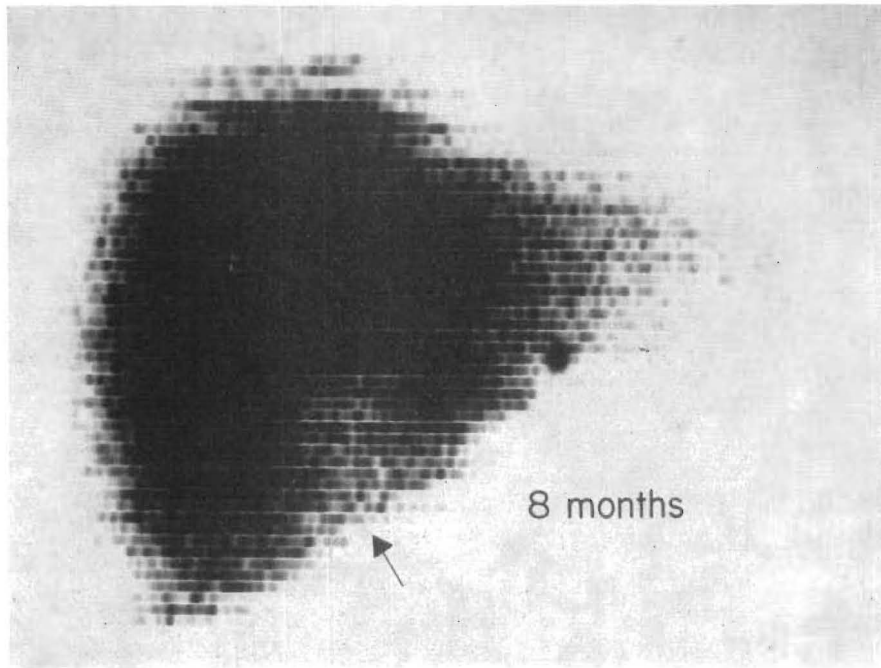


Figure 24 (text, see p. 46)

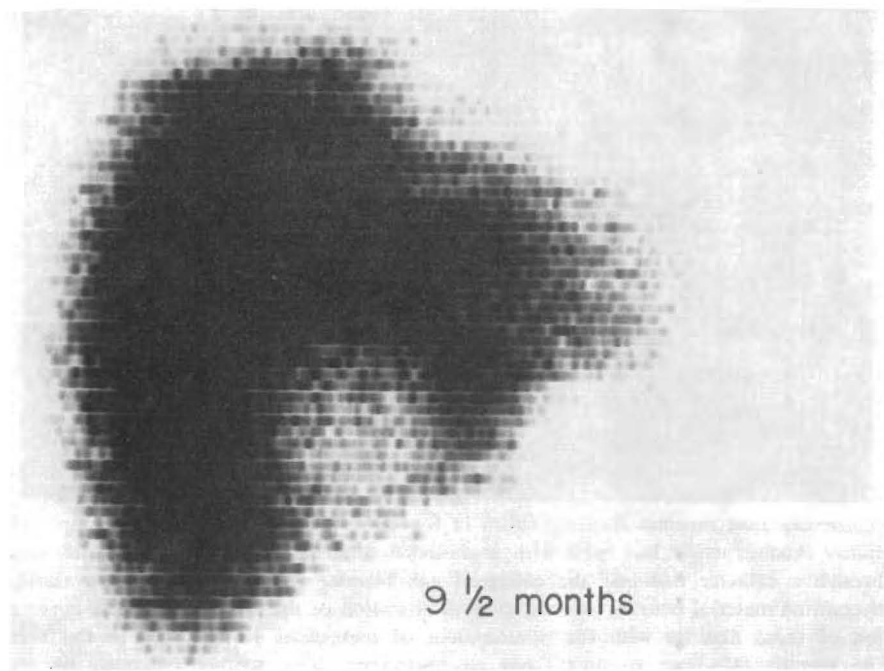
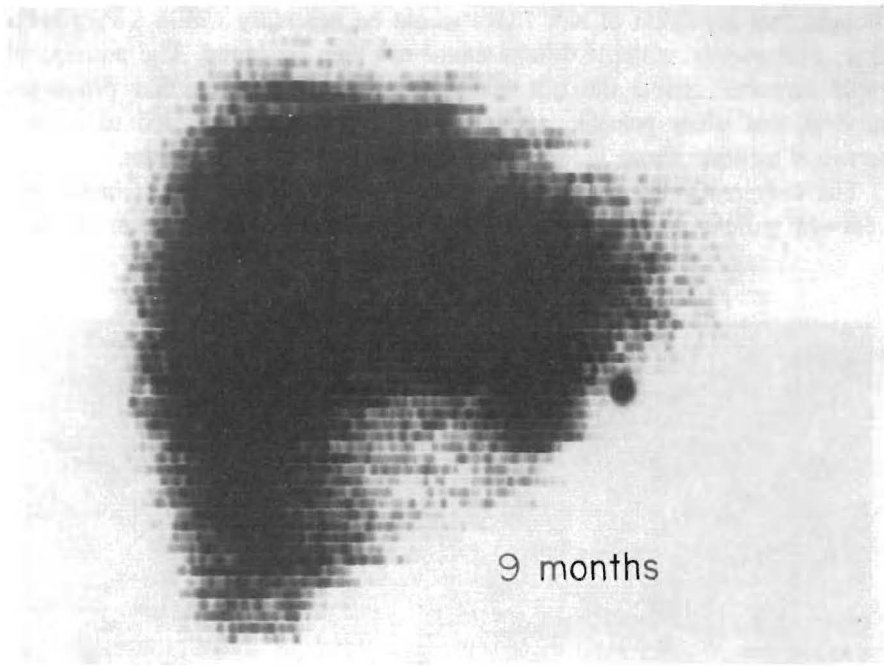


Figure 24 (text, see p. 46)

thought that provision of new livers would be necessary within a very short time. Fortunately, suitable donors could not then be found. The anticipated rapid downhill course did not materialize. The realization that prolonged survival was often possible under these circumstances has led to a conservative attitude about recommending a second organ transplant.

The only really late retransplantation carried out to date was in the 16-year-old patient described earlier who was found at reoperation to have

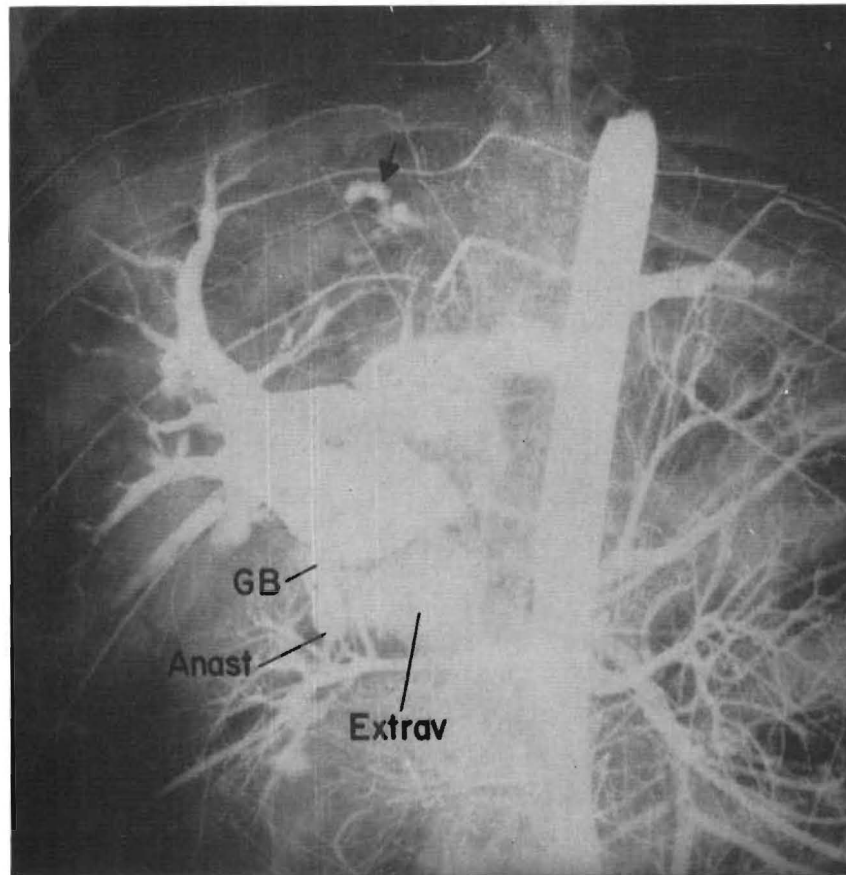


Figure 25. Post mortem cholangiogram in the same patient as in Figures 22 and 23. Biliary reconstruction had been with a cholecystoduodenostomy. The dye was injected through a catheter tied into the collapsed gall bladder (GB). Note the extravasation of contrast material (extrav) and the general dilatation of the duct system. The correlation of these findings with the development of metastases is discussed in the text. The vascular shadows resulted from an aortogram. The artifact indicated by the arrow was caused by removing a parenchymal specimen.

recurrent hepatoma (Figure 12). Both in this case and in the child who received a second liver after 68 days, the procedure was not especially difficult since the adhesions attaching the primary homograft to adjacent structures could easily be broken down.

The problem of late vascular change. In 2 of the 4 patients with hepatoma who lived for a long period after transplantation, the main hepatic artery thrombosed at an undetermined postoperative time. This was discovered at autopsy after 400 days in one patient (Figure 28). In the other, the occluded common hepatic artery was found at the time of retransplantation, 380 days after the first operation. Both primary homografts were being kept alive by portal blood alone plus whatever arterial collaterals had developed. It is unlikely that the vascular occlusions were related to the underlying malignancies. Instead, they probably represented a complication of immunologic etiology which will also be seen in patients treated with liver transplantation for non-neoplastic liver disease.

So far this concept has not been proved in the clinical series. Since none of the recipients with pre-existing benign disease has died after 6 months,

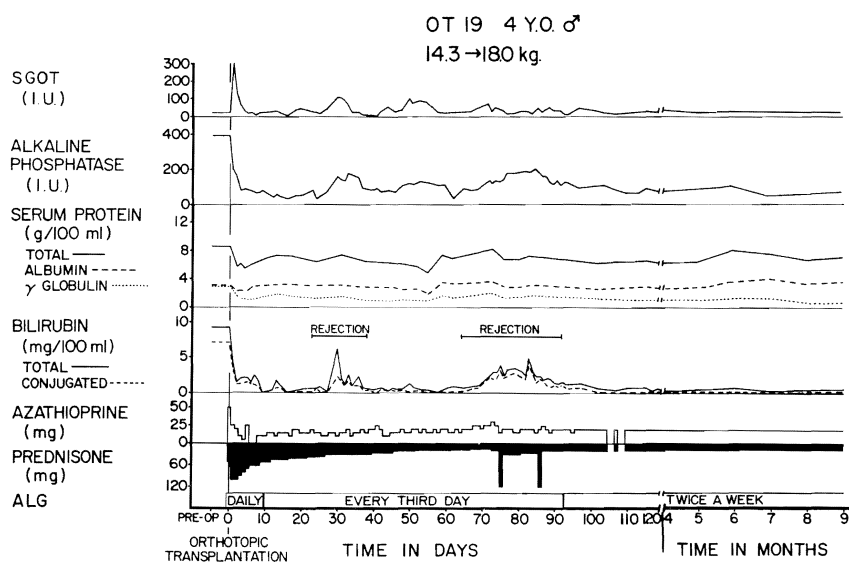


Figure 26. A 4-year-old child with intrahepatic biliary atresia who was treated with orthotopic liver transplantation. A very transient rejection occurred after one month. This underwent almost immediate and complete remission. A late rejection began on postoperative day 72 which was also easily controlled. Note the change in time scale after 4 months. The patient still has perfect liver function after a year. He is still receiving ALG. The normal enzyme values in international units at this age are: alkaline phosphatase (57–151), SGOT (3–27), and SGPT (2–30).

the state of their homograft vascular systems has not been accurately studied. However, one of the chronically surviving patients was submitted to aortography 14 months postoperatively. A stenosis was found at or near the arterial anastomosis (Figure 29). Striking abnormalities were also found in the distal vascular bed. The small terminal arteries were serpiginous and there were areas of dye staining that looked like venous lakes or areas of arterio-venous shunting (Figure 29). The angiographic changes were reminiscent of those in cirrhosis (Ekman 1966).

It is of interest that other changes in late failing homografts may be compared to cirrhosis. With serial liver scans, alterations including shrinkage and loss of isotope concentration have been seen that resemble those described by Christie *et al.* (1963) and Rozental *et al.* (1966) in end-stage cirrhosis. The histopathologic findings in this kind of liver are reviewed by Porter (1969a/b).

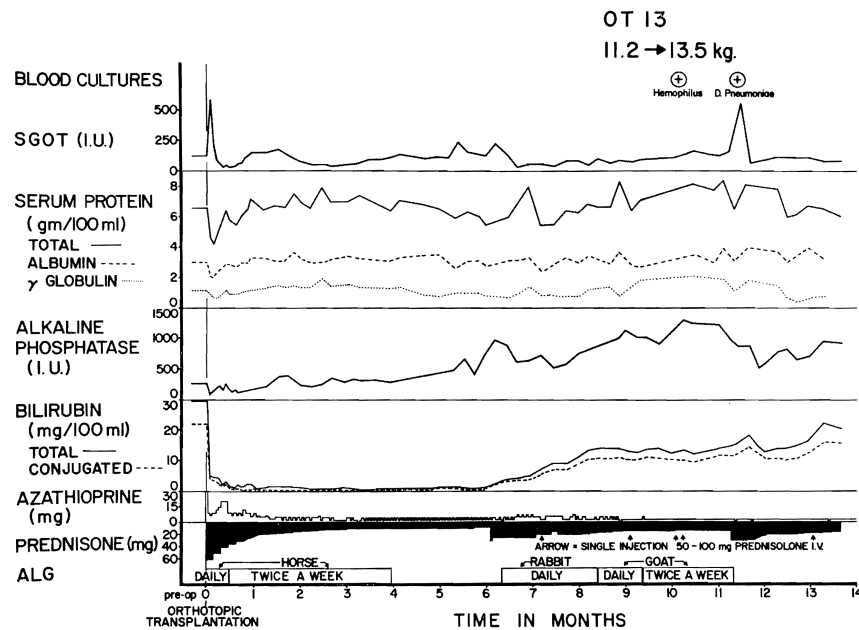


Figure 27. The first 14 months after the orthotopic liver transplantation of a patient whose original diagnosis was extrahepatic biliary atresia. As depicted in greater detail in Figure 7, an overt early rejection did not occur. However, delayed repudiation of the homograft became apparent a few weeks after discontinuing horse ALG. The manifestations of late rejection were principally those of obstructive jaundice. Biochemical evidence of severe hepatic necrosis was noted only at the time of the late septicemias. The source of the blood stream bacteria was never found. Normal ranges of serum enzymes: alkaline phosphatase 75 to 225 international units; SGOT 0 to 60; SGPT 0 to 55 international units.

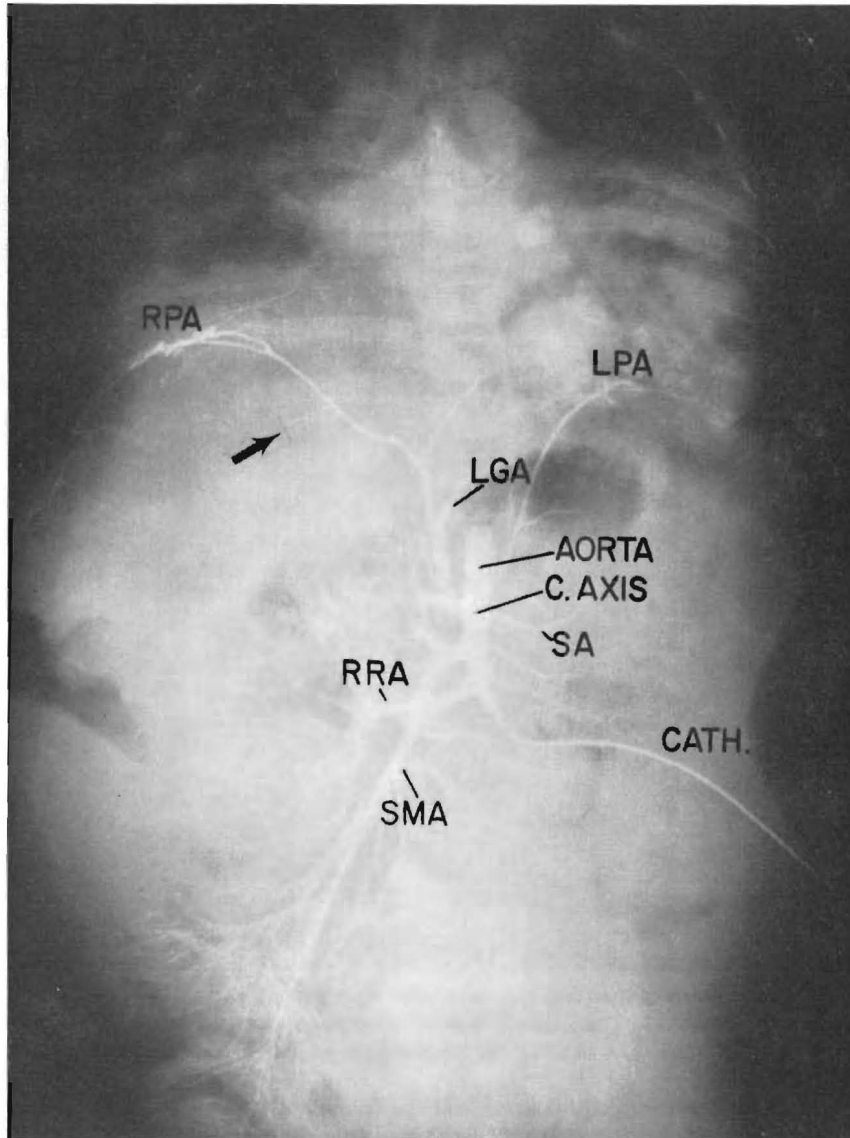


Figure 28. Post mortem aortogram obtained 400 days after orthotopic liver transplantation. Note that the hepatic artery is not present and that the only demonstrable arterial supply to the liver is from some small twigs (arrow) of the right phrenic artery (RPA). C. axis – coeliac axis; LGA – left gastric artery; LPA – left phrenic artery; RRA – right renal artery; SA – splenic artery; SMA – superior mesenteric artery.

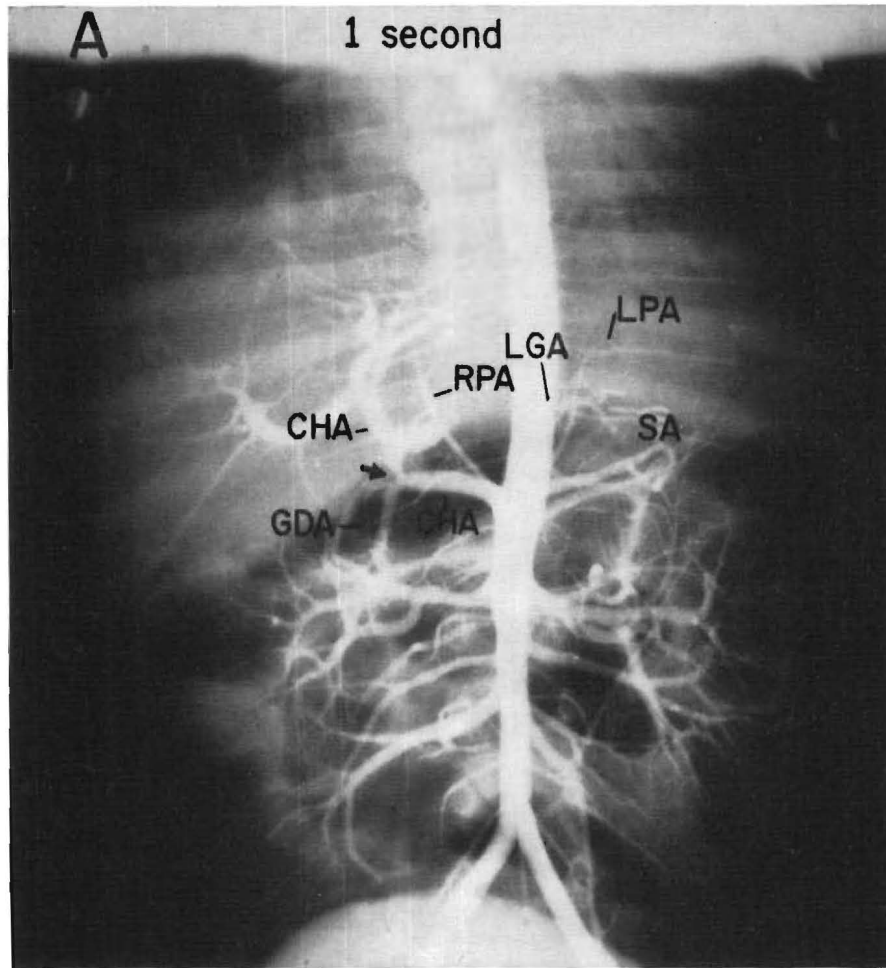


Figure 29. Aortogram obtained 425 days after operation in the patient whose course is shown in Figure 27. The original arterial anastomosis had been between the host proper hepatic artery just beyond the gastroduodenal artery (GDA) and the homograft coeliac axis.

- A - There is a stenosis (arrow) at or near the anastomosis. Note the large caliber of the right phrenic artery (RPA), probably as the result of its participation in a collateral blood supply. CHA - common hepatic artery; LGA - left gastric artery; LPA - left phrenic artery; SA - splenic artery. The X-ray is one second after injection.
- B - The terminal vessels are racemose. There are dye accumulations (arrows) suggestive of intrahepatic arterio-venous shunts. 1.5 seconds after injection.

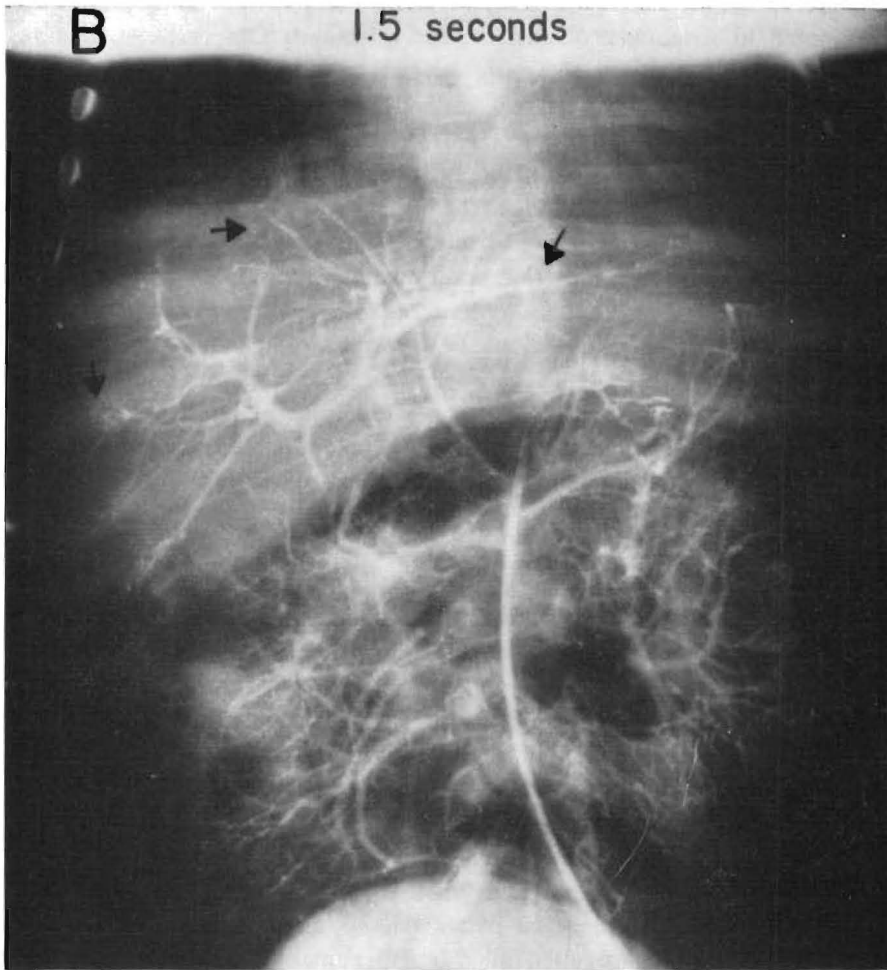


Figure 29 (text, see p. 54)

The Problem of Infection

Increased susceptibility to infection is a problem common to the transplantation of all organs as the result of the immunosuppressive measures taken to prevent repudiation of the grafts. It has become clear that the consequent risks may be disproportionately great after hepatic transplantation (Fulginiti *et al.* 1968, Starzl & Putnam 1969). Almost all of our first liver recipients developed overwhelming infections. It was suspected that the combination of drug over-dosage (especially with azathioprine) plus ischemic damage to the transplanted livers were the responsible factors. In subsequent patients who had extended survival in spite of the development of septic hepatic

infarction, the need for chronic antibiotic therapy was thought to have contributed to a number of extrahepatic infections. Observations in more recent cases in which the foregoing adverse conditions were avoided have added a more sinister dimension.

In the later patients, there was reason to believe that the transplanted intact liver was itself the portal of entry by which microorganisms of all kinds gained direct access to the blood stream. At various times after operation, both early and late, bacteria were cultured from the blood stream. These included flora that most likely originated from the gastrointestinal tract such as *E. coli*, *Aerobacter-klebsiella*, *Pseudomonas*, diptheroids, *Clostridium perfringens*, and *Corynebacterium bovis*. In addition, fungi were isolated as well as *D. pneumoniae*, *hemophilus*, and *Staphylococcus*. The patients were sometimes not clinically ill on these occasions. Only rarely could the source be found of the blood stream microorganisms. Nevertheless, the infections could be quickly controlled by the institution of specific antibiotic therapy.

It is likely that most or all these microorganisms passed through the liver homografts after being brought there via the portal venous and duct systems. If a 'leak' occurred through the ducts, this was apparently possible without the presence of cholangitis since histopathologic evidence for the latter diagnosis has not commonly been found (Porter 1969a/b). It might be added that septic portal phlebitis has not been diagnosed on morphologic grounds in any of the examined grafts. Nevertheless, visible injury to the intrahepatic portal veins with consequent increased 'porosity' is a hallmark of the immunologic injury of transplanted livers (Porter 1969a/b).

The ease with which bacteria seemed to enter the circulation through the hepatic homografts may be partly due to another kind of alteration that cannot be seen through a microscope, namely a subtle decline of a particular kind of reticuloendothelial activity. Conceivably, this could lead to a loss of the normal function of bacterial filtration. Not only would this contribute to greater permeability of the transplant to microorganisms, but it could in a more general way undermine the total host defenses against infection of other organ systems.

In spite of the special problems of infectious disease control which are introduced by liver transplantation, long-term survival after such procedures has not thereby been precluded in dogs, pigs, or humans. To consistently succeed, it will be necessary to use accurately controlled antibiotic therapy as guided by frequent cultures and sensitivities from multiple sampling sites including the blood.

Special Protein Studies

Proteins of liver origin. There is strong evidence that liver homografts retain their metabolic specificity after transfer to new hosts. This was first shown by studies of serum haptoglobin (Hp) and the group specific component (Gc) of the alpha₂ globulin fraction in patients after orthotopic liver transplantation. There are 3 kinds of Hp (Smithies & Walker 1956) and Gc (Hirschfeld *et al.* 1960) in the human population which can be detected with electrophoretic techniques.

In several of our cases of orthotopic transplantation, the donors have had different Hp or Gc types from the recipients. Within a few hours to a few days after operation, only the donor protein fractions were present (Kashiwagi *et al.* 1968, Starzl *et al.* 1964); the changes were complete and permanent (Kashiwagi *et al.* 1968). The therapeutic implication of these findings is that hepatic-based inborn errors of metabolism could be effectively treated with liver transplantation. The concept has been conclusively tested by Kuster *et al.* (1967). Using mongrel canine donors, they were able to cure the gout naturally present in Dalmatian recipients. Conversely, the transplantation of Dalmatian livers conferred the defect in uric acid metabolism upon mongrel recipients.

It is highly likely that similar information will be forthcoming about a number of other protein genotypes. Alper *et al.* (1969) have traced a C'3 phenotype from a donor to a human liver recipient treated in Boston. There was substitution of the new complement for the old type during the 45 days of postoperative survival.

Immunoglobulins. Of the aforementioned proteins, it was previously thought that at least the Hp and Gc were exclusively synthesized by the liver. Consequently, the observations in the liver recipients were not unexpected. Analogous studies of the gamma G globulin types were also carried out in 10 patients after orthotopic transplantation. Since such immune globulins are not normally hepatic in origin, it was surprising to find that the Gm types of the donors were transmitted to the recipients.

The studies have been reported by Kashiwagi (1969). In essence, he showed that the pre-existing Gm types of the recipients were never lost after liver transplantation. However, new donor-specific types were added and these persisted in highly significant quantities for at least as long as the one-year period of maximum follow-up.

Some clarification of the source of the new immunoglobulins was provided by the histopathologic studies of Porter (1969a/b). In many of the human homografts, he found prominent lymphoid deposits which had apparently been transferred with the homografts and which had survived in recognizable form. The lymphoid follicles contained prominent germinal centers and many

plasma cells in the medulla. The latter cells probably were producers of donor gamma G globulin.

Porter (1969a/b) also carried out sex identification studies of male homografts transplanted to females, using a modification of the technique first described by Barr *et al.* (1950). The sex was determined of the Kupffer cells and of the hepatic arterial and portal venous endothelial cells. In the chronically surviving female patients, the Kupffer cells became the sex of the recipient, thereby ruling out this portion of the reticuloendothelial system as the source of the new Gm types.

AUXILIARY LIVER TRANSPLANTATION

Both in experimental animals and in patients, survival after auxiliary transplantation has been inferior to that with the orthotopic procedure. The reasons for these disappointing results have not been entirely clear, but plausible explanations have been advanced indicating both metabolic and mechanical factors.

Metabolic Considerations

When auxiliary liver transplantation was first attempted in immunosuppressed canine recipients, a curious and disquieting observation was soon made (Starzl *et al.* 1964). The extra organs underwent rapid shrinkage which was usually evident within two weeks and which was very advanced at all times after one month. Many subsequent studies, especially those of Marchioro (1965, 1967), have been designed to explain the atrophy and to define the conditions for its avoidance.

The results of these investigations, which have been reviewed in detail elsewhere (Starzl & Putnam 1969), have shown that two co-existing livers may engage in a physiologic competition that can result in serious injury to one or the other organ. The competitive potential of the individual livers can be unbalanced by a variety of factors. Advantageous conditions include perfusion of adequate quantities of blood, particularly if the portal component is derived from the intestinal venous (splanchnic) effluent. Handicaps may be imposed by obstructing the biliary drainage, by reducing the total blood flow, by depriving the organ of flow from splanchnic sources, or by hindering it in a variety of other ways. The favored liver in such a situation will flourish while the disadvantaged one shrinks.

The first step in minimizing or preventing auxiliary homograft atrophy in animal experiments is to avoid situations in which the transplanted liver is placed at a positive physiologic disadvantage. The second step is to fully appreciate that the homograft requires a better than equal environmental

opportunity to counteract the immunologic duress which it alone must suffer, if there is not a perfect histocompatibility match or else totally effective immunosuppression. In dogs, auxiliary homograft atrophy can largely be prevented if it is re-arterialized and also given a portal inflow from the splanchnic venous system, and if the host liver is damaged with an Eck fistula. Additional privileges can be extended to the homograft by injuring the host liver in other ways, such as by ligation of the common duct.

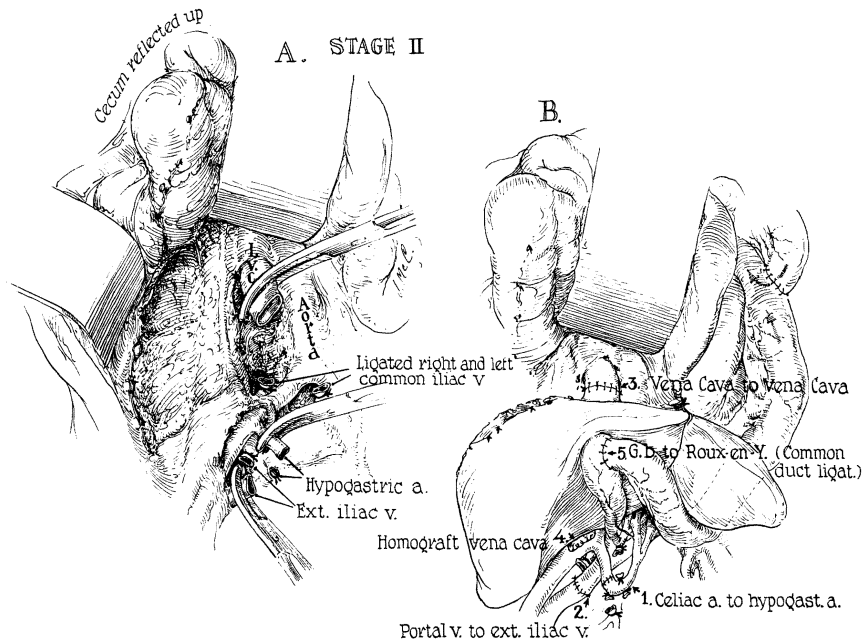


Figure 30. The method of auxiliary liver transplantation used in a 47-year-old patient on 5 July 1965; both donor and recipient had O blood type. The donor, a 12-year-old boy, died from head trauma a few minutes after arrival at the hospital. Circulation was maintained for 45 minutes by external cardiac massage until the liver could be cooled by intraportal infusion of a chilled electrolyte solution. The subsequent hypothermic period required to remove the liver and revascularize it in the recipient was 120 minutes. The outflow of the new organ was directed into the transected inferior vena cava. The portal blood supply was obtained from the common iliac vein. The hypogastric artery easily reached the coeliac axis for end-to-end anastomosis. The liver was small enough to readily fit behind the reflected cecum. The operation was done in 5 hours with a blood loss of 2,500 ml.

A - Recipient operative field.

B - Completed operation. Note the roux-en-Y cholecystojejunostomy.

(By permission of *Arch. Surg.* 93, 107, 1966.)

Clinical Experience

It is virtually certain that the principle of interliver competition applies in a general way to auxiliary hepatic transplantation in humans. However, what is not known is how important this factor will be. In adult patients with cirrhosis who might be candidates for hepatic transplantation, the competitive capacity of their own livers would be expected to be largely lost. On the other hand, it is conceivable that the host liver in pediatric victims of biliary atresia could be capable of promptly and seriously compromising the welfare of the new organ, since the hepatic parenchymal function in such patients is often surprisingly well maintained until just before death.

The above comments remain speculative since the longest survival to date after auxiliary liver transplantation in man has only been 34 days. In this case, the diagnosis was alcoholic cirrhosis. One day before transplantation a portacaval anastomosis was performed. The extra liver was obtained from a 12-year-old boy and placed in the right paravertebral gutter (Figure 30). It functioned promptly for several days until the onset of a rejection which

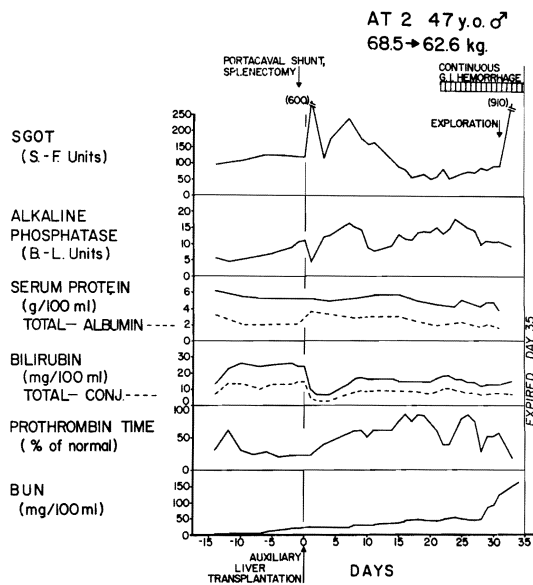


Figure 31. The course of the patient whose operation is depicted in Figure 30. There was apparently good initial function which later deteriorated when rejection was not controlled. Note the rapid development of azotemia late in the course. The gastrointestinal bleeding which was the immediate cause of death was due to widespread intestinal moniliiasis; the exploratory laparotomy was made in an effort to control the bleeding. The immunosuppression in this case was with azathioprine and prednisone. Profound leukopenia developed during the fourth postoperative week.

Reported auxiliary liver transplants*

No.	Disease	Date of operation	Survival (days)	Recipient			Donor			Cause of death		
				Age	Sex	Weight (kg)	Blood type	Age	Sex		Weight (kg)	Blood type
<i>Denver cases</i>												
1	Alcoholic cirrhosis	2-20-65	22	50	M	68.0	A	79	M	60.0	A	Sepsis, hepatic failure
2	Alcoholic cirrhosis	7- 5-65	34	47	M	68.6	O	12	M	42.0	O	Sepsis, hepatic failure, GI bleeding
3	Extrahepatic biliary atresia	11- 3-65	0	1½	F	8.0	A	7/12	F	6.0	A	Cardiac arrest
4	Alcoholic cirrhosis	6-20-68	24	48	M	84.0	A	Newborn	F	3.1	A	Sepsis, hepatic & renal failure
<i>Other reported cases</i>												
Absolon	Extrahepatic biliary atresia	11- 3-64	13	11/12	M	7.0	O	2½	F	9.0	A	Bile peritonitis, sepsis
Cree	Subacute hepatitis	10-27-66	2	17	M	-	-	Elderly	F	-	O	Hepatic failure
Fonkalsrud	Hepatoma	3- 2-67	12	46	M	-	-	9	M	-	-	Thrombosis hepatic artery, homograft necrosis
Calne	Alcoholic cirrhosis	Summer 1967?	½	47	M	-	-	50	F	-	-	Hemorrhage
Sheil	Cirrhosis	Unstated	3	45	M	-	-	44	F	-	-	Hepatic failure

* The references to the pertinent publications have been summarized in a recent book on liver transplantation (Starzl & Putnam 1969).

was never reversed (Figure 31). The patient eventually died of multiple infections.

During life several liver scans were obtained with I^{131} -Rose Bengal and with Au^{198} isotopes. The Rose Bengal scans showed an approximately equal division of the specific radioactivity between the two livers. The gold isotope was concentrated almost exclusively in the homograft. With both kinds of studies there appeared to be a diminution in the size of the transplanted organ (Figures 32). The impression of atrophy could not be supported with certainty from the histopathologic studies of the homograft (Porter 1969a/b). However, both hepatocyte loss and collapse of the supporting reticulin were features of the autopsy specimen, but these findings have been seen in orthotopic homografts.

Many other attempts have been made at auxiliary hepatic homotransplantation of which only 8 have been formally reported (Table II). Dr. Carl Groth of Stockholm recently made an international survey and found 15 more cases. Among the 24 reported and unreported recipients, there were only 4 including the patient described above who lived for as long as 3 weeks. Within the total group there was an extraordinary incidence of technical difficulties. Moreover, almost all the patients who lived for more than a few days after operation developed lethal pulmonary complications; abdominal overcrowding by the extra organs appeared to have been a contributory factor in several instances.

In view of this experience, it would seem prudent to give special thought to the relative size of the homograft which is available. Our present belief is that the organ would ideally come from a smaller donor and would be placed in a recipient whose abdomen had been prepared by stretching with long-standing ascites. Such a perfect anatomical situation was present in the recipient who lived for 34 days.

In the human it may be exceptionally difficult to provide an auxiliary liver with a portal flow from splanchnic venous sources. For this reason it is our present opinion that the best and simplest operations are compromise procedures such as that depicted in Figure 30. With such a technique, the homograft is revascularized in the right side of the abdomen as with portacaval transposition. Portal blood flow is diverted away from the host liver with a portacaval anastomosis. If the portal decompression can be done in advance of the transplantation, insertion of the homograft is made immeasurably easier by obviating the need to work in a retroperitoneal space filled with high pressure venous collaterals.

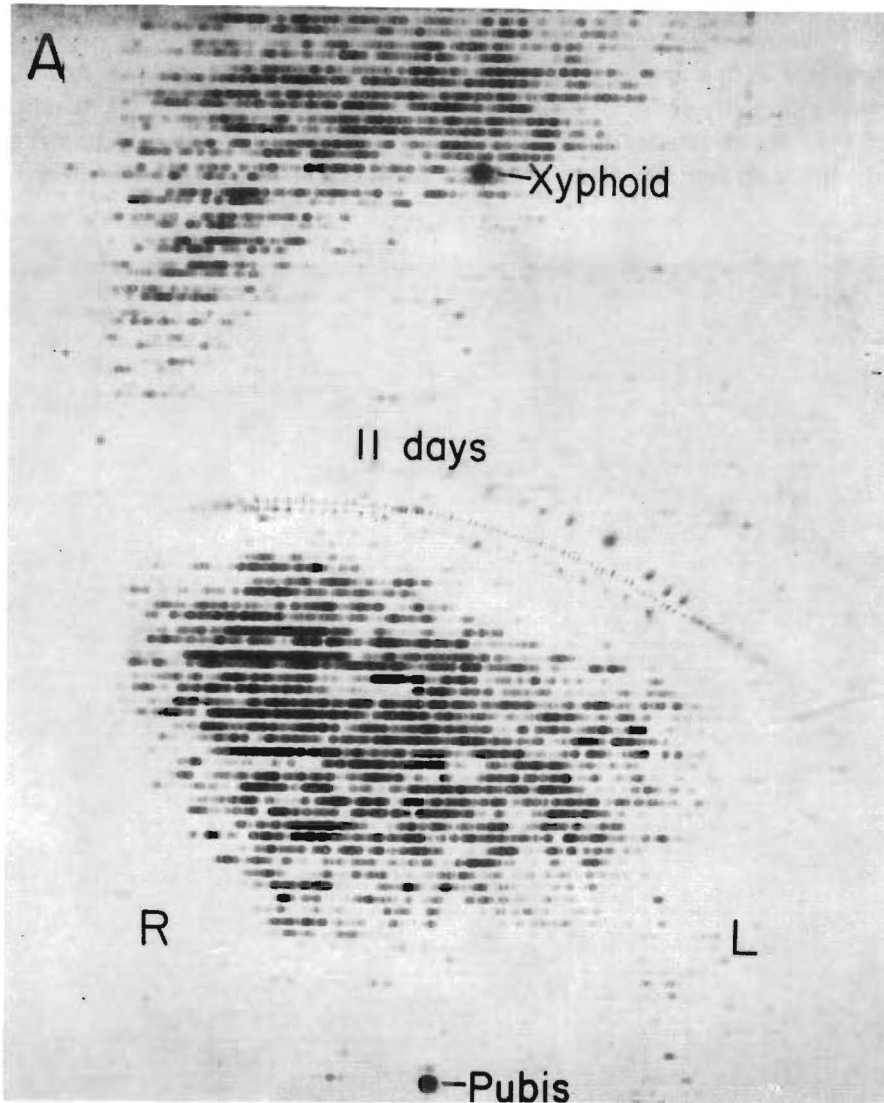


Figure 32. Three rose bengal (I^{131}) scans in the same patient as in Figures 30 and 31. The photographic reproductions were with identical magnification techniques.

- A - Eleven days postoperative. There is sharing of isotope excretion by the host liver and the homograft.
- B - Twenty-one days postoperative. The concentration of rose bengal is decreased in both livers.
- C - Twenty-eight days postoperative. The deterioration has continued. The shadow cast by the homograft is now distinctly smaller, but the change could have represented a reduction in homograft function rather than in real size.

SUMMARY

Although all the first attempts at orthotopic liver transplantation in humans resulted in early recipient death, the experience compiled since the summer of 1967 has established that this procedure can prolong life in patients dying of hepatic disease. To date the longest survival has been 17 months. Never-

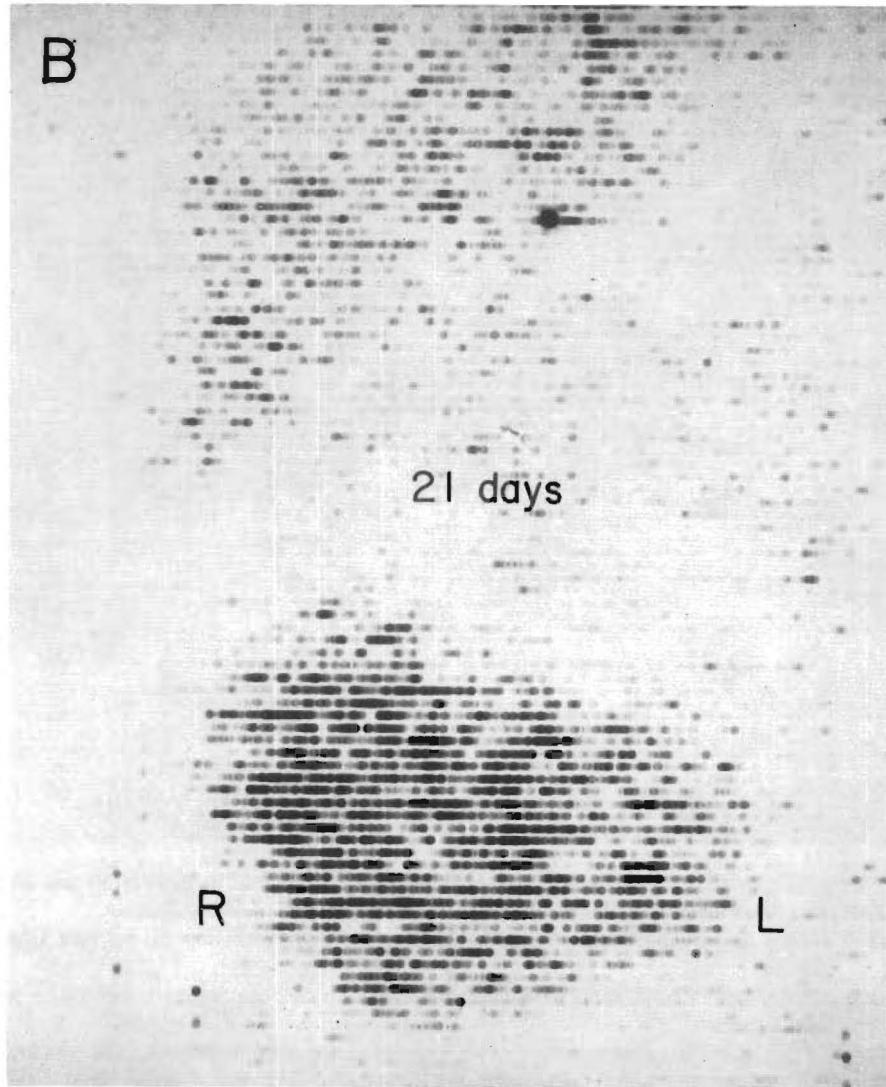


Figure 32 (text, see p. 63)

theless, the operation has proved to be a hazardous one, mostly because of technical difficulties in its performance. Later, a number of complications have been seen both from rejection and from the immunosuppressive therapy used to control this process. The malignant disease has recurred in all patients whose original indication for liver transplantation was hepatoma.

Results with auxiliary liver transplantation in animals have been inferior

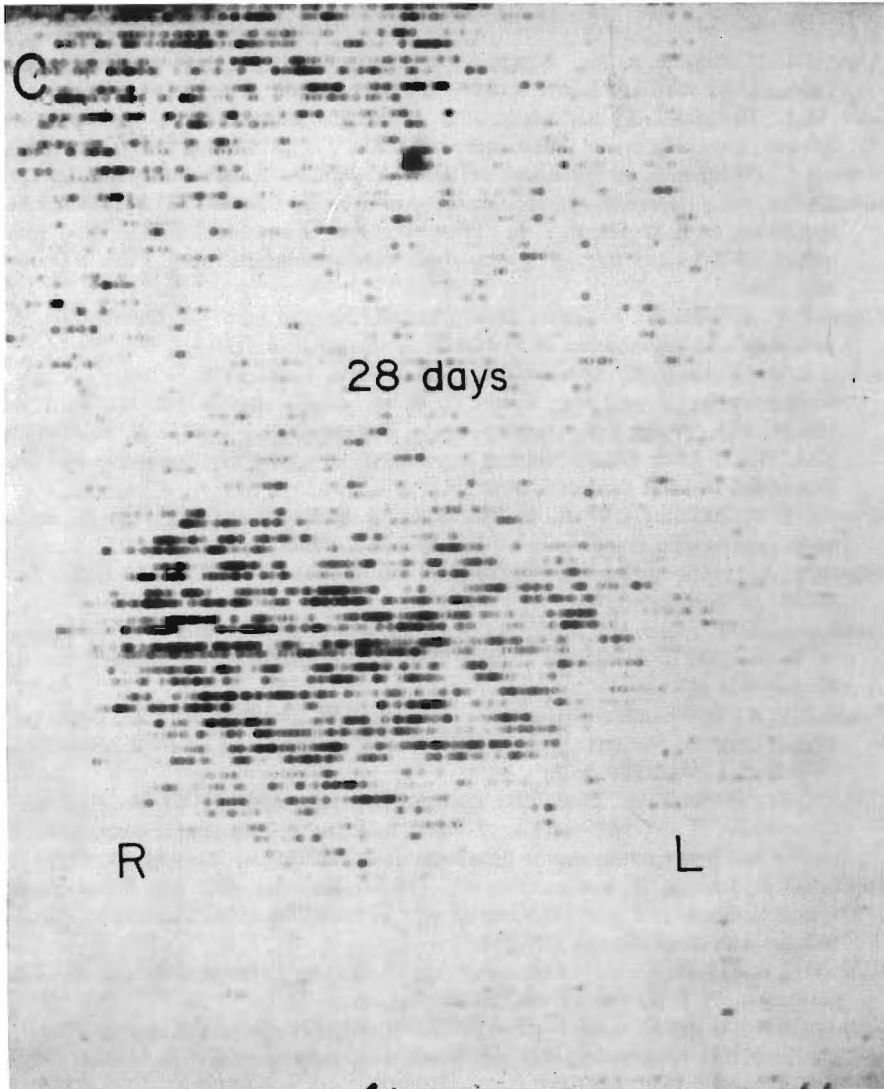


Figure 32 (text, see p. 63)

to those with the orthotopic operation, at least partly because the homograft must not only face immunologic rejection, but must also apparently compete for metabolic substrate with the host's own liver. Although the competition between the two livers would not be expected to be a severe problem in patients dying with hepatic failure, survival in human recipients of auxiliary homografts has not yet exceeded 34 days.

REFERENCES

- Alper, C. A., Johnson, A. M., Birtch, A. G. & Moore, F. D. (1969) Human C³: Evidence for the liver as the primary site of synthesis. *Science* **163**, 286.
- Barr, M. L., Bertram, L. F. & Lindsay, H. A. (1950) The morphology of the nerve cell nucleus, according to sex. *Anat. Rec.* **107**, 283.
- Berman, C. (1959) Primary carcinoma of the liver. *Bull. N. Y. Acad. Med.* **35**, 275.
- Brettschneider, L., Daloz, P. M., Huguet, C., Porter, K. A., Groth, C. G., Kashiwagi, N., Hutchison, D. E. & Starzl, T. E. (1968) The use of combined preservation techniques for extended storage of orthotopic liver homografts. *Surg. Gynec. Obstet.* **126**, 263.
- Calne, R. Y. & Williams, R. (1968) Liver transplantation in man – I. Observations on technique and organization in five cases. *Brit. med. J.* **4**, 535.
- Calne, R. Y., Williams, R., Dawson, J. L., Ansell, I. D., Evans, D. E., Flute, P. T., Herbertson, P. M., Joysey, V., Keates, G. H. W., Knill-Jones, R. P., Masow, S. A., Millard, P. R., Pena, J. R., Pentlow, B. D., Salaman, J. R., Sells, R. A. & Cullum, P. A. (1968) Liver transplantation in man. II. A report of two orthotopic liver transplants in adult recipients. *Brit. med. J.* **4**, 541.
- Christie, J. H., MacIntyre, W. J., Crespo, G. G. & Koch-Weser, D. (1963) A report upon radioisotope scanning in hepatic cirrhosis. *Radiology* **81**, 455.
- Ekman, C. A. (1966) Angiography in the diagnosis of liver cirrhosis. *Scand. J. clin. Lab. Invest.* **18** (Suppl. 92), 45.
- Fonkalsrud, E. W., Ono, H., Shafey, O. A., Joseph, W. L., Tocornal, J. & Longmire, W. P., Jr. (1967) Allogeneic canine liver transplantation with cadaver donors. *Surgery* **62**, 333.
- Fulginiti, V. A., Scribner, R., Groth, C. G., Putnam, C. W., Brettschneider, L., Gilbert, S., Porter, K. A. & Starzl, T. E. (1968) Infections in recipients of liver homografts. *New Eng. J. Med.* **279**, 619.
- Groth, C. G., Porter, K. A., Otte, J. B., Daloz, P. M., Marchioro, T. L., Brettschneider, L. & Starzl, T. E. (1968) Studies of blood flow and ultrastructural changes in rejecting and nonrejecting canine orthotopic liver homografts. *Surgery* **63**, 658.
- Hirschfeld, J., Jonsson, B. & Rasmuson, M. (1960) Inheritance of a new group-specific system demonstrated in normal human sera by means of an immunoelectrophoretic technique. *Nature (Lond.)* **185**, 931.
- Kashiwagi, N. (1969) Specific immunochemical studies. In *Experience in hepatic transplantation*. W. B. Saunders Co., Philadelphia.
- Kashiwagi, N., Groth, C. G. & Starzl, T. E. (1968) Changes in serum haptoglobin and group specific component after orthotopic liver transplantation in humans. *Proc. Soc. exp. Biol. Med.* **128**, 247.
- Kuster, G., Shorter, R. G., Dawson, B. & Hallenbeck, O. A. (1967) Effect of allogeneic

- hepatic transplantation between Dalmatian and mongrel dogs on urinary excretion of uric acid. *Surg. Forum* **18**, 360.
- Lawrence, G. H., Grauman, D., Lasersohn, J. & Baker, J. W. (1966) Primary carcinoma of the liver. *Amer. J. Surg.* **112**, 200.
- Marchioro, T. L., Huntley, R. T., Waddell, W. R. & Starzl, T. E. (1963) Extracorporeal perfusion for obtaining postmortem homografts. *Surgery* **54**, 900.
- Marchioro, T. L., Porter, K. A., Brown, B. I., Otte, J. B. & Starzl, T. E. (1967) The effect of partial portacaval transposition on the canine liver. *Surgery* **61**, 723.
- Marchioro, T. L., Porter, K. A., Dickinson, T. C., Faris, T. D. & Starzl, T. E. (1965) Physiologic requirements for auxiliary liver homotransplantation. *Surg. Gynec.* **121**, 17.
- McKneally, M. F., Atai, M., Olivers, F. E. & Kelly, W. D. (1965) Salvage of cadaver organs with left heart bypass. *Surg. Forum* **16**, 272.
- Mikaeloff, P., Kestens, P. J., Dureau, G., Rassat, J. P., Haxhe, J. J., Alexandre, G., Dubernard, J. M., Cuilleret, J., Hassoun, A., Maldaque, P., Morelle, J. & Descotes, J. (1965) Transplantation orthotopique du foie chez le chien, apres conservation de l'organe par perfusion. (Orthotopic transplantation of the liver in dogs after conservation of the organ by perfusion). *Mém. Acad. Chir.* **91**, 711.
- Moore, F. D., Wheeler, H. B., Demissianos, H. V., Smith, L. L., Balankura, O., Abel, K., Greenberg, J. B. & Damin, G. J. (1960) Experimental whole-organ transplantation of the liver and of the spleen. *Ann. Surg.* **152**, 374.
- Patton, R. B. & Horn, R. C., Jr. (1964) Primary liver carcinoma: autopsy study of 60 cases. *Cancer* **17**, 757.
- Picache, R. S., Kapur, B. M. L. & Starzl, T. E. (1969) The effect of liver disease on the need for venous decompression during the anhepatic phase of canine orthotopic liver transplantation. *Surgery* (in press).
- Porter, K. A. (1969a) The pathology of liver transplantation. *Transplant. Rev.* **2**, 129.
- Porter, K. A. (1969b) Pathology of the orthotopic homograft. In *Experience in hepatic transplantation*, ed. T. E. Starzl. W. B. Saunders Co., Philadelphia.
- Rozental, P., Miller, E. B. & Kaplan, E. (1966) The hepatic scan in cirrhosis; biochemical and histologic correlations. *J. nucl. Med.* **7**, 868.
- Schalm, S. W. (1968) *Een eenvoudige en klinisch toepasbare methode voor het conserveren van een levertransplantaat*. Leiden, Drukkerij 'Luctor et Emergo'.
- Smithies, O. & Walker, N. F. (1956) Notation for serum protein groups and the genes controlling their inheritance. *Nature* **178**, 694.
- Starzl, T. E. with Putnam, C. W. (ed.) (1969) *Experience in hepatic transplantation*. W. B. Saunders Co., Philadelphia.
- Starzl, T. E., Brettschneider, L., Penn, I., Bell, P., Groth, C. G., Blanchard, H., Kashiwagi, N. & Putnam, C. W. (1969a) Orthotopic liver transplantation in man. *Transplant. Proc.* **1**, 216.
- Starzl, T. E., Groth, C. G., Brettschneider, L., Moon, J. B., Fulginiti, V. A., Cotton, E. K. & Porter, K. A. (1968a) Extended survival in 3 cases of orthotopic homotransplantation of the human liver. *Surgery* **63**, 549.
- Starzl, T. E., Groth, C. G., Brettschneider, L., Penn, I., Fulginiti, V. A., Moon, J. B., Blanchard, H., Martin, A. J., Jr. & Porter, K. A. (1968b) Orthotopic homotransplantation of the human liver. *Ann. Surg.* **168**, 392.
- Starzl, T. E., Kaupp, H. A., Brock, D. R., Lazarus, R. E. & Johnson, R. V. (1960) Reconstructive problems in canine liver homotransplantation with special reference to the postoperative role of hepatic venous flow. *Surg. Gynec. Obstet.* **111**, 733.

- Starzl, T. E., Marchioro, T. L., Rowlands, D. T., Jr., Kirkpatrick, C. H., Wilson, W. E. C., Rifkind, D. & Waddell, W. R. (1964) Immunosuppression after experimental and clinical homotransplantation of the liver. *Ann. Surg.* **160**, 411.
- Starzl, T. E., Marchioro, T. L., von Kaulla, K. N., Hermann, G., Brittain, R. S. & Waddell, W. R. (1963) Homotransplantation of the liver in humans. *Surg. Gynec. Obstet.* **117**, 659.
- Starzl, T. E., Porter, K. A., Brettschneider, L., Penn, I., Bell, P., Putnam, C. W. & McGuire, R. L. (1969b) Clinical and pathologic observations after orthotopic transplantation of the human liver. *Surg. Gynec. Obstet.* **128**, 327.
- von Kaulla, K. N., Kay, H., von Kaulla, E., Marchioro, T. L. & Starzl, T. E. (1966) Changes in blood coagulation before and after hepatectomy or transplantation in dogs and man. *Arch. Surg.* **92**, 71.