

117

A Reprint from

VOLUME ONE

OPERATIVE SURGERY

SECOND EDITION

Under the General Editorship of

CHARLES ROB

M.C., M.D., M.CHIR., F.R.C.S.

and

RODNEY SMITH

M.S., F.R.C.S.

Published by

BUTTERWORTHS

WHOLE ORGAN TRANSPLANTATION

THOMAS E. STARZL, M.D., PH.D.

*Professor of Surgery, University of Colorado School of Medicine;
Chief of Surgery, Denver Veterans Administration Hospital*

THOMAS L. MARCHIORO, M.D.

*Associate Professor of Surgery, University of Colorado School of Medicine (Markle Scholar);
Assistant Chief of Surgery, Denver Veterans Administration Hospital*

and TANOUS D. FARIS, M.D.

*Assistant Professor of Surgery, University of Colorado School of Medicine;
Clinical Investigator, Denver Veterans Administration Hospital*

PRE-OPERATIVE

Indications

The desirability of whole organ transplantation exists with the irreversible functional failure of any vital organ system. However, an indication for such a procedure can be said to exist only with terminal renal disease since, to date, only the kidney has been transplanted with resultant significant prolongation of life. The following remarks will therefore be principally concerned with the operative and certain non-operative problems of renal transplantation. A brief description of the techniques for transplantation of other organs will be included at the end of this chapter since it is probable that such methods will prove to have clinical value within the next few decades.

In judging the indication for renal transplantation it should be determined that the patient is capable of restoration to relative health by the provision of a homograft. Not infrequently, secondary and inherently lethal complications have already occurred. Thus the patient with chronic renal failure may have developed advanced generalized atherosclerosis or permanent myocardial injury. In this connexion, the older patient must be viewed with particular suspicion since such complications are present in a high proportion of uraemic individuals over 35 or 40 years; the results in such older patients have been poor in most centres.

Because immunosuppressive therapy must be employed to prevent rejection of the homograft, the patient's ability to combat infection will be predictably reduced. For this reason it is imperative that candidates with established foci of sepsis be eliminated; the inability to control such an infection in the pre-transplant period of preparation usually establishes the inadvisability of proceeding. Occasionally it may be possible to eliminate an upper urinary tract infection by preliminary recipient nephrectomy. With this expedient the case can be rendered clean prior to the institution of immunosuppressive measures, making the risk of a subsequent transplant acceptable. The presence of a normal lower urinary tract is an additional prerequisite.

The aetiology of the recipient renal disease does not have a crucial effect upon prognosis. Patients with glomerulonephritis, burned-out pyelonephritis, polycystic renal disease, renal hypoplasia and surgical removal of their only kidney, have all been successfully treated with renal homografts.

The availability of a suitable donor may sway the final judgment for or against operation. The presence of a willing identical twin would materially influence a favourable decision, since an immunological barrier does not exist in such cases. The availability of a non-twin blood relative is also a favourable condition; here, immunosuppression will be required but often in relatively non-toxic quantities. With the non-related volunteer or cadaveric donors, the need for post-operative immunosuppression is apt to be excessive.

Under the last circumstance, a badly depleted recipient is unlikely to be able to survive the rigours of the surgical procedures as well as those of subsequent high dose therapy with steroids and radiomimetic drugs.

A special note is in order concerning the red cell blood group combinations which are permissible between donors and recipients. Experience in the past few years has shown that the rules of tissue transfer between patients who are not of the same major blood group are similar to those which pertain to the use of non-matched blood. These are summarized in Table 1.

Special equipment

Fine cardiovascular instruments are necessary. The use of this equipment, which is available in most good hospitals, is subsequently illustrated.

Pre-operative preparation

Conservative measures such as regulation of fluid and salt intake and control of hypertension may be of value but, in addition, resuscitation with the artificial kidney is almost

Table 1
DIRECTION OF ACCEPTABLE
MISMATCHED TISSUE TRANSFER*

O to non O	Safe	A to non A	Dangerous
RH- to RH	Safe	B to non B	Dangerous
RH to RH-	Rel- atively safe	AB to non AB	Dangerous

* O is universal donor, AB is universal recipient.

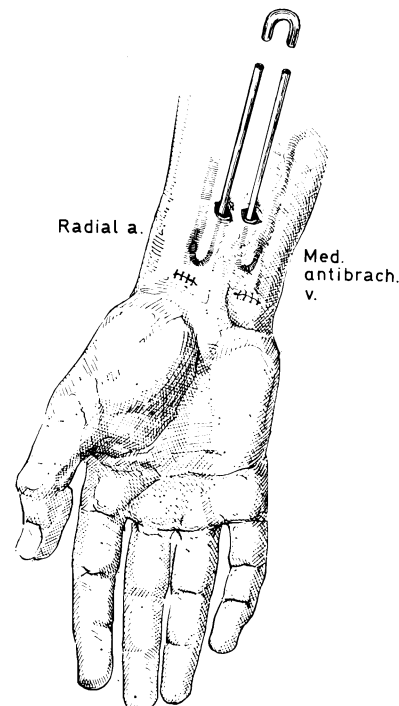
always necessary. Frequently multiple dialyses are required. Consequently, it is usually advisable to place a chronic indwelling arterio-venous cannula so that peripheral vessels are not needlessly sacrificed with each run on the artificial kidney. With a chronic shunt in place the metabolic abnormalities can be slowly corrected without a sense of urgency. In a well-treated case, the potential recipient will be able to take a healthful diet, resume ambulation, and ultimately be brought to the operating room in a greatly improved condition.

OPERATIONS IN RENAL
TRANSPLANTATION

Arterio-venous shunt for pre-operative haemodialysis

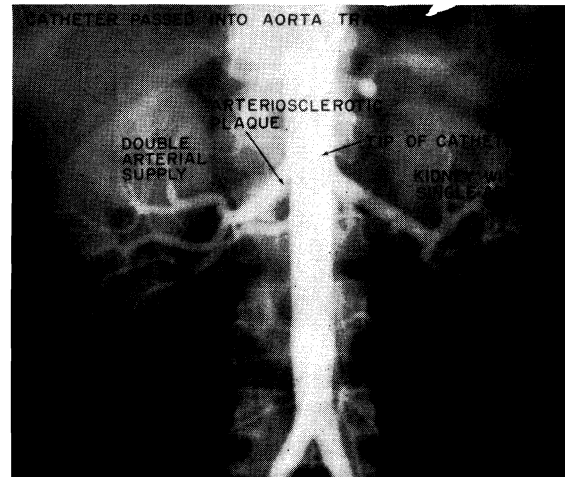
1

A peripheral artery and vein are selected which will admit Teflon cannulas. Any combination of vessels can be suitable either in the upper or lower extremities providing they are in reasonable proximity, and if their sacrifice does not result in vascular insufficiency. Insertion into the respective vessels at some distance from the point of egress of the cannulas from the skin helps prevent sepsis. For dialysis, the arterio-venous shunt is interrupted and the respective limbs attached to the artificial kidney. At all other times, the short connecting tube transmits the high flow which is necessary to prevent clotting.



Pre-operative donor aortography

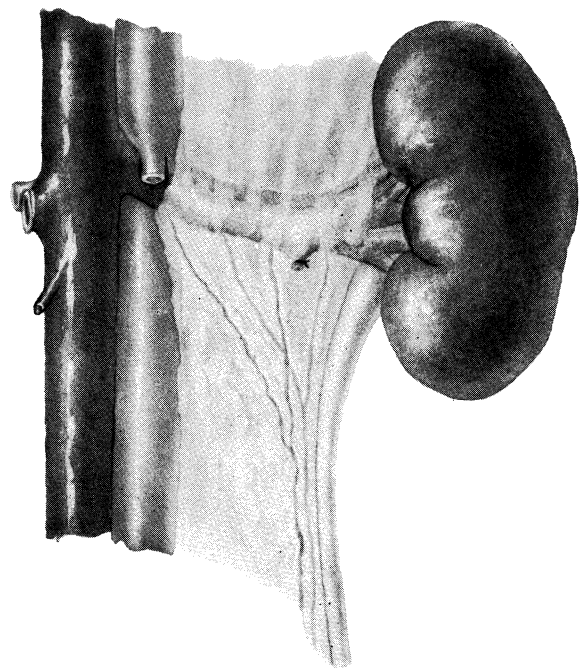
2 When living donors are used, it is determined that the volunteer is in perfect health and has completely normal renal function. If these criteria are met, aortography is performed with the Seldinger technique. A kidney with a multiple arterial supply is usually not used. Although two or more vessels can be re-arterialized, as will subsequently be demonstrated, the ischaemic interval of the homograft is thereby increased. Only if the donor were an identical twin would such a kidney be considered for excision. Aortography also provides protection for the donor. Unsuspected renal arterial lesions have occasionally been encountered in apparently normal volunteers; without this diagnostic aid, the donor might have been left with a defective single kidney.



DONOR OPERATIONS

General objective

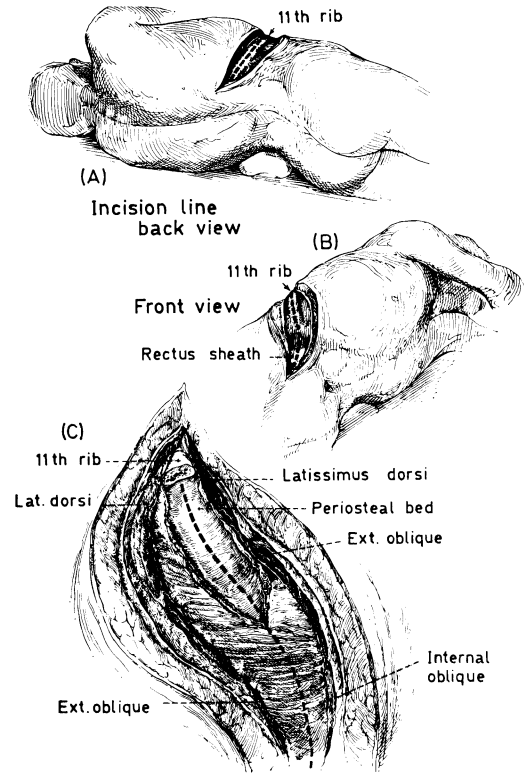
3 The principle of the donor operation is block excision of the kidney. Dissection in the central hilar area is avoided in order to protect the blood supply to the pelvis and upper ureter. This is particularly important if the arterial supply to the pelvis and ureter is multiple in origin as depicted. Generous exposure is needed for this objective as well as to ensure the donor against surgical accident such as loss of control of a renal vessel stump.



4

Position for donor right nephrectomy

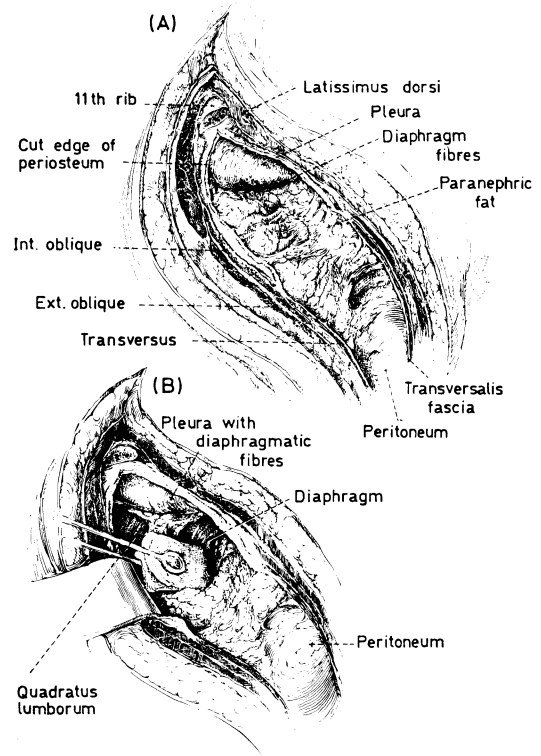
Nephrectomy in cadaveric donors is usually done trans-abdominally through a long mid-line incision. The operation is essentially the same for living donors except that a flank incision is employed, beginning over the 11th rib extending medially to the lateral border of the rectus sheath (A, B). The distal portion of the 11th rib is resected subperiosteally (C) and the lateral abdominal muscles incised, taking care not to enter the peritoneum. Occasionally the pleural space is inadvertently opened but this is not a serious complication if it is recognized.



5

Exposure of right kidney

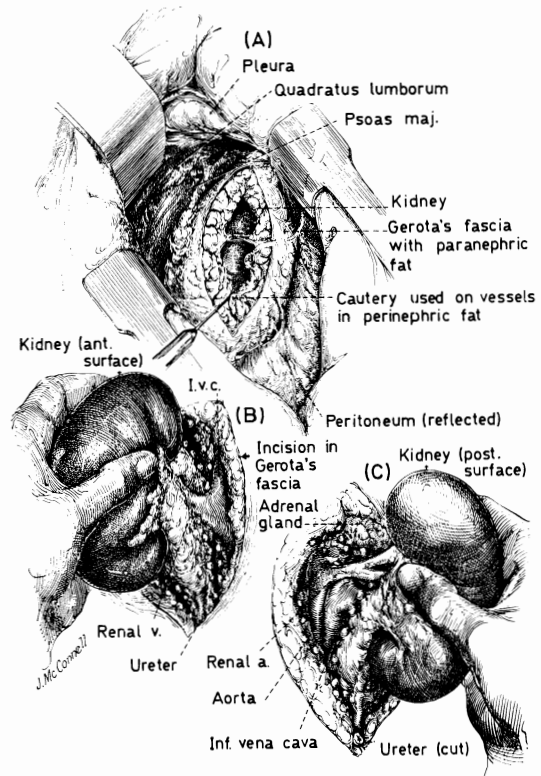
With mobilization of the peritoneum medially the right kidney and covering paranephric fat and Gerota's fascia are exposed (A, B).



6

Extraction of right kidney

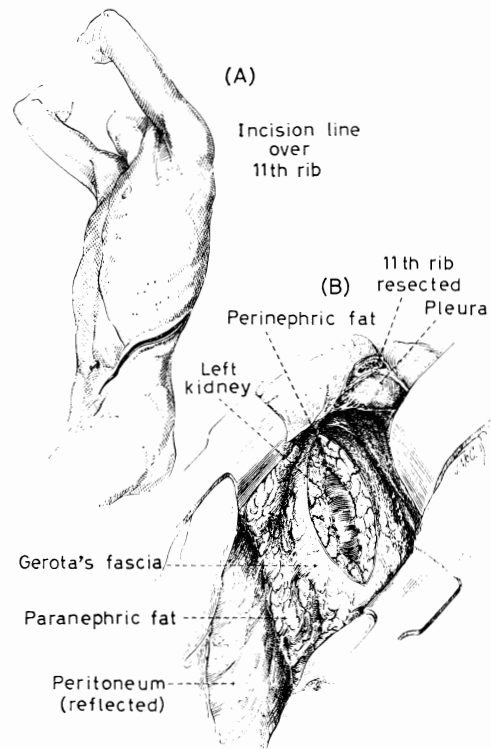
Gerota's fascia is incised in the supero-inferior direction, exposing the perirenal fat and true renal capsule (A). The kidney is extracted from its bed and the right renal vein identified at its origin (B). There are occasionally small tributaries which enter near the junction of the renal vein with the inferior vena cava. These are ligated and divided. The kidney is swept anteriorly and the origin of the renal artery dissected free (C). Except for mobilization of the ureter, the organ is now ready for removal.



7

Approach to left kidney

The preliminary stages of the operation are identical to those on the right (A). On both sides, excessive elevation of the contralateral kidney rest is avoided. Gerota's fascia is incised (B).

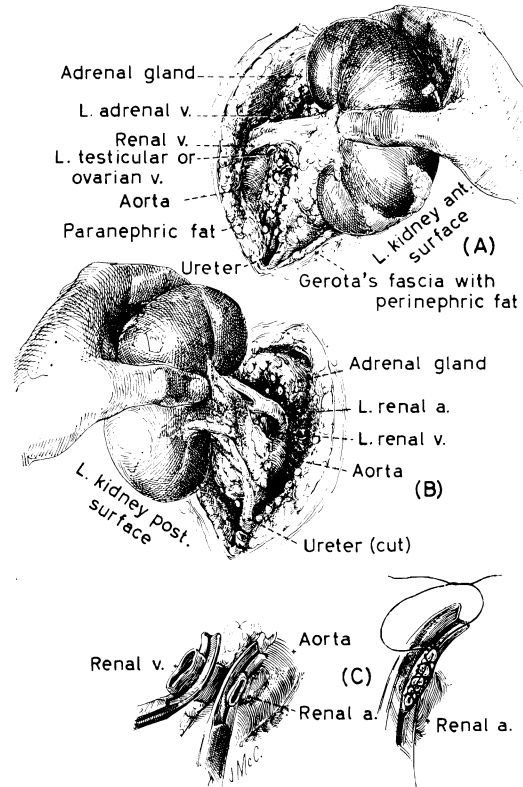


Removal of left kidney

8

The dissection on the left differs from that on the right in that the left renal vein constantly admits the adrenal vein superiorly and the ovarian (or internal spermatic) vein inferiorly. These vessels are ligated and divided (A). The extent of renal vein which must be freed is usually somewhat longer than on the right. In addition, the origin of the left renal artery is easier to free than the right because it is not covered by the vena cava (B). In mobilizing the ureter on either side, care is taken to avoid damaging the blood supply. Ureteric haematomas are prevented by ligating the filaments of tissue which bind the ureter to the posterior body wall.

After excision of the kidney the stumps of the renal artery and vein are closed with two layers of continuous 5/0 vascular silk (B, C). The technique is essentially the same on either the right or left side. After careful checking for haemostasis the wound is closed without drainage with the interrupted fine silk technique. If the pleura has been entered, air is evacuated from the chest during closure by means of tube aspiration carried out in conjunction with the anaesthetist who provides vigorous positive pressure.



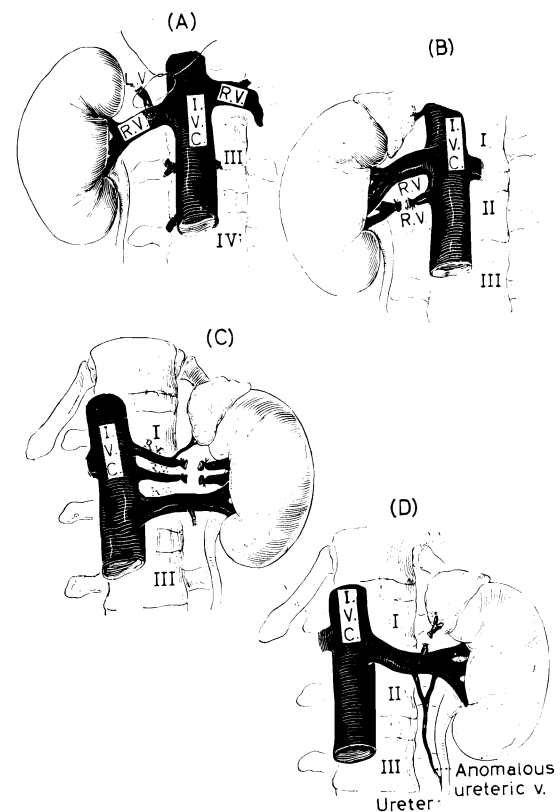
Venous anomalies

9

Venous anomalies are frequently encountered. One of the most common is a posteriorly entering lumbar vein near the junction of the renal vein with the inferior vena cava (A). If the potential presence of such a vessel were not appreciated, it would be possible to avulse it in passing a clamp posteriorly to the renal vein. When encountered, the lumbar vein is ligated and the renal vein transected proximal to this point.

On two occasions an anomalous single ureteric vein has been seen (D), test occlusion of which caused intense cyanosis of the entire ureter. Ligation of such a vein with the impression that it is an ovarian or spermatic vessel could be disastrous.

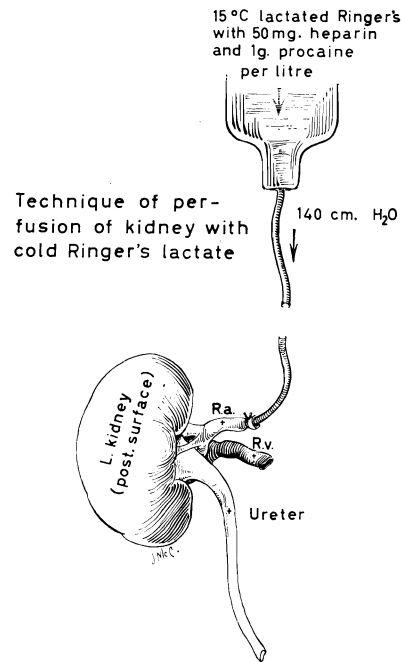
In about 20 per cent of the cases, there is more than one renal vein (B, C). It is usually permissible to ligate the smaller of these vessels since rich intercommunications provide for adequate drainage through a single outflow.



Before ligation, however, the vein or veins to be sacrificed should have test occlusion to be certain that regional cyanosis of the kidney does not result.

10 Perfusion of excised kidney

A smooth-tipped cannula is inserted into the renal artery immediately after extirpation of either a cadaveric or voluntarily donated homograft, and the organ is perfused for several minutes with cold lactated Ringer's solution; 50 mg. of heparin and 1 g. of procaine per litre are added to the solution. The pressure can be controlled either with gravity or with a manometric device. Between 200 and 400 ml. of the solution are used. During perfusion, the organ becomes blanched and bloodless.

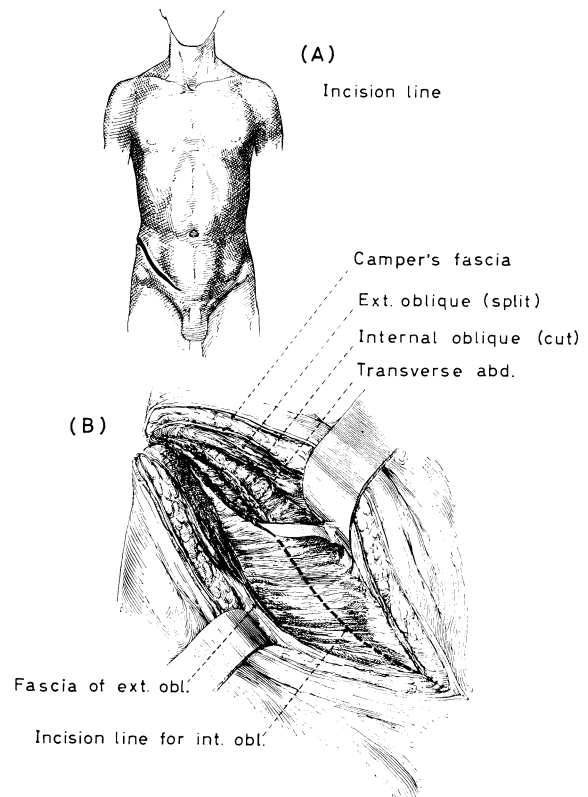


RECIPIENT OPERATIONS

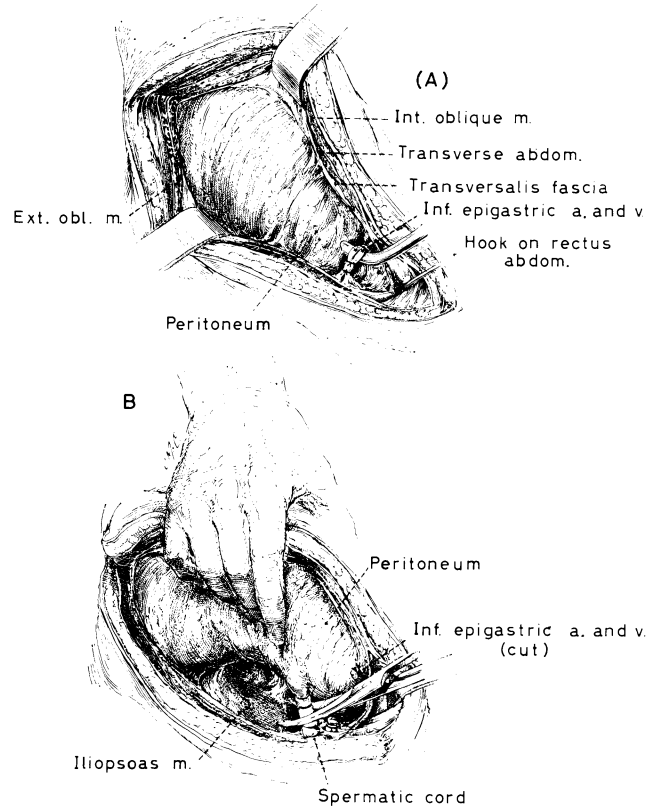
11 Position for patient

The patient is supine. In adults an oblique lower abdominal incision is made (A). If the left kidney of the donor is to be employed, the recipient incision is on the right side; conversely, if the donor right kidney is to be used, the incision is made on the recipient's left. As will be subsequently described, the transfer of the contralateral kidney results in reversal of the normal antero-posterior relations of the renal pedicle.

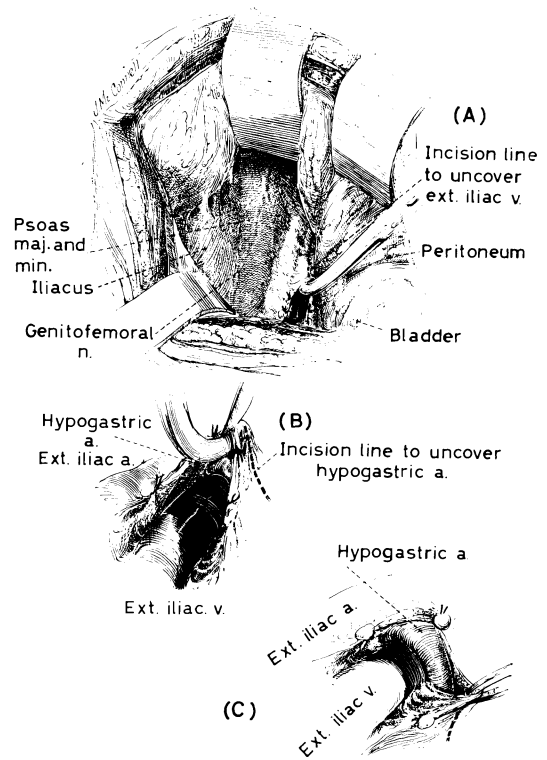
The incision is deepened (B), taking care not to undermine any of the abdominal wall layers. The external oblique muscle and fascia is split in the direction of its fibres. The fused internal oblique and transversalis muscles and the subjacent transversalis fascia are cut as far as possible as a single structure. If the transversalis fascia is not incised, the subsequent dissection will be in a more vascular and therefore less desirable plane.



12 Mobilization of peritoneum
 With sharp and blunt dissection the peritoneum is wiped away from the iliac fossa. The inferior epigastric artery and vein (A) and the spermatic cord (or round ligament) are ligated and divided (B).



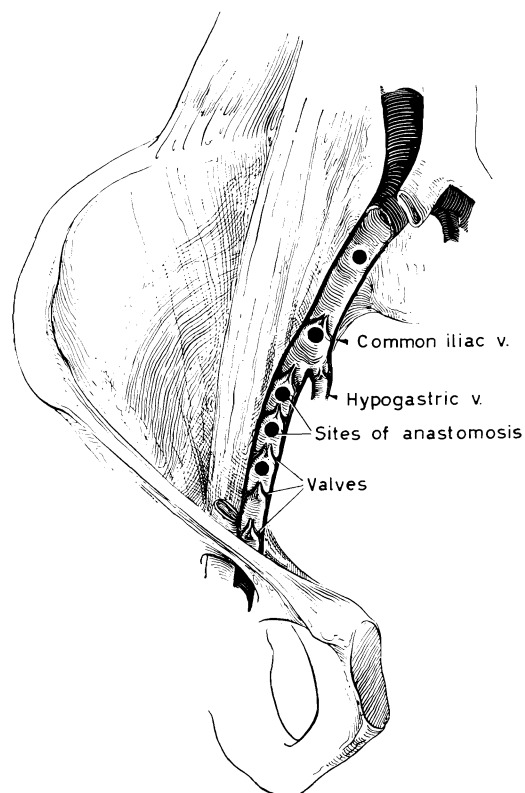
13 Exposure of iliac vessels
 With Deaver retractors the peritoneum and bladder are held superiorly and medially (A). The adventitial-lymphatic veil over the external iliac vein is divided between ligatures to the level of the hypogastric artery (B). Although this filmy tissue is essentially avascular, its ligation helps prevent lymph leaks. Finally, the hypogastric artery is dissected free (C) from its origin to its principal division.



Venous valves

14

In approximately one-third of the cases valves have been encountered at various levels in the iliac veins. These structures can be excised at the time of renal-iliac venous anastomoses if absolutely necessary. In general, however, it is preferable to recognize their presence and to plan the venous anastomosis at a different location.

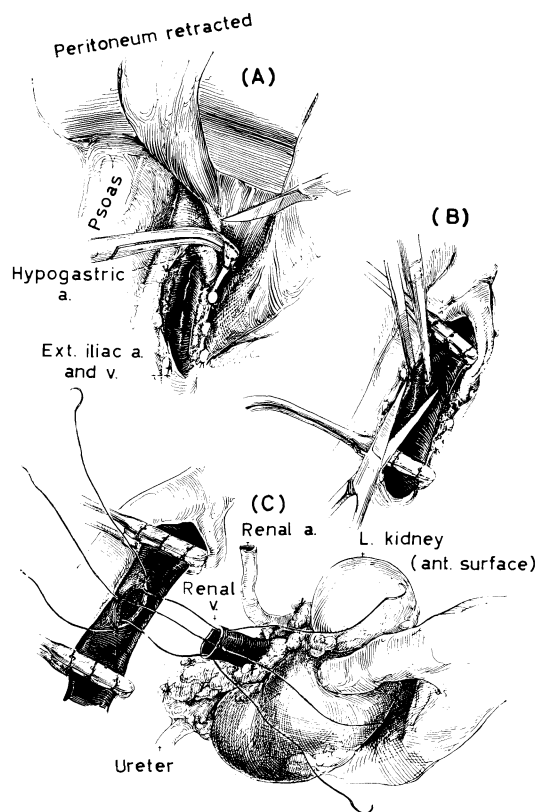


Venous anastomosis

15

When the operative field is ready (A), the donor team begins final preparations for removal of the kidney. In the meantime, a segment of recipient external iliac vein is isolated between two vascular clamps (B). The instruments described by Brown* are ideally suited for this purpose. These non-crushing clamps have tips covered with sponge rubber, protecting the delicate vein wall from injury.

An ellipse is removed from the antero-lateral surface of the external iliac vein after prior consultation with the donor team concerning the appropriate dimension. When the kidney arrives, it is held in the operative field in the same position it formerly occupied in the donor (C); this orients the vein anteriorly. Stay sutures of 5/0 silk on swaged-on needles are placed in the superior, inferior and lateral portions of the iliac vein defect and the corresponding portion of the donor vessel (C).

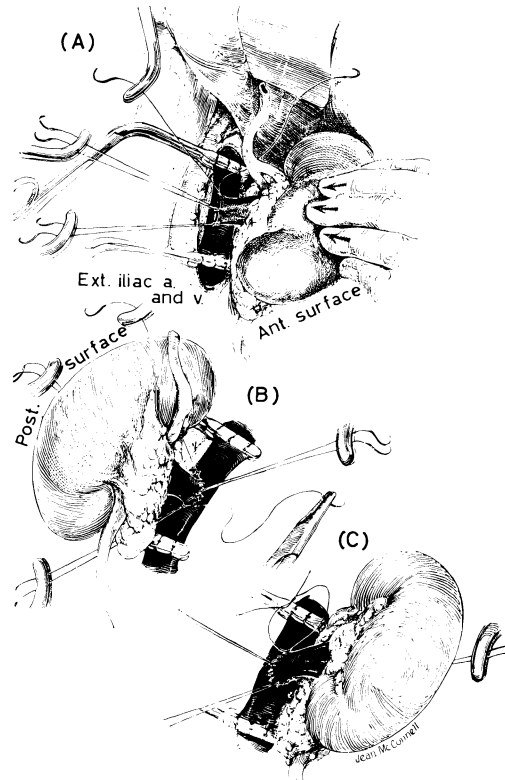


* Edward Weck & Co., Long Island City, New York.

16

Completion of venous anastomosis

One of the end stay sutures is used to form an everting anastomosis. The other stay sutures can be manipulated to provide exposure (A, B). Usually, the entire anastomosis is made with one suture. Alternatively, it may be desirable to interrupt the suture line by tying at the opposite end and continuing with a new needle.



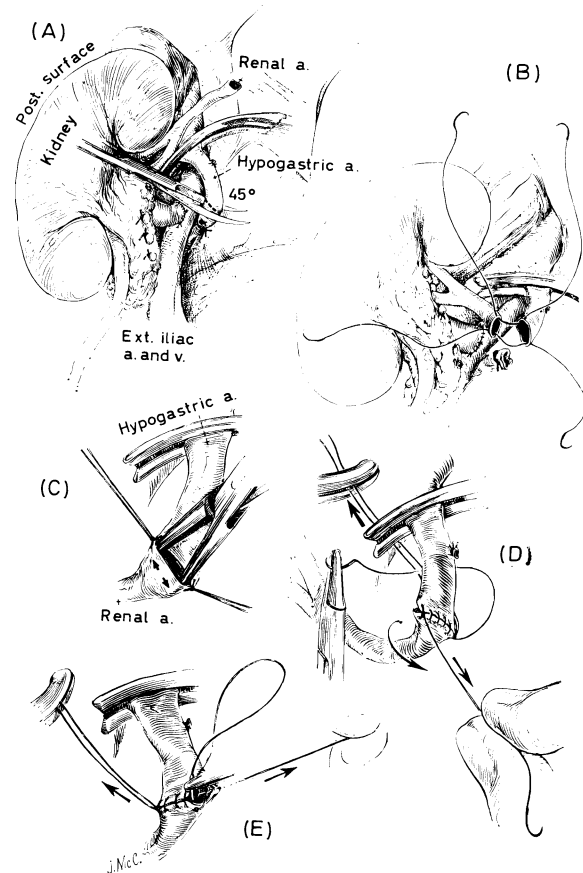
17

Arterial anastomosis

After placing the kidney laterally, the previously dissected hypogastric artery is occluded with a Potts clamp at its origin, tied distally, and transected (A). The vessel is usually cut at an angle (A) in order to obtain a smoother curve at and near the site of anastomosis. Two stay sutures with 6/0 silk are placed between the renal and hypogastric arteries (B).

Often a disparity exists between the size of the two arteries. This can be partially corrected by gentle dilatation of the smaller vessel (C), although this must be done with caution to avoid rupturing the intima. The anastomosis is then performed with a continuous everting technique (D), rotating the vessel to gain access to the posterior wall (E). Because the donor left kidney is transplanted to the right side of the recipient, the ultimate location of the artery is anterior to the renal vein.

The total ischaemic interval for the homograft is almost invariably 30 minutes or less, unless there is some technical complication. Special measures are not necessary during this interval for prevention of clotting either in the occluded iliac vein or in the host arterial system. Thrombosis of these vessels has never been observed in our experience.

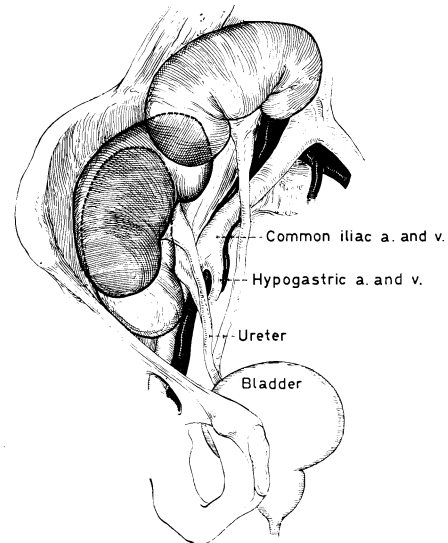


Location of kidney

18

As soon as the vascular anastomoses are completed the blood supply is restored to the kidney, either releasing all clamps simultaneously or allowing an arterial inflow for a few seconds before opening the venous outflow. Vascular suture line leaks must be repaired without re-occluding the circulation; failure to observe this precaution may result in multiple small vessel thrombosis within the homograft.

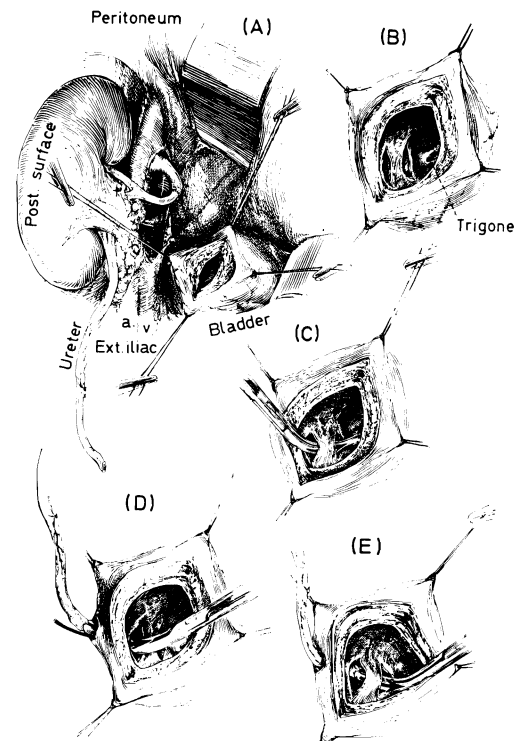
It is important at this time to determine the approximate definitive site of the homograft. Usually the decision is self-evident since the new kidney will spontaneously assume a comfortable location in the retroperitoneal space, the exact place varying widely. However, it is important to check immediately the influence of this position upon both the artery and vein. In some cases, it has been necessary to construct anteriorly located peritoneal pockets in order to prevent kinking of either the artery or vein, or both.



19

Uretero-neocystostomy

Urinary drainage may be provided with uretero-neocystostomy. The supero-lateral surface of the bladder is identified and incised for $1\frac{1}{2}$ - $2\frac{1}{2}$ cm. (A). The interior of the bladder is visualized through this relatively small incision and a site selected for placement of the ureteral tip; this is planned as close to the patient's trigone as possible so that subsequent cystoscopy could be easily performed if necessary. Two small parallel incisions are then made in the bladder mucosa approximately 1 cm. apart (B), the distal of these being the eventual site of the uretero-vesicle anastomosis. The bridge of mucosa separating the two incisions is undermined (C). The homograft ureter is then brought through an oblique tunnel in the vesicle wall (D) and through the submucosal tunnel (E).

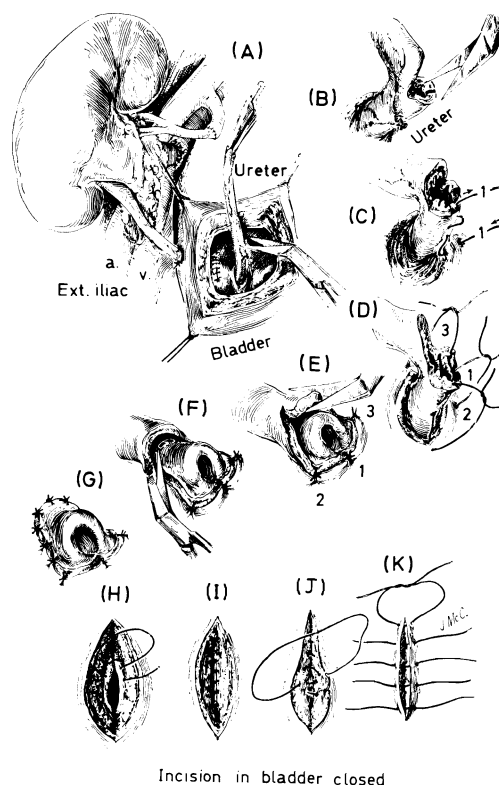


20

Ligation of ureteral arteries

The ureteral arteries are ligated with 6/0 plain catgut near the proposed site of ureteral transection (A). A fish-mouth incision is made (B). Plain catgut sutures of 6/0 are placed around the circumference of the ureteral tip in such a way as to produce eversion (C, D, E). The resulting nipple is made eccentric by leaving a somewhat longer flap on the side opposite the fish mouth (E, F, G).

The bladder is closed with continuous 4/0 chromic catgut to the mucosa and muscularis (H, I, J) and with interrupted 4/0 silk to the superficial layer (K). The use of an everting mucosal suture introduces the slight long-term risk of providing a catgut nidus for stone formation but this is thought to be justified in the interests of obtaining a secure closure without fear of an early urinary leak.

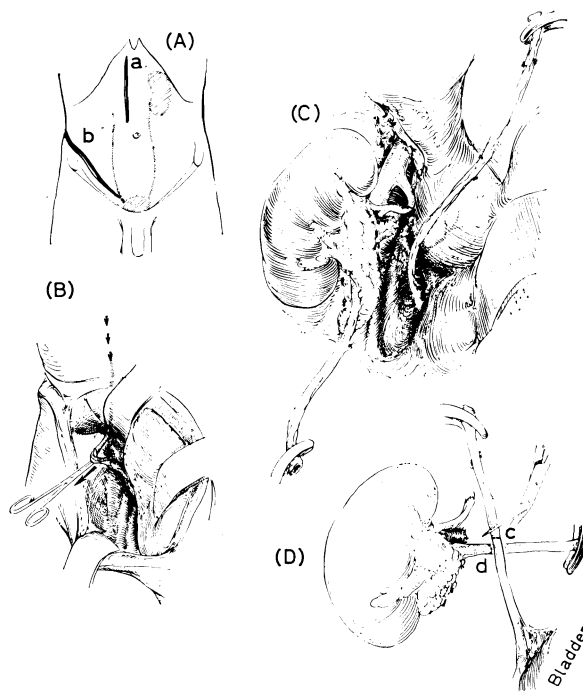


Incision in bladder closed

21

Uretero-ureterostomy

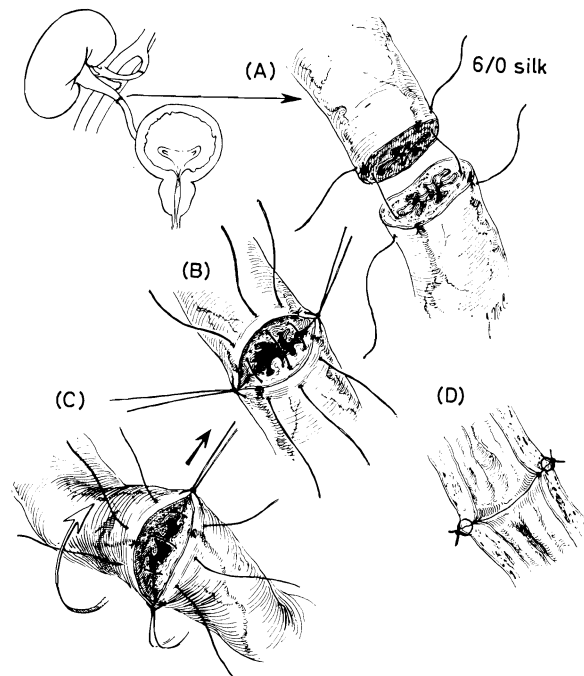
Alternatively, uretero-ureterostomy may be preferred. With this operation the patient's own ipsilateral kidney is removed through a separate abdominal operation and the distal ureter left *in situ* (A). This distal ureter is extracted (B) into the lower abdominal wound and mobilized to within 1-2 in. of its vesicle entry (C). The patient's own ureter and that of the homograft are tailored to the desired length (D).



End-to-end anastomosis

22

An end-to-end anastomosis is performed using 6/0 cardiovascular silk with swaged-on needles. Eight sutures are required. Care is taken to place the needles just outside the mucosa (A, B). A quartering technique is essential to ensure equivalent partition of the circumference of the donor and recipient structures. After completing the front row, the anastomosis is turned to obtain access to the posterior wall (C). With this technique a water-tight anastomosis can be routinely obtained. Because of the extra-mucosal suturing technique there is no silk within the lumen (D); furthermore, through-and-through suture slits which might be the origin of a subsequent urinary fistula are thereby avoided. Each of the two methods has certain advantages. Uretero-ureterostomy is easier to perform and provides a normal uretero-vesicle junction. Furthermore, strictures have not been observed in our experience in more than 35 such operations. However, we have had 8.5 per cent incidence of ureteral fistula. In 2 of these 3 cases a secondary re-anastomosis was curative. A uretero-ureterostomy is apt to be a dangerous operation where urine flow is not promptly observed from the homograft since under these circumstances it is difficult to be sure that a completely water-tight anastomosis is present before wound closure.

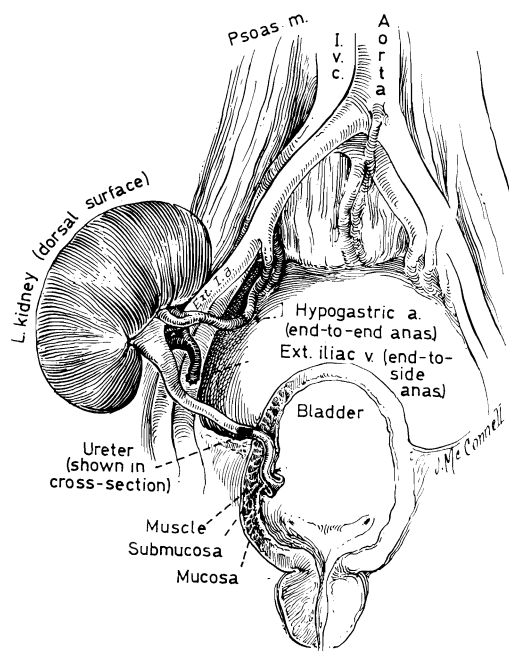


In contrast, urinary fistula rarely occurs with the uretero-neocystostomy. However, we have had a 9 per cent incidence of later stricture formation. Although these strictures were all successfully repaired, the secondary operations were dangerous and difficult. Finally, uretero-neocystostomy provides far less assurance of a physiologically adequate uretero-vesicle junction; reflux is a not uncommon late complication.

Completed transplantation

23

The donor left kidney has been placed in the recipient right iliac fossa, employing a uretero-neocystostomy. Note that the antero-posterior relationships of the renal pedicle are reversed from normal, the pelvis and ureter now being anterior, the renal artery in the middle, and the renal vein posterior. The entire field of operation is extraperitoneal. The wound is closed in layers with fine silk technique. Drains are not used, except when fluid accumulation is anticipated. Should this be the case, a small drain is placed through a separate stab wound below the incision, and gradually extracted during the ensuing week.

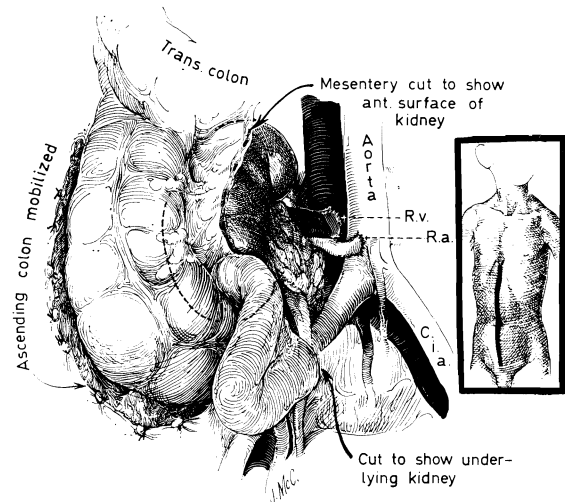


Variant operations

Children

24

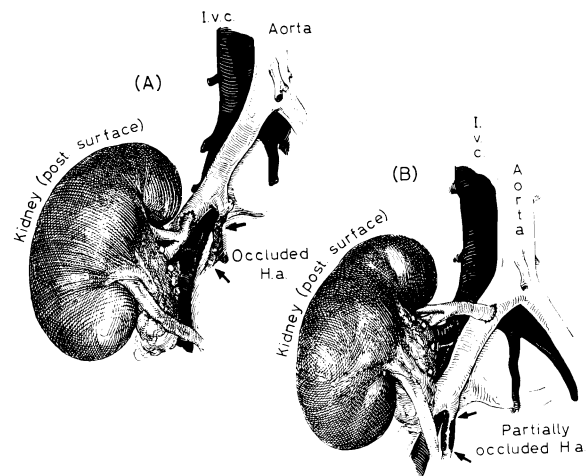
Although the above-described procedures are applicable in more than 90 per cent of cases, deviations from these techniques may be mandatory. In children, for example, the retroperitoneal space is often too small to accommodate an adult kidney. In such cases the operation can be done through a mid-line transperitoneal incision (*see insert*). The ascending colon is reflected towards the left and the kidney placed behind the mesocolon. The renal artery is attached to the side of the terminal aorta or the common iliac artery and the renal vein to the side of the inferior vena cava. Either a donor left or right kidney can be effectively transplanted in this way. Urinary drainage is usually best achieved with ureteroneocystostomy because of the disparity in the size of the donor and recipient ureters.



Adults

25

In older patients the hypogastric artery may be so diseased that it cannot be used. If so, the renal artery can be anastomosed to the side of either the external iliac (A) or the common iliac (B) artery. With the higher location (B) it should be noted that the renal venous anastomosis will be located lateral to the artery and that the renal vein does not pass over the iliac artery. Occasionally this anatomical feature may be exploited, when the donor renal vein is found to be so short that the standard technique is not feasible.



26

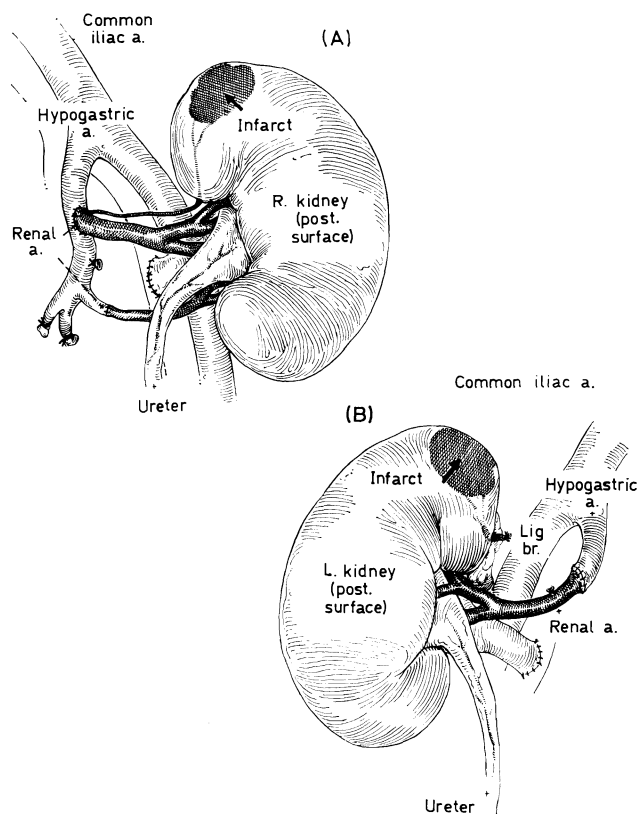
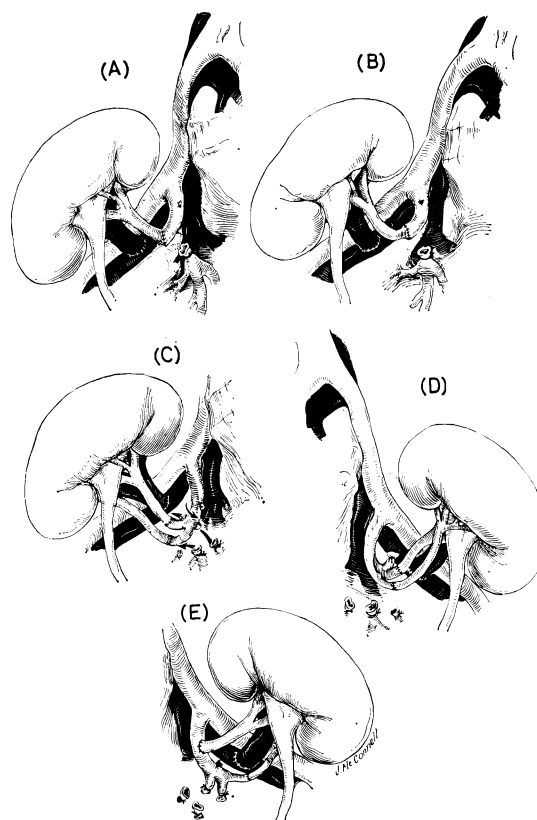
Multiple homograft renal arteries

The usual appearance after anastomosis with a single renal artery is depicted in A and B. Although it is highly desirable to deal with a single artery, this may not always be possible, especially when cadaveric donors are used in which the pattern of the renal blood supply is not known in advance. When two or more renal arteries are present it is easiest to attach these to the terminal branches of the recipient hypogastric artery (C). Normally, there is a terminal bifurcation of the latter vessel into large anterior and posterior branches. One of these vessels must be rotated for an end-to-end anastomosis; the other is oriented directly towards the homograft renal pedicle, facilitating an end-to-end reconstruction.

Occasionally the hypogastric bifurcation into two large trunks is replaced with several smaller ramifications. Here, the largest terminal branches may be used (D). Alternatively one of the renal arteries may be placed into the side of either the hypogastric or external iliac systems and the other attached end-to-end (E). When cadaveric kidneys are used which have a multiple arterial supply, it may be easier to remove a disc of donor aorta from which all of the arteries originate; this patch is sutured into the side of one of the recipient pelvic arteries.

27

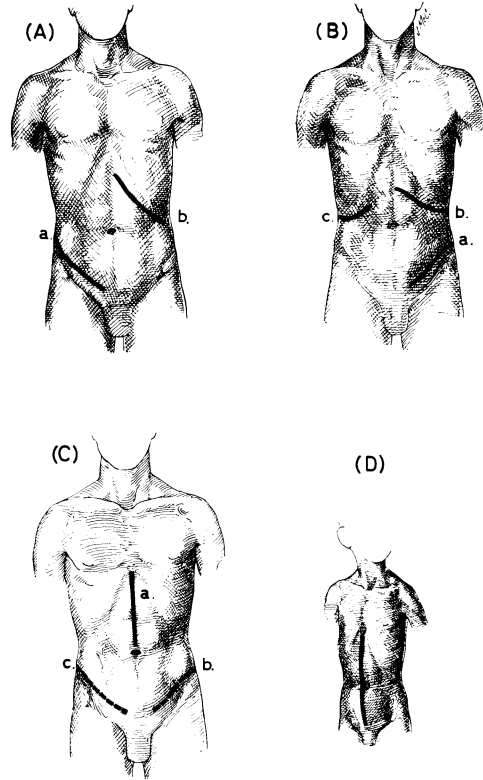
It is mandatory that all arteries to the homograft be reconstructed, since these are end vessels with a discrete area of supply. Failure to do so inevitably results in a regional ischaemic infarct. On five occasions complete revascularization has not been possible either because of thrombosis (A) of a polar branch or because of its accidental ligation (B). These kidneys all functioned, in four instances for a protracted interval, but varying degrees of haematuria were observed in the early post-operative period; in one case this led to obstruction of the ureter with clot, necessitating re-operation. It is possible that such cases will have a late morbidity from persistent renal hypertension.



Auxiliary operations

28 Bilateral recipient nephrectomy with or without splenectomy is usually done at the same time as transplantation or, alternatively, either in advance or at a later date. Various combinations of incisions have been used, the most common being an upper midline incision for the nephrectomies and splenectomy with a lower abdominal incision on either the right or left (C).

29 Through the upper midline incision it is easy to remove both kidneys. An incision is made in the posterior peritoneum (A), and the kidney extracted from its capsule (B). The hilar structures are divided individually. This is particularly important if a uretero-ureterostomy is planned, since the ureter must eventually be drawn into the lower wound. If the ligature around the upper ureter were not restricted to this structure it would be possible to avulse adjacent tissue or vessels when the ureter is pulled down from below.

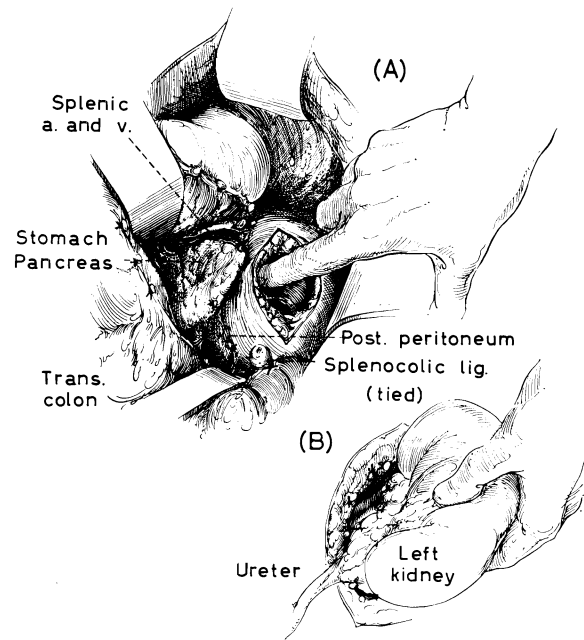


Thymectomy and splenectomy

Both thymectomy and splenectomy have been carried out in an effort to reduce the host immunological potential. The rationale for these operations is theoretical since proof of their efficacy in man has not been established. The techniques employed are standard.

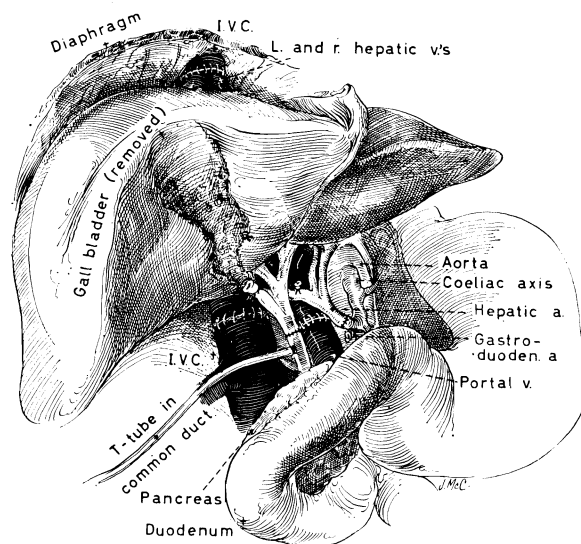
TRANSPLANTATION OF OTHER ORGANS

Clinical attempts have been made to transplant organs other than the kidney during the last 3-4 years. Such efforts have been well supported by laboratory investigation since chronic survival has been obtained in the dog after homotransplantation of each of the organs to be described. Unfortunately, the clinical trials were not successful. Nevertheless, since the feasibility of these procedures has already been established from the animal work, it is quite likely that such operations will ultimately become practical.



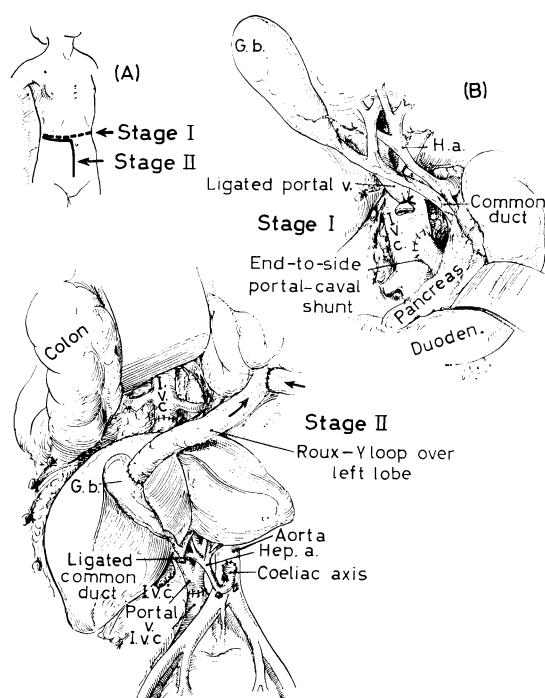
Orthotopic liver transplantation

30 Hepatic homotransplantation can be performed by either of two techniques. With the first, the recipient's own liver is excised and totally replaced. Since the liver is an unpaired organ, the cadaveric donor sources must be employed. As with the kidney, hypothermia is the most practical adjunct to protect against the effects of post-mortem ischaemia. Rapid cooling of the excised liver is possible by perfusion with electrolyte solution in the same way as described for the kidney. Alternatively, the cadaver may be perfused totally or regionally with an extracorporeal heart-lung apparatus to which a heat exchanger is added. With the orthotopic operation the blood supply to the homograft is reconstructed in a completely normal manner and biliary drainage provided with a choledocho-choledochostomy, choledocho-enterostomy or cholecysto-enterostomy. During the actual insertion of the homograft it is necessary to occlude both the vena caval and splanchnic venous beds. Some form of by-pass must be used for at least one of these systems to prevent cardiocirculatory collapse resulting from reduced venous return. Orthotopic transplantation is known to have been carried out in at least 7 patients. There were 2 operative deaths. The other 5 patients lived from 6 to 22 days; all 5 ultimately died of a variety of complications other than rejection.



Auxiliary liver transplantation

31 Another possibility is that of auxiliary hepatic transplantation. With this procedure, the residual function in the patient's own diseased liver is not sacrificed. However, it is necessary to place the homograft in an ectopic site, thereby creating important mechanical problems of space. Moreover, it is usually necessary to revascularize the heterotopic liver in an abnormal way in which the portal inflow is either not provided at all or is derived from a systemic venous source. It is clear from recent physiological studies that such compromise expedients have a more or less deleterious effect upon the function of the homograft. Therefore it is not yet clear if auxiliary transplantation is an operation based upon sound principles of hepatic physiology.

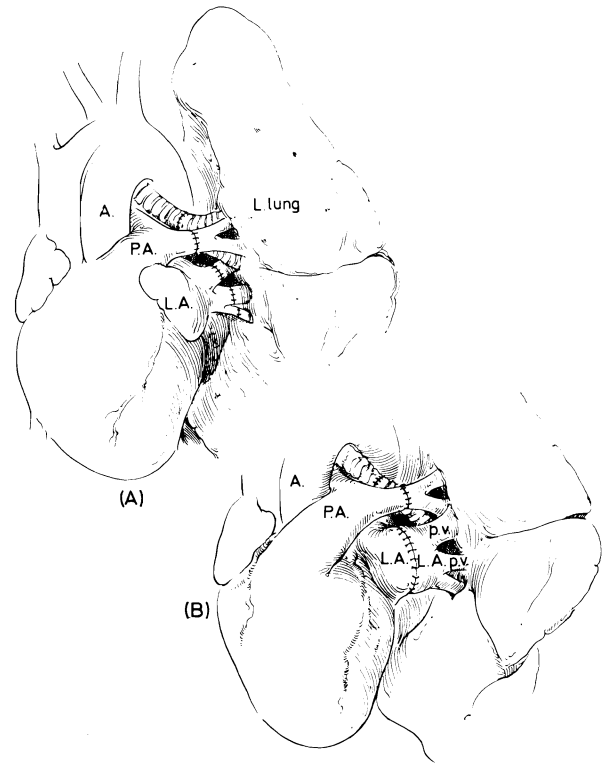


Lung transplantation

32

There have been two attempts at homotransplantation of the lung in man, by Hardy and his colleagues (1963) and by Magovern and Yates (1964). Both patients died within three weeks. The anastomosis of the pulmonary artery is done with standard vascular techniques using 4/0 or 5/0 arterial suture material. The bronchus is reconstituted with interrupted fine 4/0 non-absorbable sutures which are placed just external to the mucosa in order to avoid intraluminal foreign bodies. The pulmonary veins may be attached individually (A). Alternatively, a cuff of the cadaveric donor's atrium may be excised and used to fashion a large anastomosis with the recipient patient's atrium (B).

Two special problems have been observed in the post-operative period of animals. The first is congestive atelectasis which may complicate the course of an animal; function is greatly depressed for the first several weeks. Secondly, there is an additional physiological handicap imposed by denervation and the loss of the Hering-Breuer reflex. Finally, a high incidence of bronchial anastomotic strictures has been reported even with autografts, a finding probably related to the loss of the bronchial arterial supply.

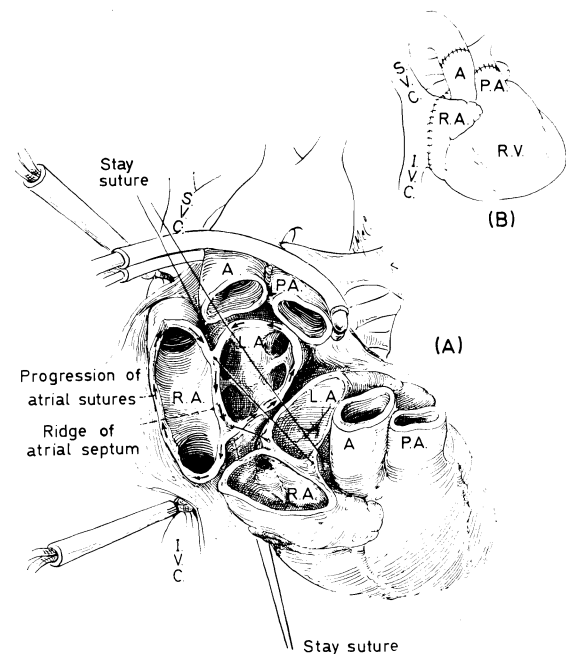


Cardiac transplantation

33

Hearts have been transplanted in animals either as auxiliary organs or by an orthotopic method in which the recipient's own heart is first excised. With the latter procedure cardiopulmonary by-pass is required. Hardy and his colleagues (1964) have attempted one clinical heterotransplant employing a chimpanzee heart; the patient died after an hour.

For experimental orthotopic transplantation the procedure popularized by Lower and Shumway and their colleagues (1961, 1965) has proved to be the most useful. A cuff of recipient right and left atrium is retained and used to anastomose to similar cuffs on the homograft (A). The atria and the inter-atrial septum are attached with a continuous technique, employing 4/0 cardiovascular suture. End-to-end anastomoses of the pulmonary artery and aorta are then carried out with a similar method (B).



Shumway has found that the best method of preservation is immersion of the excised canine heart in iced electrolyte solution. Secondly, a high incidence of serious or even fatal arrhythmias have been noted in dogs after orthotopic heart transplantation, a not surprising finding inasmuch as it is impossible to reconstruct a completely normal conducting system in such experiments.

Other organs

Transplantation of the spleen, various endocrine organs, thymus and brain have been performed either in animals or man, or both, but a description of these various techniques is beyond the scope of this chapter.

SPECIAL POST-OPERATIVE CARE AND COMPLICATIONS

Skilful technical performance is essential for success. However, the most fundamental problems are non-surgical except in the special instance of transplantation between identical twins (isografts). In all other cases, measures must be taken to control rejection. The implications of the necessary anti-rejection therapy are beyond the scope of this chapter and are described in several of the appended references. In substance, the resultant special problems are largely due to the fact that it is necessary to suppress the patient's immunological capacity in order to permit survival of the foreign tissue. In turn, the patient is rendered more susceptible to a variety of septic complications. The agents currently being employed clinically for immunosuppression are azathioprine, prednisone, azaserine, cyclophosphamide, actinomycin-C, total body irradiation and local homograft irradiation.

Early post-operative course

When living donors are used, immediate and gratifying urine excretion by the homograft is almost invariably observed. The resultant massive diuresis, which can be as much as 2,000 ml. per hour, results in dramatic improvement in the patient's condition. However, very accurate fluid and electrolyte replacement is necessary during this time; failure to do so may result in sudden death. The general care of the patient does not differ from that after any other major abdominal operation. Gastric suction is used for the first day or so and alimentation then resumed. The urinary catheter placed prior to operation is usually removed the morning after surgery. If a drain has been employed, it is extracted within 5 or 6 days.

Subsequent post-operative course

Despite continuous immunosuppression with one or more agents, acute homograft rejection is often observed, beginning as early as a few hours to as late as several months after operation. With rejection, renal function secondarily deteriorates. The homograft may become enlarged with tenderness in the transplant wound. The patient who has not been receiving steroid therapy develops fever. Fortunately these adverse events can usually be reversed by intensification of the pre-existing immunosuppressive programme. The risk of death due to drug overdosage and/or secondary sepsis is greatest at this time. If the patient can be successfully managed during this critical interval, the stringency of the requisite immunosuppressive therapy can usually be subsequently relaxed.

The medical management of the patient after renal homotransplantation and the evolution of the ultimate course are special subjects which must be reviewed in detail before undertaking an operation of this sort.

Prognosis

Homotransplantation between identical twins (isografts) is almost invariably successful. When familial living donors other than identical twins are used, 2 out of every 3 recipient patients in our experience have survived for at least 2 years. Only 2 deaths have occurred after 7 months in a group of 31 patients followed for 2-3½ years. The therapeutic benefit with paternal, sibling or even less distantly related donors is therefore substantial.

With non-related kidneys obtained either from living or cadaveric donor sources the survival is less encouraging, due principally to the necessity for generally more prolonged immunosuppression. In our experience only 44 per cent of such patients have lived for as long as a year. In addition, late deaths, occurring between 1 and 2 years, have frequently been observed. However, the fact that chronic survival has been obtained after transplantation of both related and non-related kidneys emphasizes the probability that this form of therapy will almost certainly have an important and increasing place in the medical armamentarium of the future.

[Grateful acknowledgment is made to the following journals and publishers for their permission to re-utilize the illustrations in this Chapter on Whole Organ Transplantation: Archives of Surgery; Annals of Surgery; Journal of the American Medical Association; Surgery; Gynecology and Obstetrics; and the W. B. Saunders Company.]

References

- Blumenstock, D. A., Collins, J. A., Hechtman, H. E., Hosbein, D. J., Lempert, N., Thomas, E. D., and Ferrebec, J. W. (1964). "Lung Transplantation in the Dog." *Ann. N.Y. Acad. Sci.*, **120**, 677.
- Hamburger, J., Crosnier, J., Dormont, J., Reveilland, R.-J., Hors, J.-H., and Alsina, J. (1965). "Homotransplantation rénale humaine. Resultats personnels chez 52 malades. I. Techniques et resultats d'ensemble. II. Histoire naturelle du greffon dans les cas de tolerance prolongée. III. Complications extra-rénales—Conclusions d'ensemble." *Presse Med.*, **73**, 2793, 2873 and 2911.
- Hardy, J. D., Webb, W. R., Dalton, M. L., and Walker, G. R. (1963). "Lung Homotransplantation in Man." *J. Am. med. Ass.*, **186**, 1065.
- Chavez, C. M., Kurrus, F. D., Neely, W. A., Eraslan, S., Turner, M. D., Fabian, L. W., and Labeck, T. D. (1964). "Heart Transplantation in Man." *J. Am. med. Ass.*, **188**, 1132.
- Hume, D. M., Lee, H. M., Williams, G. M., Wolf, J. S., Prout, G. R., Slapak, M., Kauffman, H. M., Jr., and Cleveland, R. J. (1966). "The Comparative Results of Cadaver and Related Donor Renal Homografts in Man, and the Immunologic Implications of the Outcome of Second and Paired Transplants." Paper presented at the Annual Meeting of the American Surgical Association, Boca Raton, Florida, March 23, 1966.
- Lower, R. R., Stofor, R., and Shumway, N. E. (1961). "Homovital Transplantation of Heart." *J. thorac. cardiovasc. Surg.*, **41**, 197.
- Dong, E., Jr., and Shumway, N. E. (1965). "Long-term Survival of Cardiac Homografts." *Surgery*, **58**, 110.
- Magovern, G. J., and Yates, A. J. (1964). "Human Homotransplantation of Left Lung: Report of a Case." *Ann. N.Y. Acad. Sci.*, **120**, 710.
- Marchioro, T. L., Huntley, R. T., Waddell, W. R., and Starzl, T. E. (1963). "The Use of Extracorporeal Perfusion for Obtaining Postmortem Grafts." *Surgery*, **54**, 900.
- Porter, K. A., Dickinson, T. C., Faris, T. D., and Starzl, T. E. (1965). "Physiologic Requirements for Auxiliary Liver Homotransplantation." *Surgery Gynec. Obstet.*, **121**, 17.
- Murray, J. E., and Harrison, J. H. (1963). "Management of 50 Patients with Kidney Transplants Including 18 Pairs of Twins." *Am. J. Surg.*, **105**, 205.
- Starzl, T. E. (1964). *Experience in Renal Transplantation*. Philadelphia; Saunders.
- Marchioro, T. L., and Porter, K. A. (1966). "Progress in Homotransplantation of the Liver." In *Advances in Surgery*. Ed. by Claude Welch. Chicago; Year Book Medical Publishers.
- — Terasaki, P. I., Porter, K. A., Faris, T. D., Herrmann, T. J., Vredevoe, D. L., Hutt, M. P., Ogden, D. A., and Waddell, W. R. (1965). "Chronic Survival after Human Renal Homotransplantation." *Ann. Surg.*, **162**, 749.

©
Butterworth & Co. (Publishers) Ltd.
1968

Printed in Great Britain by The Chapel River Press, Andover, Hants