

# Transplantation Pneumonia

David Rifkind, PhD, MD, Thomas E. Starzl, MD, PhD, Thomas L. Marchioro, MD,  
William R. Waddell, MD, David T. Rowlands, Jr., MD, and Rolla B. Hill, Jr., MD, Denver

A clinically distinct pneumonitis occurred in six renal transplant recipients receiving azathioprine and prednisone immunosuppressive therapy. The patients ranged in age from 3 to 20 years. The onset was 42 to 102 days postoperatively, coinciding with decrease in prednisone dosage below approximately 1 mg per kilogram of body weight per day. Mild nonproductive cough, fever, and cyanosis were present. Chest x-rays demonstrated extensive hazy to nodular infiltrates usually involving both hila and lower lung fields. Cold agglutinins were present in five patients. Pulmonary function studies demonstrated an alveolar capillary block. The duration of illness was 12 to 34 days and was not influenced by antibiotic therapy. Autopsy of the single case in which death occurred revealed *Pneumocystis carinii* pneumonia and disseminated cytomegalic inclusion-body disease.

**T**HE HIGH INCIDENCE and fulminant course of infectious diseases in renal transplantation patients receiving immunosuppressive therapy has recently been reported.<sup>1,2</sup> Such complications contributed to 14 of the 17 deaths which have occurred among the first 42 patients treated at this center by means of renal transplantation from normal donors. Pneumonia of bacterial or fungal etiology occurred in six of the 42 patients following surgery and proved fatal in five.

In addition, six of the 42 patients developed a clinically distinct and characteristic pneumonic process which was fatal in one. In this communication the clinical and laboratory features of the pneumonias in this latter group will be described and the several possible etiological factors will be discussed.

## Composite Description

**Age and Sex Distribution.**—The pneumonic processes showed a marked predilection for the younger age group. The six cases occurred among the 13 patients in the series who were less than 21 years

of age. In contrast, no cases occurred among the 29 patients aged 21 years or more. Three male and three female patients were affected.

**Symptoms.**—Cough was a presenting feature in five of the six patients. It was mild in four patients and moderately severe in one. In the latter patient, cough produced small amounts of white mucoid-foamy sputum without blood. A mild pharyngitis was present in two patients. There were no instances of chills or pleuritic chest pain.

**Physical Findings.**—All patients demonstrated fever with this illness; the highest temperature recorded in each case being from 39 C to 41 C (102.2-105.8 F). The pulse rate was elevated, but not out of proportion to the degree of hyperpyrexia. Cyanosis was present in five of the cases and was severe in four. The auscultatory findings in the chest were remarkably few considering the marked changes seen by x-ray examination. In four patients the chest was completely clear; in one there were a few scattered rhonchi, and in another the breath sounds were slightly decreased. Although in one patient minimal enlargement of the liver occurred, in no instance was right-sided heart failure clinically apparent.

**Course (Table 1).**—The pulmonary disease developed in these patients at a mean of 82.5 days after transplantation (range, 42 to 102 days). The onset was suggestive of a mild, upper respiratory illness. The signs and symptoms progressed in severity for a variable period of time, and in five cases recovery occurred in a mean time of 20 days (range, 12 to 34 days). In case 2 the illness was fatal and death occurred on the 12th day of pneumonia.

**Relationship to Steroid Therapy.**—These pneumonias all appeared in a characteristic relationship to the daily dosage of prednisone administered (Fig 1). The disease uniformly became manifest

Table 1.—Chronology of Pneumonias and Relation to Prednisone Dosage

Case No.	Onset, Days After		Duration of Pneumonia, Days	Prednisone Dosage at Onset of Pneumonia	
	Transplant	Starting Prednisone		Mg/Day	Mg/Kg/Day
1	52	33	22	45	1.05
2	85	76	12	45	0.80
3	102	101	34	30	1.20
4	80	73	13	30	0.55
5	42	41	12	20	0.97
6	90	85	20	20	0.80
Mean	82.5	74.5	20*	30	0.89

\*Case 2 not included.

From the departments of medicine, surgery, and pathology of the University of Colorado Medical Center and the Veterans Administration Hospital.

when the dose of prednisone was decreased to approximately 1 mg per kilogram of body weight per day (mean, 0.89; range, 0.55 to 1.05 mg/kg/day). In contrast, the onset varied from 33 to 101 days after the initiation of such therapy. The etiological significance of this feature will be discussed below.

**Chest X-Rays (Fig 2).**—The chest x-ray findings were moderate to advanced in five of the patients and minimal in one. These included bilateral hazy infiltration at the hila or in one lower lung field. With progression, the lower and then middle lung fields became involved bilaterally and only in the patient who died was there spread to the apices. In the areas of involvement, confluent nodular densities appeared which were indistinct in outline and varied in size from less than one to several centimeters in diameter. There was no evidence of pleural fluid or thickening, lobar consolidation, or cavitation.

**Laboratory Studies (Table 2).**—The white blood count ranged from 3,100 to 16,200/cu mm. While these values were influenced by the immunosuppressive drug therapy as well as the pneumonic process, they do indicate that the infections were not primarily the result of profound granulocytopenia, a feature seen not infrequently in bacterial infections among renal transplantation patients.<sup>1,2</sup>

Cold-agglutinin titers were detected in five of the six patients—in high titer in two and in moderate titer in two. The agglutination in all cases was reversed by incubation at room temperature. In case 4, the titer of 1:1,024 had fallen to 1:256 by 17 days later, while in case 1, the titer of 1:2,024 had fallen to 1:16 at 63 days later. In three patients, two of whom had significant cold-agglutinin titers, no Eaton agent PPO antibody was detected by the complement fixation test in either the acute or convalescent serum specimens.

Heterophilic antibodies were present in case 4. The presumptive titer was 1:896 and the antibodies were completely absorbed with beef but not guinea pig cells. The absorption pattern is that seen in infectious mononucleosis. This patient also had a markedly elevated cold-agglutinin titer. Heterophile titers were detectable but were not significantly elevated in the other five patients.

Lupus erythematosus (LE) preparations were negative in all patients; however, tart cells were noted in two cases. Rheumatoid factor, as tested by the latex flocculation test, was found in one of the two patients tested. The serum  $\gamma$ -globulin concentrations were slightly elevated in three of five patients; the erythrocyte sedimentation rate (ESR) was normal in the two patients tested. The serum mucoprotein concentration was elevated in case 6.

There was no evidence of impairment of renal function resulting from the pneumonias as measured by serial creatinine clearance rates.

**Pulmonary Function Studies (Table 3).**—Studies of pulmonary function were performed in three

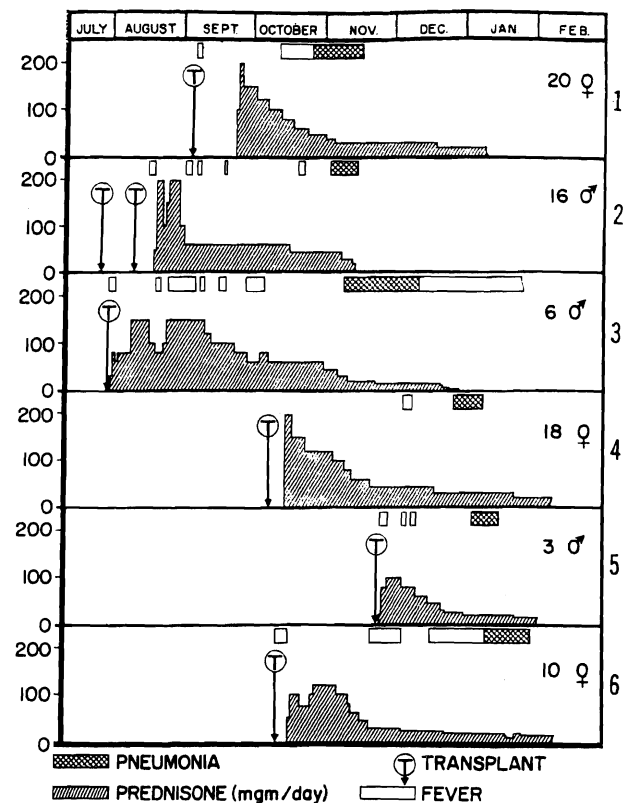


Fig 1.—Relationship between daily dose of prednisone and onset of pneumonia. In each case, pneumonias appeared when prednisone was decreased below 1 mg/kg/day.

patients during the course of the course of the pneumonia. These showed marked arterial oxygen desaturation in all three cases; two of these patients improved with oxygen administration. The arterial carbon dioxide content was normal in the three cases. The diffusion capacity of carbon monoxide was low in the single patient in whom this function was measured. These data suggest that the physiological result of the pulmonary disease was primarily an alveolar-capillary block.

**Bacteriological Cultures.**—Pneumococci were present in small to moderate numbers in cultures of throat swabs from five of the six patients and in the sputum of one of the three patients in whom a suitable specimen was obtained. In contrast, pneumococci were not obtained from the nasopharynx of the patient who died; however, two colonies of this organism, as well as  $\alpha$ - and  $\gamma$ -hemolytic streptococci, were cultured from the lung

Fig 2 (Case 6).—Chest x-ray demonstrating diffuse and nodular infiltrates spreading bilaterally from the hila.



Table 2.—Laboratory Data

Case No.	WBC per cu mm	Cold Agglutinin	Eaton Agent a Complement Fixation	Heterophile	LE Preparation	Rheumatoid Factor	$\gamma$ -Globulin, Gm/100 cc	ESR mm/hr
1	4,500	1:2,048	<8	1:7	Tart cells	....	2.5	....
2	8,000	1:64	<8	1:14	Tart cells	....	2.0	....
3	3,000	1:4	<8	1:7	....	Negative	1.1	....
4	14,000	1:1,024	....	1:896*	Negative	Positive	2.0	....
5	13,400	0	....	1:14	Negative	....	0.7	12
6	16,200	1:16	....	1:28	Negative	....	....	13

\*Absorbed with guinea pig cells = 448, absorbed with beef cells = <7.

at autopsy. The absence of pneumococcus in the sputum of two of three patients tested, its lack of numerical predominance in cultures of the nasopharynx, and the lack of clinical response to antibiotics suggest that this organism was not etiologically related to the pneumonias. In three cases attempts to isolate Eaton agent PPLO from the nasopharynx by the method of Chanock et al<sup>3</sup> were negative. In five of the six patients, culture-confirmed oral moniliasis was present at the time of onset of pneumonia.

**Therapy.**—Three of the patients, including the one who died, were treated with systemic antibiotics. The antibiotics used were penicillin G, sodium methicillin, tetracycline, and chloramphenicol. The clinical course of patients so treated was not significantly different from those receiving no antibiotics.

Four of the six patients received oxygen by nasal catheter which resulted in clinical improvement in cyanosis and tachypnea. None of the patients were digitalized. Mucolytic agents were not employed. Tracheostomy with assisted mechanical respiration was used terminally in the patient who died.

### Report of Cases

Case 6 represents the typical course of this disease in which resolution occurred with only supportive care. Case 2 describes the course of the single patient in this series who died.

**CASE 6.**—A 10-year-old white girl with chronic glomerulonephritis underwent bilateral nephrectomy, splenectomy, and renal homotransplantation from her mother on Nov 11, 1963. Both mother and daughter had type O, Rh-positive blood. Treatment with azathioprine was begun seven days preoperatively. Prednisone was begun on the fifth postoperative day, increased in dosage to 120 mg daily, and then gradually decreased. The patient's postoperative course was complicated by intestinal obstruction requiring lysis of adhesions on the 28th day. This was followed by an esophageal moniliasis which improved with oral nystatin therapy.

The patient was intermittently febrile and on the 90th day a nonproductive cough appeared. The prednisone dosage was 20 mg daily. The temperature was 40 C (104 F) and the respiratory rate, 40 per minute. Thrush was present on the tongue and soft palate. There was moderate cyanosis and the lungs were clear. A throat culture revealed *Diplo-*

*coccus pneumoniae*, although a sputum culture showed no pathogens. The white blood cell count was 16,200/cu mm. A chest x-ray revealed bilateral diffuse and patchy infiltrates throughout both lung fields.

Only oxygen and supportive care were given, and the patient improved. During the course of improvement, prednisone dosage was decreased abruptly from 20 to 10 mg daily because of the appearance of severe gastrointestinal bleeding. With this reduction, however, there was a recurrence of cyanosis and tachypnea requiring restoration of the previous prednisone dosage. There was a rapid response to the readjustment of steroid dosage and the pneumonia cleared by the 109th day.

**CASE 2.**—A 16-year-old white boy (blood type A, Rh positive) with chronic glomerulonephritis underwent bilateral nephrectomy, splenectomy, and an unsuccessful renal homotransplantation from his mother (type O, Rh positive) on July 26, 1963. The kidney was removed immediately. On Aug 9 a successful transplantation from an unrelated donor with type O, Rh-positive blood was performed. Azathioprine had been started nine days prior to the first procedure and continued from the day of successful transplantation. Prednisone, 200 mg daily, was begun on the ninth postoperative day and the dose gradually tapered.

On the 85th day fever and cough productive of small amounts of whitish-yellow sputum developed. The prednisone dosage was 45 mg daily. The temperature was 39.3 C (102.7 F) and the respiratory rate, 36 per minute. Moniliasis of the buccal mucosa was present. The patient was cyanotic and the lungs were clear. The white blood cell count was 8,000/cu mm. A chest x-ray showed diffuse reticular and nodular infiltrates primarily in the right lung field. A sputum culture showed only normal flora. Penicillin G, sodium methicillin, and chloramphenicol were given and, during the course of the illness, the steroids were decreased from 45 to 20 mg daily. The pulmonary lesions progressed; cyanosis, fever, and dyspnea became more marked, and the patient died of respiratory insufficiency on the 97th day.

At autopsy the lungs were heavy, red-purple in color, and meaty in consistency. Microscopically, the septal lining cells were hypertrophic. Minimal lymphocytic infiltration and a few giant cells were present in the interstitium. The alveoli were filled with a pink-stained foamy proteinaceous material containing many cysts of *Pneumocystis carinii*. Intranuclear inclusions showing primarily basophilia but with variable degrees of associated eosinophilia were present in swollen alveolar cells, a few of which also contained cytoplasmic inclusions (Fig 3). In addition, the inclusions were found in the cells of the salivary and parathyroid glands, lymph nodes, pancreas, and Brunner's glands in the gastrointestinal tract.

### Comment

It should be emphasized that, while all six cases presented here form a clinically homogeneous group, an etiological diagnosis has been established in only the single fatal example. In this instance, *Pn carinii* and cells with cytomegalic inclusion bodies were identified. *Pn carinii* is currently believed by most investigators to be a protozoan parasite.<sup>4</sup> The organism is found in the lungs of man and a variety of animals in the latent or subclinical state and is associated with interstitial plasma cell pneumonia, a syndrome which occurs most frequently in the premature or marantic infant. Children and adults with agammaglobulinemia, lymphomas, or leukemias, and those receiving cytotoxic drugs, antibiotics, or corticosteroids

may also be affected. The incubation period is four to eight weeks; the course, days to weeks; and the fatality rate, 20% to 50%. The clinical syndrome is characterized by cyanosis, tachypnea, low-grade fever, and a marked disparity between the minimal physical and striking x-ray findings in the chest. The latter are those of perihilar haziness which spreads, becomes granular, and then coalesces to form irregular indistinct nodules.<sup>5</sup>

The characteristic pathological findings of interstitial plasma cell pneumonia are primarily those of a mononuclear interstitial infiltrate and a foamy eosinophilic alveolar exudate packed with cysts of *Pn carinii*. Giemsa-stained preparations reveal that the cysts contain up to eight bodies of approximately 1 $\mu$  in diameter.<sup>6</sup> Although the cysts are well stained with methenamine silver, the internal structure cannot be seen by this method.

The diagnosis of *Pneumocystis* pneumonia is usually made postmortem. However, in outbreaks of this disease, such as occasionally occur in nurseries, nonfatal infections can be recognized. An instance in which the organism was demonstrated in stained sputum smears prior to death has been reported.<sup>7</sup> A complement fixation test using lung extract from fatalities has been employed in Europe but has yet to be evaluated in this country.<sup>4</sup>

In light of the laboratory findings reported here, it is of interest that ten of 66 cases of *Pneumocystis* pneumonia tested by Barta et al demonstrated cold-agglutinin titers of 1:2,048 or greater.<sup>8</sup> While this nonspecific serologic finding is a characteristic of Eaton agent PPL0 primary atypical pneumonia, no antibody response to this agent was found in three cases tested, nor could the organism be isolated in the three cases in which this was attempted.

Kossel reported 13 cases of *Pneumocystis* pneumonia in children receiving corticosteroids for a variety of severe illnesses including leukemias and lymphomas.<sup>9</sup> The pneumonias in these cases occurred 50 to 90 days after steroid therapy was begun. The author emphasized the appearance of these infections, not at the time of maximal steroid dosage, but rather at a time when the steroid dosage had been decreased or even withdrawn. The reason for the relationship between steroid withdrawal and *Pneumocystis* pneumonia is unknown. It may merely indicate that fairly prolonged steroid therapy is required for susceptibility to develop. Alternatively, the infection may occur relatively early during high-dosage steroid administration but the symptoms are masked by such therapy and become manifest only when the dosage of steroids has been sufficiently reduced. There is some support for this hypothesis in reports of temporary remission associated with steroid therapy of *Pneumocystis* pneumonia in premature infants. Also, the increase in respiratory symptoms and cyanosis noted in case 6 when steroids were sharply withdrawn and the subsequent amelioration of

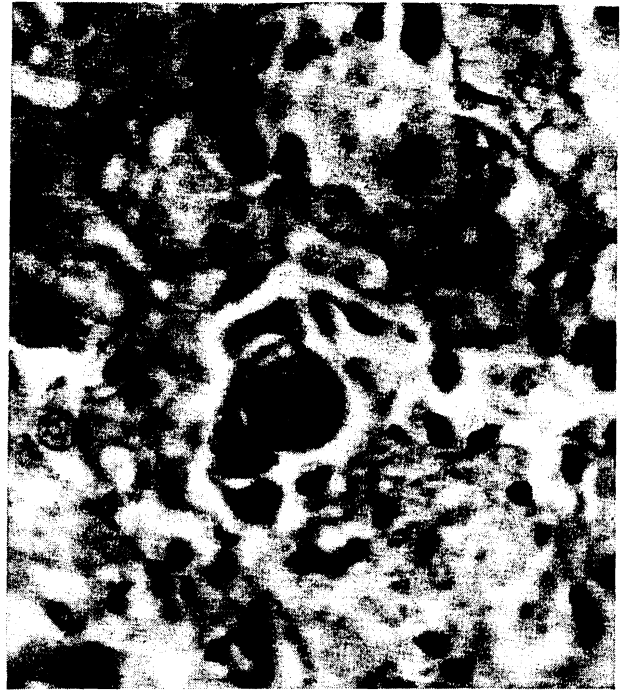

Fig 3 (Case 2).—Photomicrograph of lung section. Intranuclear inclusions are seen within the enlarged alveolar septal cells (x 480).

these symptoms following restoration of the previous prednisone dosage could be explained on the same basis.

Although no drug has been shown to be curative in *Pneumocystis* pneumonia, beneficial effects have been reported with several antiprotozoal agents including pamaquine naphthoate, quinacrine hydrochloride, and pentamidine isethionate.<sup>10</sup> Antibiotics are ineffective and can augment the activation of *Pneumocystis* infection by steroids in rabbits.<sup>11</sup>

The intranuclear and intracytoplasmic inclusion bodies seen in the lungs as well as in the lymph nodes, pancreas, gastrointestinal tract, and parathyroid and salivary glands in case 2 are believed on morphologic grounds to represent disseminated cytomegalic inclusion-body disease (salivary gland virus, cytomegalovirus). This viral agent has been found in the salivary glands of 10% of unselected infants at autopsy but has not been noted in this location in patients past the age of 16 years.<sup>12</sup> Serologic data, however, suggest that the incidence of infection increases with age so that 80% of adults will demonstrate a positive complement fixation test to the agent. Abortions, stillbirths, and a syndrome of jaundice, hepatosplenomegaly, and hemorrhagic diathesis results from disseminated infection in the newborn. In older children the virus can be transmitted by the respiratory route and a pneumonitis may occur. Whereas this virus has been found in lungs of adults dying of leukemia and lymphomas, the clinical symptoms of pulmonary

involvement have not been clearly differentiated from those of the terminal neoplastic disorder. Inclusion bodies of this type have been found in the lungs of ten of the 17 renal transplant recipients in this series who died, although only four of the ten patients had clinically recognized pneumonia.

The coexistence of *Pn carinii* and cytomegalovirus in pneumonia has been noted frequently. Ten of 16 infants and six of 15 adults with generalized cytomegalovirus infection were found to have *Pneumocystis* pneumonia.<sup>13,14</sup> In addition, generalized cytomegalovirus infection can be demonstrated in 25% of cases of *Pneumocystis* pneumonia.<sup>15</sup> The association is so constant that it has been questioned whether cytomegalovirus can cause pneumonia in adults in the absence of *Pn carinii*.<sup>16</sup> It is believed that the six cases of pneumonia reported here are compatible with *Pn carinii* infection in patients whose defense mechanisms have been impaired by immunosuppressive drug therapy. The cytomegalovirus may have been present and contributed to the pathological process in some of the nonfatal cases, but it is not possible to establish this on clinical grounds. In case 2, however, the inclusion bodies were widely disseminated throughout the body and this may have been the unique factor which led to fatality.

Both of the infectious agents found in case 2 are opportunistic; that is, they usually produce clinical disease only when host defense mechanisms are depressed. Whether there are, in addition to the suppressive drug therapy, immunologic factors unique to organ transplant recipients which contribute to the development of these pneumonic processes is a matter of speculation. Fever without recognized pulmonary disease has occurred in approximately 40% of renal transplant recipients during attenuation of prednisone therapy; frequently when the dose is decreased below 1 mg/kg/day. This phenomenon of "steroid-withdrawal fever" may result from the unmasking of an immunologic response of the host directed against the implanted organ. A lack of absolute specificity of this reaction could permit the host's lungs to be attacked in a fashion analogous to localization of rabbit antirat-kidney antibody in both the lungs and kidney of the rat. Such an allergic or autoimmune mechanism has been suggested for pulmonary disorders occurring in a variety of collagen diseases.<sup>16</sup> Conceivably, immune mechanisms of this type could both produce their own unique pathological changes and predispose the lung to endogenous or exogenous infectious agents just as, for example, pulmonary alveolar proteinosis predisposes to nocardial pneumonia.<sup>17,18</sup>

#### Addendum

Since submission of this communication, two additional renal transplant recipients have died with pneumonia of the type reported here. In an 18-year-old boy, the cold-agglutinin titer rose to 1:32

prior to death. Unfortunately, permission for post-mortem examination was denied. In a 17-year-old boy, autopsy revealed an *Aspergillus fumigatus* brain abscess and *Pn carinii* pneumonia.

4200 East Ninth Ave, Denver 20 (Dr. Rifkind).

This study was supported by US Public Health Service grants A6283, A6344, HE07735, AM07772, AI04152, and OG27.

The Eaton agent complement fixation test was done by Dr. Maurice A. Mufson, National Institutes of Health.

#### Generic and Trade Names of Drugs

Prednisone—*Deltason, Delta, Meticortin, Paracort*.  
Sodium methicillin—*Dimocillin-RT, Staphcillin*.  
Chloramphenicol—*Chloromycetin*.  
Mycostatin—*Mycostatin*.

#### References

- Rifkind, D., et al: Infectious Diseases Associated With Renal Homotransplantation: I. Incidence, Types, and Predisposing Factors, *JAMA* 189:397-401 (Aug 10) 1964.
- Rifkind, D., et al: Infectious Diseases Associated With Renal Homotransplantation. II. Differential Diagnosis and Management, *JAMA* 189:402-407 (Aug 10) 1964.
- Chanock, R.M.; Hayflick, L.; and Barile, M.F.: Growth on Artificial Medium of Agent Associated With Atypical Pneumonia and Its Identification as PPLO, *Proc Nat Acad Sci USA* 48:41-49 (Jan) 1962.
- Gajdusek, D.C.: *Pneumocystis carinii*—Etiologic Agent of Interstitial Plasma Cell Pneumonia of Premature and Young Infants, *Pediatrics* 19:543-565 (April) 1957.
- Cohen, W.M., and McAlister, W.H.: *Pneumocystis carinii* Pneumonia: Report of Four Cases, *Amer J Roentgen* 89:1032-1037 (May) 1963.
- Bommer, W., and Lahn, M.: *Pneumocystis carinii* in Interstitial Plasma-Cell Pneumonia, *Amer J Dis Child* 102:375-379 (Sept) 1961.
- Erchul, J.W.; Williams, L.P.; and Meighan, P.P.: *Pneumocystis carinii* in Hypopharyngeal Material, *New Eng J Med* 267:926-927 (Nov) 1962.
- Barta, K., et al, quoted by Gajdusek.<sup>4</sup>
- Kossel, A.: Interstitielle Plasmazelluläre Pneumonie beim Alteren Kind als Folge Lang dauernder Corticosteroidbehandlung, *Deutsch Med Wschr* 87:1133-1139 (June) 1962.
- Dvořák, J., and Jírovec, O.: Diagnostik und Therapie der durch *Pneumocystis Carinii* Verursachten Parasitären Atypischen Pneumonien bei Säuglingen, *Acta Paediat* (Stockholm) 42:232-245 (May) 1953.
- Sheldon, W.H.: Experimental Pulmonary *Pneumocystis carinii* Infection in Rabbits, *J Exp Med* 110:147-160 (July) 1959.
- Weller, T.H., and Hanshaw, J.B.: Virologic and Clinical Observations on Cytomegalic Inclusion Disease, *New Eng J Med* 266:1233-1244 (June 14) 1962.
- Wong, T., and Warner, N.E.: Cytomegalic Inclusion Disease in Adults: Report of 14 Cases With Review of Literature, *Arch Path* (Chicago) 74:403-422 (Nov) 1962.
- Hendry, W.S., and Patrick, R.L.: Observations on Thirteen Cases of *Pneumocystis carinii* Pneumonia, *Amer J Clin Path* 38:401-405 (Oct) 1962.
- Hamperl, H.: Variants of *Pneumocystis* Pneumonia, *J Path Bact* 74:353-356 (Oct) 1957.
- Read, J.: Pathologic Changes Produced by Anti-Lung Serum, *J Path Bact* 76:403-417 (Oct) 1958.
- Andriole, V.T.; Ballas, M.; and Wilson, G.L.: Association of Nocardiosis and Pulmonary Alveolar Proteinosis, *Ann Intern Med* 60:266-275 (Feb) 1964.
- Carlsen, E.T.; Hill, R.B., Jr.; and Rowlands, D.T., Jr.: Nocardiosis and Pulmonary Alveolar Proteinosis, *Ann Intern Med* 60:275-281 (Feb) 1964.