


74



PUBLISHED BY  
SOUTHERN  
MEDICAL  
ASSOCIATION

February 1965

# Clinical Experience With Organ Transplantation\*

THOMAS E. STARZL, M.D., Ph.D., THOMAS L. MARCHIORO, M.D.,  
DAVID RIFKIND, M.D., Ph.D., DAVID T. ROWLANDS, JR., M.D., and  
WILLIAM R. WADDELL, M.D.† *Denver, Colo.*

The authors have had an exceptional experience in the transplantations of organs in humans. This paper clearly indicates the current status in this area of medical experimentation.

IN THIS COMMUNICATION, the problems of tissue transplantation will first be surveyed as they apply specifically to the kidney and its function. As an experimental model, transplantation of this organ has unique advantages for the acquisition of knowledge which will undoubtedly have more general application. With renal homografts, the functional status of the kidney can be followed with precision, using the specific parameters of urine volume, blood urea nitrogen, creatinine clearance, urine protein and urea, and blood pressure. The onset of rejection can be defined with great accuracy. Inferential information concerning the mechanisms of tissue deterioration are available for analysis. The effect of agents used for the prevention or reversal of rejection can be determined unequivocally, since the transplanted kidney is essential for life and its function can be scrutinized on a moment-to-moment basis. Finally, the technical necessities of operation have much in common with those met with other organs such as the liver, inasmuch as the factors of ischemic injury, preservation of homograft, reconstitution of blood supply, and reconstruction of nonvascular visceral passages are all essential details in the trans-

plantation of most organs. Having first surveyed progress with kidneys, we will then describe how such information has been extrapolated to hepatic and splenic whole organ homotransplantation within our own experience.

## Kidney Transplants

Forty-two renal homotransplantations were performed from 1 to 12 months ago. Glomerulonephritis, polycystic kidney disease, and pyelonephritis were the most common diseases in the recipient. In all cases but one, multiple hemodialyses were required for preoperative preparation. The majority of patients had neurologic abnormalities prior to operation, including convulsions, coma, neuropathies and psychoses. All except seven were males, and ages ranged from 6 to 50 years.

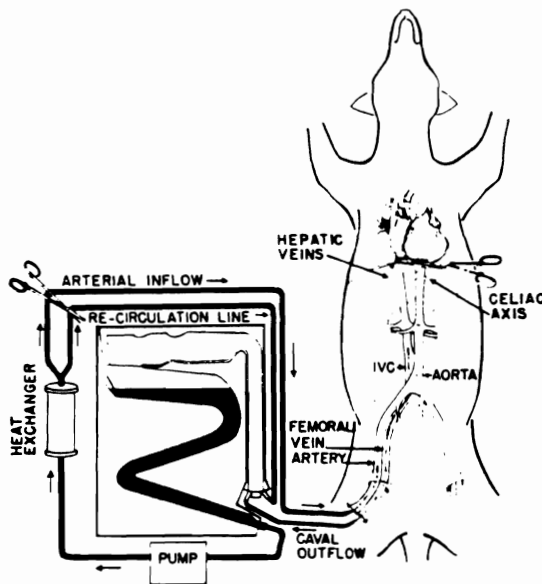
*Source of donor organs.* Forty-five homografts were used in the treatment of the 42 cases. In two instances, cadaveric kidneys were obtained using an extracorporeal hypothermic perfusion technic which is instituted immediately after death of the donor (Fig. 1), but good renal function was not obtained in either case and both recipients died after 25 and 40 days respectively. In the other 10 cases, 43 living donors were used, 3 of these being removed at or shortly after their implantation. In the exceptional 3 patients, second transplants were provided subsequently. In analyses involving the influence of consanguinity

\*Read before the Symposium on Organ Transplantation, Southern Medical Association, Fifty-Seventh Annual Meeting, New Orleans, La., Nov. 18-21, 1963.

†From the Surgical Service, Veterans Administration Hospital, and the University of Colorado Medical School, Denver, Colo.

Aided by Grants A-6283, A-6344, AI 04152, HE 07735, and AM 07772 from the United States Public Health Service.

FIG. 1



Method of combined perfusion and cooling of kidneys employed in two human cases. Immediately after death, the cannulas are placed in the femoral vessels. The priming solution is heparinized in advance, and 1 Gm. per liter of procaine chloride is added to the perfusate. Selective perfusion of the lower portion of the cadaver is obtained by cross-clamping the lower thoracic aorta. (Marchioro et al., by permission of *Surgery*, 54:900, 1963.)

upon results, the genetic relationships in these three cases are tabulated as those between the second donor and the recipient.

The genetic relationships were as follows: There were 9 mother to offspring transfers, 1 from father to daughter; 16 sibling donations (including 2 pairs of fraternal twins and 2 pairs of identical twins); and 16 from genetically unrelated donors (Table 1). In 13 patients, female kidneys were transplanted to male recipients, and in 3 others an intersex change was made in the reverse direction.

With living donors, cooling of the homograft was provided either by total hypothermia of the donor's body or with intra-arterial perfusion of the excised kidney with cold lactated Ringer's solution, where a major donor-re-

TABLE 1  
RENAL TRANSPLANTS

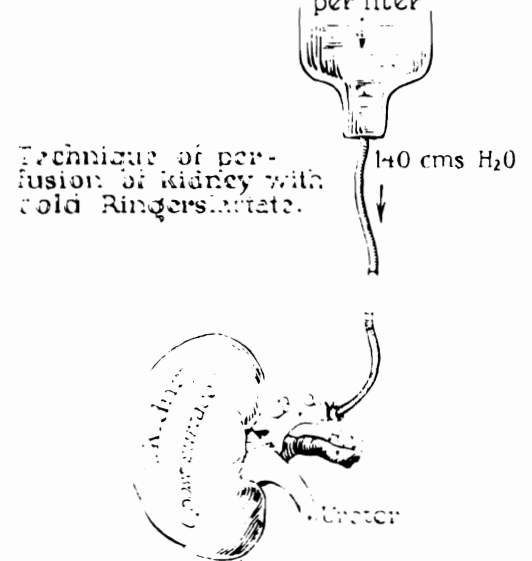
Genetic Relationships		No.	Alive
Identical twins	Isografts	2	2
Mother	Offspring	9	9
Father	Offspring	1	0
Sibling		14	10
Unrelated			
Living source		11	7
Cadaver		2	0

ipient incompatibility of blood type existed (Fig. 2). In the series of living donors, the mean ischemia time was 34 minutes with a range of 17 to 85 minutes. The transplantation technic of Kuss as modified by Murray and Harrison was used, with a nipple and tunnel ureteroneocystostomy (Fig. 3).

*Antirejection therapy.* The two patients who received kidneys from their identical twins did not receive treatment with immunosuppressive drugs since the donors and recipients in such cases have no immunologic cross reaction and the transplanted tissue behaves as an autograft. In the other 40 cases, antirejection therapy was usually provided with a single agent, azathioprine (Table 2), starting 2 to 19 days before the transplantation. When the diagnosis of rejection was subsequently made, 150 to 300 mg. of prednisone per day were added as well as intermittent courses of 200 to 400 mcg. of actinomycin C given every 2 to 5 days (Fig. 4). In general,

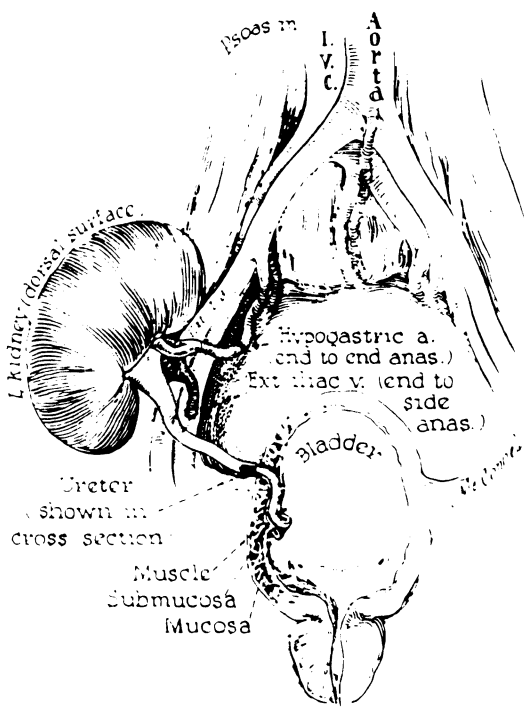
FIG. 2

15°C lactated Ringers with 50 mgm heparin and 1 gram procaine per liter



Method of infusion used to cool and wash the kidney in those cases where the donor and recipient patients have different major blood types. Good flow cannot be obtained without the addition of procaine chloride. Note that heparin is added to the lactated Ringer's solution which is cooled to 15° centigrade. (Starzl et al., by permission of *Surgery*, 55:195, 1964.)

FIG. 3



General technic of renal transplantation. Note the tunnel and nipple technic used for ureteroneocystostomy. (Starzl et al., by permission of J.A.M.A. 187:734, 1964.)

it was attempted to avoid suppression of the white blood count.

Excision of the spleen was carried out as adjuvant surgical measure in 39 of the 40 cases of true homotransplantation. Usually bilateral nephrectomy, splenectomy and renal homotransplantation were carried out in one stage. In nine patients, the thymus was also removed, a procedure no longer employed. Despite intensive investigative efforts in the laboratory using dogs, statistical proof of the effectiveness of either of these additional operative procedures for mitigation of the rejection process has not been obtained by us, and hence their use must be considered a clinical experiment.

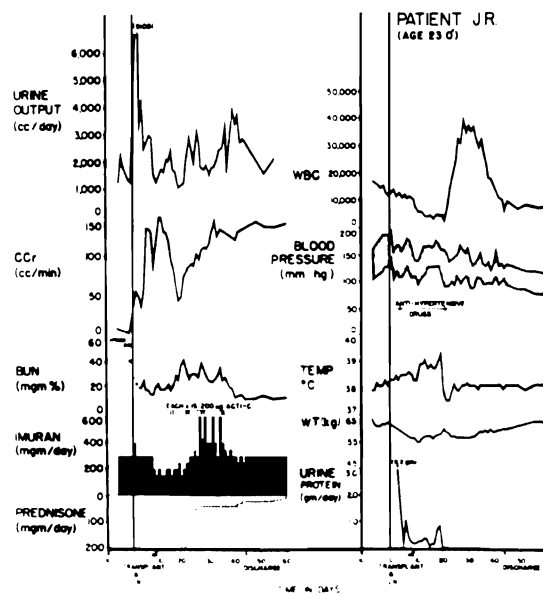
TABLE 2  
KIDNEY HOMOTRANSPLANTS

Predominant Method for Host Immune Suppression:	Number of Patients
1. Total body x-irradiation	0
2. Local x-irradiation	0
3. Drugs	39
4. Combination of 1 and 3	1
5. Combination of 2 and 3	0

One patient in the series, a 12 year old boy who received a kidney from his mother, was treated with combined total body irradiation and pharmacologic agents (Fig. 5). He received 400 roentgens in divided doses before and after transplantation. Despite profound suppression of the white blood count, a rejection episode began on the fourteenth day. This was reversed by the administration of large doses of prednisone and actinomycin C. He has subsequently been converted to therapy with azathioprine.

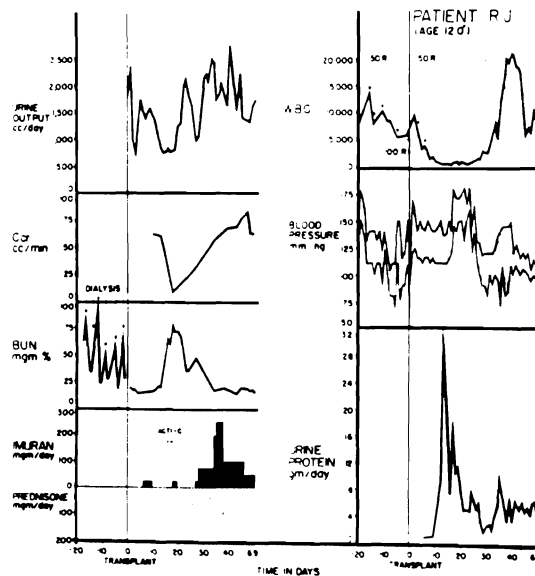
*Survival statistics.* The two identical twins are well, 20 and 4 months after receipt of their transplants (isografts). Twenty-six of the 40 patients receiving true homografts are alive, one month to one year postoperatively. Both patients who received cadaveric kidneys died within 5½ weeks of a combination of sepsis and continuing uremia. Of the 38 patients receiving kidneys from living donors, 26 or 69% are alive, and 20 of these have been discharged from the hospital. The causes of death are indicated in table 3. It will be noted that multiple factors were usually responsible for an unfavorable outcome, the most common combination being drug tox-

FIG. 4



Depiction of details of immunosuppressive therapy. Note deterioration of renal function after 19 days, and subsequent reversal of this process. Acti-C, actinomycin C. LN, left nephrectomy at time of transplantation. RN, right nephrectomy. Imuran is synonymous with azathioprine. The patient still has normal function, now seven months postoperative. (Starzl et al., by permission of Surg Gynec Obstet 117:385, 1963.)

FIG. 5



Rejection crisis in case treated initially with irradiation. Note transient oliguria, depression of creatinine clearance, and elevation in BUN, blood pressure, and excretion of urinary protein. The changes were all reversible. The patient previously had bilateral nephrectomy, splenectomy, and thymectomy. R-dose total body irradiation. Actu-C—each arrow equals 200 mcg. actinomycin C intravenously. Imuran is synonymous with azathioprine. The patient now has normal renal function one year postoperatively. (Starzl et al., by permission of *Surg Gynec Obstet* 117:383, 1963.)

icity and infection which occurred during treatment of the rejection crisis.

The influence of consanguinity upon results is shown in table 1. Except for identical twins, the most favorable pair appears to be mother to offspring, next sibling transfer,

and with the poorest results in that group with nonrelationship. Age of the patient was also profoundly influential in determining the outcome (Table 4). Three fourths of all deaths in the group receiving kidneys from living donors occurred in the age group of 35 or older, including 3 of the 4 failures in which kidneys had been obtained from siblings. These observations have led recently to a more rigid policy of case selection with restriction of the operation to the youthful patients, and preferably those with familial donors.

*Influence of blood groups upon the results.* Eleven of the homografts were taken from donors who had a different ABO blood type than the recipient (Table 5). The donor-recipient transfers were O to A in 4 patients, O to B in 1 patient, A to O in 3 patients, B to A in 1 patient, A to AB in 1 patient, and B to O in 1 patient. In 3 of these ABO mismatches, there was coexistent Rh incompatibility, and in 5 more the Rh difference was the sole incompatibility. Good function was obtained with various combinations of these blood mismatches and it was initially thought that indiscriminate crossing of blood groups was possible. Indeed, this conclusion was supported by the fact that satisfactory renal function has been obtained with virtually every combination. More recently, however, two accidents have occurred with the use of A and B donors to O recipients respec-

TABLE 3

CAUSIS OF DEATH IN FIRST 40 PATIENTS RECEIVING RENAL HOMOTRANSPLANTS

Patient No.	Age	Drug Toxicity	During Rejection Crisis	Unrelieved Uremia	Infection	Other
<i>Cadaveric Kidneys</i>						
1	21	X	X	X	X	
2	29			X	X	Hemorrhage Dialysis, shunt
<i>Kidneys from Living Donors</i>						
4	35				X	
5	50	X			X	
7	25				X	Small pulmonary emboli
8	29					Unknown
11	35	X	X		X	Paralysis Heart failure Pancreatitis
16	44					
21	41	X			X	
24	42	X	X			
26	16					
28	49	X	X		X	Electrolyte imbalance Intestinal necrosis small pulmonary emboli
29	40	X	X		X	
31	54	X	X		X	Lobar pulmonary embolus

TABLE 4

INFLUENCE OF AGE ON OUTCOME IN 78 PATIENTS  
WITH VOLUNTEER KIDNEY DONORS  
IDENTICAL TWINS EXCLUDED

	Alive	Dead
35 years or older	9	9
34 to 25 years	7	2
24 years or less	10	1

tively. Immediately upon revascularization, the kidneys became purple and it was obvious that blood flow through the cortex was not occurring. After observation for several hours, the homografts were removed (Fig. 6). Angiograms showed absent vascularization of the cortex (Fig. 7). Histologic sections showed intra-renal "sludge" lesions. Second transplants were provided 14 and 10 days later with satisfactory results. These experiences have led to two conclusions. First, homotransplantation in the presence of donor-recipient incompatibility of blood group may be sporadically successful with almost any combination. However, certain mismatches appear to carry a higher risk (Table 6). The situations in which this would be the case are A to non-A, B to non-B and AB to non-AB. The donor to recipient incompatibilities which would be relatively safe are O to non-O and Rh incompatibilities except in the unusual and predictable circumstance in which recipient presensitization has occurred in an Rh negative patient. Thus, the pattern of acceptable tissue transfer within the ABO system seems to be comparable to that already defined for blood transfusions in that O patients are probably universal donors and AB patients are universal recipients (Table 6).

*Incidence of immediate anuria.* The cadaveric kidneys either had sluggish or absent renal function at the outset. Thirty-seven of the homografts obtained from 41 living donors

TABLE 5  
BLOOD GROUP MISMATCHES

		Good Early Function	Alive
O to A	4	4	2
O to B	1	1	1
A to O	3	1	2*
B to A	1	1	1
A to AB	1	1	0
B to O	1	0	1*
Rh- to Rh-	3	3	2
Rh- to Rh+	5	5	4

\*2nd homograft placed in one patient from each group.

FIG. 6




Kidney provided by an A positive donor to an O positive recipient, and removed 3 hours after revascularization. Note dark color of organ.

had immediate diuresis. In 2 patients, described above, instant failure of the organ occurred presumably due to acute hemagglutination reactions. In 2 others prolonged ischemia was associated with failure of immediate urine production. The mean interval between revascularization and the detection of first urine flow in these 37 cases was 24 minutes, ranging from 5 to 150 minutes. The magnitude of diuresis was sometimes astonishing, being as much as 2,000 ml. per hour.

*The phenomenon of the rejection crisis.* In the treatment of these cases, a characteristic

FIG. 7



Angiogram obtained after removal of a homograft, obtained from a B positive donor and transplanted to an O positive recipient. The kidney was removed three hours after it had been placed because of its cyanotic appearance. Note major vessels are open but that outer cortex is avascular.

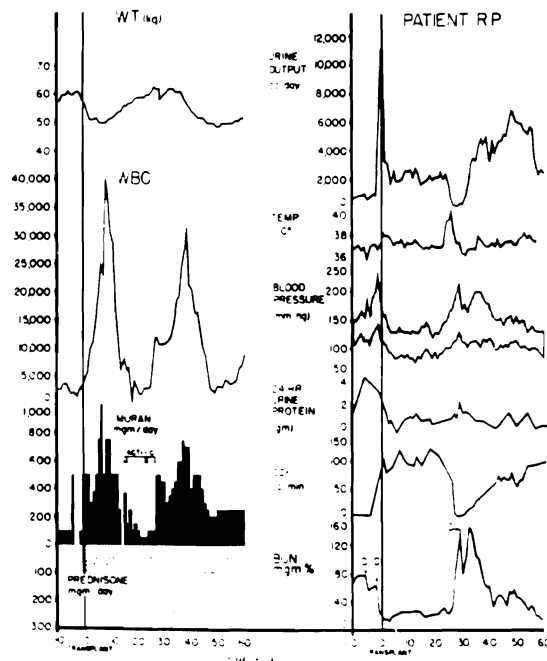
**TABLE 6**  
DIRECTION OF ACCEPTABLE MISMATCHED  
TISSUE TRANSFER\*

O to non-O	Safe
Rh- to Rh-	Safe
Rh+ to Rh-	Relatively safe
A to non-A	Dangerous
B to non-B	Dangerous
AB to non-AB	Dangerous

\*O is universal donor  
AB is universal recipient

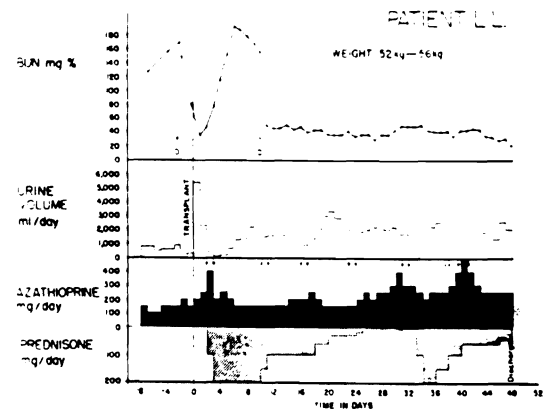
pattern of behavior of the homograft has emerged which appears to be of the utmost significance in the planning and execution of effective therapy. After technically successful homotransplantation, there is a temporary improvement in the general condition with resolution of the azotemia. At various times in the postoperative period, ranging from 1 to 42 days, secondary deterioration of the renal function occurs in 90% of the cases with hyperpyrexia and multifaceted evidence of acute renal failure (Fig. 8). With the diagnosis of a rejection crisis, and with the addition of massive doses of prednisone as well as intravenous actinomycin C, it is almost always

**FIG. 8**



Rejection crisis observed in second case treated at the University of Colorado Medical Center. The episode was unusually severe, with development of anuria on the 26th to 29th days after operation. The process was completely reversible, and the patient now has normal renal function, 10 months after operation. (Starzl et al., by permission of *Surg Gynec Obstet* 117:335, 1963.)

**FIG. 9**



Development of early rejection crisis after 36 hours, following an initial brisk diuresis. Although temporary anuria resulted, the crisis was reversed. Such an early rejection episode is encountered in approximately 15% of these cases. (Starzl et al., by permission of *Surg Gynec Obstet* 113:319, 1964.)

possible to reverse the rejection crisis in patients who have had initial good renal function. The time necessary to reverse the events of the rejection episode ranges from 7 to 35 days. No instrumentation or manipulation of any sort is carried out at this time. It is assumed that a technical accident had not occurred. Even those patients who became anuric at this time usually have subsequent return of normal renal function (Fig. 9). After successful reversal of the rejection process, a state of host-graft adaptation appeared to occur. Return to a drug regimen which was inadequate to prevent the onset of the rejection now serves to prevent additional rejection insults. In only 2 of the 26 living patients has a recurrence of secondary rejection been seen.

*The present status of renal transplantation.* Despite considerable progress in the past two years, renal homotransplantation cannot yet be regarded as an established surgical procedure, because it has failed to conform to certain criteria. These requirements are: first, that the operation be performed with a reasonably low mortality; second, that the patient be restored to a reasonable state of health for a significant period of time; and, finally, that the financial burden of care should be within the reach of the patient, the hospital, and the community. If these practical objectives could be achieved, it would be possible to extend the use of renal transplantation to a position of more general utility in which such care could be offered in an increasing number of hospitals.

TABLE 7  
LIVER TRANSPLANTS

No.	Donor and Recipient Ages	Date of Transplant	Disease	Donor-Recipient Blood Types	Donor Death to Revas. (Minutes)	Survival (Days)	Cause of Death	Cause of Donor Death
1	3 — 3	3-1-63	Biliary atresia	A+ — A+	420	0	Operative hemorrhage	Cardiac arrest at operation
2	55 — 48	5-5-63	Cirrhosis and hepatoma	A+ — A+	152	22	Pulmonary emboli	Terminal brain tumor
3	69 — 67	6-24-63	Cholangio carcinoma	O- — O+	192	7½	Pulmonary emboli, GI bleeding	Stroke
4	73 — 52	7-16-63	Cirrhosis and hepatoma	O+ — A-	174	6½	Pulmonary emboli; congestive heart failure	Coronary
5	64 — 29	10-4-63	Cirrhosis and hepatoma	O+ — O+	164	23	Common duct necrosis & bile peritonitis; ? rejection	Gunshot wound head (Suicide)

Experience at the University of Colorado Medical Center has led to a growing hope that these objectives are within reach, but it is perfectly clear that they have not yet been attained. The mortality figures have steadily improved, but they are still unacceptably high, even when judged within the reference of short term follow-up. It is evident that dramatic improvement in the patient's health can be achieved, but the permanence of homograft function is a matter for speculation. It has been our impression that late deterioration of renal function becomes a decreasing threat as time passes, but the follow-up of such patients will be meaningful only in terms of years rather than months. Finally, the expense of transplantation as it is currently practiced is so great that the cost can be borne only by institutions which are subsidized specifically for such clinical investigation. These facts must be realized by any group contemplating entry into the field of homotransplantation. At the present time sober analysis of the situation suggests that such a developmental undertaking should still be confined to a research installation.


#### Liver Transplants

In a recent publication, experience was recounted with the first hepatic homografts treated at the University of Colorado Medical Center. The technics employed, methods of preservation, approach to immunosuppressive therapy, and the pathologic studies in these patients were all fully recounted. In the present report, the salient features of these first cases are recapitulated in tabular form (Table 7), and further experience with two subsequent cases will be described.

#### Technical problems specific to hepatic

transplantation. The magnitude of operation is much greater in hepatic than with renal transplantation. Removal of the recipient's own liver has been complicated in all five cases by the disease for which the operation was performed. In Case 1, hepatomegaly and varices were present. In the other four patients, all treated for primary intrahepatic malignancies (Table 7), the increased size of the liver was also troublesome, and in three of these underlying cirrhosis increased the vascularity in the operative field. The necessity for performing four vascular anastomoses, instead of two, doubles the possibility of complications at the suture-line (Fig. 10). Reconstruction of the common duct is probably a more dangerous procedure than ureteroneocystostomy, inasmuch as the major blood supply to the upper portion of the common duct normally comes from inferiorly, and is of necessity sacrificed in preparation of the donor organ (Fig. 10). Finally, an external

FIG. 10



View of the completed subhepatic vascular and common bile duct anastomoses. An additional anastomosis of vena cava is located at the diaphragm. Note that the arterial anastomosis is performed distal to the recipient gastroduodenal artery and proximal to the donor gastroduodenal artery. The T-tube is placed through the recipient portion of the composite common duct. (Starzl et al., by permission of *Surg Gynec Obstet*, 117:659, 1963.)


by-pass is required to shunt blood from the occluded venous pools of the lower half of the body to the superior caval collecting system—an additional technical requirement of potential hazard in view of the alterations in dynamics of coagulation which have been regularly observed.

*Specific biologic problems.* With renal homografts, it has been observed that virtually all attempts at rejection can be reversed. The difficulty with which this is accomplished is, however, subject to wide variation, and in some cases there are protracted periods of oliguria or anuria before resumption of adequate function. Cessation or serious deterioration of renal function can be tolerated for several days or even weeks with appropriate use of the artificial kidney. With hepatic homografts, the prospect of temporary failure is unacceptable inasmuch as complete loss of function even for a brief time would be fatal. At the present time mechanical devices are not available which can be used for interim treatment. This fact alone dooms in advance a certain fraction of patients receiving hepatic transplants.

*Results.* The courses in the first three cases have been previously described in detail, and are summarized in table 7. In this group, the maximum survival was 21 days. Since that time, two additional patients have been treated, and brief accounts of their course follow:

**Case 4.** (Denver V.A. Hosp.) A 52 year old man was found at exploration, on May 5, 1963, to have a primary hepatoma of the liver (Fig. 11). He was re-

FIG. 11



(Case 4, Table 7). The patient had cirrhosis with a superimposed primary hepatoma. Note numerous satellite tumor nodules replacing virtually all of normal parenchyma.

FIG. 12

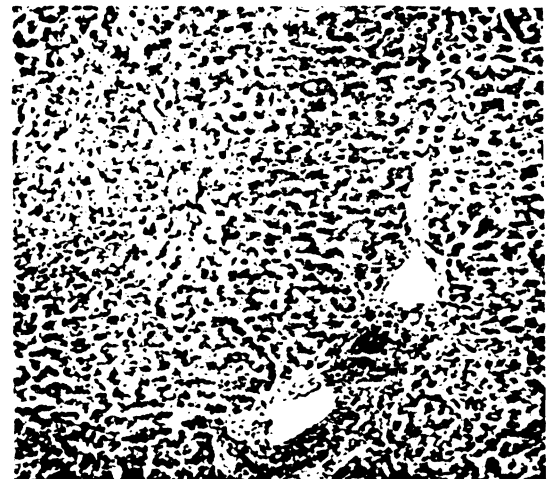


(Case 4, Table 7). Posterior view of viscera excised *en bloc* at autopsy. Note the large fresh thrombus occupying most of the lumen of the inferior vena cava in the upper portion of the photographic view.

ferred to the Denver V.A. Hospital. On July 15, emergency laparotomy was necessary because of a massive upper gastrointestinal hemorrhage. At operation, a posterior penetrating duodenal ulcer was found and treated with vagotomy, pyloroplasty, and suture ligation of the ulcer base. At the time of this operation, first-stage mobilization of the liver was carried out, cutting the triangular, falciform, and coronary ligaments. The vena cava above and below the liver and the portal structures were skeletonized. One day later hepatic transplantation was performed.

The cadaveric liver was provided by a 73 year old

FIG. 13



(Case 4, Table 7). Histologic section of liver homograft. Note relatively well-preserved parenchymal architecture, as well as the focus of round cells in the periportal area in the right lower portion of the field. There was a fine mononuclear cell infiltrate scattered throughout the lobules as well (H & E, X 325).



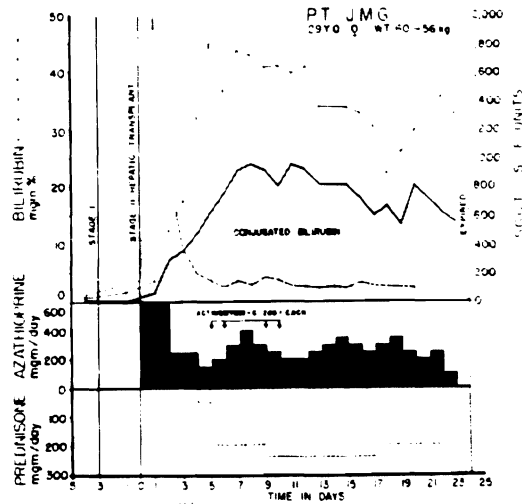
man who died of coronary heart disease. The donor was O— blood type and the recipient A—. The time from death of the donor to revascularization of the liver in its new bed was 174 minutes. A technical point of interest was that the donor liver was vascularized by two small arteries, each lobar in distribution, one of which arose from the superior mesenteric and the other from the hepatic artery. These two vessels were individually anastomosed to the recipient hepatic artery. A single external by-pass was used from the inferior vena cava to the internal jugular vein. In the course of the operation, hemorrhage from the duodenal ulcer was reactivated and it was necessary to do a hemigastrectomy in addition to the hepatic transplantation. During the operation and in the ensuing two hours, fibrinogen levels were seriously depressed to as low as 10 mg.%. High titres of fibrinolysis were detected by analysis of euglobulin lysis times. Human fibrinogen and epsilon amino caproic acid were administered.

After restoration of the vascular supply to the liver, the external by-pass was removed and the right superficial femoral vein through which it had been inserted inferiorly was sacrificed. At completion of the operation, it was noticed that the right leg had evidence of phlegmasia cerulea dolens.

Postoperatively the patient developed respiratory insufficiency within 24 hours after operation, and required ventilatory support until his death six and a half days later. During most of this time, he was irrational and at times comatose. Bilirubin, which was 0.6 mg. preoperatively, rose to a maximum of 7.7 mg. on the 4th postoperative day and had returned to 1.1 mg.% on the last day of his life. (An acute rise in SGOT, was not observed, as was the case in the other three patients who survived operation.)

Six and a half days postoperatively, after an apparently improving clinical course, the patient developed a cardiac arrest. At autopsy, there was evidence of bilateral pulmonary edema and several small pulmonary emboli were found in the distal pulmonary arteries on both sides. Grossly, the liver appeared to be slightly swollen, but otherwise was normal. The vas-

FIG. 15




(Case 5). Note the striking early rises in SGOT, and bilirubin with later partial reversal of these abnormalities. On the 16th postoperative day, the patient's condition deteriorated, and a secondary rise in bilirubin occurred. Immunosuppressive therapy is depicted at bottom of chart.

cular anastomoses were patent, but large clots occupied the inferior vena cava (Fig. 12). Histologic sections of the liver revealed moderate numbers of lymphocytes and small numbers of larger mononuclear cells in many of the intrahepatic portal triads (Fig. 13). Widely scattered areas of parenchymal necrosis were seen with neutrophilic reaction. Mild bile stasis was present. The findings could not be construed as unequivocal evidence of rejection.

**Case 5. (Colo. General Hosp.)** A 29 year old woman with a huge hepatoma (Fig. 14) of the liver received an hepatic transplant at 2:00 a.m. on Oct. 5, 1963. A first stage operation had been performed two and a half days earlier, at which time mobilization of the liver had been carried out, as well as a prophylactic vagotomy and pyloroplasty. The homograft was obtained from a 64 year old man who had committed suicide by shooting himself in the head. The time from death of the donor to revascularization was 164 minutes. Both patients had O+ blood types.


Postoperatively, the early course was benign, despite an alarming rise of bilitubin to a maximum of 45 mg.% (Fig. 15). SGOT, 14 hours after operation was 2,050 units, with a progressive fall over the next few days. No complications developed during early convalescence. She was treated with azathioprine, prednisone, and actinomycin C (Fig. 15). All wounds healed cleanly. The patient spent most of the time outside the hospital from the 4th to the 17th postoperative day, at which time her chemical jaundice, which had been improving, began once again to deepen (Fig. 15). Plasma fibrinogen and prothrombin values, which had been low throughout the course, began to fall even further, reaching 70 mg.% and 8% respectively the day before death. She became profoundly weak. Serum levels of lactate and pyruvate were elevated to 5 to 10 times normal values. Terminally, she became comatose and ultimately developed gastrointestinal hemorrhage

FIG. 14



(Case 5). Primary hepatoma. All dark cells in the field are neoplastic; no normal parenchyma is seen (H & E, X 80).

FIG. 16



(Case 5, Table 7). The hepatic homograft shows rather poor staining quality of large portions of the field, as well as a few scattered lymphocytes throughout. Heavily stained amorphous areas are collections of bile, suggestive of biliary stasis (H & E, X 32).

as well as petechial hemorrhages over various areas of the body. Death occurred 23 days after operation.

At autopsy the liver was soft. All vascular anastomoses were patent, and no intravascular clots were present anywhere. The donor portion of the composite common duct had undergone necrosis and the upper limb of the T-tube was protruding free in the para-choledochal area. At this site there was a collection of bile of approximately 300 ml.

Histologically, the liver had large areas in which parenchymal cells were absent or remained only as ghosts (Fig. 16). The centrilobular zones were selectively involved. Cellular infiltration was almost absent, only a few small lymphocytes being present in the portal areas (Fig. 17). Silver stains showed almost perfect preservation of the reticular pattern (Fig. 18).

*Comment.* The diagnosis of rejection is difficult on the basis of the pathologic findings. Nevertheless, the clinical course was highly suggestive in such a cause for failure in this case.

Management of this patient differed from that of the others in two respects. The single by-pass was inserted via the saphenous vein into the inferior vena cava instead of through a venotomy in the femoral vein, and after its removal the cannulated vessel was ligated flush at its entrance into the femoral vein. Furthermore, no measures were used at any time to promote coagulation. During transplantation systemic heparinization with 3 mg. kg. of heparin was provided; this was not neutralized subsequently with protamine sulphate, nor were EACA and fibrinogen given. The avoidance of the hypercoagulability syndrome encountered later in the earlier cases may have been due to observance of these precautions. The penalty was the need for the

transfusion of 18 units of fresh blood during and immediately after the transplantation.

*The future of hepatic transplantation.* In theory the rationale for hepatic transplantation is not dissimilar to that which applies to a kidney. The additional difficulties imposed by an operation of such magnitude, however, make it unlikely that this mode of therapy can ever be applied as freely as with renal transplantation. In addition, the problem of dealing with a rejection crisis involving an organ of such complex function as the liver imposes an additional serious handicap.

The principal value of the clinical experience thus far obtained by us and by Moore at the Peter Bent Brigham Hospital has been to highlight additional problems which must now be attacked further in the laboratory. It seems inevitable that hepatic transplantation will eventually be successful, but not until further controlled information becomes available upon the alterations to be expected in coagulation, and on a more effective application of immunosuppressive therapy. Until such time, further clinical trials have been discontinued by us.

### Spleen Transplants

Five spleens have been transplanted, four in an attempt to treat patients with disseminated carcinoma, and one for treatment of a child with congenital sex linked hypogammaglobu-

FIG. 17



(Case 5). Higher power view of liver showing a portion of a portal area containing many small lymphocytes (H & E, X 160).

TABLE 8  
HUMAN SPLEEN TRANSPLANTS

No.	Age	Date Transplant	Indication	Donor to Recipient Blood Groups	Ischemia Time	Fever Crisis	Evidence Hyposplenism	Survival
1	55	2-19-63	Terminal alveolar cell Ca	A- — A+	45 min.	4 days	No	Alive—9 months
2	46	4-19-63	Terminal gastric Ca	A- — A-	53 min.	1 day	Transient	3 months
3	53	7-10-63	Terminal renal Ca	A- — A+	54 min.	1½ day	No	2 months
4	45	7-28-63	Terminal gastric Ca	O+ — A+	62 min.	1½ day	Sustained	10 days
5	12	6-28-63	Hypogammaglobulinemia	A+ — A+	28 min.	1½ days	Transient	Alive—11½ months

linemia. It should be stated at the outset that such operations are entirely developmental and without proven value. Indeed, evidence will be presented from the following brief experience which suggests that the patients received only transient, if any, benefit.

The rationale for splenic homotransplantation for either purpose is similar. In hypogammaglobulinemia it was hoped that the deficient protein fraction would be provided by the new lymphoid source, a concept previously developed by Good in his human experiments, using lymph node transplantation for such cases. In patients with cancer, it was hoped that the homograft would provide an antibody inimical to the tumor with a consequent graft-versus-host reaction. In an effort to give selectivity to such a reaction, the splenic donors were presensitized with tumor cells from the eventual recipient, as will be described.

In experimental animals, protocols to test the foregoing concepts are difficult to formulate since experimental models to simulate the appropriate disease states are not available. However, Marchioro and his associates have provided considerable information in dogs which bears on the safety and manageability of this kind of transplant. They showed that it was possible to prevent rejection of splenic homografts for several months, judged from the anatomic and histologic characteristics of the chronically transplanted tissue. Furthermore, they defined the experimental circumstances in which splenic homotransplantation acted to the detriment of the host, and the means by which these deleterious effects could be prevented or reversed. These authors, as well as Fiscus and his associates, demonstrated a presumed graft-versus-host reaction which was characterized by an acute hemolytic process in those animals treated

with total body irradiation. In animals treated with azathioprine autohemolysis did not occur.

*Donor-recipient relationships and selection.* In the group of patients having carcinoma (Table 8), each recipient received a spleen from another patient who also had terminal malignancy (Fig. 19). The prospective donor was injected subcutaneously, 12 to 56 days before transplantation, with nonviable tumor cells from the recipient, the inoculum being suspended in a mixture of complete (0.5 ml.) and incomplete (3.5 ml.) Freund's adjuvant. A booster dose of the same suspension was given 3 to 21 days preoperatively with a mixture of 2 cc. complete and 2 cc. incomplete adjuvant. The series was open-ended (Fig. 19) so splenic but not host sensitization would be produced. The first patient did not, therefore, have removal of his own spleen, and the final patient did not receive a transplant. ABO blood types were identical in all pairs except Case 4 in which the direction of tissue transfer was from O+ to A+ (Table 8).

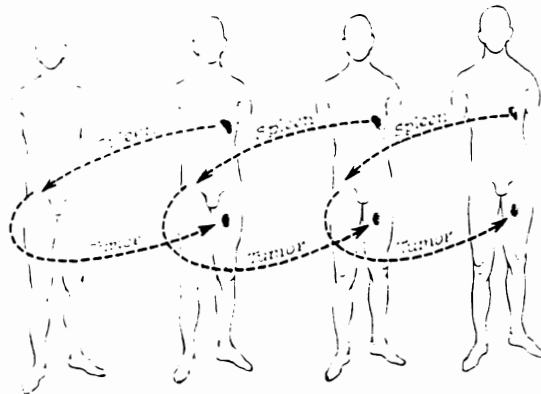
The 12 year old child with hypogamma-

FIG. 18



(Case 5). Reticulum of liver shows good preservation of stroma. Silver stain, X 80.

FIG. 19

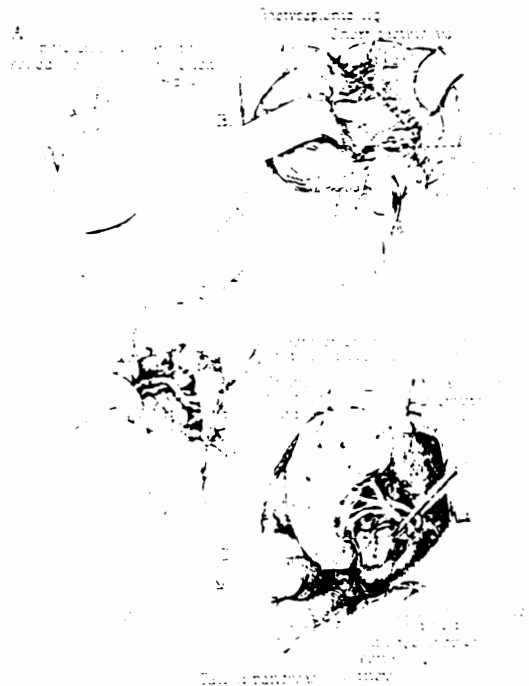


Experimental procedure in patients with disseminated malignancies who were treated with splenic homotransplantation. Note that the donor is sensitized with the recipient's tumor in each case. (See text for details.)

globulinemia received a spleen from his 32 year old mother, both being of A<sub>2</sub> Rh+ blood type. In 15 subgroups there were four differences, the child having C+, S+, K+ and Fy<sup>a</sup>- and the mother C-, S-, K- and Fy<sup>a</sup>±.

*Technic of operation.* The donor operation was performed through a thoracoabdominal incision with division of the diaphragm (Fig.

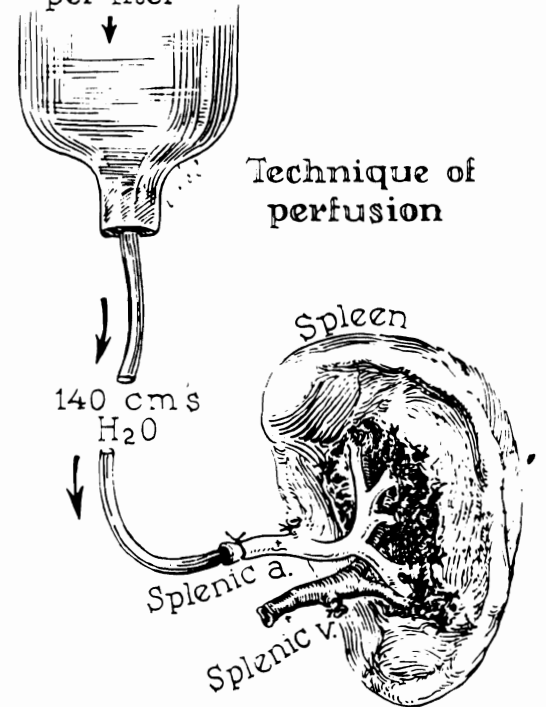
FIG. 20



Details of removal of spleen from the donor. The gastrosplenic ligament is divided separately, allowing skeletonization of the central splenic vessels.

FIG. 21

Lactated Ringers 15°c.  
50mqm heparin + 1 gram procaine per liter



Technique of perfusion

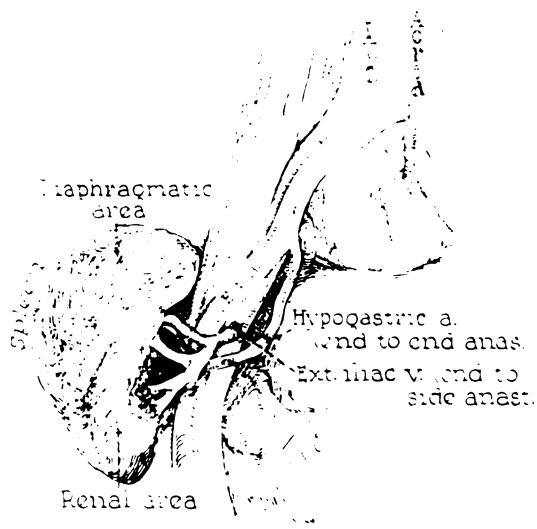
Method of infusion of the splenic homograft with cold solution after its removal from the donor patient.

20,A). The gastrosplenic ligament was divided (Fig. 20,B). The splenophrenic, splenorenal, and splenocolic ligaments were then incised. The splenic artery and vein were skeletonized (Fig. 20,C and D), and the spleen removed upon a signal from the recipient room.

Immediately after excision, the spleen was flushed by infusion with cold lactated Ringer's solution to which heparin and procaine chloride had been added (Fig. 21). In two cases, difficulty was encountered with the infusion, and it was terminated before the venous effluent had become clear.

Transplantation was carried out to the right iliac fossa, through an oblique right lower abdominal extraperitoneal incision, thereby reversing the normal anteroposterior relationships of the spleen. Vascular continuity was restored by anastomosis of the splenic to the hypogastric artery and end-to-side connection of the splenic vein to the external iliac vein (Fig. 22). Two of the spleens had small capsular tears which were closed with

FIG. 22

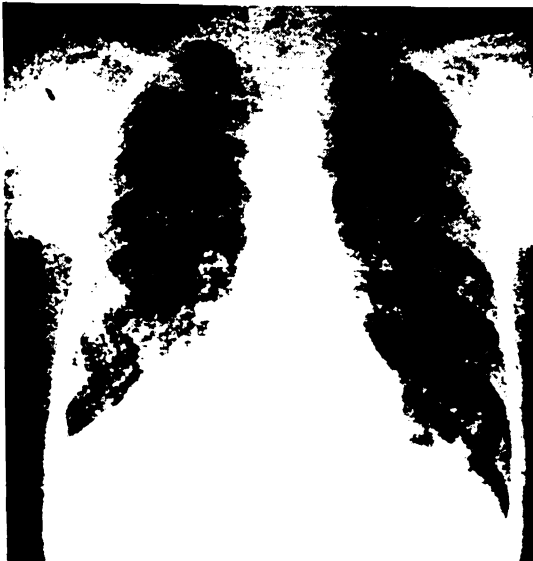

Technic of transplantation of the spleen. The spleen is placed in the right iliac fossa and the anteroposterior relationships of splenic surface and the pedicle are reversed, the former raw area of the splenic capsule now being directed anteriorly. The hypogastric artery and external iliac vein are used for the anastomoses.

continuous fine silk. The transplants fit comfortably in the extraperitoneal space and wound closure was carried out without difficulty.

*Postoperative hypersplenism.* In two patients transient hypersplenism was observed (Cases 2 and 5). The principal evidence for

FIG. 23



(Case 5). Preoperative chest x-ray of a 12 year old child with hypogammaglobulinemia shows atelectasis of both lower lobes. Since operation, the radiographic appearance of the chest has not changed materially.

this was shortening of the survival time of red cells to a half-life of nine and four days respectively. In these two cases, six and one transfusions respectively were required after operation because of excessive drops in hematocrit. An illustrative case follows:

**Case 5.** (Colo. General Hosp.) A 12 year old, white boy with congenital hypogammaglobulinemia received a splenic homograft from his 32 year old mother on June 28, 1963. He had had recurrent pulmonary infections, necessitating continuous hospitalization for 18 months prior to operation. X-ray studies revealed bilateral bronchiectasis of the lower lobes and atelectasis (Fig. 23). For five years he had been given gamma globulin 18 ml. intramuscularly every 20 to 30 days. One year before operation this treatment had been withdrawn temporarily and the gamma globulin level, which had been maintained at approximately 200 mg.%, dropped to 80 mg.

Within 24 hours after operation, his temperature rose to 40.2° C.; there was tenderness at the site of transplant. Sixty mg. per day of prednisone was instituted in addition to the basic regimen of 3 to 6 mg. per kg. per day of azathioprine, which had been started preoperatively. Immediate defervescence occurred with improvement in the tenderness of the wound.

Cr<sup>51</sup> red cell half-life, which had been 21 days preoperatively, was tested one week after operation and found to have fallen to four days. By 17 days after operation, the PCV. had dropped from 32 to 20%,

FIG. 24



Case 5). Scintigram shows concentration of radioactivity in the patient's own spleen (upper right) and in the splenic homograft (lower left). The examination was done 30 days after the homotransplantation operation.

FIG. 25



Scintogram of abdomen three months after splenic homotransplantation. Note concentration of radioactivity in the child's own spleen (upper right), with greatly diminished activity in the transplant (lower left).

necessitating transfusion with 1 unit of blood. Beginning seven days postoperatively, plasma hemoglobin was elevated to a high of 5 mg.%. A spleen scan 30 days postoperatively revealed concentration of radioactivity, both in the child's own and in the transplanted spleens (Fig. 24). After one month, evidence of hypersplenism had disappeared, and repeat determinations of red cell survival and plasma Hgb. performed 6 and 12 weeks after operation were normal. A follow-up spleen scan on September 24 did not reveal sequestration of radioactivity at the transplant site (Fig. 25).

By the 14th postoperative day, the gamma globulin had risen from its preoperative level of 250 to 600 mg. Gamma globulin remained above 300 mg.% for 96 days after operation with a subsequent fall to 200 to 300 mg.%. No exogenous gamma globulin has been administered since operation. Therapy has been continued until the present time with 2 to 4 mg. per kg. per day of azathioprine and with diminishing doses of prednisone (now 20 mg. day). The child had a severe bout of pneumonitis in mid September and early October 1963. Except for these episodes, he has been clinically well. The spleen is palpable and of approximately the same size as in the early postoperative period.

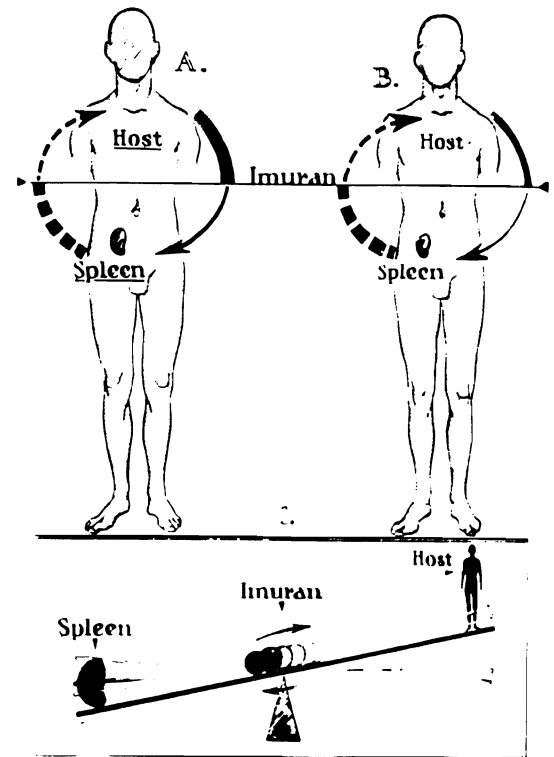
In the third case, in which an extremely severe and persistent autohemolytic reaction

occurred, the spleen was donated by an O+ patient to an A+ recipient:

**Case 4.** (Denver V.A. Hosp.) A patient with disseminated gastric carcinoma received a splenic homotransplant on May 28, 1963. Twelve hours after operation his temperature rose to 41° C. Prednisone was immediately added to the previously instituted regimen of azathioprine. Incomplete defervescence resulted. Two days later, a rapid fall in hematocrit was noted. Studies of red cell survival were rendered inaccurate by the need for repeated transfusions at this time, but the rate of disappearance was extremely rapid. Hemolytic jaundice, with a peak serum bilirubin of 24 mg. developed. Splenomegaly of the transplant, thrombocytopenia of 24,000 platelets, and leukopenia to as low as 800 per cu. mm. completed the picture. Ten days after transplantation, while being prepared for re-exploration and removal of the homograft, the patient aspirated and died.

*Immunosuppressive therapy.* In contrast to renal or hepatic homografts, the prevention or treatment of rejection in splenic transplants is complicated by the fact that no precise measure of function can be followed. In animals and in man the development of an acute febrile illness accompanied by local tenderness at the transplant site is the only clinical index of rejection. These findings were pres-

FIG. 26



Schematic depiction of a possible balance between the graft and the host in the patients with splenic homotransplantation. (See text for details.)

ent in all five patients, occurring at an early time after operation. The fever was immediately reversed in all but Case 4 by the addition of prednisone to the basic therapy with azathioprine. In the child with hypogammaglobulinemia it was possible to follow the level of serum gamma globulin, but since the half-life of this protein fraction is 30 to 60 days the significance of change is of little immediate value. Accordingly, therapy was provided more or less empirically, using the general scheme which has evolved from experience with renal homotransplantation. Initial therapy was provided with azathioprine, and prednisone and actinomycin C added when rejection was inferred from the presence of fever and local transplant tenderness.

In the treatment of other organ homografts, doses of azathioprine are generally pushed to the highest levels which are possible without depressing the white blood count. With spleen homografts such a regimen has been shown by Marchioro and his associates in dogs to prevent or mitigate autohemolysis. The mechanism of this effect may be explicable on the basis depicted in figure 26. The immunosuppressive therapy undoubtedly acts both on the graft and also upon the host, thereby possibly attenuating not only the standard rejection process but upon a graft-versus-host reaction as well. With proper manipulation of




FIG. 27

A. S. 21 FEB 1963

(Case 1). Preoperative chest x-ray of splenic homotransplantation. The patient had a histologically proven diagnosis of alveolar cell carcinoma of the lung by biopsy from the left lower lobe. Note also small lesions on the right side.

FIG. 28



A. S. 24 OCT 1963

Same case as figure 27. Patient had received splenic homotransplantation eight months previously. Note that the pulmonary lesions have progressed in size and number.

the dosages, a balance between host-versus-graft and graft-versus-host reactions might thus be obtained.

*Effect of splenic homotransplantation on disseminated carcinoma.* No objective evidence could be obtained that the course of the neoplasia was altered in any way. The inexorable terminal courses of Cases 2 and 3 were unmodified. The long survival of Case 1 was exceptional. Nevertheless, the pulmonary lesions which were present before operation have progressed (Figs. 27 and 28). The terminal course of Patient 4 was obviously accelerated by the superimposition of an acute autohemolytic process.

*Effect of splenic homotransplantation on hypogammaglobulinemia.* As recounted in the section on hypersplenism, there appeared to be an early increase in serum gamma globulin level in Case 5. This was accompanied by collateral evidence of splenic activity, manifested principally by hypersplenism. The increase in serum gamma globulin level apparently lasted for approximately three months. During this time, the child gained 35 pounds and was free of infection. Subsequently a progressively falling gamma globulin and recurrence of pulmonary infections have been observed, suggesting loss of functional activity

of the homograft. It should be noted, however, that Rifkind and his associates have demonstrated that an immunosuppressive regimen similar to that employed for this child can result in and of itself in striking depression of serum gamma globulin. Thus, the treatment employed could conceivably defeat the purpose of the operation.

*Pathologic material.* Three patients died 11 days (Case 4), 2 months (Case 3), and 3 months (Case 2) after transplantation. All major vessels were patent.

The homograft in Case 4 weighed 1,000 Gm., and was reddish-brown except for scattered yellowish necrotic areas. Microscopically, congestion and hemorrhage were present throughout. The remaining cords of Billroth were thickened and the cellular elements stained poorly. The white pulp was markedly reduced and all that remained were thin mantles of lymphocytes surrounding splenic arterial branches (Fig. 29). Erythrophagocytosis was not prominent.

In the homografts obtained two and three months after transplantation, alterations were severe. The organ of Patient 3 weighed 400 Gm. and was extremely firm. Microscopically, the parenchyma was almost entirely replaced by hemorrhage and necrosis. In only a very few areas were small numbers of red cells and fragments of viable stroma seen. White pulp was totally absent.


The spleen obtained at autopsy three

FIG. 29



(Case 4). Splenic homograft at autopsy 10 days after operation. There is virtual disappearance of the white pulp; there is an area of necrosis in the upper left portion of the field (H & E, X 32).

FIG. 30



(Case 2). Splenic homograft at autopsy. There are small numbers of lymphocytes and other mononuclear cells. A relatively amorphous and fibrotic pattern characterized the microscopic picture (H & E, X 32).

months after implantation in Case 2 weighed 240 Gm. and had a very firm consistency. Microscopically, broad bands of fibrous connective tissue replaced large amounts of the parenchyma (Fig. 30). Scattered throughout were small patches of hemorrhage and aggregates of lymphocytes (Fig. 30). White pulp was not identified.

*Critique.* The results must first be viewed in light of the fact that effective prevention of homograft rejection was apparently not accomplished in at least three of the five cases, and perhaps in all. The homograft specimens obtained at autopsy in the three patients with terminal malignancy retained gross characteristics of spleen, but microscopic study showed parenchymal destruction so extensive that it is difficult to conceive of functional integrity of these organs.

Therefore, it must be conceded that the initial objectives of these trials cannot be evaluated. Whether the concept is valid that a specific graft-versus-host reaction can be directed against tumor tissue must await the development of a more predictable and effective way of treating homograft rejection. Similarly, the single case in which homotransplantation was attempted for treatment of hypogammaglobulinemia may have failed for the same reason. In the last case, a much longer follow-up period will be necessary before final judgment can be rendered concerning the efficacy of this means of therapy.



*Addendum*—(December 18, 1964). In the 13 months since submission of the manuscript, more meaningful follow-ups have become available in a number of cases.

Both patients who received renal homografts (isografts) from identical twins remain well, 33 and 18 months postoperative. In November 1963, 26 of the 38 patients who received true homografts from volunteer donors were still alive 1 to 12 months postoperatively. In December 1964, 18 of these 26 patients are still alive, survival now ranging from 13 to 25 months. The principal additional attrition has been in those patients treated with kidneys from nonrelated sources.

Serial studies of the gamma globulin in Patient 5 of the spleen series were subsequently done by Dr. Hugh Fudenberg of the University of California, San Francisco, using a gamma globulin typing method which can identify the source of this protein. Gamma globulin

from the material spleen could not be found in the recipient patient's serum at any time after operation. Failure of the objective of this operation, which was implied in the text of the manuscript, has, therefore, been subsequently proved. The patient is still alive, having since received bilateral lower pulmonary lobectomy.

Patient 1 of the spleen series died in November 1964, of disseminated carcinomatosis. All immunosuppression had been discontinued approximately one year previously. The residual splenic tissue was a fist-sized mass of connective tissue. The splenic artery and vein were obliterated.

#### References

*Selected references will appear in the authors' reprints.*

---

## FILMS AVAILABLE ON TRAINING OF A PHYSICIAN

The challenges of the medical profession are limitless, and the rewards are great. But what of the difficult years of study, the years of hard work, the years of training that go into molding tomorrow's physicians?

The inspiring and revealing story of the rigorous effort, the constant pressure, and the mounting drama that face the aspiring doctor of tomorrow and the practicing physician of today is told in a penetrating 3-part film series, "The Making of A Doctor," sponsored jointly by the American Medical Association, Southern Medical Association, the Student American Medical Association, and Merck Sharp & Dohme.

The films, available singly or as a series, may be secured on loan without charge from Southern Medical Association, 2601 Highland Avenue, Birmingham, Alabama 35205.