

# Pseudotumors Due to Pulmonary Infarction

T. E. STARZL, M.D., ROBERT S. BRITTAIN, M.D.,  
GILBERT HERMANN, M.D., THOMAS L. MARCHIORO, M.D. AND  
WILLIAM R. WADDELL, M.D.

*Denver, Colorado*

## The American Journal of Surgery

This article reprinted from the Oct. issue, volume 106, number 4, pages 619-627,  
copyright 1963. Published by *The Reuben H. Donnelley Corporation*,  
466 Lexington Avenue, New York 17 and printed in the U.S.A.

# Pseudotumors Due to Pulmonary Infarction\*

T. E. STARZL, M.D.,† ROBERT S. BRITTAIN, M.D., GILBERT HERMANN, M.D.,  
THOMAS L. MARCHIORO, M.D. AND WILLIAM R. WADDELL, M.D., Denver, Colorado

From the Department of Surgery, University of Colorado Medical Center, Denver, Colorado. Aided by Grants A-3176, A-6344 and A-6283 from the United States Public Health Service.

ONE OF THE UNCOMMON consequences of pulmonary infarction, due either to an embolus or thrombosis, is the development of a mass in the pulmonary parenchyma. If the diagnosis is certain, the appropriate treatment is usually nonsurgical. Under some circumstances, however, thoracotomy may be necessary to establish the diagnosis. In rare instances, pulmonary resection may prove to be an advisable form of therapy.

The purpose of the present report is to document experience with five patients who had organizing pulmonary infarction (Fig. 1) in whom carcinoma was suspected prior to surgery. A diagnosis of pulmonary infarction was established only after thoracotomy. In retrospect, the diagnosis could have been made without surgery in some patients. In others, the location and radiographic appearance of the infarcts, the absence of peripheral venous disease, and the background of general good health directed attention away from preoperative consideration of this possibility. The result of resection, and in one patient, pulmonary endarterectomy, was complete relief of the presenting symptoms. No recurrent postoperative infarctions occurred, despite the fact that prophylactic therapy was not given in four of the five patients after the diagnosis was established.

## CASE REPORTS

**CASE 1.** (Lutheran Deaconess Hospital, Chicago, No. 37165.) A fifty-four year old man was admitted on July 15, 1961, because of hemoptysis.

His past health had been excellent, with no history of cardiovascular or pulmonary disease, or trauma. Auscultation revealed diffuse rales bilaterally, most marked in the upper part of the right lung. There were varices of both legs but no swelling, calf tenderness, or superficial phlebitis. Chest roentgenograms, laminograms and bronchograms revealed a ground-glass density in the posterior segment of the upper lobe of the right lung. (Fig. 2.) Sputum smear and culture for acid fast bacilli were negative. Skin tests were negative. Electrocardiogram was within normal limits. Cytologic studies of sputum and bronchial washings showed no malignant cells.

Unabating hemorrhage continued until operation, two weeks after admission. Despite four transfusions, the hematocrit fell from 42 per cent to 33 per cent, and hemoglobin from 14.5 gm. per cent to 10.5 gm. per cent. On July 19 bronchoscopic examination was performed. It was determined that bleeding was localized to the right

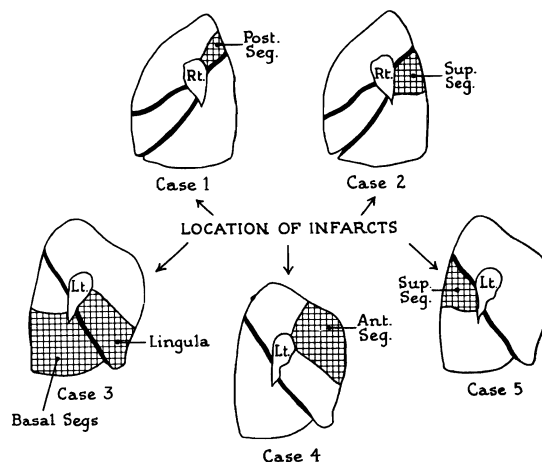


FIG. 1. Location and extent of the pulmonary infarcts in five cases, viewed from the hilar surfaces of the right (Cases I and II) and left (Cases III, IV and V) lungs.

\* Presented at the Fifteenth Annual Meeting of the Southwestern Surgical Congress, Mexico, D. F., April 22-25, 1963.

†Markle Scholar.

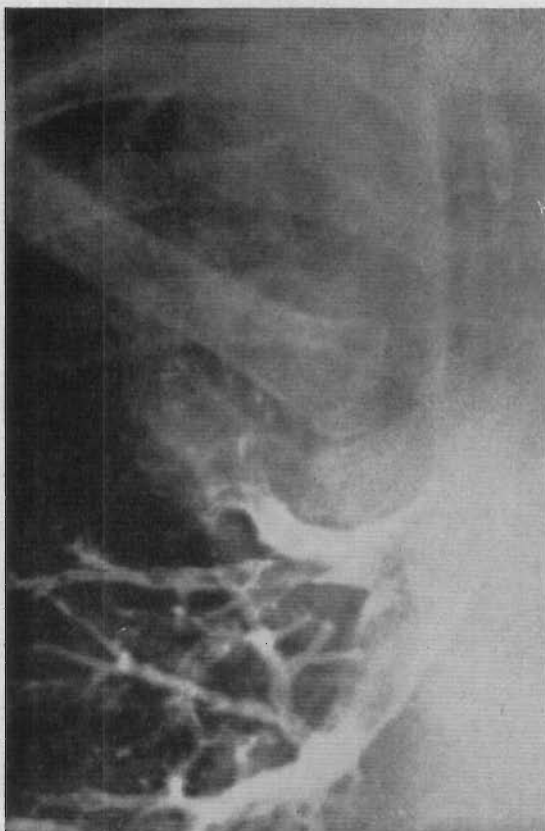


FIG. 2. Hazy density in the upper lobe of the right lung (Case 1). The patient had an infarct of the posterior segment of the upper lobe of the right lung with unremittent hemoptysis.

side but the loss of 400 cc. of blood during the procedure prevented more detailed observation. Bronchogenic carcinoma was considered the most likely preoperative diagnosis. On July 28, 1961, a lobectomy of the upper portion of the right lung was performed. Continuing hemorrhage complicated anesthesia until occlusion of the bronchus of the upper lobe. Convalescence was rapid and uncomplicated and the patient was discharged on August 7, 1961. One year later he was asymptomatic and in excellent health.

*Pathologic Findings.* The posterior segment of the upper lobe of the right lung was collapsed, firm and purple. The bronchi were filled with dark clotted and nonclotted blood. When the lung was cut, a hemorrhagic area was seen with a 5 by 5 by 5 cm. necrotic center. Histologic section showed destroyed architecture in the central part of the infarct with surrounding atelectasis. The alveoli were filled with blood and macrophages. One of the larger pulmonary vessels contained a fresh thrombus which had not been recognized grossly. The pathologic diagnosis was hemorrhagic infarct

of the lung with secondary atelectasis and local pneumonitis.

*Comment.* Despite a preoperative diagnosis of carcinoma of the upper lobe of the right lung, the final pathologic diagnosis was pulmonary infarction. An embolus was not found in the pulmonary artery, but histologic evidence of recent thrombosis was noted. This was thought to be the only case in which embolus was not the cause of infarction. Resectional therapy became mandatory in this patient because of unremitting hemorrhage.

**CASE II.** (Massachusetts Memorial Hospital, Boston, No. 364651.) A seventy year old man was admitted on March 7, 1953, for the treatment of a "lung tumor." He had been in good health until June 1952, at which time he was involved in an automobile accident, sustaining a cerebral concussion, multiple rib fractures on the left, and a left hemothorax which required multiple thoracenteses. During the ensuing nine months, he lost forty-five pounds. In January of 1953, he had been readmitted to another hospital for repair, first of a left inguinal hernia, and then a left femoral hernia two weeks later. On February 12, 1953, thirteen days after repair of the second hernia, pain developed in the lower part of the right portion of the chest with hemoptysis, and low grade fever. There was no evidence of peripheral thrombophlebitis. He recovered from this, but after discharge a roentgenogram revealed a mass in the right lung.

Upon admission to Massachusetts Memorial Hospital, the physical examination was essentially normal except for enlargement of the prostate. There was no evidence of peripheral thrombophlebitis, or of heart failure. Chest roentgenograms and laminograms revealed an ill-defined density in the superior segment of the lower lobe of the right lung. (Fig. 1.) The lesion appeared to be dense with a central radiolucent shadow. Bronchoscopy and electrocardiogram were within normal limits.

Prior to surgery, the diagnostic possibilities were thought to be carcinoma, chronic lung abscess or pulmonary infarct. Lobectomy of the lower part of the right lung was performed on March 19, 1953. When the pulmonary artery to the lower lobe was transected, a small thrombus within the vessel was encountered. Upon pathologic confirmation of the diagnosis of pulmonary infarct, bilateral superficial femoral vein ligation was performed two days later on March 21, 1953. Convalescence was uncomplicated and the patient was discharged on April 3, 1953.

*Pathologic Findings.* The specimen consisted of a lower lobe in which all segments except the superior were well aerated. The superior segment

## Pseudotumors

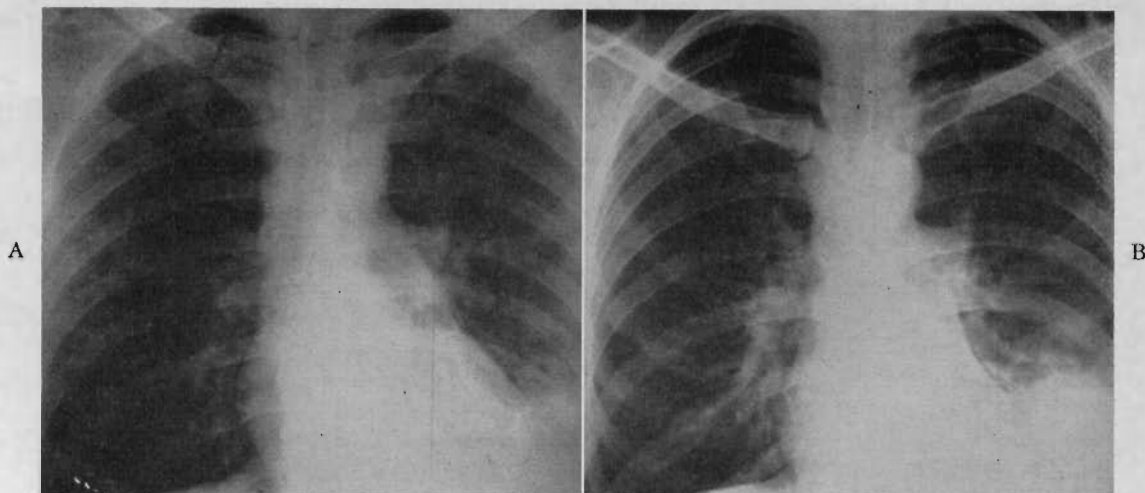


FIG. 3. Roentgenogram of chest (Case III): A, at admission, and B, three weeks later. Note increase in size of density.

was atelectatic with a central, well-circumscribed, firm mass measuring 3 by 5 cm. On section, the mass showed dark, reddish-green areas in which no pus was found. In the pulmonary artery, there was a completely occluding thrombus measuring 2.5 cm. which began at the level of the superior segmental artery. The bronchi were normal. Microscopic findings were typical of pulmonary infarction of four to six weeks' duration.

*Comment.* This patient had a clinical course consistent with pulmonary infarction due to embolus. Eight months prior to operation he had been involved in a serious accident and two months previously he had had elective surgery which had been complicated by a bout of postoperative hemoptysis. Possibly a period of observation would have been justified in this patient, thereby avoiding thoracotomy if resolution of the lesion had occurred. The atelectatic appearance of the infarcted lung and surrounding parenchyma at operation was a consistent findings in all five cases.

CASE III. (Denver VAH, No. A-10030.) A thirty-six year old white man was admitted because of intermittent cough, hemoptysis and fever of one month's duration. Except for a temperature of 99.4°F. and dullness at the left base posteriorly, the physical examination was within normal limits. White blood cell count was 19,200 per cu. mm. with a shift to the left. Hematocrit was 44 per cent. Electrocardiogram was within normal limits. Sputum cultures revealed moderate numbers of *D. pneumoniae*. Smears and culture for acid fast bacilli were negative. Skin tests were negative.

Chest roentgenograms at admission revealed an infiltrate in the lower part of the left lung with a small pleural effusion. (Fig. 3A.)

The initial impression was pneumonia in the lower lobe of the left lung. The patient was treated with penicillin and streptomycin and became afebrile after three days. However, chest roentgenograms showed increasing consolidation in the lower lobe of the left lung (Fig. 3B) during the ensuing three weeks. Two thoracenteses yielded serosanguineous fluid, which on cytologic examination contained no tumor cells. A small, raised, granular area was at the beginning of the bronchus from the lower lobe of the left lung. A biopsy specimen at bronchoscopic examination showed chronic inflammatory tissue. Cytologic studies of the sputum obtained at bronchoscopy were negative for malignant cells. An azygogram was within normal limits. Bronchogenic carcinoma was suspected.

At thoracotomy the basilar segments of the lower lobe of the left lung and the inferior lingular segments were atelectatic. The hilum was free of adenopathy. The pulmonary artery in the fissure contained organized thrombus which extended proximally. (Fig. 4.) After obtaining control of the artery, the thrombus was removed under direct vision. (Fig. 4.) The basilar and inferior lingular segments were then excised. Convalescence was uncomplicated. Eight months postoperatively, angiographic studies revealed patency of the remaining branches of the left pulmonary artery.

*Pathological Findings.* The specimen consisted of segments of the lingula and the lower lobe of the left lung, and an embolus from the left pulmonary artery. The pleural surface was purple-white with some small elevated fibrin patches. One 8 mm. pulmonary artery in the specimen

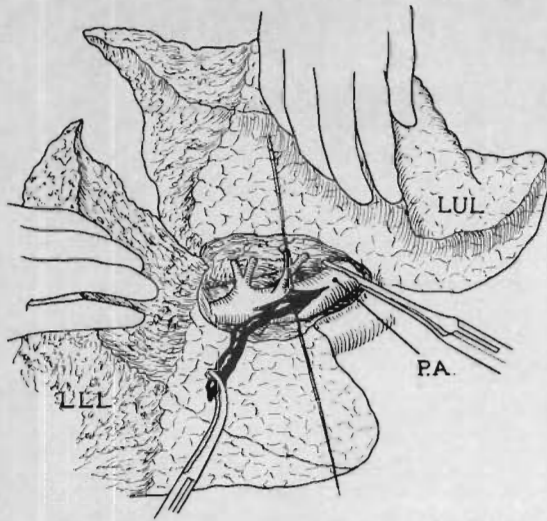


FIG. 4. Pulmonary endarterectomy in Case III. Note organized embolus extending into proximal pulmonary artery.

contained a yellow-tan friable blood clot. On microscopic examination, this thrombus was attached to the wall of the pulmonary artery by dense fibrous tissue. The bronchus showed squamous metaplasia. Many portions of the lung showed fibroblastic invasion of the alveoli and organization. There was thickening of the pleura by granulation tissue.

*Comment.* In retrospect, thoracotomy could have been avoided in this patient. The history and the roentgenographic findings were consistent with the diagnosis of pulmonary infarc-

tion despite the absence of a detectable peripheral thrombotic focus. It is probable that multiple pulmonary embolizations had occurred prior to admission. The embolus in the left pulmonary artery was well organized and adherent to the wall by the time of operation and required thromboendarterectomy for removal.

CASE IV. (Denver VAH, No. A-11391.) A fifty-one year old white man was admitted shortly after the sudden onset of pleuritic pain in the lower posterior part of the right lung. There was no history of fever, chills or peripheral phlebitis. Eighteen months prior to admission, a chronic cough productive of greyish yellow sputum had developed, which at times had been streaked with blood. He had lost approximately fifteen pounds, but had continued to work. In the past, he had had pneumonia on several occasions but a chest roentgenogram, two years prior to admission, was within normal limits. The patient had smoked one package of cigarettes a day for forty-one years. On physical examination, the lungs were clear. There was no evidence of heart failure. Chest roentgenograms showed a diffuse infiltrate in the lower lobe of the right lung suggesting pneumonitis. In the anterior segment of the upper lobe of the left lung, an area of increased density was noted. (Figure 5A.) The clinical impression was pneumonitis of the lower lobe of the right lung with possible carcinoma of the upper lobe of the left lung.

The infiltrate in the lower lobe of the right lung had completely cleared in three days, but the opacity in the mid-portion of the left lung field

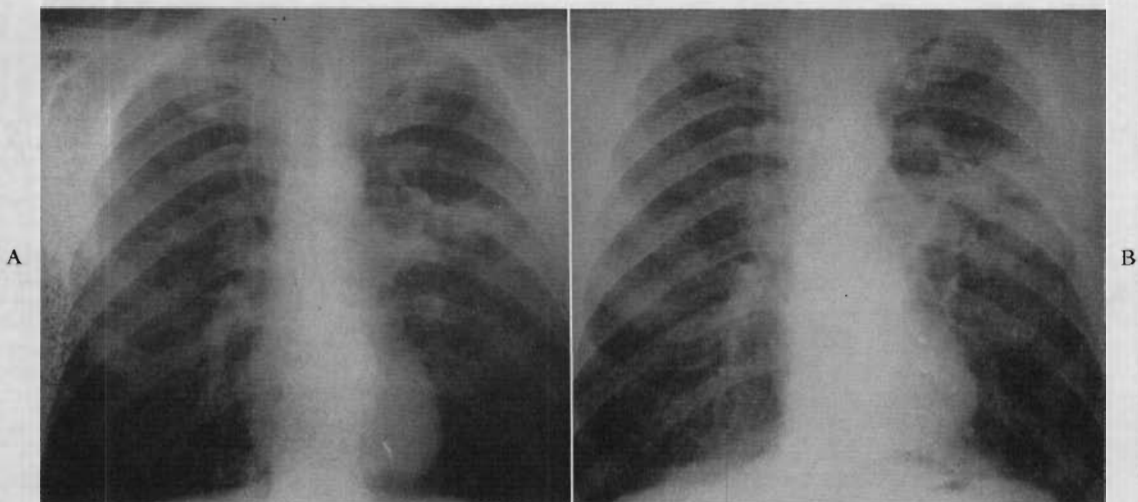


FIG. 5. CASE IV. A, one week after admission, and B, four weeks after admission. Note increase in size of density.

## Pseudotumors

persisted. Laminograms of this area showed equivocal central cavitation. The mass appeared to enlarge during the ensuing several weeks. (Figure 5B.) Bronchograms showed no filling of the upper division of the bronchus to the upper lobe of the left lung. Bronchoscopy was unremarkable and cellular studies of the bronchial secretions did not suggest tumor. A bilateral scalene node biopsy was negative. Electrocardiogram was within normal limits. Bronchogenic carcinoma was considered the most likely diagnosis.

At thoracotomy, extremely dense apical adhesions were found. The anterior segment of the upper lobe of the left lung was atelectatic. It was firm, non-nodular, and did not have the gross appearance of carcinoma. A frozen section biopsy specimen obtained from this area and from hilar lymph nodes revealed inflammatory tissue. The left main pulmonary artery was 3 cm. in diameter. Old pulmonary infarction was considered the most likely diagnosis and the anterior segment of the upper lobe of the left lung was removed. Postoperatively a bronchopleural fistula developed, which required thoracoplasty. He did not have recurrent pulmonary emboli. There was never any evidence of peripheral thrombophlebitis.

*Pathologic Findings.* The specimen consisted of a single segment of the upper lobe of the left lung which was noncrepitant and covered with shaggy purple pleura. Cut section revealed a yellow-tan, nonaerated parenchyma. Microscopic section revealed compressed parenchyma which was replaced by large bands of collagen. No granulomas were seen. Many macrophages were present in the fibrous tissue and alveolar septa. No sizable blood vessels were apparent in this specimen. The pathologic diagnosis was pulmonary infarction.

*Comment.* This patient had an expanding mass in the left lung. Symptoms, while compatible with pulmonary infarction, were consistent with a diagnosis of carcinoma of the lung. Fortunately, the benign nature of the lesion was recognized at operation and he was treated with a conservative procedure. As in the other patients, there was atelectasis of the involved lung with a central area of necrosis. Of interest at surgery was the huge size of the pulmonary artery despite the fact that infarction was confined to a single segment.

CASE V. (Denver VAH, No. A-14136.) A twenty-three year old white man had a mass-survey chest roentgenogram on August 13, 1962. A soft 2 cm. density was detected in the upper part of the left lung. (Fig. 6.) He was admitted five days later for diagnosis and treatment. He had

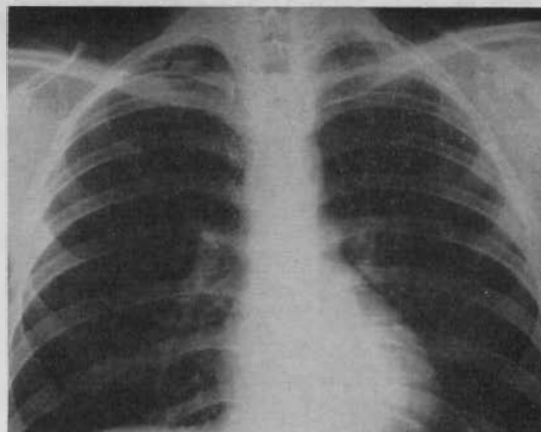


FIG. 6. CASE V. Density noted in upper lobe of the left lung was detected with routine roentgenogram of the chest.

been in poor health since 1960 with ulcerative colitis, treated by total colectomy in February, 1961. The postoperative course was complicated by a femoral embolus. On physical examination, the patient was a well developed, thin, white man in no distress. The lungs were clear to percussion and auscultation. The heart was within normal limits. Examination of the extremities revealed that the left leg was greater in circumference than the right. Good pulses were noted in both extremities, and there was no tenderness.

Skin tests for blastomycosis, coccidioidomycosis, histoplasmosis and tuberculosis were negative. An electrocardiogram revealed right axis deviation. Repeat roentgenograms of the chest on August 24, 1962, and September 5, 1962, revealed no change in the lung density. Laminograms showed an irregular density with poorly defined borders, containing no calcium. Gastric washings, sputum cultures and three urine cultures for acid fast bacilli, which had been obtained upon admission, revealed no growth.

On September 10, 1962, a wedge resection of the lesion of the superior segment of the lower lobe of the left lung was performed. The postoperative course was benign and the patient was discharged on the tenth postoperative day.

*Pathological Findings.* The specimen consisted of a 3 by 5 by 6 cm. wedge of pulmonary tissue containing an indistinct firm mass in the center. On cut section, the mass was homogenous and tended to blend with the surrounding pulmonary tissue. Microscopic examination revealed scattered areas of acute and chronic inflammatory cellular infiltration throughout a dense fibrous stroma. There was no evidence of neoplastic tissue in the specimen although a few tiny clusters of metaplastic squamous cells were noted. The pathologic diagnosis was old pulmonary infarction.

*Comment.* This patient had no symptoms of an old or recent pulmonary infarct. Perhaps the history of an arterial embolus, and the asymmetry of the legs should have directed attention to this diagnostic possibility. Lack of a diagnosis prompted thoracotomy.

COMMENTS

Occlusion of the pulmonary artery or its various branches does not ordinarily produce infarction in experimental animals [1-5]. Similarly there is considerable evidence in man that occlusion of a major pulmonary artery by ligature, embolus, or by primary thrombus formation, does not by itself cause necrosis of pulmonary parenchyma [6-8]. Viability of the involved lung is probably maintained by the bronchial artery circulation which undergoes rapid and extensive collateral enlargement [1-5].

Since concomitant occlusion of the pulmonary and bronchial arterial systems is rare, clinical pulmonary infarction must involve other factors. The most common of these is impaired venous outflow from the lungs, as exemplified by congestive heart failure. Other conditions which have been described as promoting infarction in the presence of pulmonary arterial occlusion are pleural effusion, bronchial obstruction, atelectasis, pneumonia and shock [7,8]. In addition, there is a small but definite group of patients in whom simple pulmonary arterial occlusion to all or part of the lung results in frank infarction despite the absence of other recognizable contributory influences. The cases presented in the present study are examples. All five patients were active persons until the onset of their acute illness. In no case was there any detectable remote, immediate or subsequent evidence of cardiac or chronic pulmonary disease.

In a typical case of pulmonary infarction, the clinical features are characteristic [7,9]. The cardinal symptoms are pleuritic pain, hemoptysis and fever. Other symptoms, which may be present, are cyanosis, dyspnea and jaundice. Frequently, the patients have had an antecedent chronic illness, a recent surgical operation, or a traumatic accident. A pleural friction rub and radiographic evidence of a pulmonary infiltrate provide strong confirmatory evidence for the diagnosis. The commonest cause of pulmonary vascular occlusion in pulmonary infarction is embolus. If this is the

cause of the infarction, the lower lobes are usually involved, most commonly on the right.

The first four cases in the present series had symptoms or findings which might have been construed as indicating pulmonary infarction. These included hemoptysis, fever, chest pain, pleural rub, weight loss and pleural effusion. Although these features are common with pulmonary infarction, they are also important symptoms and signs of carcinoma of the lung and, hence, are nonspecific. The presence of a pulmonary parenchymal mass on roentgenograms made it difficult to rule out carcinoma. In some cases, pulmonary infarction was initially considered as a strong diagnostic possibility, but persistence and even growth of the mass on repeat roentgenograms of the chest made it difficult to sustain this impression. The location of the infarcts, particularly when the upper lobes were involved (Fig. 1), added to the difficulty of the diagnosis.

Little has been written in the surgical literature concerning the differentiation of pulmonary infarction from other lesions for which surgical intervention is indicated. In 1935, Bigger and Vermilya [10] described a case of an infiltrate in the upper lobe of the left lung in a previously healthy thirty-five year old man who presented with hemoptysis and a 20 pound weight loss of one month's duration. After six weeks, the mass had not changed in size and it was excised. The pathologic report was pulmonary infarction. Recovery was complete. In 1945 Perkins and Bradshaw [11] described two patients with pulmonary infarcts who presented with a history of hemoptysis and who had thoracotomy with the erroneous diagnosis of carcinoma of the lung. Radiographically, there was a coin lesion of the lower lobe on the right in one case, and in the other there was atelectasis of the lateral segment of the middle lobe. The latter patient died of massive recurrent pulmonary embolus four days after resection.

Neville and Munz [12] described an additional two cases with hemoptysis, fever, and chest pain. At the time of resection, relatively fresh infarcts were found, one in the lower lobe of the right lung and the other in the upper lobe of the right lung. Both patients survived and in one evidence of femoral thrombophlebitis subsequently developed. Souchery [13] and Lane [14] each reported a successfully treated case in which the diagnosis was estab-

## Pseudotumors

lished only after lobectomy. The former patient was a twenty-six year old professional ball player who presented with acute hemoptysis and in whom a persisting mass developed in the lower lobe of the left lung. The latter patient was a thirty-nine year old woman with mitral stenosis in whom an asymptomatic mass in the lower lobe of the right lung was detected by roentgenographic examination. In 1960 Arora, Lyons and Cantor [15] described three patients with masses in upper lobes who were treated with resection. Hemoptysis was not prominent in any of these patients. Recurrent embolization did not occur postoperatively. These authors pointed out that approximately 10 per cent of the pulmonary emboli lodge in the upper lobes.

Particularly illuminating is Sharp's recently described case [16]. Lobectomy was performed on a patient with multiple masses in the lower lobe of the right lung, which proved to be organizing infarcts. In retrospect, there was a suggestive history of previous multiple pulmonary embolization during the five preceding months. On the third postoperative day, a massive recurrent embolus lodged in the main pulmonary artery. The patient was saved by emergency pulmonary embolectomy, employing cardiopulmonary bypass.

Pulmonary resection in patients with organizing pulmonary infarcts is usually contraindicated. The infiltrates seen on roentgenograms may consist chiefly of congested tissue, most or all of which may not be destined for necrosis [2,6,17]. The ultimate pathologic residua may be undetectable or consist of minimal scarring which is seen only with close scrutiny or upon microscopic examination. In addition to the fact that operation is usually unnecessary, there are added risks of recurrent embolization in such patients who are subjected to extirpative therapy. This has been well documented in the cases of Perkins and Bradshaw [11] and Sharp [16].

It may be that thoracotomy in some cases of pulmonary infarction is unavoidable or even advisable as will be discussed subsequently. However, a high index of suspicion will prevent unwarranted thoracotomy in many instances. Some of the patients in the present study, as well as others in the literature, have been operated upon despite considerable evidence that the lesion was indeed an infarct. Among the features that should suggest the possibility

of pulmonary infarction are: History of sudden hemoptysis, sudden onset of pleuritic chest pain followed by bloody pleural effusion, lower lobe lesions particularly in association with the above features, the presence of multiple areas of infiltration, radiographic evidence of rapid change of the infiltrate, evidence of recent cardiac or other chronic disease and evidence of peripheral venous thrombosis. If there is a strong index of suspicion, a period of observation and serial radiographic studies are warranted.

In the future, more immediately decisive diagnostic technics may become available employing angiocardiology or blood gas studies, although these methods are as yet developmental. Storey and Jacobs [18] have been able to localize experimental emboli by angiographic methods. Robin and his associates [19] have described a technic for demonstrating increased dead space after embolization in which infarction has not occurred. The method is based on a decreased gas exchange which occurs in the lung parenchyma supplied by an occluded artery, despite continuing ventilation. Expired air has, as a consequence, a reduced carbon dioxide content in relation to the arterial carbon dioxide. The authors believe the method to be useful if the occluded vessels are of lobar or larger size.

Despite all precautions, there will be some patients in whom thoracotomy becomes mandatory for diagnostic purposes because of failure of resolution or actual growth (Cases III and IV) of the mass. To a greater or less degree, all five patients in the present study fall into this category. Under other circumstances, surgical therapy may become the preferred means of therapy, even though the infarction is recognized in advance. Uncontrollable hemorrhage is the most obvious example, as in Case 1. This patient was the only one in the present series in whom a primary pulmonary thrombosis had occurred.

In addition, the delayed sequelae of pulmonary infarction may provide various indications for deliberate surgical intervention, even when the diagnosis is known. In the past, these complications have included empyema [20] and unresolved post-infarction lung abscesses. In the future, it is possible that the reconstructive vascular technics applied elsewhere in the body may have a limited but definite place in the delayed treatment of



pulmonary arterial disease. Hurwitt and his associates [21] have demonstrated the feasibility of placing vascular grafts in the pulmonary arterial system. Bjork and Norhagen [22] reported a case of pulmonary endarterectomy in a patient who had concomitant resection of an upper lobe of the left lung, thereby improving the circulation to the residual lung tissue. Case III is an additional example of this type of therapy in which five infarcted segments on the left were removed. Pulmonary arterial supply to the rest of the lung was restored by means of a pulmonary endarterectomy. The latter achievement, although worthwhile, occurred purely by chance. Before these technics can be applied with predictability, it will be necessary to further standardize angiographic technics for complete and reliable visualization of the pulmonary arterial vasculature.

A special problem in patients who have been found at operation to have pulmonary infarction due to embolus is the prevention of the recurrences in the postoperative period. The cases of Perkins and Bradshaw [11] and Sharp [16] make it apparent that lethal embolization under these circumstances may occur with distressing frequency. In the present series in which four of the five infarcts were thought to be due to emboli, no specific prophylactic therapy was given in the postoperative period except in Case II, chiefly because the sources of the dislodged thrombi were not apparent. The success with which this policy was pursued may have been due to the fact that the infarctions had occurred many weeks or months previously and that the originating thrombotic focus had undergone spontaneous resolution. If thoracotomy is performed soon after embolization, it is probable that vena caval ligation or a vena cava filter procedure [23,24] should be employed as soon as the diagnosis is made. At the moment this policy does not seem routinely indicated when thoracotomy has been performed long after the infarction has occurred.

#### SUMMARY

The preferred treatment of pulmonary infarction is nonoperative when the diagnosis can be established. In the present study, five cases are described in which failure of resolution or growth of a radiographic density resulted in eventual thoracotomy and pulmonary

resection. Carcinoma was suspected in each case, and in one patient, unremitting hemoptysis was an additional indication for operation. It is thought that the infarction was due to an embolus in four patients and to pulmonary arterial thrombosis in the other. Only one of the patients had evidence of peripheral thrombophlebitis, and none had underlying cardiac disease.

The infarcts involved the upper lobes in two patients, the lower lobes in two, and both the upper and lower lobes in one. The benign nature of the process was recognized at operation and conservative resections performed. The typical finding was atelectasis of the involved parenchyma with a central necrotic area. In two patients organizing pulmonary emboli were encountered when transecting the pulmonary arterial supply, and in one of these, pulmonary endarterectomy of the remaining vessel was successfully performed.

The apparent ages of the infarcts ranged from two weeks to several months. After the diagnosis had been established at operation, prophylactic anticoagulant therapy was not given in four patients, and no recurrences were observed. In the fifth, bilateral superficial femoral vein ligation was performed, also with a good result.

*Acknowledgment:* Permission to use Case II was kindly provided by Lamar Soutter of Boston, Massachusetts, who performed the operation. Cases III and IV were done by residents at the Denver Veterans Administration Hospital under the direction of R. K. Brown, M.D.

#### REFERENCES

1. BLOOMER, W. F., HARRISON, W., LINDSKOG, G. E. and LIEBOW, A. A. Respiratory function and blood flow in the bronchial arteries after ligation of the pulmonary artery. *Am. J. Physiol.*, 157: 317, 1949.
2. KARSNER, H. T. and ASH, J. E. Studies in infarction. II. Experimental bland infarction of the lung. *J. Med. Res.*, 27: 205, 1912.
3. LIEBOW, A. A., HALES, M. R., BLOOMER, W. E., HARRISON, W. and LINDSKOG, G. E. Studies on the lung after ligation of the pulmonary artery. II. Anatomical changes. *Am. J. Path.*, 26: 177, 1950.
4. MATHES, M. E., HOLMAN, E. and REICHERT, F. L. A study of the bronchial, pulmonary and lymphatic circulations of the lung under various pathologic conditions experimentally produced. *J. Thoracic. Surg.*, 1: 339, 1931.

## Pseudotumors

5. PARKER, B. M. and SMITH, J. R. Studies of experimental pulmonary embolism and infarction and the development of collateral circulation in the effected lung lobe. *J. Lab. & Clin. Med.*, 49: 850, 1957.
6. HAMPTON, A. O. and CASTLEMAN, B. Correlation of postmortem teloroentgenograms with autopsy findings, with special reference to pulmonary embolism and infarction. *Am. J. Roentgenol.*, 43: 305, 1940.
7. PARKER, B. M. and SMITH, J. R. Pulmonary embolism and infarction: a review of the physiologic consequences of pulmonary arterial obstruction. *Am. J. Med.*, 24: 402, 1958.
8. TORACK, R. M. The incidence and etiology of pulmonary infarction in the absence of congestive heart failure. *Arch. Path.*, 65: 574, 1958.
9. HICKAM, J. B. and SIEKER, H. O. Pulmonary embolism and infarction. *Disease of the Month*. January, 1959.
10. BIGGER, I. A. and VERMILYA, G. D. Aseptic anemic infarct of the lung with sequestration: case report. *J. Thoracic Surg.*, 5: 315, 1935.
11. PERKINS, R. B. and BRADSHAW, H. H. Pulmonary infarction mistaken for bronchogenic carcinoma. *J. A. M. A.*, 151: 545, 1953.
12. NEVILLE, W. E. and MUNZ, C. W. Pulmonary resection (lobectomy) for infarction simulating bronchogenic cancer. *Dis. Chest*, 27: 447, 1955.
13. SOUCHERY, P. H. and O'LOUGHLIN, B. J. Cavitation within bland pulmonary infarcts. *Dis. Chest*, 24: 180, 1953.
14. LANE, L. L., JAMISON, W. L. and MASSEY, F. C. Pulmonary infarct simulating a mass pulmonary lesion in a patient being evaluated for mitral commissurotomy. *Am. J. Surg.*, 87: 921, 1954.
15. ARORA, Y. C., LYONS, H. A. and CANTOR, P. A. Unusual clinical and roentgenographic features of pulmonary infarction. *Am. Rev. Resp. Dis.*, 82: 232, 1960.
16. SHARP, E. H. Pulmonary embolectomy: successful removal of a massive pulmonary embolus with the support of cardiopulmonary bypass. *Ann. Surg.*, 156: 1, 1962.
17. TORRANCE, D. J. Roentgenographic signs of pulmonary artery occlusion. *Am. J. M. Sc.*, 237: 651, 1959.
18. STOREY, W. S. and JACOBS, J. K. Pulmonary embolism and embolectomy. *Tuberculosis*, 20: 111, 1961.
19. ROBIN, E. D., JULIAN, D. G., TRAVIS, D. M. and CRUMP, C. H. A physiologic approach to the diagnosis of acute pulmonary embolism. *New England J. Med.*, 260: 586, 1959.
20. HARVEY, J. C. and SABISTON, D. C. Empyema as a complication of bland infarction: consideration of problem and report of five cases. *Ann. Int. Med.*, 40: 285, 1954.
21. ROBINSON, G., GLOTZER, P., GILBERT, M. and HURWITT, E. S. Aortic homograft replacement of the main pulmonary artery. *J. Thoracic Surg.*, 36: 555, 1958.
22. BJORK, V. O. and NORHAGEN, A. Thrombosis of the pulmonary artery complicating a case of pulmonary tuberculosis. *J. Thoracic Surg.*, 30: 108, 1955.
23. DEWEESE, M. S. and HUNTER, D. C. A vena cava filter for the prevention of pulmonary emboli. *Bull. Soc. Internat. Chir.*, 17: 17, 1958.
24. SPENCER, F. C., QUATTLEBAUM, J. K., QUATTLEBAUM, J. K., JR., SHARP, E. H. and JUDE, J. R. Plication of the inferior vena cava for pulmonary embolism: report of 20 cases. *Ann. Surg.*, 155: 827, 1962.

