

# Journal of Child Neurology

<http://jcn.sagepub.com/>

---

## Early Globus Pallidus Internus Stimulation in Pediatric Patients With Generalized Primary Dystonia: Long-Term Efficacy and Safety

Jan Hinnerk Mehrkens, Ingo Borggraefe, Berend Feddersen, Florian Heinen and Kai Bötzel  
*J Child Neurol* 2010 25: 1355 originally published online 5 May 2010  
DOI: 10.1177/0883073810365369

The online version of this article can be found at:  
<http://jcn.sagepub.com/content/25/11/1355>

---

Published by:



<http://www.sagepublications.com>

Additional services and information for *Journal of Child Neurology* can be found at:

**Email Alerts:** <http://jcn.sagepub.com/cgi/alerts>

**Subscriptions:** <http://jcn.sagepub.com/subscriptions>

**Reprints:** <http://www.sagepub.com/journalsReprints.nav>

**Permissions:** <http://www.sagepub.com/journalsPermissions.nav>


**Citations:** <http://jcn.sagepub.com/content/25/11/1355.refs.html>

>> [Version of Record](#) - Nov 12, 2010

[OnlineFirst Version of Record](#) - May 5, 2010

[What is This?](#)

# Early Globus Pallidus Internus Stimulation in Pediatric Patients With Generalized Primary Dystonia: Long-Term Efficacy and Safety

Journal of Child Neurology  
25(11) 1355-1361  
© The Author(s) 2010  
Reprints and permission:  
sagepub.com/journalsPermissions.nav  
DOI: 10.1177/0883073810365369  
http://jcn.sagepub.com  


Jan Hinnerk Mehrkens, MD<sup>1,\*</sup>, Ingo Borggraefe, MD<sup>2,\*</sup>,  
Berend Feddersen, MD, PhD<sup>3</sup>, Florian Heinen, MD<sup>2</sup>, and  
Kai Bötzel, MD<sup>3</sup>

## Abstract

Primary generalized dystonia presents mainly at a young age and commonly is severely disabling. The authors report the long-term follow-up (mean, 73 months; range, 50-101 months) of 5 pediatric patients (mean age at surgery 13 years; range, 8-16 years) undergoing globus pallidus internus deep brain stimulation. Mean improvement in the Burke-Fahn-Marsden movement score was 67.4% (range, 47.0%-87.5%), 75.4% (range, 61.5%-91.7%), and 83.5% (range, 72.0%-93.3%) at 3 months, 12 months, and long-term follow-up (>36 months), respectively. Hardware problems (electrode dislocation/breakage of extension cable, and imminent perforation of extension cable) were observed in 2 patients (operative revision without sequelae). Except for mild dysarthria in 2 patients, no other therapy-related morbidity was observed. The authors found globus pallidus internus stimulation to offer a very effective and safe therapy in pediatric patients with primary dystonia. Early neurosurgical intervention seems to be crucial to prevent irreversible impairment of motor function.

## Keywords

globus pallidus internus, deep brain stimulation, primary dystonia, long-term outcome

Received January 18, 2010. Received revised February 10, 2010. Accepted for publication February 10, 2010.

Generalized primary dystonia is commonly a severely disabling disease in which affected patients suffer from repetitive twisting movements or abnormal postures due to involuntary muscle contractions.<sup>1,2</sup> Onset is usually around 10 years of age with initial misdiagnosis (especially as psychogenic movement disorder) being common.<sup>3</sup> In contrast to focal and segmental dystonia, in which injections of botulinum toxin can alleviate symptoms for extended periods, conservative (medical) treatment options are very limited.<sup>4,5</sup> In some cases, the chronic intrathecal administration of baclofen via an implanted (programmable) pump may alleviate dystonic muscle cramping of the lower extremities.<sup>6</sup>

In light of this dilemma, the search for effective therapeutic approaches has been ongoing for many years. With the growing implementation of chronic high-frequency deep brain stimulation in the treatment of movement disorders, including dystonia, this neurosurgical procedure has become safer, and control of side effects has widely improved. Over the past years, the globus pallidus internus has been identified as the most promising target in different types of dystonia, and several study groups have presented convincing retrospective (long-term) data using the globus pallidus internus as a target

for deep brain stimulation.<sup>7-14</sup> The efficacy of this approach was further underscored by the data from the prospective controlled studies by Vidailhet et al<sup>15,16</sup> along with the results of the prospective randomized controlled 2-armed study by Kupsch et al.<sup>17</sup> The evidence of the effectiveness of globus pallidus internus deep brain stimulation in dystonia was thus taken to a very high level. However, these studies did not focus on early treatment in children and the associated special

<sup>1</sup> Department of Neurosurgery, Klinikum Grosshadern, Ludwig-Maximilians-University, Munich, Germany

<sup>2</sup> Department of Pediatric Neurology and Developmental Medicine, Dr von Hauner's Children's Hospital, Ludwig-Maximilians-University, Munich, Germany

<sup>3</sup> Department of Neurology, Klinikum Grosshadern, Ludwig-Maximilians-University, Munich, Germany

\*These authors have contributed equally to this manuscript.

## Corresponding Author:

Jan Hinnerk Mehrkens, MD, Department of Neurosurgery, Klinikum Grosshadern, Ludwig-Maximilians-University Munich, Marchioninstr. 15, 81377 Munich, Germany  
Email: Jan.Mehrkens@med.uni-muenchen.de

**Table 1.** Characteristics of the Study Population

ID	Age at Surgery, y	Gender	Duration of Disease Preoperatively, y	DYT1 Gene Mutation	Initial Clinical Presentation	Functional Impairment Prior to Surgery	Follow-Up, mo	Long-Term Clinical Performance Postoperatively
1	12	Male	4	Yes	Dystonia in right arm, handwriting deterioration	Limbs and trunk muscles affected; severe difficulties with sitting and walking	101	Almost normal gait, independent self-care, finished school, got driver's license, plays soccer, skis
2	14	Female	2	Yes	Dystonia in both legs	Limbs, trunk, and oromotor muscles affected; severe difficulties with sitting and walking	100	Walks unaided, gait mildly affected, finished school, self-care skills improved
3	16	Male	4	No	Dystonia in right leg	Bilateral lower limbs, trunk, and laryngeal muscles affected; severe difficulties with sitting and walking	64	Walks unaided, occasionally uses wheelchair for better mobility, self-care skills improved
4	15	Male	8	No	Dystonia in right upper and lower extremities	Right upper and lower extremities and trunk affected, walking possible	52	No obvious signs of dystonia, started college, totally independent
5	8	Female	1	Yes	Pain and limping in left leg	Limbs and trunk muscles affected, severe difficulties with sitting, unable to walk	50	Almost normal gait, attends school, rides bicycle, independent self-care

Clinical characteristics of the study population, including functional impairment prior to surgery and long-term clinical performance postoperatively at last follow-up. ID = patient number.

implications and possible restrictions: there are only sparse data available on (mainly) short-term outcome derived from some series or case reports focusing on pediatric patients<sup>8,18,19</sup> or children being part of a predominantly adult cohort.<sup>9,20</sup> Although the review by Alterman and Tagliati<sup>21</sup> and the current analysis by Borggraefe et al,<sup>22</sup> focusing on pediatric and juvenile patients, have provided some very convincing data on short-term outcome and predictive factors, still very little is known about long-term efficacy and side effects of early chronic globus pallidus internus deep brain stimulation in pediatric patients suffering from primary generalized dystonia. In a very recent study, Cif et al<sup>23</sup> report the long-term follow-up (up to over 10 years) of 26 patients after globus pallidus internus deep brain stimulation, including 15 pediatric patients. However, there again is no focus on this special subgroup of patients. To address these problems in the present study, we analyzed the immediate postoperative results and long-term follow-up data from one stereotactic center evaluating 5 young patients suffering from primary generalized dystonia after early globus pallidus internus deep brain stimulation with special focus on long-term efficacy and safety.

## Clinical Material and Methods

### Patient Population/Inclusion Criteria

This retrospective study has been performed in accordance with the ethical standards laid down in the 1964 Declaration of Helsinki.

Only pediatric patients with a history of severely disabling, medically intractable primary generalized dystonia, an age <16 years at date of surgery, and a follow-up of >36 months were considered

eligible for this retrospective analysis. Thus, a cohort of 5 young patients (mean age at surgery 13 years, with a range of 8-16 years, 2 female/3 male) suffering from primary generalized dystonia (3 tested positive, 2 tested negative for a mutation in the DYT1 gene located on chromosome 9q34) in whom globus pallidus internus deep brain stimulation had been performed between 1999 and 2005 could be included. The reference point of this study was date of electrode implantation. Patient characteristics are summarized in Table 1.

### Neurosurgical Technique/Implants

Bilateral pallidal electrode implantation (3387, Medtronic, Minneapolis, Minnesota) was performed under general (propofol) anesthesia with magnetic resonance imaging (MRI)-guided stereotaxy using a modified Leksell/Lerch system. The applied methodology for imaging, treatment planning, and implantation was published in detail elsewhere.<sup>7</sup> In brief, the MRI-compatible stereotaxy frame was invasively fixed to the patient's head according to external anatomical landmarks to be as parallel to the intercommisural plane as possible. Stereotactic MRI (2-mm T1- and T2-weighted axial images) was then performed using a 1.5 Tesla scanner (Magnetom Vision, Siemens, Erlangen, Germany). The preliminary target point within the globus pallidus internus was defined as 3 mm anterior to the midpoint between the anterior and posterior commissure, 18 to 22 mm lateral to the midline, and 3 to 6 mm below the intercommisural plane.<sup>24</sup> The standard target coordinates were adjusted based on individual anatomical landmarks (third ventricle, optical tract) and direct visualization of the globus pallidus internus on the T2-weighted images. Intraoperative microrecordings were performed in 3/5 patients. Permanent implantation of the Soletra (4 patients) or Kinetra (1 patient) (Medtronic) stimulation system was performed in a subcutaneous infraclavicular (Soletra) or abdominal pouch (Kinetra) after 3 to 5 days of testing for unwanted side effects with an external pulse generator system

**Table 2.** Burke-Fahn-Marsden Dystonia Rating Scale

	Preoperatively	Improvement Pre-3 Months, %	Improvement Pre-12 Months, %	Improvement Pre-36 Months, %	Improvement Pre-Last Follow-Up, %
Movement Score	55.4 ± 13.7	67.4 ± 18.7	75.4 ± 13.5	82.9 ± 7.3	82.8 ± 8.1
P value		<.001	<.001	<.001	<.001
Disability Score	16.0 ± 3.8	54.4 ± 22.4	73.4 ± 16.9	68.4 ± 17.2	69.5 ± 18.6
P value		<.001	<.001	<.001	<.001

Preoperative Burke-Fahn-Marsden Dystonia Rating Scale scores and relative improvement postoperatively. Values are given as mean ± standard deviation.

using percutaneous extensions. Prophylactic systemic antibiotic treatment (Cefuroxim, 3 × 0.5 g/d) was administered to all patients preoperatively and for at least 1 week postoperatively. Hospital stay ranged between 14 and 24 days.

### Stimulation/Parameters

The most distal contact of the quadripolar electrode that caused no unwanted side effect when activated was chosen for permanent monopolar stimulation (initial standard settings: amplitude: 2.5 V, pulse width: 120 μs, frequency: 130 Hz). Thereafter, the amplitude was stepwise increased over several days to determine each patient's individual settings, which yielded a maximum clinical response with no or minimal side effects (eg, phosphenes, motor symptoms, and speech disturbance).

### Patient Evaluation

Clinical outcome was assessed using the Burke-Fahn-Marsden Dystonia Rating Scale (motor and disability)<sup>25</sup> at discharge from hospital (mean 10 days after initial programming) at 3, 6, and 12 months post-op and from then on every 12 months (or on demand). All patients had been screened for a DYT1 gene mutation.

Correct electrode position within the globus pallidus internus was verified on immediate postoperative nonstereotactic MRI using the customized planning software and coregistration with the treatment planning MRI and the Schaltenbrand brain atlas.<sup>26</sup> The exact position of all active contacts was calculated with reference to the midpoint between the anterior and posterior commissure (Matlab 7.1, MathWorks, Inc, Natick, Massachusetts).

### Statistical Methods

The Wilcoxon matched-pairs signed rank test was applied to compare changes in the rating scale scores pre- and postoperatively (immediate response, 3 months, 12 months, 36 months, and "open-label" long-term follow-up [ $>36$  months]). A correlation analysis using the Spearman correlation coefficient together with a linear regression analysis was used to test for pretreatment prognostic factors for long-term outcome (at 36 months) as well as correlation between electrode localization and outcome. A statistical threshold of  $P < .05$  was considered to be significant. Statistical analyses were performed using the SPSS 16.0 software (SPSS, Inc, an IBM Company, Chicago, Illinois).

## Results

### Clinical Patient Outcome

In general, patients were severely affected with a mean preoperative Dystonia Rating Scale movement and disability score of  $55 \pm 13.7$  (range, 32-65) and  $16 \pm 3.8$  (range, 10-20), respectively. All patients included in the present study showed a very rapid positive response to globus pallidus internus deep brain stimulation with significant improvement of their symptoms already during the first postoperative week. The improvement was  $>50\%$  in 4/5 patients ( $>85\%$  in 2/5 patients).

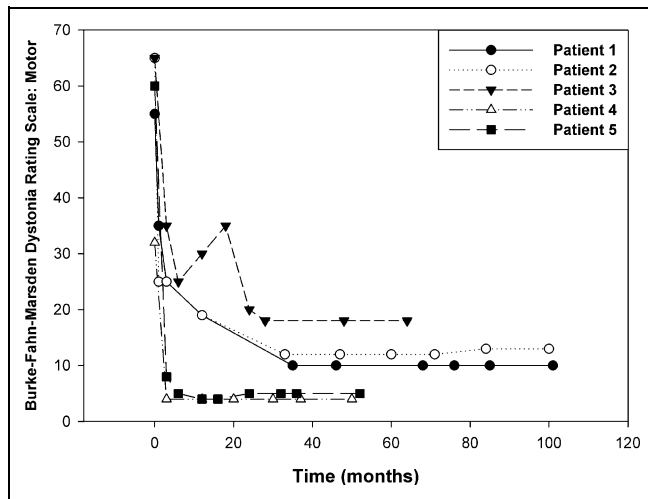
At 3-month follow-up, there was a mean improvement in the Dystonia Rating Scale movement score of  $67.4\% \pm 18.7\%$  (range, 47.0%-87.5%) and a mean improvement in the disability score of  $54.4\% \pm 22.4\%$  (range, 33.3%-90.0%). At intermediate analysis after 12 months, the scores (both movement and disability) were further improved in 4 and unchanged compared with the beneficial 3-month status in 1 patient. This improvement was stable during the long-term follow-up at 36 months and at last follow-up (mean 73 months; range, 50-101 months) in all 5 patients. The mean percentage improvement of the study cohort in comparison to the preoperative status together with the statistical values is listed in Table 2. Individual courses of Dystonia Rating Scale scores at long-term follow-up are given in Figures 1 and 2, and the functional aspects of long-term outcome are included in Table 1.

### Statistical Analysis

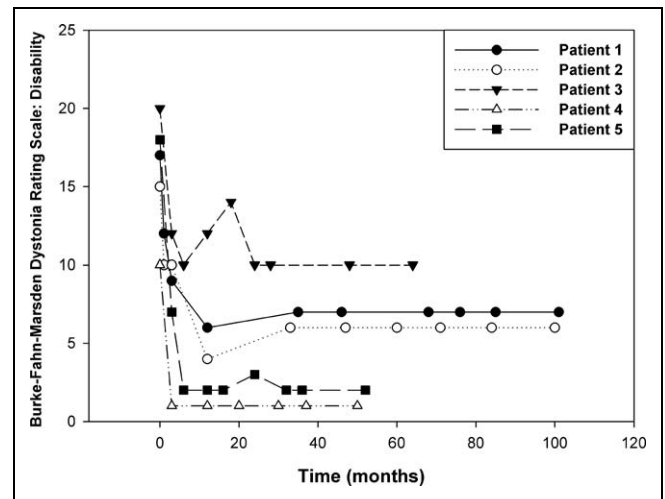
Mean improvement compared with the preoperative status evaluated at 3 and 12 months as well as long-term follow-up (36 months) was significant at all points of time tested (both motor and disability score; Table 2). There was no statistically significant difference between long-term benefit at 36 months and last ("open-label" long-term) follow-up, where available. Correlation and regression analysis could not detect any statistically significant correlation of outcome and pretreatment factors (factors tested: age at surgery, duration of disease prior to deep brain stimulation, severity of symptoms, DYT1 status) in this cohort.

### Electrode Position

The postoperative MRI confirmed correct placement of electrodes within the (posteroventral) globus pallidus internus in all



**Figure 1.** Graph showing the individual course of Burke-Fahn-Marsden Dystonia Rating Scale: movement scores for the 5 patients in long-term follow-up (reference point was date of electrode implantation).



**Figure 2.** Graph showing the individual course of Burke-Fahn-Marsden Dystonia Rating Scale: disability scores for the 5 patients in long-term follow-up (reference point was date of electrode implantation).

patients. Mean stereotactic coordinates of the active electrode contacts were as follows:

1. Left hemisphere:  $1.9 \pm 2.4$  mm (range,  $-0.9$  to  $5.5$  mm) anterior to the midcommisural point,  $18.4 \pm 1.94$  mm (range,  $16.0$ - $21.0$  mm) lateral to the midline of the third ventricle, and  $3.4 \pm 2.7$  mm (range,  $0.2$ - $6.2$  mm) below the intercommisural plane
2. Right hemisphere:  $2.2 \pm 1.2$  mm (range,  $0.9$ - $3.3$  mm) anterior to the midcommisural point,  $18.3 \pm 1.9$  mm (range,  $16.0$ - $21.0$  mm) lateral to the midline of the third ventricle, and  $4.06 \pm 2.3$  mm (range,  $1.0$ - $7.0$  mm) below the intercommisural plane

An example for the postoperative MRI results together with a graph showing localization of the contacts for all electrodes with respect to anterior/posterior commissure coordinates for the 5 patients is given in Figure 3. There was no statistically significant correlation between electrode position and outcome.

### Stimulation Parameters

The initial amplitude settings (on discharge, mean  $3.0 \pm 0.7$  V) had to be gradually adjusted in all patients during follow-up to optimize symptom control along with minimization of unwanted side effects (involuntary movements, speech disturbance). There was no significant difference of the parameters at 12 months (mean amplitude  $3.4 \pm 0.4$ , mean pulse width  $138.0 \pm 40.3$   $\mu$ s, mean frequency  $133.0 \pm 6.7$  Hz) and last follow-up (mean amplitude  $3.3 \pm 0.5$ , mean pulse width  $138.0 \pm 40.3$   $\mu$ s, mean frequency  $130.0 \pm 0.0$  Hz).

### Pulse Generator Replacement

Interval for first replacement (necessary in all 5 patients) was 28, 36, 38, 52, and 59 months, respectively. One patient had

to undergo a second replacement during follow-up at another 32 months after the first replacement (patient 2).

### Complications

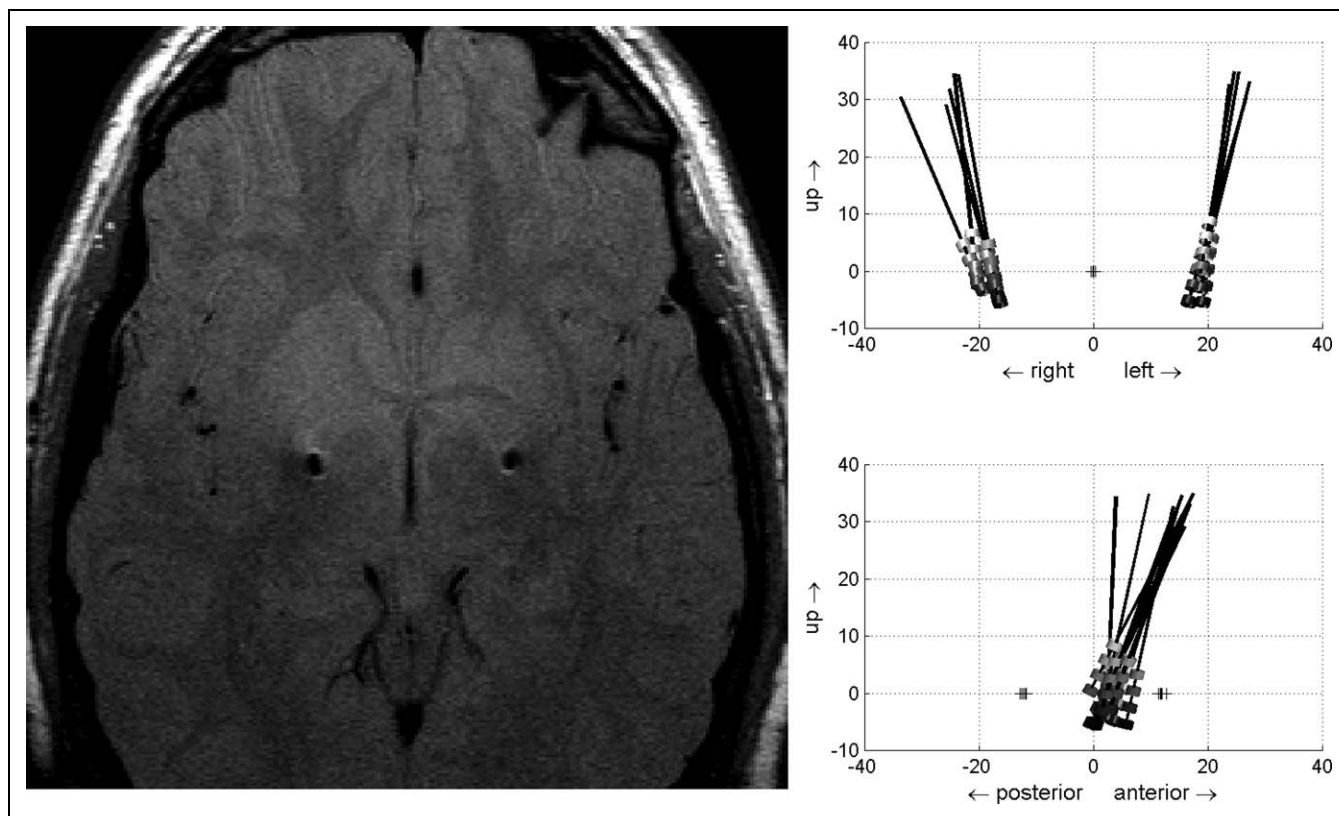
**Perioperative Mortality and Morbidity.** There was no perioperative morbidity or mortality observed in this series.

**Infections.** There were no local (burr hole site, extension cable, pulse generator pouch) or systemic infections documented in this series.

**Long-Term Complications/Side Effects.** One female patient (patient 2) with an excellent clinical response and significant improvement developed extreme psychosocial behavioral abnormalities (aggressiveness, uncooperativeness) with a delay of 36 months after implantation, necessitating intensive psychological treatment (partially as an inpatient). With adequate psychological support, her clinical status could be stabilized.

Mild dysarthric speech disturbance depending on stimulation intensity occurred in 2 patients (patients 4 and 5). Because of the otherwise excellent clinical response, this mild impairment was well accepted.

**Hardware Complications.** In 1 patient (patient 2), loosening of the burr hole cap with consecutive electrode dislocation (39 months postoperatively) and, in the later course (58 months postoperatively), breakage of the extension cable occurred. Both events were accompanied by a loss of stimulation and consecutive severe worsening of clinical symptoms. Complete restitution could be achieved in either event by immediate revision of the deep brain stimulation electrode and revision of the extension cable, respectively. Revision of the abdominal pulse generator pouch to prevent imminent percutaneous cable



**Figure 3.** Representative postoperative magnetic resonance imaging (proton density-weighted sequence, patient 3) showing correct position of bilateral electrode contacts (artifacts) within the globus pallidus internus (left) and graphs (right) showing localization of the contacts for all electrodes with respect to anterior/posterior commissure coordinates for the 5 patients. Localization of anterior/posterior commissure in the individual patients is indicated by the crosses. Reference point (0) on the vertical axis (“up”): anterior/posterior commissure plane; reference point (0) on the horizontal axis: anterior/posterior commissure line (distance right/left, upper graph) and anterior/posterior commissure midpoint (distance posterior/anterior, lower graph), respectively. All values on axes are given in mm.

perforation 5 months after the initial implantation had to be performed in the youngest patient (patient 5).

**Discussion**

Multicenter studies with a controlled (randomized) protocol have proved the efficacy of globus pallidus internus deep brain stimulation for patients with primary generalized dystonia.<sup>15-17</sup> In addition, the long-term benefit of this approach has also been shown.<sup>16,23,27,28</sup> However, although primary generalized dystonia presents mainly at a young age (<10 years) and is usually severely disabling, globus pallidus internus deep brain stimulation is still often not applied in the early course of the disease<sup>1,3,4,10</sup>—even in the absence of effective medical treatment options<sup>4,6,21</sup> and the presence of convincing data on this neurosurgical procedure in pediatric patients (eg, the pioneering work by Coubes and coworkers<sup>8,9,23</sup>). This phenomenon might in part be due to the persisting lack of long-term data on the efficacy and safety of early globus pallidus internus deep brain stimulation in pediatric and juvenile patients and the averseness to a “neurosurgical procedure” on the part of parents and primary caregivers/neurologists.

The present analysis addresses immediate postoperative and long-term (mean follow-up: 73 months) results for a cohort of 5 young patients suffering from primary generalized dystonia all having undergone early globus pallidus internus deep brain stimulation (mean age at surgery, 13 years; range, 8-16 years). In contrast to recent reports covering almost exclusively adult patients, we observed a significant improvement of symptoms already during the first postoperative week in all patients, with 2/5 patients even having improved >85%.<sup>8-17</sup>

In detail, the present analysis showed that the Dystonia Rating Scale scores, which were significantly improved 3 months (movement: 67.4% ± 18.7%, disability: 54.4% ± 22.4%) and 12 months (movement: 75.4% ± 13.5%, disability: 73.4% ± 16.9%) after the start of deep brain stimulation, remained stable during long-term follow-up in all patients with a mean motor improvement of 82.9% at a 36-month follow-up and beyond. These convincing results exceed the long-term outcome data available of recently published studies on cohorts consisting mainly of adult patients that report a persistent mean Dystonia Rating Scale motor improvement at 36 months between 50% and 66%<sup>16,27,28</sup> and correspond well with the long-term results in the pediatric subgroup of the study by Cif et al.<sup>23</sup> Together with current data clearly supporting the role of early

intervention, these observations might well be taken as an indicator for the necessity of early neurosurgical intervention to achieve the optimal clinical outcome and to prevent irreversible impairment of motor function (muscle, joint, and bone destruction/deformity), especially in pediatric patients.<sup>18,22,28-30</sup> The beneficial results of the globus pallidus internus deep brain stimulation procedure performed at young age and at an early stage of the disease allowed for the patients to return to a life of much higher quality, restoring social integration and participation: all patients were able to attend school and interact with their peer group with almost no or little restrictions (patient 1 plays soccer and skis, patient 4 plays various sports, and patient 5 rides a regular bicycle; see Table 1).

The absence of predictive factors for long-term outcome (at 36 months) in this series, apart from the low number of cases, might well be explained by the fact that all patients were operated on at a young age, and response was excellent in all cases. In concordance with the results of the randomized controlled series by Kupsch et al,<sup>17</sup> there also was no difference in outcome between the patients with (3) or without (2) DYT1 mutation in our patient cohort.

### Complications

Stereotactic implantation of the brain electrodes did not give rise to any morbidities (eg, symptomatic intracerebral hemorrhage, new neurological deficits), which are reported as known but nevertheless rare complications of deep brain stimulation.<sup>14,31,32</sup> Moreover, there were no local (burr hole site, extension cable, pulse generator pouch) or systemic infections observed in this (small) series.

Except for the temporary aggressive behavior observed in a female patient (patient 2) who responded very well to supportive psychological treatment, we did not observe any other mood alterations (eg, toward depression or even suicidal tendencies), as observed by other authors.<sup>33</sup> The mild dysarthria registered in 2 patients (patients 4 and 5) was very well tolerated and of no clinical relevance to these patients because of the otherwise excellent clinical improvement of the dystonic symptoms. There were no obvious cognitive impairment or neurodevelopmental abnormalities that could be attributed to globus pallidus internus deep brain stimulation (although specifically tested for only in patient 5; data not shown). However, as reported by other groups, the impact that an intervention in the globus pallidus internus might have on a “developing” brain remains unclear and should be further evaluated, preferably in a prospective manner.<sup>34,35</sup> In this context, it is very important to keep in mind that it is completely unknown which psychological or neurodevelopmental/behavioral effects might be induced in a pediatric patient bearing a deep brain stimulation system for the rest of his or her life—which might well be 70 years and older. A “curative” therapeutic approach restoring function without any permanently “implanted hardware” (routinely requiring multiple replacements and making the bearer prone to “hardware complications”) would definitely be the treatment of choice. Yet, for the time being, globus

pallidus internus deep brain stimulation seems to remain the therapy of choice in primary generalized dystonia.

In summary, the (long-term) complication rate in this series covering 5 pediatric patients was very low without any severe events, but with 2 patients needing (low-risk) surgical revisions and hospitalization, which underscores the invasive nature of the applied therapy. Except for the imminent percutaneous cable perforation at the abdominal pulse generator pouch in our youngest patient (patient 5), which might be attributed to the delicate skin and connective tissue situation that definitely needs to be given special attention in any (neuro)surgical procedure, there was no complication/event of deep brain stimulation “specific” for this young patient cohort. Whether the introduction of rechargeable pulse generators will further improve quality of life and surgery/hardware-related morbidity (smaller volume, less replacements) as hoped for will be subject to an ongoing prospective analysis.

### Conclusion

Globus pallidus internus deep brain stimulation offers a very effective and safe therapy in pediatric patients suffering from primary dystonia. Highly significant and stable long-term relief of symptoms can be achieved. Early neurosurgical intervention seems to be crucial for optimal clinical outcome and to prevent irreversible impairment of motor function.

### Declaration of Conflicting Interests

The authors declared a potential conflict of interest (eg, a financial relationship with the commercial organizations or products discussed in this article) as follows: Drs Bötzel and Mehrkens have received speaker’s honoraria from Medtronic.

### Funding

The authors received no financial support for the research and/or authorship of this article.

### References

1. Fahn S, Bressman SB, Marsden CD. Classification of dystonia. *Adv Neurol*. 1998;78:1-10.
2. Klein C, Ozelius LJ. Dystonia: clinical features, genetics, and treatment. *Curr Opin Neurol*. 2002;15:491-497.
3. Angelini L, Nardocci N, Rumi V, Lamperti E. Idiopathic dystonia with onset in childhood. *J Neurol*. 1989;236:319-321.
4. Albanese A, Barnes MP, Bhatia KP, et al. A systematic review on the diagnosis and treatment of primary (idiopathic) dystonia and dystonia plus syndromes: report of an EFNS/MDS-ES Task Force. *Eur J Neurol*. 2006;13:433-444.
5. Balash Y, Giladi N. Efficacy of pharmacological treatment of dystonia: evidence-based review including meta-analysis of the effect of botulinum toxin and other cure options. *Eur J Neurol*. 2004;11:361-370.
6. Ford B, Greene P, Louis ED, et al. Use of intrathecal baclofen in the treatment of patients with dystonia. *Arch Neurol*. 1996;53:1241-1246.

7. Bereznai B, Steude U, Seelos K, Bötzel K. Chronic high-frequency globus pallidus internus stimulation in different types of dystonia: a clinical, video, and MRI report of six patients presenting with segmental, cervical, and generalized dystonia. *Mov Disord.* 2004;17:138-144.
8. Coubes P, Roubertie A, Vayssiere N, et al. Treatment of DYT1-generalised dystonia by stimulation of the internal globus pallidus. *Lancet.* 2000;355:2220-2221.
9. Coubes P, Cif L, El Fertit H, et al. Electrical stimulation of the globus pallidus internus in patients with primary generalized dystonia: long-term results. *J Neurosurg.* 2004;101:189-194.
10. Krause M, Fogel W, Kloss M, et al. Pallidal stimulation for dystonia. *Neurosurgery.* 2004;55:1361-1370.
11. Krauss JK, Loher TJ, Weigel R, et al. Chronic stimulation of the globus pallidus internus for treatment of non-dYT1 generalized dystonia and choreoathetosis: 2-year follow up. *J Neurosurg.* 2003;98:785-792.
12. Starr PA, Turner RS, Rau G, et al. Microelectrode-guided implantation of deep brain stimulators into the globus pallidus internus for dystonia: techniques, electrode locations, and outcomes. *J Neurosurg.* 2006;104:488-501.
13. Tronnier VM, Fogel W. Pallidal stimulation for generalized dystonia: report of three cases. *J Neurosurg.* 2000;92:453-456.
14. Yianni J, Bain P, Giladi N, et al. Globus pallidus internus deep brain stimulation for dystonic conditions: a prospective audit. *Mov Disord.* 2003;18:436-442.
15. Vidailhet M, Vercueil L, Houeto JL, et al.; French Stimulation du Pallidum Interne dans la Dystonie (SPIDY) Study Group. Bilateral deep-brain stimulation of the globus pallidus in primary generalized dystonia. *N Engl J Med.* 2005;352:459-467.
16. Vidailhet M, Vercueil L, Houeto JL, et al.; French SPIDY Study Group. Bilateral, pallidal, deep-brain stimulation in primary generalised dystonia: a prospective 3 year follow-up study. *Lancet Neurol.* 2007;6:223-229.
17. Kupsch A, Benecke R, Muller J, et al.; Deep-Brain Stimulation for Dystonia Study Group. Pallidal deep-brain stimulation in primary generalized or segmental dystonia. *N Engl J Med.* 2006;355:1978-1990.
18. Borggraefe I, Boetzel K, Boehmer J, et al. Return to participation: significant improvement after bilateral pallidal stimulation in rapidly progressive DYT-1 dystonia. *Neuropediatrics.* 2009;39:239-242.
19. Parr JR, Green AL, Joint C, et al. Deep brain stimulation in childhood: an effective treatment for early onset idiopathic generalised dystonia. *Arch Dis Child.* 2007;92:708-711.
20. Zorzi G, Marras C, Nardocci N, et al. Stimulation of the globus pallidus internus for childhood-onset dystonia. *Mov Disord.* 2005;20:1194-2000.
21. Alterman RL, Tagliati M. Deep brain stimulation for torsion dystonia in children. *Childs Nerv Syst.* 2007;23:1033-1040.
22. Borggraefe I, Mehrkens JH, Telegravciska M, et al. Bilateral pallidal stimulation in children and adolescents with primary generalized dystonia: report of six patients and literature-based analysis of predictive outcomes variables. *Brain Dev.* 2010;32:223-228.
23. Cif L, Vasques X, Gonzalez V, et al. Long-term follow-up of DYT1 dystonia patients treated by deep brain stimulation: an open-label study. *Mov Dis.* 2010;25:289-299.
24. Laitinen LV, Bergenheim AT, Hariz MI. Leksell's posteroventral pallidotomy in the treatment of Parkinson's disease. *J Neurosurg.* 1992;76:53-61.
25. Burke RE, Fahn S, Marsden CD, et al. Validity and reliability of a rating scale for the primary torsion dystonias. *Neurology.* 1985;35:73-77.
26. Schaltenbrand G, Wahren W. *Atlas for Stereotaxy of the Human Brain.* Stuttgart, PA: Georg Thieme; 1977.
27. Loher TJ, Capelle HH, Kaelin-Lang A, et al. Deep brain stimulation for dystonia: outcome at long-term follow-up. *J Neurol.* 2008;255:881-884.
28. Mehrkens JH, Bötzel K, Steude U, et al. Long-term efficacy and safety of chronic globus pallidus internus stimulation in different types of primary dystonia. *Stereotac Funct Neurosurg.* 2008;87:8-17.
29. Isaias IU, Alterman RL, Tagliati M. Outcome predictors of pallidal stimulation in patients with primary dystonia: the role of disease duration. *Brain.* 2008;131:1895-1902.
30. Vasques X, Cif L, Gonzalez V, et al. Factors predicting improvement in primary generalized dystonia treated by pallidal deep brain stimulation. *Mov Disord.* 2009;24:846-853.
31. Voges J, Waerzeggers Y, Maarouf M, et al. Deep-brain stimulation: long-term analysis of complications caused by hardware and surgery—experiences from a single centre. *J Neurol Neurosurg Psychiatry.* 2006;77:868-872.
32. Voges J, Hilker R, Bötzel K, et al. Thirty days complication rate following surgery performed for deep-brain-stimulation. *Mov Disord.* 2006;22:1486-1489.
33. Foncke EM, Schuurman PR, Speelman JD. Suicide after deep brain stimulation of the internal globus pallidus for dystonia. *Neurology.* 2006;66:142-143.
34. Scott RB, Harrison J, Boulton C, et al. Global attentional-executive sequelae following surgical lesions to globus pallidus interna. *Brain.* 2002;125:562-574.
35. Scott RB, Gregory R, Wilson J, et al. Executive cognitive deficits in primary dystonia. *Mov Disord.* 2003;18:539-550.