

Clinical and Applied Thrombosis/Hemostasis

<http://cat.sagepub.com/>

Plantar Vein Thrombosis due to Busy Night Duty on Intensive Care Unit

Carolin Geiger, Antje Rademacher, Daniel Chappell, Mojtaba Sadeghi-Azandaryani and Jens Heyn

CLIN APPL THROMB HEMOST 2011 17: 232 originally published online 2 December 2009

DOI: 10.1177/1076029609351878

The online version of this article can be found at:

<http://cat.sagepub.com/content/17/2/232>

Published by:



<http://www.sagepublications.com>

Additional services and information for *Clinical and Applied Thrombosis/Hemostasis* can be found at:

Email Alerts: <http://cat.sagepub.com/cgi/alerts>

Subscriptions: <http://cat.sagepub.com/subscriptions>

Reprints: <http://www.sagepub.com/journalsReprints.nav>

Permissions: <http://www.sagepub.com/journalsPermissions.nav>

Citations: <http://cat.sagepub.com/content/17/2/232.refs.html>

>> [Version of Record](#) - Mar 14, 2011

[OnlineFirst Version of Record](#) - Dec 2, 2009

[What is This?](#)

Plantar Vein Thrombosis due to Busy Night Duty on Intensive Care Unit

Clinical and Applied
Thrombosis/Hemostasis
17(2) 232-234
© The Author(s) 2011
Reprints and permission:
sagepub.com/journalsPermissions.nav
DOI: 10.1177/1076029609351878
http://cath.sagepub.com



Carolin Geiger, MD,¹ Antje Rademacher, MD,²
Daniel Chappell, MD,³ Mojtaba Sadeghi-Azandaryani, MD,⁴ and
Jens Heyn, MD³

Abstract

A 32-year-old woman with severe foot pain came to our emergency department after a busy night duty in hospital followed by an extended sleep period. Physical examination revealed a discrete swelling of the medial aspect of the right foot and a painful plantar arch during digital examination. Magnetic resonance imaging (MRI) with intravenous gadolinium showed filling defects in the lateral plantar vein. Doppler sonography displayed noncompressible structures in the plantar veins without flow signals, suggesting a plantar vein thrombosis. Therapy was initiated with low-molecular-weight heparin in combination with customized elastic bandages for the lower leg. Follow-up sonography 6 weeks later showed complete patency of the plantar veins. To our knowledge, we present the first case of isolated plantar vein thrombosis independent of trauma, surgery, or malignant disease, most probably caused by a busy night duty on the intensive care unit (ICU) followed by a prolonged sleeping period.

Keywords

plantar vein thrombosis, MRI, sonography

Inferior heel pain is a common symptom after trauma or exercise. This symptom is often associated with bone fracture, plantar fibromatosis, ganglion cysts, or plantar fasciitis.¹ In rare cases, inferior heel pain can be caused by plantar vein thrombosis. Despite, the exact etiology of plantar vein thrombosis still being unknown, the predisposing conditions include previous trauma or surgery, paraneoplastic conditions, and coagulation disorders.²⁻⁴ Indicative symptoms often imply swelling and pain of the respective foot. We present the first case of isolated plantar vein thrombosis independent of trauma, surgery, or malignant disease, most probably caused by a busy night duty on the intensive care unit (ICU) followed by a prolonged sleeping period.

Case Report

A 32-year-old woman came to our surgical emergency department presenting acutely incipient foot pain after 14 hours of sleep following a busy night duty on ICU. When getting up, a sudden stinging pain along the medial and plantar aspects of her right foot had occurred, which still persisted. She had no history of foot trauma or similar symptoms before. Besides a contraceptive (Etonogestrel and Ethinylestradiol—NuvaRing[®]), she had no further pre-existing medication. Physical examination revealed a painful plantar arch, which even precluded standing or walking. Fractures of the tarsal bones and ankle joint were excluded by x-ray. As the diagnostic findings indicated

a plantar fasciitis, physical rest was advised and anti-inflammatory medication was started.

After 1 week, the symptoms still persisted without improvement. Recurrent anamnesis revealed no thrombosis in the patient's history (family anamnesis was also negative). Reassessment showed an unchanged digital examination as well as continuous plantar swelling and pain. Magnetic resonance imaging (MRI) with intravenous gadolinium was performed to exclude small bone lesions. Neither fractures nor other bone abnormalities or any signs of the previous diagnosis plantar fasciitis could be detected by MRI. However, it revealed filling defects in the lateral plantar vein (Figure 1). These findings were also confirmed by Duplex sonography, which visualized noncompressible structures in the medial veins around the ankle joint and in the plantar veins. Examination of the

¹ Department of Cardiology and Intensive Care Medicine, Bogenhausen Hospital, Munich, Germany

² Department of Internal Medicine, University Hospital Munich (LMU), Munich, Germany

³ Department of Anaesthesiology, University Hospital Munich (LMU), Munich, Germany

⁴ Department of Surgery, University Hospital Munich (LMU), Munich, Germany

Corresponding Author:

Jens Heyn, Clinic of Anaesthesiology, Campus Grosshadern, Ludwig-Maximilians-University, Marchioninistrasse 15, D-81377 Munich, Germany.
Email: Jens.Heyn@med.uni-muenchen.de

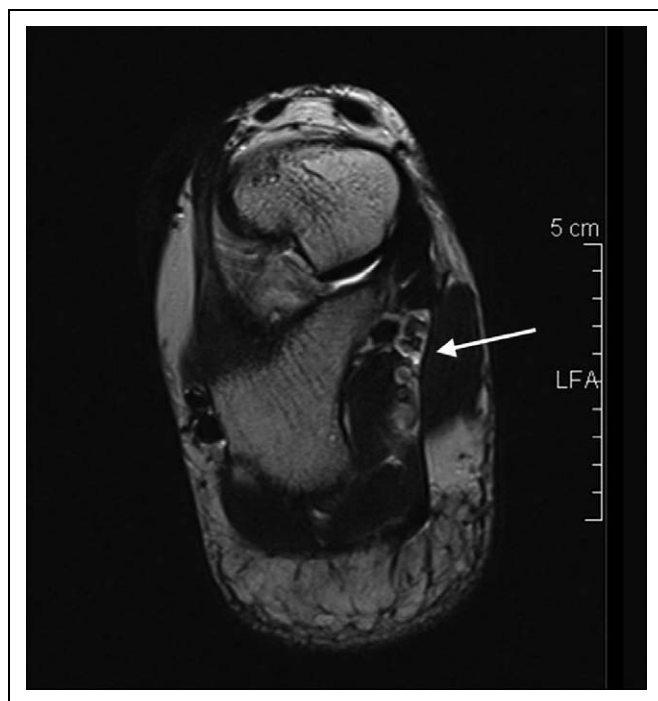


Figure 1. Magnetic resonance imaging of the right foot revealed thrombophlebitis and filling defects (white arrow) in the lateral plantar vein (T2 sequence), indicating a plantar vein thrombosis.

contralateral foot presented a normal compression of the plantar veins and unhindered blood flow. Additional sonography of the deep veins of the right upper and lower extremity showed no abnormality. Finally, a coagulogram (including protein C, protein S, phospholipid antibodies, activated protein C (APC) resistance, factor V gene, and platelet abnormalities) was carried out and a gynecological examination with sonography of the abdomen was performed—all without any pathological finding.

Accordingly, a plantar venous thrombosis was diagnosed. Therapy was initiated with low-molecular-weight heparin (Tinzaparin 10 000 U/d for 2 weeks, followed by Enoxaparin 60 mg/d for the next 2 weeks). A special customized elastic bandage was manufactured and worn for the following 6 weeks. Follow-up sonography 6 weeks later showed a complete patency of all plantar veins, with the patient being free of pain.

Discussion

Occurrence of plantar vein thrombosis is extremely rare, and the underlying etiology remains unknown.²⁻⁴ Review of the literature showed that plantar vein thrombosis has been associated with athletic activity,² with immobilization following surgery,^{5,6} with the coagulation disorders anticardiolipin antibody syndrome⁴ and prothrombin G20210A mutation,³ and as a paraneoplastic syndrome in a patient with bone metastasis.²

We here present the first case of plantar vein thrombosis without prior surgery, malignancy, or coagulation disorders. In our case, plantar vein thrombosis was most probably caused by a busy night duty on ICU followed by a prolonged sleeping period for 14 hours.

Since their introduction, oral contraceptives have been linked to an increased incidence of thromboembolic events. Epidemiologic studies have shown that women who use third-generation oral contraceptives containing desogestrel, gestodene, or norgestimate have a higher risk of venous thrombosis than women who use second-generation oral contraceptives containing levonorgestrel.⁷ NuvaRing[®] (Etonogestrel and Ethinylestradiol) is associated with a minimal effect on hemostatic variables (increased Factor VII levels and higher activity of protein C and antithrombin).⁸ The special and relative risk (in comparison to oral contraceptives) of thrombosis in patients using NuvaRing[®] is still unknown. Within this report, we report for the first time about thrombosis in a patient, using NuvaRing[®] as contraceptive.

In prior reports, the diagnosis of plantar vein thrombosis was established by initial Doppler sonography and the inability to reduce the lumen of the vessels during compression. Additional findings included hypoechoic enlarged venous structures in the transverse plane and hypoechoic enlarged veins in the longitudinal plane.^{2,4-6} Only 2 case reports describe MRI as a tool to diagnose plantar vein thrombosis. Sonography may also be a useful tool to diagnose this disease; however, this procedure is operator dependent and including the plantar veins in the investigation of deep vein thrombosis is not a routine procedure. Therefore, in a lot of cases, this diagnosis might escape detection.

Magnetic resonance imaging is often used for evaluating persistent foot pain. Therefore, an exact knowledge of the anatomical structures of the plantar vessels is essential. Typical radiological signs in the MRI in patients with plantar vein thrombosis are tissue edema, enhancement of bordering soft tissue, and filling defects of the plantar veins.³

Until today, no standardized therapy for plantar vein thrombosis exists. In 4 patients, a therapy with heparin was initiated^{2,5} with additional elastic compression of the ankle region in a single case.⁵ In a further case, a mono-treatment of the thrombosis with oral anticoagulation was performed,⁴ and another treatment regimen consisted of rest, nonsteroidal anti-inflammatory medications, and acetaminophen.³ We combined a therapy with low-molecular-weight heparin and elastic compression of the ankle region using a customized elastic bandage. Interestingly, all different therapeutic regimes led to full regeneration without any residues, as in our case.

In conclusion, plantar vein thrombosis is a very rare entity and may occur in young patients without previous trauma, malignancy, or surgery. Although the symptoms are not specific, MRI is an optimal tool to establish the diagnosis with Duplex sonography as a noninvasive marker also for follow-up examinations. The therapy is heterogeneous—however, low-molecular-weight heparin optional in combination with elastic bandage seems to be the therapy of choice for regeneration without residues.

Declaration of Conflicting Interest

The authors declared no conflicts of interest with respect to the authorship and/or publication of this article.

Funding

This research received no specific grant from any funding agency in the public, commercial, or not-for-profit sectors.

References

1. Cardinal E, Chhem RK, Beauregard CG, Aubin B, Pelletier M. Plantar fasciitis: sonographic evaluation. *Radiology*. 1996;201(1):257-259.
2. Bernathova M, Bein E, Bendix N, Bodner G. Sonographic diagnosis of plantar vein thrombosis: report of 3 cases. *J Ultrasound Med*. 2005;24(1):101-103.
3. Siegal DS, Wu JS, Brennan DD, Challies T, Hochman MG. Plantar vein thrombosis: a rare cause of plantar foot pain. *Skeletal Radiol*. 2008;37(3):267-269.
4. Long A, Bura-Riviere A, Sapoval M. Plantar venous thrombosis and anticardiolipin antibody syndrome. Case report. *J Mal Vasc*. 2004;29(1):39-40.
5. Cavezzi A. Isolated thrombosis of plantar veins. Case report [in Italian]. *Minerva Cardioangiol*. 1999;47(9):309-313.
6. Legrand MS, Papon X, Leftheriotis G, Saumet JL. Isolated plantar venous thrombosis. Report of a case [in French]. *J Mal Vasc*. 1997;22(5):364-365.
7. Belicová M, Lukác B, Dvorský J, Peter G, Mokán M, Kubisz P. Thromboembolic disease and present oral contraception. *Clin Appl Thromb Hemost*. 2003;9(1):45-51.
8. Magnúsdóttir EM, Bjarnadóttir RI, Onundarson PT, et al. The contraceptive vaginal ring (NuvaRing) and hemostasis: a comparative study. *Contraception*. 2004;69(6):461-467.