

Lupus

<http://lup.sagepub.com/>

Anti-phospholipid-antibodies in patients with relapsing polychondritis
M Zeuner, R H Straub, U Schlosser, G Rauh, G Schmitz, J Schölmerich and B Lang
Lupus 1998 7: 12
DOI: 10.1191/096120398678919615

The online version of this article can be found at:
<http://lup.sagepub.com/content/7/1/12>

Published by:



<http://www.sagepublications.com>

Additional services and information for *Lupus* can be found at:

Email Alerts: <http://lup.sagepub.com/cgi/alerts>

Subscriptions: <http://lup.sagepub.com/subscriptions>

Reprints: <http://www.sagepub.com/journalsReprints.nav>

Permissions: <http://www.sagepub.com/journalsPermissions.nav>

Citations: <http://lup.sagepub.com/content/7/1/12.refs.html>

>> [Version of Record](#) - Jan 1, 1998

[What is This?](#)



PAPER

Anti-phospholipid-antibodies in patients with relapsing polychondritis

M Zeuner¹, RH Straub¹, U Schlosser², G Rauh³, G Schmitz², J Schölmerich¹ and B Lang¹

¹University of Regensburg, Medical Center, Department of Internal Medicine I, Germany; ²University of Regensburg, Medical Center, Institute of Clinical Chemistry and Laboratory Medicine, Germany; and ³Ludwig-Maximilian's University Munich, Medical Policlinic, Germany

Relapsing polychondritis (RP) is an extremely rare multisystemic disease thought to be of autoimmune origin. In order to assess if RP is associated with anti-phospholipid antibodies (aPL), clinical data and sera of 21 patients with RP were collected in a multicentre study. Concentration of anti-cardiolipin antibodies (aCL) (IgG-, IgM- and IgA-isotypes), anti-phosphatidylserine-antibodies (aPS) (IgG- and IgM-isotypes) and anti- β -2-glycoprotein I-antibodies ($\alpha\beta$ 2 GPI) were measured by ELISA. In eight patients aCL were found to be elevated. One patient had elevated aPS. No patient had elevated $\alpha\beta$ 2 GPI. No patient had clinical signs and symptoms of a aPL syndrome. Interestingly, the two RP patients with the highest aPL had concomitant systemic lupus erythematosus (SLE). Therefore the presence of elevated aPL in RP is probably more closely related to an associated SLE than to RP itself. There is no convincing evidence that aPL are associated with RP.

Keywords: anti-phospholipid antibodies; relapsing polychondritis

Introduction

Relapsing Polychondritis (RP) is a multisystemic rheumatic disease, characterized by widespread and potentially destructive inflammatory lesions of the cartilage.¹ The aetiology of RP is still unknown; however, the high incidence of coexisting other autoimmune or rheumatic diseases (such as SLE) together with abundant anti-collagen autoantibodies and with immunogenetic findings such as a HLA-DR4 association with susceptibility for RP² provide evidence that RP is an immunological disorder, probably of autoimmune origin.

In many other autoimmune diseases, such as SLE, aPL are prevalent.³ Like patients with primary aPL syndrome these SLE patients have a higher frequency of thrombosis, spontaneous abortion, thrombocytopenia, livedo reticularis and positive direct Coombs test than SLE patients without aPL. In order to assess if

RP is like many other autoimmune diseases, also associated with aPL, we measured aCL, aPS and $\alpha\beta$ 2 GPI in 21 patients with RP and examined the patients for clinical symptoms and signs of an aPL syndrome.

Patients and methods

Patients with RP were recruited in a multicentre study between 1990 and 1995 from rheumatic disease units in university hospitals and other tertiary referral centers in Germany, Switzerland and the Netherlands. From 21 of a total of 62 patients sera were available for further analysis. All patients fulfilled the diagnostic criteria according to Mc Adam *et al.*⁴ and Michet *et al.*⁵ Positive histology of the involved cartilage was not required for inclusion, when clinical diagnosis of RP was undoubted. To qualify for this study a patient must have had proven inflammatory episodes, involving at least two of three sites (auricular, nasal and laryngotracheal cartilage) or one of these sites together with two other manifestations, such as ocular inflammation, hearing loss, vestibular dysfunction or seronegative inflammatory arthritis.

Correspondence: Dr B Lang, Department of Internal Medicine I, Rheumatology/Clinical Immunology Unit, University of Regensburg Medical Center, D-93042 Regensburg, Germany.
Received 25 February 1997; accepted 23 July 1997

Clinical data were obtained by a questionnaire, sent to the patient's physician, requiring data about specific disease manifestations, associated diseases, treatment and follow up.

Serum concentration of aCL (IgG-, IgM- and IgA-isotypes) (ELIAS, Freiburg, Germany), aPS (IgG- and IgM-isotypes) (IMTEC, Zepernick, Germany) and a β 2 GPI (polyvalent) (IMTEC, Zepernick, Germany) were measured using standardized commercially available enzyme linked immunosorbent assays (ELISA).⁶ The results are given in optical densities (OD). Thirty healthy controls were used for comparison (mean age 42.5 ± 5.8 years). Cut off values for positive results were defined as mean plus 3 standard deviations (s.d.) of the results of healthy controls. The cut off values were: aCL IgG: 0.449 OD, aCL IgM: 0.277 OD, aCL IgA: 0.237 OD, aPS IgG: 0.943 OD, aPS IgM: 0.560 OD, a β 2 GPI: 0.360 OD.

Statistical analysis was performed using the chi-square test with Yates' correction.

Clinical and immunogenetic findings of the 21 patients from this study have already been described.^{2,7}

Results

Demographic data

All 21 patients met the inclusion criteria for RP. Nine patients were female and 12 male. The median age at the time of diagnosis was 46.2 years with a range of 17–62 years.

Clinical data

Of the 21 patients, 18 had auricular chondritis, 13 ocular symptoms, 11 nasal chondritis, 10 laryngo-tracheal involvement, eight arthritis, five vertigo, five skin manifestations, four cardiovascular involvement, three hearing loss, two central nervous system involvement and one renal involvement. Some of the patients' clinical manifestations, e.g. cardiac, may not necessarily be manifestations of the underlying RP, but be due to other concomitant conditions. None of the patients showed signs of aPL syndrome like recurrent fetal loss, thrombosis or livedo reticularis. 2 patients suffered from migraine headache, but they had no other signs of systemic vasculitis. 6 of the 21 patients had an associated disease (2 SLE, 4 rheumatoid arthritis). None of the

remaining 41 patients with RP, where no sera were available for aPL testing, had signs of an aPL syndrome.

Laboratory findings

Almost all patients showed non-specific increased inflammatory activity in the laboratory tests. Erythrocyte sedimentation rate was elevated in 18 patients, C-reactive protein in 10 patients. In 11 patients serum protein electrophoresis showed signs of chronic inflammation. In two patients mild (Coombs test negative) anaemia and thrombocytopenia was detected. No patient had prolonged activated partial thromboplastin time or thrombocytopenia or positive Coombs test. Rheumatoid factor was found in four patients, three patients had anti-nuclear antibodies. The two patients with associated SLE had positive anti-nuclear antibodies with a homogenous pattern in the indirect immunofluorescence staining, and had anti-dsDNA antibodies.

The serum concentration of aCL (IgG-, IgM- and IgA-isotypes), aPS (IgG- and IgM-isotypes) and a β 2 GPI are shown in Figures 1 and 2. In eight patients elevated aPL were detected. No patient had elevated a β 2 GPI. In patient no. 7, aCL IgG-isotype (0.463 OD) and aPS IgG- (1.181 OD) were significantly elevated. This patient suffered from associated SLE. The other patient with SLE (no. 11) had also elevated aCL IgA- (1.014 OD) and IgM-isotype (0.863 OD). Patients with RP and associated SLE had significantly more often aPL antibodies with compared patients with RP without SLE (in 4 of 12 determinations vs in 7 of 114 determinations; $P < 0.01$). No other significant association between clinical findings (e.g. thrombosis, recurrent fetal loss, livedo reticularis, cerebral emboli) and aPL could be found.

Discussion

RP is an extremely rare inflammatory disorder, affecting cartilaginous structures throughout the body.^{4,5,7} There is strong evidence suggesting immunologically mediated mechanisms in its pathogenesis. As in many other autoimmune diseases a high prevalence of aPL can be found, we addressed the question whether this is also the case in RP. Some recent anecdotal cases suggested the possibility of an association between aPL and RP. Balsa-Criado *et al.*⁸ reported one patient with lupus anticoagulant among eight patients with RP. Quere *et al.*⁹ described two patients with RP and positive lupus anticoagulant suffering from vasculitis and thrombosis. In a recent

anti-cardiolipin-antibodies

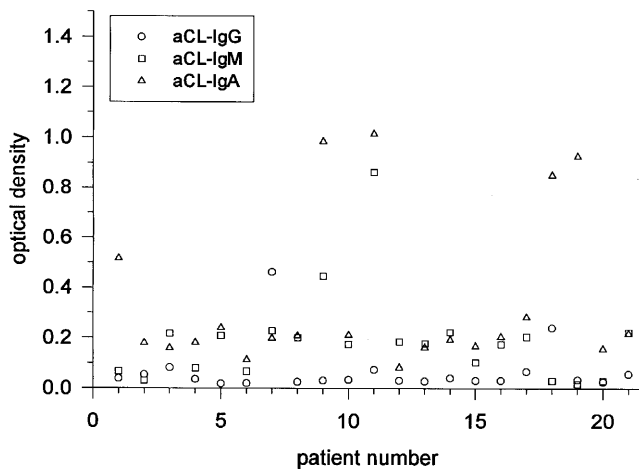


Figure 1 Concentration of anti-cardiolipin antibodies (aCL) in 21 patients with relapsing polychondritis (cut off values for positive results: aCL IgG: 0.449 OD, aCL IgM: 0.277 OD, aCL IgA: 0.237 OD).

anti-phosphatidylserine-antibodies

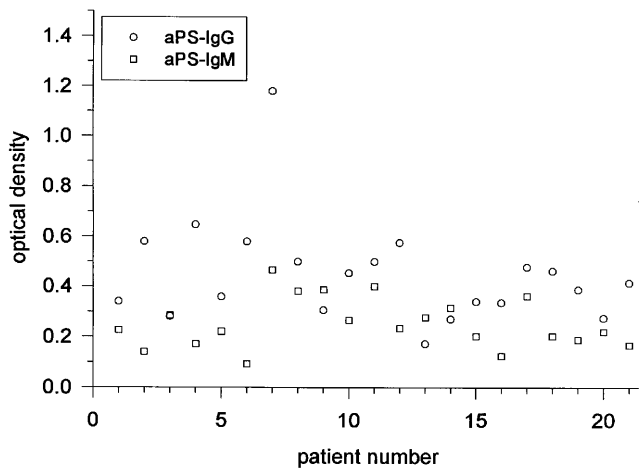


Figure 2 Concentration of anti-phosphatidylserine antibodies (aPS) in 21 patients with relapsing polychondritis (cut off values for positive results: aPS IgG: 0.943 OD, aPS IgM: 0.560 OD).

study of a large series of RP patients, five were identified to have an aPL syndrome.¹⁰ Four of these five patients had other associated conditions (three of them SLE, at least one had myelodysplasia). The authors of this study concluded that aPL syndrome may occur in RP, but is more closely related to associated conditions like SLE.

The purpose of our study was, to evaluate the prevalence of aPL and the aPL syndrome in an unselected cohort of RP patients. In a recent study on 62 patients with RP we could not identify a single patient with signs of a aPL syndrome.⁷ In the present study on 21 patients with RP we found elevated aCL in eight of them, aPS in one patient and $\alpha\beta 2$ GPI in no patient. Interestingly the two patients with extremely high aPL had associated SLE. Therefore, we speculate that aPL elevation in these two patients is more likely to be associated with the underlying SLE than with RP. None of the eight patients with elevated aPL had signs of an aPL syndrome.

In conclusion, there is no convincing evidence that RP itself is associated with aPL. If aPL occurs in RP it seems to be more closely related to associated conditions like SLE. Therefore patients with RP and clearly elevated aPL serum concentrations should be carefully investigated for other autoimmune diseases such as SLE.

Acknowledgement

We thank all of our colleagues who contributed blood samples and clinical data from their patients and Mrs Daniela E. Hant for expert technical assistance.

References

- Herman JH. Polychondritis. In: 3rd edn. Kelley WN, Harris ED, Ruddy S, Sledge CD (eds). *Textbook of Rheumatology*, WB Saunders: Philadelphia, 1993; pp. 234–238.
- Lang B et al. Susceptibility to relapsing polychondritis is associated with HLA-DR4. *Arthritis Rheum* 1993; **36**: 660–664.
- Wang Y et al. Antiphospholipid antibodies in systemic lupus erythematosus: clinical and laboratory associations in 111 patients. *Rheumatol Int* 1990; **10**: 75–80.
- McAdam LP, O'Hanlan MA, Bluestone R, Pearson CM. Relapsing polychondritis: prospective study of 23 patients and a review of the literature. *Medicine (Balt)* 1976; **55**: 193–215.
- Michet CJ, McKenna CH, Luthra HS, O'Fallon WM. Relapsing polychondritis. Survival and predictive role of early disease manifestation. *Ann Intern Med* 1986; **104**: 74–78.
- Harris EN. Antiphospholipid antibodies. *Br J Haematol* 1990; **74**: 1–9.
- Zeuner M et al. Relapsing polychondritis: clinical and immunogenetic analysis of 62 patients. *J Rheumatol* 1997; **24**: 96–101.
- Balsa-Criado A et al. Lupus anticoagulant in relapsing polychondritis. *J Rheumatol* 1990; **17**: 1426–1427
- Quere I, Biron C, Dubois A. Lupus anticoagulant and thrombosis in relapsing polychondritis. *J Rheumatol* 1996; **23**: 946–947.
- Piette JC et al. APS in relapsing polychondritis (RP) is more closely related to associated conditions than to RP itself. *Lupus* 1996; **5**: 550 (abstract 190).