

# Foot & Ankle International

<http://fai.sagepub.com/>

## Fibromatosis of the Plantar Fascia: Diagnosis and Indications For Surgical Treatment

Hans R. Dürr, Andreas Krödel, Hans Trouillier, Andreas Lienemann and Hans J. Refior

*Foot Ankle Int* 1999 20: 13

DOI: 10.1177/107110079902000103

The online version of this article can be found at:

<http://fai.sagepub.com/content/20/1/13>

Published by:



<http://www.sagepublications.com>

On behalf of:



AMERICAN ORTHOPAEDIC  
FOOT & ANKLE SOCIETY.

RECONSTRUCTION • SPORTS MEDICINE • TRAUMA • TECHNOLOGY

[American Orthopaedic Foot & Ankle Society](#)

Additional services and information for *Foot & Ankle International* can be found at:

**Email Alerts:** <http://fai.sagepub.com/cgi/alerts>

**Subscriptions:** <http://fai.sagepub.com/subscriptions>

**Reprints:** <http://www.sagepub.com/journalsReprints.nav>

**Permissions:** <http://www.sagepub.com/journalsPermissions.nav>

>> [Version of Record](#) - Jan 1, 1999

[What is This?](#)

## Fibromatosis of the Plantar Fascia: Diagnosis and Indications For Surgical Treatment

Hans R. Dürr,\*‡ Andreas Krödel,\* Hans Trouillier,\* Andreas Lienemann,† and Hans J. Refior\*  
Munich, Germany

### ABSTRACT

Plantar fibromatosis is a rare, benign lesion involving the plantar aponeurosis. Eleven patients (13 feet) underwent 24 operations, including local excision, wide excision, or complete plantar fasciectomy. Clinical results were evaluated retrospectively. There were no differences among the subgroups in postoperative complications. Two primary fasciectomies did not recur. Three of six revised fasciectomies, seven of nine wide excisions, and six of seven local excisions recurred. Our results indicate that recurrence of plantar fibromatosis after surgical resection can be reduced by aggressive initial surgical resection.

### INTRODUCTION

Plantar fibromatosis, or Ledderhose's disease, is a benign lesion involving the plantar aponeurosis. It is composed of highly differentiated fibroblasts that eventually invade the overlying skin or deep structures by growing in an infiltrative manner. Although locally aggressive, these fibromatoses do not metastasize. The degree of similarity between the palmar contractures known as Dupuytren's disease and plantar fibromatosis has led to the term "Dupuytren's disease of the plantar fascia."<sup>7</sup> In European literature, the term "Ledderhose's disease" is commonly used.

Despite numerous reports on Dupuytren's contracture of the hand, descriptions of similar plantar lesions are limited.<sup>13,26b</sup> After Ledderhose reported approximately 50 cases in 1897,<sup>26a</sup> none were reported until 1948 when Meyerding and Shellito<sup>28</sup> published 24 cases of simultaneous plantar and palmar contrac-

tures. Allen et al.<sup>1</sup> described their experience with 69 patients in 1955. Four recent series presented at least 10 patients.<sup>3,5,34,41</sup> During the last 15 years, 11 cases of plantar fibromatosis have been treated surgically at our institution. This article describes clinical manifestation, diagnostic procedures, operative techniques, and results of those cases.

### Selection of Patients and Methods Used

Between October 1980 and December 1995, 11 patients (five men and six women) with plantar fibromatosis were treated. Mean age at onset of symptoms was 33 years (range, 9–53 years). Three left feet, two right feet, and six cases with both feet were involved. Nonsurgical treatment included orthoses providing sufficient pain relief in four feet of the six patients with both sides involved. In these four cases, only one foot each was surgically treated, whereas in two patients, both feet were surgically treated. Twenty-four operations were performed on 13 feet. Eight ultrasound and four magnetic resonance imagings (MRI) were performed on those lesions suspected of infiltrations of deep anatomic layers. This was based on the size and extent of the lesions. Statistical analysis was performed using the chi-square test to measure the influence of surgery.

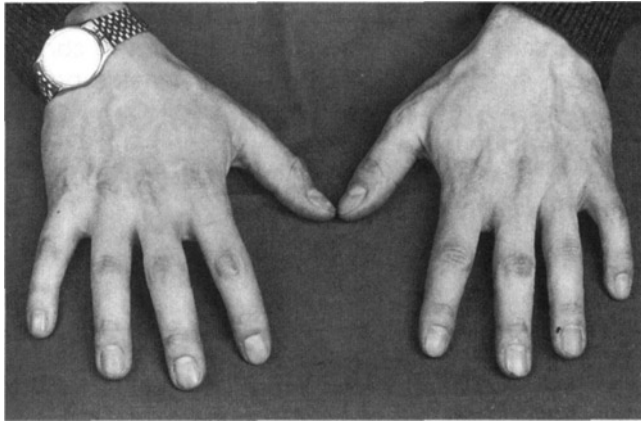
### Clinical Features

All patients complained of pain and swelling on the sole of the affected foot. The time between onset of symptoms and first operation varied from 5 months to 15.5 years (mean, 44 months; median, 18 months). One patient had a simultaneous Dupuytren's contracture of the hand, another had Peyronie's disease. All other cases represented isolated lesions of the feet. In three cases, knuckle pads (Fig. 1) were apparent. One woman had the onset of the disease at 9 years old. She had a positive family history, with both sisters and one brother affected by plantar fibromatosis and a mother who had palmar fibromatosis; her brother and his son also suffered from Dupuytren's disease. Three

\* Department of Orthopaedics and Orthopaedic Surgery, Ludwig-Maximilians-University Munich, Klinikum Grosshadern, Munich, Germany.

† Institute of Radiology.

‡ To whom requests for reprints should be addressed at Orthopädische Klinik und Poliklinik, Ludwig-Maximilians-Universität München, Klinikum Grosshadern, D-81366 München, Marchionistr. 15.



**Fig. 1.** Knuckle pads (circumscribed fibromatosis at the level of the proximal interphalangeal joints) in a patient with plantar fibromatosis.

other patients reported knuckle pads in the family. All other presumed factors showed no relevance to the disease. Most lesions were located in the medial aspect of the proximal third of the plantar fascia.

## RESULTS

Surgical procedures were classified into three groups: (1) local excision (LEX) close to the lesion, performed in our first cases and in patients treated first elsewhere, (2) wide excision (WEX) in noninvolved tissue, with a margin of 2 to 3 cm, and (3) complete plantar fasciectomy (PFC). The incision used was either straight or S-shaped, as proposed by Curtin.<sup>9</sup> In cases of involvement of the skin, a sparse resection (avoiding need for a skin-graft) was performed. A plaster splint was used for 2 weeks. After satisfactory

**TABLE 2**  
Treatment and Results of 24 Operations on 13 Feet Involved by Plantar Fibromatosis

Procedures	Number	Recurrence
PFC—Primary surgery	2	0
WEX—Primary surgery	8	6
Second surgery		
PFC	2	1 (no 3rd surgery)
WEX	1	1 (no 3rd surgery)
LEX	3	2
Third surgery		
PFC	2	0
LEX—Primary surgery	3	3 (1 no 2nd surgery)
Second surgery		
LEX	1	1
PFC	1	1 (no 3rd surgery)
Third surgery		
PFC	1	1

PFC, plantar fasciectomy; WEX, wide excision; LEX, local excision; N = 24.

wound healing, the patient was allowed weightbearing after 3 to 4 weeks.

Treatments and recurrences are shown in Tables 1 and 2. In the two primary lesions after complete PFC, there was no recurrence. Of the eight WEX primary lesions, six (80%) recurred and all three LEX primary lesions recurred.

Altogether, 16 recurrences were observed and 11 were operated on, resulting in a total of 24 procedures that were performed in our patient group. Eight procedures were complete PFC with three recurrences on follow-up (38%). Nine were WEX with seven recurring lesions (78%), and seven procedures consisted of LEX with six recurrences (86%). Neither type of surgery nor bilateral involvement showed a significant influence on

**TABLE 1**  
Treatment and Results in 11 Patients with Plantar Fibromatosis

Patient	Age <sup>a</sup> , sex, foot	Primary surgery	1. Recur. (months)	Second surgery	2. Recur. (months)	Third surgery	3. Recur. (Months)	Disease-free months
1. (O.K.)	45, m, l	PFC	—	—	—	—	—	2
2. (B.L.)	12, f, l	LEX	48	LEX	48	PFC	44	No
3. (T.M.)	31, m, r	WEX	—	—	—	—	—	45
4. (K.W.)	27, m, r	WEX	11	PFC	12	—	—	No
4. (K.W.)	35, m, l	LEX	24	PFC	11	—	—	No
5. (A.K.)	54, f, l	WEX	—	—	—	—	—	158
6. (N.R.)	23, m, l	WEX	6	LEX	2	PFC	—	138
6. (N.R.)	23, m, r	WEX	6	LEX	1	PFC	—	138
7. (S.H.)	29, m, r	PFC	—	—	—	—	—	97
8. (S.H.)	50, f, l	WEX	4	PFC	—	—	—	24
9. (F.G.)	42, f, l	WEX	1	WEX	9	—	—	No
10. (B.C.)	32, f, l	WEX	11	LEX	—	—	—	28
11. (E.M.)	44, f, l	LEX	43	—	—	—	—	No

Recur., recurrence; m, male; f, female; l, left; r, right; patients 4 and 6 with involvement of both feet; PFC, plantar fasciectomy; LEX, local excision; WEX, wide excision.

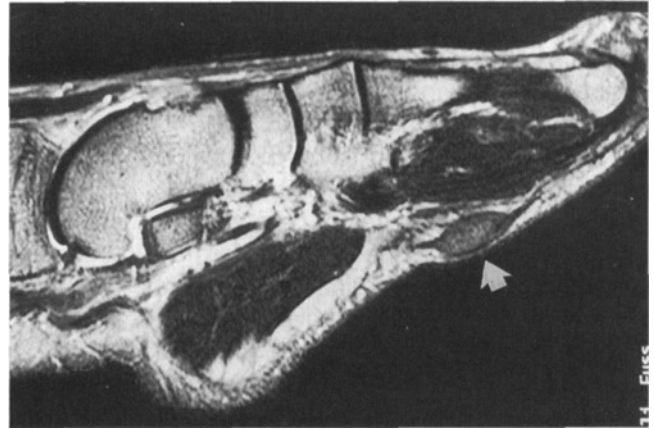
<sup>a</sup> At first surgery.

outcome ( $P = 0.095$ ) because of the small number of subjects. No patient disease-free at final examination complained of any complication caused by surgery. All patients with recurring disease complained of swelling and pain at times but refused further surgery.

## DISCUSSION

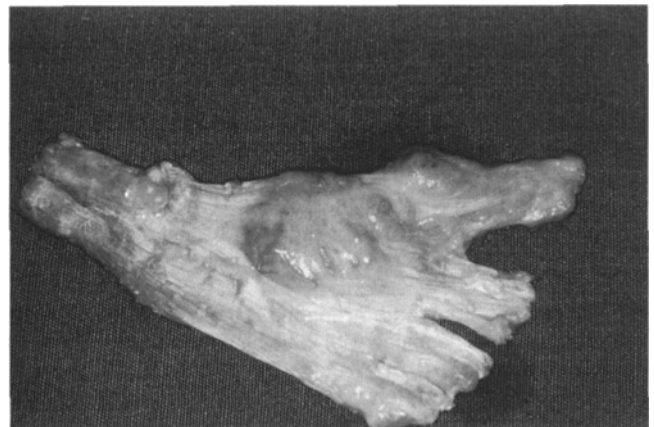The clinical features of plantar fibromatosis are either swelling or pain and swelling. A contracture of the toes does not usually occur,<sup>26b</sup> but has been reported.<sup>8</sup> Three phases of the disease are described: (1) a proliferative phase with increased fibroblastic activity, succeeded by (2) an involutinal phase with formation of typical nodules, and then (3) a residual phase with reduced fibroblastic activity, maturation of collagen, and subsequent contractures of tissue.<sup>14,27</sup> There seems to be an association among four fibrosing diseases: Dupuytren's hand contracture, plantar fibromatosis, knuckle pads, and Peyronie's disease.<sup>6,25,38,47</sup> We noted this in our cases, but their cause has not yet been established. There is an increase in the ratio of type III to type I collagen.<sup>19</sup> It is thought this is caused by inhibition of production of type I collagen through increased density of fibroblasts.<sup>31</sup> Modified fibroblasts present in granulation tissue called "myofibroblasts"<sup>18</sup> and in other fibromatoses<sup>17,21</sup> may contribute to the clinically important contracture of the lesions.<sup>24</sup> Also frequently found are macrophages potentially acting as inflammatory cells. The cause of Dupuytren's disease has been suggested to be capillary occlusion by endothelial proliferation leading to fibroblast-stimulating hypoxia.<sup>2</sup> Perivascular accumulations of inflammatory cells have also been noted,<sup>39</sup> but their influence seems unclear.

The lesions of plantar fibromatosis are found in extracompartmental soft tissue. Plain radiographs and bone scans are not usually helpful.<sup>26b</sup> Sonography may help determine the extent of the lesion,<sup>36</sup> but MRI is the most helpful diagnostic procedure.<sup>23,30,44</sup> On T1-weighted conventional spin-echo images, the lesions have nearly the same low-signal intensity as adjacent muscle (Fig. 2). On T2-weighted images, an increase in intensity may be a sign of more aggressive growth.<sup>16</sup> This appearance is rare. Enhancement with contrast-medium is variable, and distinguishing fibromatosis from malignant processes is often difficult. MRI should be considered as modality of choice for evaluating plantar fibromatosis, especially in large or recurrent cases where it is helpful to define the extent of the lesion.<sup>33</sup> In recurrent cases, it may be difficult to distinguish recurrences from scarring, which has similar characteristics on MRI.



**Fig. 2.** Sagittal T1-weighted conventional SE-image of a foot with plantar fibromatosis related to the superficial surface of the plantar aponeurosis. Signal intensity of the lesion is minimally higher than that of adjacent muscle.

Operative treatment is indicated by pain and local aggressiveness. LEX and WEX showed identical rates of recurrence (7/9 vs 6/7) among our cases. Published reports indicate that WEX and extended PFC give better results than LEX alone.<sup>4,5,10-12,15,20,22,32,35,37,40-42,45,46</sup> In recurrent cases, complete removal of the plantar fascia and the fascial bands to the toes should be performed (Fig. 3).<sup>43</sup> In five of our cases, involvement of skin was evident. Four cases showed recurring disease after PFC, indicating that in these cases, partial skin excision and skin grafting might be necessary. There are reports that postoperative adjuvant treatment with radiation may influence the rate of recurrence. However, because the lesion is benign and radiation in the long term may lead to secondary malignancies, this should only be recommended for those who fail to respond to surgical treatment.<sup>29</sup>



**Fig. 3.** (Same patient as Fig. 2) Resected specimen showing the lesion medially in the plantar fascia, with extension to the subcutaneous side. Treated by total plantar fasciectomy.

## SUMMARY

Plantar fibromatosis is a benign lesion of unknown origin. Heredity and the simultaneous occurrence of other fibromatoses are reported in the literature and in our cases. MRI proved to be the best diagnostic imaging procedure. Nonsurgical treatment is initially recommended, but in cases of pain and aggressiveness, plantar fasciectomy should be performed. In our series with incomplete or marginal resection, there were recurrences which needed to be salvaged with wider resections. Initial surgical procedure should hence be a complete removal of the plantar fascia (PFC). In cases where PFC was performed, we did not see any recurrences, but these have been reported in about 10% of cases. Recurrence after a second surgical treatment is closely linked to the extent of the primary resection.

## REFERENCES

- Allen, R.A., Woolner, L.B., and Chormley, R.K.: Soft tissue tumors of the sole with special reference to plantar fibromatosis. *J. Bone Joint Surg.*, **37A**:14–26, 1955.
- Andrew, J.G., Andrew, S.M., Ash, A., and Turner, B.: An investigation into the role of inflammatory cells in Dupuytren's disease. *J. Hand Surg.*, **16B**:267–271, 1991.
- Aviles, E., Arlen, M., and Miller, T.: Plantar fibromatosis. *Surgery*, **69**:117–120, 1971.
- Bardelli, M., D'Arienzo, M., and Veneziani, C.: [Ledderhose's disease] La malattia di Ledderhose. *Arch. Putti. Chir. Organi. Mov.*, **39**:335–339, 1991.
- Bottinelli, N.F.: [Ledderhose disease (case considerations)] Malattia di Ledderhose (considerazioni casistiche). *Chir. Ital.*, **34**:1005–1008, 1982.
- Caroli, A., Zanasi, S., Marcuzzi, A., Guerra, D., Cristiani, G., and Ronchetti, I.P.: Epidemiological and structural findings supporting the fibromatous origin of dorsal knuckle pads. *J. Hand Surg.*, **16B**:258–262, 1991.
- Cavolo, D.J., and Sherwood, G.F.: Dupuytren's disease of the plantar fascia. *J. Foot Surg.*, **21**:12–15, 1982.
- Classen, D.A., and Hurst, L.N.: Plantar fibromatosis and bilateral flexion contractures: a review of the literature. *Ann. Plast. Surg.*, **28**:475–478, 1992.
- Curtin, J.W.: Fibromatosis of the plantar fascia: surgical technique and design of skin incision. *J. Bone Joint Surg.*, **47A**:1605–1608, 1965.
- Dartoy, C., Le Nen, D., Riot, O., Lefevre, C., and Courtois, B.: [Ledderhose's disease: report of 7 cases] Maladie de Ledderhose: a propos de 7 cas. *J. Chir. (Paris)*, **127**:533–536, 1990.
- Delgadillo, L.A., and Arenson, D.J.: Plantar fibromatosis: surgical considerations with case histories. *J. Foot Surg.*, **24**:258–265, 1985.
- Dell'Orto, R., and Percudani, W.: [Ledderhose's disease] La malattia di Ledderhose. *Chir. Ital.*, **31**:101–107, 1979.
- Dupuytren, G.: Retraction permanente des doigts: leçons orales de clinique chirurgicale, faites à L'Hôtel-Dieu de Paris. *Germer-Baillière*, **1**:2–24, 1832.
- Enzinger, F.M., and Weiss, S.W.: Fibromatoses. In Enzinger, F.M., and Weiss, S.W. (eds.), *Soft Tissue Tumors* (3rd ed.). St. Louis, Mosby Year-Book, 1994, pp. 201–229.
- Federzoni, F.: [Ledderhose's disease. (Presentation of 3 cases)] Il morbo di Ledderhose. (Presentazione di tre casi). *Arch. Putti. Chir. Organi. Mov.*, **21**:251–259, 1966.
- Feld, R., Burk, D.L., McCue, P., Mitchell, D.G., Lackmann, R., and Rifkin, M.D.: MRI of aggressive fibromatosis: frequent appearance of high signal intensity on T2-weighted images. *Magn. Reson. Imaging*, **8**:583–588, 1990.
- Gabbiani, G., and Majno, G.: Dupuytren's contracture: fibroblast contraction? an ultrastructural study. *Am. J. Pathol.*, **66**:131–146, 1972.
- Gabbiani, G., Ryan, G.B., and Majno, G.: Presence of modified fibroblasts in granulation tissue and their possible role in wound contraction. *Experientia*, **27**:549–550, 1971.
- Gelbermann, R.H., Amiel, D., Rudolph, R.M., and Vance, R.M.: Dupuytren's contraction of plantar fascia. *J. Bone Joint Surg.*, **62A**:425–432, 1980.
- Haedicke, G.J., and Sturim, H.S.: Plantar fibromatosis: an isolated disease. *Plast. Reconstr. Surg.*, **83**:296–300, 1989.
- Hasegawa, T., Hirose, T., Kudo, E., Abe, J., and Hizawa, K.: Cytoskeletal characteristics of myofibroblasts in benign neoplastic and reactive fibroblastic lesions. *Virchows Arch. A. Pathol. Anat. Histopathol.*, **416**:375–382, 1990.
- Kates, M., Cohen, S., Reese, H.W., Belden, L.M., Jacoby, R.P., Sheridan, L.E., Gorman, M.R., Pitha, N.R., and Kratzer, D.E.: A clinical conference on plantar fibromatosis. *J. Am. Podiatr. Med. Assoc.*, **64**:427–434, 1974.
- Kirby, E.J., Shreff, M.J., and Lewis, M.M.: Soft-tissue tumors and tumor-like lesions of the foot. An analysis of eighty-three cases. *J. Bone Joint Surg.*, **71A**:621–626, 1989.
- Kiryu, H., Tsuneyoshi, M., and Enjoji, M.: Myofibroblasts in fibromatoses: an electron microscopic study. *Acta Pathol. Jpn.*, **35**:533–547, 1985.
- 25a. Lagier, R., and Meinecke, R.: Pathology of "knuckle pads": study of four cases. *Virchows Arch. A. Pathol. Anat. Histopathol.*, **365**:185–191, 1975.
- 25b. Ledderhose, H.: Zur Pathologie der Aponeurose des Fusses und der Hand. *Langenbecks Arch. Klin. Chir.*, **55**:694–712, 1897.
- Lee, T.H., Wapner, K.L., and Hecht, P.J.: Plantar fibromatosis. *J. Bone Joint Surg.*, **75A**:1080–1084, 1993.
- Luck, J.V.: Dupuytren's contracture. *J. Bone Joint Surg.* **41A**:635–664, 1959.
- Meyerding, H.W., and Shellito, J.G.: Dupuytren's contracture of the foot. *J. Internat. Coll. Surg.* **11**:595–603, 1996.
- Miralbell, R., Suit, H.D., Mankin, H.J., Zuckerberg, L.R., Stracher, M.A., and Rosenberg, A.E.: Fibromatoses: from postsurgical surveillance to combined surgery and radiation therapy. *Int. J. Radiat. Oncol. Biol. Phys.* **18**:535–540, 1990.
- Morrison, W.B., Schweitzer, M.E., Wapner, K.L., and Lackman, R.D.: Plantar fibromatosis: a benign aggressive neoplasm with a characteristic appearance on MR images. *Radiology*, **193**:841–845, 1994.
- Murrell, G.A.C., Francis, M.J.O., and Bromley, L.: The collagen changes of Dupuytren's contracture. *J. Hand Surg.* **16B**:263–266, 1991.
- Oster, J.A., and Miller, A.E.: Resection of plantar fibromatosis with interposition of Marlex surgical mesh. *J. Foot Surg.* **25**:217–225, 1986.
- Pasternack, W.A., and Davison, G.A.: Plantar fibromatosis: staging by magnetic resonance imaging. *J. Foot Ankle. Surg.* **32**:390–396, 1993.

34. **Pickren, J.W., Smith, A.G., Stevenson, T.W., and Stout, A.P.:** Fibromatosis of the plantar fascia. *Cancer* **4**:846-1951.
35. **Rao, G.S., and Luthra, P.K.:** Dupuytren's disease of the foot in children; a report of three cases. *Br. J. Plast. Surg.* **41**:313-315, 1988.
36. **Reed, M., Gooding, G.A., Kerley, S.M., Himebaugh Reed, M.S., and Griswold, V.J.:** Sonography of plantar fibromatosis. *J. Clin. Ultrasound* **19**:578-582, 1991.
37. **Runkel, N., Gohring, U., Friedl, W., and Roeren, T.:** [Isolated Ledderhose fibromatosis plantaris] Isolierte Fibromatosis plantaris Ledderhose. *Chirurg* **64**:589-591, 1993.
38. **Snyder, M.:** Dupuytren's contracture and plantar fibromatosis: is there more than a causal relationship? *J. Am. Podiatry Assoc.* **70**:410-415, 1980.
39. **Ushijima, M., Tsuneyoshi, M., and Enjoji, M.:** Dupuytren type fibromatoses. A clinicopathologic study of 62 cases. *Acta Pathol. Jpn.* **34**:991-1001, 1984.
40. **Villiger, K.J.:** [Fibromatosis plantaris Ledderhose (Dupuytren's contracture of the foot sole)] Fibromatosis plantaris Ledderhose (Dupuytren'sche Kontraktur an der Fussohle). *Schweiz. Med. Wochenschr.* **112**:653-658, 1982.
41. **Wapner, K.L., Ververeli, P.A., Moore, J.H., Hecht, P.J., Becker, C.E., and Lackman, R.D.:** Plantar fibromatosis: a review of primary and recurrent surgical treatment. *Foot Ankle Int.* **16**:548-551, 1995.
42. **Warthan, T.L., Rudolph, R.I., and Gross, P.R.:** Isolated plantar fibromatosis. *Arch. Dermatol.* **108**:823-825, 1973.
43. **Westerkamp, M.:** A case history of recurrent plantar fibromatosis (Dupuytren's contracture). *J. Foot Surg.*, **17**:73-74, 1978.
44. **Wetzel, L.H., and Levine, E.:** Soft-tissue tumors of the foot: value of MR imaging for specific diagnosis. *Am. J. Roentgenol.*, **155**:1025-1030, 1990.
45. **White, S.W.:** Plantar Fibromatosis. *Arch. Dermatol.*, **117**:375-376, 1981.
46. **Wiseman, G.G.:** Multiple recurring plantar fibromatosis and its surgical excision. *J. Foot Surg.*, **22**:121-125, 1983.
47. **Wooldridge, W.E.:** Four related fibrosing diseases. When you find one, look for another. *Postgrad. Med.*, **84**:269-71, 274., 1988.

## ERRATUM

In the article, "Fibromatosis of the Plantar Fascia: Diagnosis and Indications for Surgical Treatment," by Hans R. Dürr et al. (1999;20:13-17, January issue), on page 13, Reference 26b should be "26" and Reference 26a should be "25b." On page 15, Reference 26b should be "26," Reference 25 should be "25a," and Reference 26b should be "26."