

# Foot & Ankle International

<http://fai.sagepub.com/>

## Preoperative Imaging of Charcot Neuroarthropathy in Diabetic Patients: Comparison of Ring PET, Hybrid PET, and Magnetic Resonance Imaging

Stefan Höpfner, Christoph Krolak, Stefan Kessler, Reinhold Tiling, Kirsten Brinkbäumer, Klaus Hahn and Stefan Dresel

*Foot Ankle Int* 2004 25: 890

DOI: 10.1177/107110070402501208

The online version of this article can be found at:

<http://fai.sagepub.com/content/25/12/890>

Published by:



<http://www.sagepublications.com>

On behalf of:



[American Orthopaedic Foot & Ankle Society](http://www.aofas.org)

Additional services and information for *Foot & Ankle International* can be found at:

Email Alerts: <http://fai.sagepub.com/cgi/alerts>

Subscriptions: <http://fai.sagepub.com/subscriptions>

Reprints: <http://www.sagepub.com/journalsReprints.nav>

Permissions: <http://www.sagepub.com/journalsPermissions.nav>

>> [Version of Record](#) - Dec 1, 2004

[What is This?](#)

## Preoperative Imaging of Charcot Neuroarthropathy in Diabetic Patients: Comparison of Ring PET, Hybrid PET, and Magnetic Resonance Imaging

Stefan Höpfner, M.D.<sup>1</sup>; Christoph Krolak, M.D.; Stefan Kessler, M.D.; Reinhold Tiling, M.D.; Kirsten Brinkbäumer; Klaus Hahn, M.D.; Stefan Dresel, M.D.  
Giessen, Germany

### ABSTRACT

**Introduction:** The treatment of Charcot neuroarthropathy in the feet of diabetic patients has undergone fundamental changes in the last few years. Formerly, treatment was almost exclusively limited to nonoperative measures; since the late 1990s, however, current practice has shifted to early, stage-appropriate surgical therapy. The objective of this prospective study was to investigate the value of two types of positron emission tomography (PET) in the preoperative evaluation of diabetic patients with Charcot foot deformities. **Materials and Methods:** Ring [<sup>18</sup>F]FDG (2-fluoro-2-deoxy-glucose) and hybrid PET were compared to magnetic resonance imaging (MRI). MRI, ring PET, and hybrid PET imaging were used as part of the preoperative evaluation of 16 patients with type II diabetes mellitus. The diagnosis of Charcot neuropathy of the foot requiring operative treatment had been made on the basis of clinical and radiographic criteria. **Results:** Of 39 Charcot lesions confirmed at surgery, 37 were detected by ring PET, 30 by hybrid PET, and 31 by MRI. **Conclusions:** PET (ring or hybrid) can be used in the evaluation of patients with metal implants that would compromise the accuracy of MRI. Another advantage of PET is its ability to distinguish between inflammatory and infectious soft-tissue lesions, and between osteomyelitis and Charcot

neuroarthropathy. The differentiation between Charcot neuroarthropathy and florid osteomyelitis provides the surgeon with important additional information that often is unavailable from MRI. Because it provides important additional data, ring PET may be preferable to radiography and MRI in the preoperative evaluation of patients with Charcot neuroarthropathy of the foot. Hybrid PET, because of its poorer resolution compared to ring PET, appears less suitable for routine clinical application.

**Key Words:** Bone Detritus; Charcot Neuroarthropathy; Diabetic Neuropathy; Magnetic Resonance Imaging; Positron Emission Tomography

### INTRODUCTION

Charcot neuroarthropathy is a late complication of diabetes mellitus. According to the definition proposed in 1868 by J. M. Charcot, it consists of a non-infectious destruction of single or multiple bone and joint structures in patients with concomitant neuropathy, most often affecting the skeletal structures of the foot.<sup>4,6</sup> Autonomic neuropathy results in local hyperperfusion with pathologic innervation of the vascular musculature. This, in turn, leads to maximal vascular dilatation with resultant absorption of bone (bone detritus). Disease progression is accompanied by associated sensory and sensorimotor neuropathy, with reduced touch and pain sensation. Chronic malpositioning of the limb with associated microtrauma and macrotrauma results in long-term destruction of both soft-tissue and bony structures (Figure 1).<sup>11</sup>

If Charcot neuroarthropathy of the foot is not diagnosed early and treated appropriately, physical disability usually occurs within an average of 10 years.<sup>6,12</sup> Worldwide, foot-related morbidity is one of the leading reasons for in-patient hospital admissions of patients with diabetes mellitus and is associated with a

<sup>1</sup>Department of Radiology, Justus-Liebig-University of Giessen, Klinikstr. 36, 35385 Giessen, Germany

Department of Nuclear Medicine, Ludwig-Maximilians-University of Munich, Ziemssenstrasse 1, 80336 Munich, Germany

Department of Clinical Radiology, Ludwig-Maximilians-University of Munich, Ziemssenstrasse 1, Germany

Department of Surgery, Ludwig-Maximilians-University of Munich, Nussbaumstrasse 20, 80336 Munich, Germany

#### Corresponding Author:

Dr. med. Stefan Höpfner, M.D.

Department of Radiology

Justus-Liebig-University of Giessen

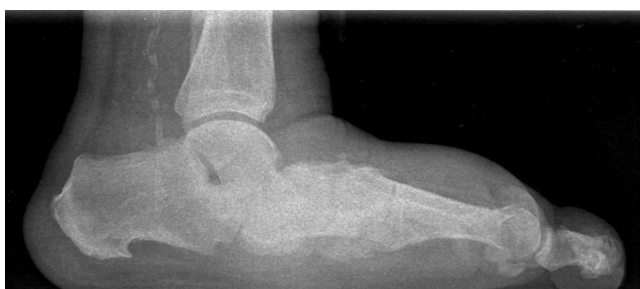Klinikstrasse 36

D-35385 Giessen

Germany

E-mail: stefan.hoepfner@web.de

For information on prices and availability of reprints, call 410-494-4994 X226



**Fig. 1:** A 65-year-old male with a 23-year history of type-II diabetes mellitus and pain in both feet. Radiograph shows damage to the arch of the foot resulting in a rocker-bottom deformity.

corresponding financial impact on national health-care systems.<sup>3,5</sup> These facts have contributed to fundamental changes in the management of Charcot neuroarthropathy of the foot in the last few years.

Formerly, treatment was almost exclusively limited to nonoperative measures; since the late 1990s, however, current practice has shifted to early, stage-appropriate operative.<sup>3,7</sup> Although nonoperative treatment is still the standard treatment of the disease in its initial stages (Eichenholtz stages I and II),<sup>2</sup> operative management is considered much earlier in the course of the disease. Indications for surgery include soft-tissue infections, joint instability, recurring collapse of the foot, and foot deformities. To determine if surgery is indicated, the surgeon must consider, in addition to anatomic conditions in the limb, the extent of osseous involvement. Preoperative evaluation seeks to establish anatomic conditions in the limb using conventional radiography (Figure 1). If radiographic findings are inadequate, computed tomography (CT) using a thin-layer technique can be added. Because of the frequency of poor wound healing and recurrent disease in diabetic patients, it is increasingly important to detect both early-stage Charcot lesions and secondary inflammatory changes in bony and soft-tissue structures.

Diagnostic imaging techniques also are essential to differentiate between Charcot neuroarthropathy and osteomyelitis because their surgical treatments are very different. Often, because clinical features alone are not sufficient to distinguish between the two, contrast enhanced magnetic resonance imaging (MRI) is used. The bone marrow edema that is typical in patients with diabetes can make it difficult to distinguish between unspecific coincidental reactions in adjacent bone and early-stage Charcot neuroarthropathy.<sup>10,14</sup> The efficacy of MRI also is compromised by the presence of metal artifacts in patients who have had earlier operations.

The objective of this prospective study was to determine the value of positron emission tomography (PET) in the preoperative evaluation of diabetic patients with Charcot neuroarthropathy of the foot and to

compare the efficacy of ring PET and hybrid PET with that of MRI.

## METHODS AND MATERIALS

Sixteen patients (nine males, seven females) with an average age of 60.1 years ( $\pm 10$  years) had both MRI and PET scanning between June, 2001, and August, 2002, as part of their preoperative evaluations of Charcot foot conditions. All 16 patients had type II diabetes mellitus. The decision to proceed to operative treatment of their Charcot foot deformities was based on clinical and radiographic findings. No more than 1 week elapsed between preoperative radiographic examination and nuclear medical imaging. PET examinations were conducted after a minimum 12-hour fasting period. The radiopharmaceutical 2-<sup>[18F]</sup>-fluorodeoxyglucose (FDG) was injected (250 to 370 MBq) immediately after blood glucose levels were determined. In all patients, ring PET scanning was begun 45 minutes after injection of the radiopharmaceutical and was followed immediately by hybrid PET scanning.

Ring PET examinations were done with a Siemens ECAT EXACT HR+ (Siemens/CTI, Knoxville, TN). The emission data was acquired in 3D mode beginning at the tips of the toes and proceeding proximally (five bed positions; 8 minutes per bed position; field of view per bed position, 15.5 cm). The acquired data was then subjected to iterative reconstruction. Datasets were reoriented in transverse, coronal, and sagittal projections.

The hybrid PET examinations were done with a Marconi AXIS  $\gamma$ -PET<sup>2</sup> scanner (Marconi Medical Systems, Cleveland, OH) in list mode using an axial filter. The acquisition of two bed positions (35 minutes per bed position; field of view per bed position, 42 cm) began at the tips of the toes. Data were rebinned in a 128  $\times$  128 matrix and iteratively reconstructed. Transverse, coronal, and sagittal layers were generated.

MRI examinations were done with a Siemens Harmony scanner (1.0 Tesla field strength; Siemens AG, Erlangen, Germany) using a standardized protocol with a sagittal short time inversion recovery (STIR) sequence and subsequent coronal T1 and T2-weighted sequences. After intravenous administration of contrast medium (gadolinium DTPA, 0.2 ml/kg body weight), a fat-suppressed T1-weighted sequence in coronal and sagittal projections was acquired.

All findings were interpreted using a special evaluation form by two experienced examiners blinded to the results of the other imaging method. The bony structures of the foot were subdivided into six subgroups: calcaneus, talus, navicular bone, cuboid bone, cuneiform bones and metatarsals. Also evaluated were the soft-tissue structures of the affected feet

and the intraarticular spaces, particularly the transverse tarsal articulation (Chopart line) and Lisfranc articulation, both of which are frequently affected in Charcot foot deformities (Table 1).

Findings at subsequent surgery were compared to those of the three imaging techniques.

## RESULTS

Sixteen diabetic patients with Charcot neuroarthropathy of the foot had MRI, ring PET, and hybrid PET examinations as part of their preoperative evaluations. Thirty-nine lesions consistent with Charcot neuroarthropathy were identified by diagnostic imaging and confirmed at surgery, including 24 osseous lesions with bone detritus formation typical of Charcot neuroarthropathy without evidence of osteomyelitis; six secondary, circumscribed foci of inflammation in adjacent soft tissue with no evidence of infection; and nine lesions with inflammatory tissue along typically affected articulations such as those in the ankle and at the Chopart and Lisfranc articulations.

Of the 39 lesions confirmed at surgery, 37 (95%) were successfully identified by ring PET. All lesions involving inflammation of soft tissue or articulation lines were correctly identified. In evaluating disease involving the bones, only two small sites of detritus formation escaped detection. In general, areas of detritus formation exhibit only moderately increased glucose metabolism and at visual interpretation usually are not typical of acute osteomyelitis or soft-tissue infection. The average standardized uptake value (SUV) was 1.8 (range 0.5 to 4.1). It also was easy to differentiate between disease foci limited to the bone and secondary soft-tissue involvement. The exact localization of lesions is presented in Table 1.

In contrast, hybrid PET successfully identified only 30 lesions (77%). Particularly prone to evade detection were small osseous lesions involving the talus or calcaneus and the tarsals. Inflammatory processes in typically affected articulations were detected with equal

efficacy by both hybrid and ring PET, whereas two smaller soft-tissue lesions were not correctly diagnosed by hybrid PET.

MRI correctly identified 31 of the 39 lesions (79%) confirmed by surgery. This lower detection rate can be explained by the inclusion of three patients with metal implants in whom the resulting extensive metal artifacts interfered with the detection of six lesions. If these three patients are excluded, there is little difference between MRI (31 of 33 lesions correctly detected, 94%) and ring PET (32 of 33 lesions, 97%). With the exception of a small area of bone detritus formation, MRI successfully identified all sites of osseous, articulation-line, and soft-tissue inflammation.

Because of significant contrast medium uptake in the T1-weighted sequences and the bone marrow edema in the STIR sequences, it was not always possible to definitively differentiate between infected bone detritus and an osteomyelitic lesion or between soft-tissue inflammation and soft-tissue infection.

All 16 patients had type-II diabetes mellitus. Despite a minimum of 12 hours of fasting before examination, the blood glucose concentrations measured before administration of the radiopharmaceutical ranged from 92 to 254 mg/dl (average 153.8 mg/dl). A comparison of PET examinations obtained from patients with blood glucose concentrations within the normal range (80 to 120 mg/dl) and from those with blood sugar levels of more than 200 mg/dl revealed better image quality in the group with the lower blood glucose concentrations. There was, however, no difference in the rate of detecting Charcot lesions between the two groups using either PET modality.

## DISCUSSION

In diabetic patients with Charcot neuroarthropathy, the decisive issue to be clarified at preoperative evaluation, besides identification of the osseous structures involved, is the exclusion of acute inflammatory or infectious disease processes, such as osteomyelitis. The

**Table 1:** Surgical Findings Compared to the MRI and PET Findings

	Talus/ Calcaneus	Navicular/Cuboid/ Cuneiform	Metatarsals	Articulations	Soft tissue	Σ
<b>Surgical findings</b>	11	10	3	9	6	<b>39</b>
<b>Ring PET</b>	10	9	3	9	6	<b>37</b>
<b>Hybrid PET</b>	8	7	2	9	4	<b>30</b>
<b>MRI</b>	8	8	3	7	5	<b>31</b>

Findings in 16 patients with diabetic Charcot neuroarthropathy. The findings of diagnostic imaging methods are correlated with surgical findings. Lesions detected by imaging methods outside of the surgical field are not included in the table.

extent of bony destruction is determined with radiography and thin-layer computed tomography (CT).<sup>6</sup> While these methods are considered sufficiently accurate for routine clinical use, conventional radiography often misses early-stage Charcot lesions, and findings may be normal during the acute phase.<sup>12</sup> For this reason and because of the frequency of disease recurrence and wound-healing disorders in patients with Charcot neuroarthropathy, there has been increasing recognition of the importance of distinguishing between this entity and infectious processes of the bone and adjacent soft tissues.

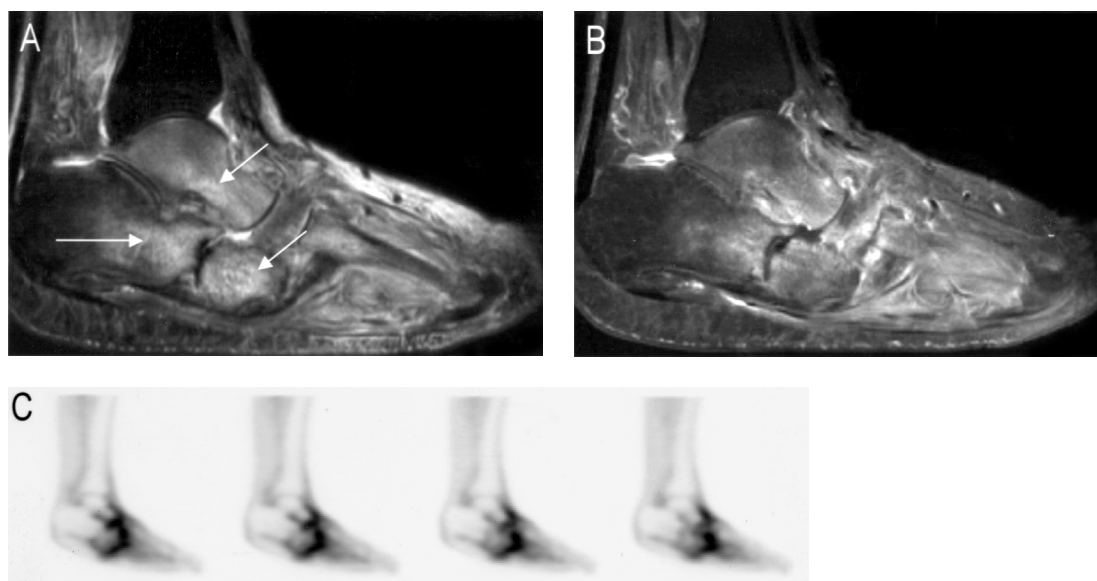
At present, this is done almost exclusively by contrast-enhanced MRI. The current international literature reports generally good results with this modality.<sup>10,14</sup> However, overestimation of the extent of inflammation caused by associated edema of adjacent osseous and soft-tissue structures can cause difficulty in interpreting MRI findings of bone marrow edema for differentiation between lesions typical of Charcot neuroarthropathy and those secondary to foci of infection, such as osteomyelitis.

Our results indicate that both ring PET and MRI are effective in the preoperative detection of small, inflammatory, non-infectious Charcot lesions (Figure 2). The most important limitation of MRI is its restricted efficacy in patients with metal implants. In the present study, all but one of the lesions confirmed during surgery were successfully identified by ring PET, the exception being a small area of osseous involvement of the talus near the Chopart articulation. Both methods, however, identified the Chopart articulation as a site of

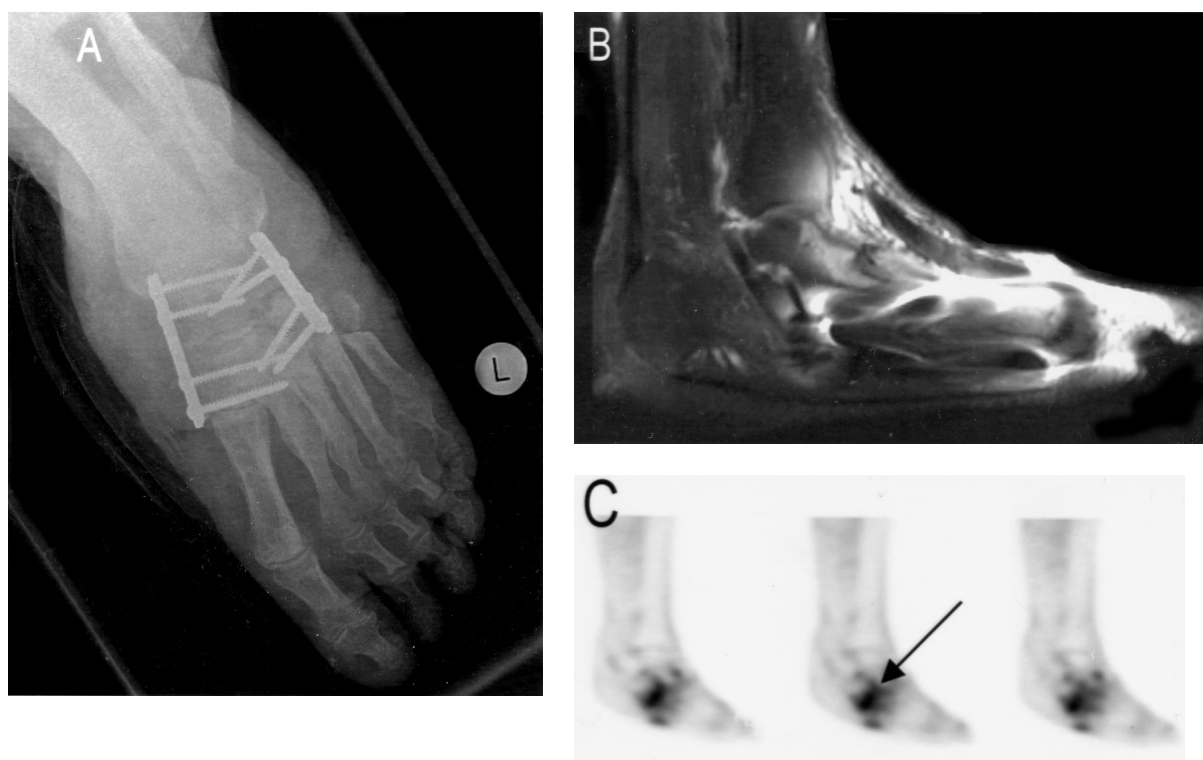
disease involvement in this patient, and the failure to identify the additional bone detritus did not markedly affect preoperative planning. Our MRI findings correspond with current published data describing the early detection of Charcot lesions with MRI.<sup>6,8,10</sup> Our experience, however, also corresponds to reports of the difficulty of interpreting MRI findings because of the overestimation of the extent of inflammation based on associated edema in adjacent and nearby osseous and soft-tissue structures.

In patients who have metal implants, artifact formation normally precludes adequate MRI examination. Our study showed that ring PET or hybrid PET can supply adequate information in such patients, as confirmed by surgical findings (Figure 3). An additional advantage of PET is the capacity to differentiate between inflammatory and infectious soft-tissue lesions and between Charcot lesions and osteomyelitis on the basis of glucose metabolism. Charcot lesions at a mean SUV of 1.8 (range 0.5–4.1) can be distinguished from florid osteomyelitis, which typically has a much higher SUV.<sup>13</sup> This differentiation on the basis of increased glucose metabolism provides the surgeon with important additional data that often is not reliably provided by MRI.

Other imaging methods that have been compared with conventional radiography or MRI for evaluation of Charcot neuroarthropathy include three-phase bone scanning, indium-111 white blood cell (WBC) scintigraphy and technetium-99m hexamethylpropyleneamine oxine (HMPAO) WBC scintigraphy. Mougendre and Pioror<sup>9</sup> showed that, in the evaluation of patients



**Fig. 2:** A 69-year-old male with 25-year history of type-II diabetes mellitus. **A**, MRI fat-suppressed T1-weighted sequence; **B**, MRI STIR sequence; and **C**, PET, all in sagittal projection. Evidence of typical Charcot lesions is present in all imaging methods. MRI overestimates the extent of inflammation because of adjacent and associated edema.



**Fig. 3:** A 58-year-old female with a 4-year history of type-II diabetes mellitus and previous surgery involving the metatarsals of the left foot. **A,** Radiography shows only the metal implant but no new destructive changes. **B,** Because of the extensive metal artifacts, adequate interpretation of MRI findings is impossible. **C,** PET shows typical Charcot lesions in the previous surgical zone at the Chopart articulation.

with Charcot neuroarthropathy of the foot, comparable results were obtained by bone scans and conventional radiography. Lipman et al.<sup>8</sup> Reported that MRI was more effective in the detection of osteomyelitis foci, particularly in the tarsals. Leukocyte scintigraphy has been proposed as a method for confirming or excluding osteomyelitis when other imaging methods suggest its presence.<sup>8,9,15</sup> Our results, however, showed both PET and MRI to be effective in detecting osteomyelitis.

Compared to MRI and ring PET, hybrid PET had a lower sensitivity in detecting smaller bone and soft-tissue lesions (diameter of less than 1 cm). In addition to several osseous lesions, some sites of inflammation in soft tissues were missed. While hybrid PET may be acceptable in the evaluation of patients with Charcot neuroarthropathy of the foot, it appears to be less suitable as part of preoperative planning than ring PET, which is better able to detect inflammatory lesions.

Despite the very high blood glucose concentrations measured in some patients before administration of the radiopharmaceutical, there was little difference in the detection of Charcot lesions between patients whose blood sugar levels were within normal limits and those with elevated blood glucose levels.

Our data demonstrated that PET provides results comparable to MRI in the preoperative evaluation of

patients with Charcot neuroarthropathy. In addition, PET offers the advantages of being unaffected by metal implants and being able to differentiate between inflammatory and infectious soft-tissue lesions and between osteomyelitis and Charcot lesions on the basis of glucose metabolism with increased FDG uptake (SUV). Because of this ability to provide complementary imaging data, ring PET should be considered as an adjunct to conventional radiography and MRI in the preoperative evaluation of patients with Charcot neuroarthropathy of the foot. Hybrid PET, because of its poorer resolution than ring PET, appears less suitable for routine clinical use.

## REFERENCES

1. Alnafisi, N; Yun, M; Alavi, A: F-18 FDG positron emission tomography to differentiate diabetic osteoarthropathy from septic arthritis. *Clin. Nucl. Med.* **26**:638–639, 2001.
2. Eichenholtz, SN: *Charcot Joints*, Springfield, Charles C. Thomas, 1966.
3. Frykberg, RG; Armstrong, DG; Giurini, J; Edwards, A; Kravette, M; Kravitz, S; Ross, C; Stavosky, J; Stuck, R; Vanore, J: American College of Foot and Ankle Surgeons: Diabetic foot disorders: a clinical practice guideline. *American College of Foot and Ankle Surgeons. J Foot Ankle Surg.* **39**(Suppl. 1):1–60, 2000.
4. Frykberg, RG; Armstrong, DG: *The Diabetic Foot 2001*. A summary of the proceedings of the American Diabetes

- Association's 61st Scientific Symposium. J. Am. Podiatr. Med. Assoc. **92**:2–6, 2002.
5. **Green, MF; Aliabadi, Z; Green, BT**: Diabetic foot: evaluation and management. South. Med. J. **95**:95–101, 2002.
  6. **Kessler, SB; Kalteis, TA; Botzlar, A**: Principles of surgical treatment of diabetic neuropathic osteoarthropathy. Internist (Berl). **40**:1029–1035, 1999.
  7. **Kessler, SB; Kreuz, PC**: Diabetic foot syndrome. When is surgery reliable and necessary? MMW Fortschr. Med. **143**:34–36, 2001.
  8. **Lipman, BT; Collier, BD; Carrera, GF; Timins, ME; Erickson, SJ; Johnson, JE; Mitchell, JR; Hoffmann, RG; Finger, WA; Krasnow, AZ; Hellman, RS**: Detection of osteomyelitis in the neuropathic foot: nuclear medicine, MRI and conventional radiography. Clin. Nucl. Med. **23**:77–82, 1998.
  9. **Maugendre, D; Poirier, JY**: Nuclear medicine in the diagnosis of diabetic foot osteomyelitis. Diabetes Metab. **27**:396–400, 2001.
  10. **Morrison, WB; Ledermann, HP; Schweitzer, ME**: MR imaging of the diabetic foot. Magn. Reson. Imaging Clin. N Am. **9**:603–613, 2001.
  11. **Rajbhandari, SM; Jenkins, RC; Davies, C; Tesfaye, S**: Charcot neuroarthropathy in diabetes mellitus. Diabetologia. **45**:1085–1096, 2002.
  12. **Sommer, TC; Lee, TH**: Charcot foot: the diagnostic dilemma. Am. Fam. Physician. **64**:1591–1598, 2001.
  13. **Sugawara, Y; Braun, DK; Kison, PV; Russo, JE; Zasadny, KR; Wahl, RL**: Rapid detection of human infections with fluorine-18 fluorodeoxyglucose and positron emission tomography: preliminary results. Eur. J. Nucl. Med. **25**:1238–1243, 1998.
  14. **Vesco, L; Boulahdour, H; Hamissa, S; Kretz, S; Montazel, JL; Perlemuter, L; Meignan, M; Rahmouni, A**: The value of combined radionuclide and magnetic resonance imaging in the diagnosis and conservative management of minimal or localized osteomyelitis of the foot in diabetic patients. Metabolism. **48**:922–927, 1999.
  15. **Wegener, WA; Alavi, A**: Diagnostic imaging of musculoskeletal infection. Roentgenography; gallium, indium-labeled white blood cell, gammaglobulin, bone scintigraphy; and MRI. Orthop. Clin. North Am. **22**:401–418, 1991.