

## Glomangioma of the lungs: a rare differential diagnosis of a pulmonary tumour

Glomangiomas (glomus tumours) are uncommon, and in most cases are benign perivascular tumours, usually located in the dermis of the extremities, especially in the subungual region of the fingers. They also occur in other organs and in other regions of the body. Histogenetically, they are derived from modified smooth muscle cells of the glomus apparatus, which is associated with temperature regulation. These tumours are composed of capillaries, sometimes of dilated endothelial bigger vessels surrounded by nests of uniform, cytoplasm-rich cells with isomorphic round or ovoid nuclei (glomus cells). They also contain a variable amount of smooth muscle tissue. Three different types of glomus tumours are described according to their different components. The common form is predominantly made up of glomus cells, with a smaller amount of vessels and smooth muscle cells. The second variant, called “glomangioma”, contains more partly dilated vessels resembling cavernous haemangiomas and is less circumscribed than the common form. In the most rare type, the “glomangiomyoma”, the glomus cells undergo a transition to elongated smooth muscle cells.

Immunohistochemically, glomus tumours usually show a positivity for vimentin and smooth muscle actin and a negativity for cytokeratin, neuroendocrine markers (chromogranin and others), CD31, CD34 and S-100.<sup>1</sup>

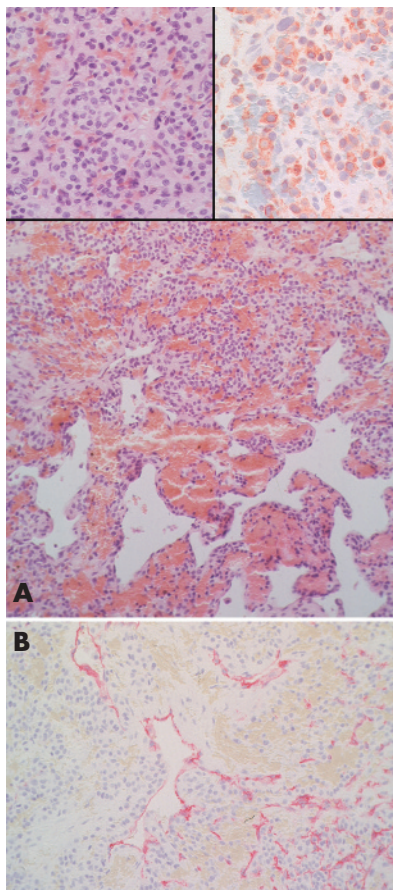
These tumours are very rare in the lungs, and, to our knowledge, only 14 cases have been described, including two malignant glomus tumours.<sup>2–10</sup>

### Case report

A 64-year-old man was admitted to the hospital for resection of a carcinoma of the rectum. The preoperative computed tomography showed a round tumour (3.5 cm) in the left lower lung lobe that was removed 2 weeks after the resection of the rectum.

### Findings

On macroscopic examination, the round tumour was reddish. Histological examination (haematoxylin and eosin, Elastic-van-Gieson, Prussian Blue and periodic-acid Schiff) showed lung tissue with partly compressed, partly hyperaemic and ectatic



**Figure 1** (A) Part of the glomangioma with many partly dilated vessels and the pericapillary cytoplasm-rich cells with small round isomorphic nuclei (haematoxylin and eosin; original magnification  $\times 25$ ). The left inset depicts the typical cells of the glomus tumour at a higher magnification (haematoxylin and eosin; original magnification  $\times 100$ ). The right inset shows cytoplasmic staining of the tumour cells with antibodies against  $\alpha 1$ -smooth muscle actin (original magnification  $\times 100$ ). (B) Transition of the glomangioma from the solid, cell-rich part (left) to the more vascularised area (right; CD34; original magnification  $\times 50$ ).

vessels that exceeded the normal density of alveolar capillaries (fig 1A,B). Cytoplasm-rich cells with round isomorphic nuclei were arranged diffusely perivascularly and in nests. Immunohistologically, the tumour cells featured a cytoplasmic staining for  $\alpha 1$ -smooth muscle actin (fig 1A), whereas the reactions with antibodies against CD31, CD34, pancytokeratin and TTF-1 were negative.

### Comment

On the basis of the histological and immunohistological results, a metastasis of the rectal carcinoma was ruled out and the tumour was identified as a glomangioma of the lung.

The other important differential diagnoses, including carcinoid small-cell lung cancer, melanocytic neoplasms, haemangiopericytoma, smooth muscle neoplasms, paraganglioma and primitive neuroectodermal

tumours, were also excluded by morphology and immunostaining pattern.

**M Rössle**

Institute of Pathology, Kantonsspital St Gallen, St Gallen, Switzerland

**W Bayerle**

Institute of Pathology, Kreisklinik München-Pasing, Munich, Germany

**U Löhrs**

Institute of Pathology, Ludwig-Maximilians-University, Munich, Germany

Correspondence to: M Rössle, Institute of Pathology, Kantonsspital Luzern, 6000 Luzern 16, Switzerland; [matthias.roessle@ksl.ch](mailto:matthias.roessle@ksl.ch)

doi: 10.1136/jcp.2005.031237

Competing interests: None.

### References

- Weiss SW, Goldblum JR, eds. *Perivascular tumors. Enzinger and weiss's soft tissue tumors*. 4th edn. St Louis, MO: Mosby, 2001:985–1001.
- Ueno M, Nakashima O, Mishima M, et al. Pulmonary glomus tumor: CT and MRI findings. *J Thorac Imaging* 2004;131–4.
- Hishida T, Hasegawa T, Asamura H, et al. Malignant glomus tumor of the lung. *Pathol Int* 2003;53:632–6.
- Zhang Y, England DM. Primary pulmonary glomus tumor with contiguous spread to a peribronchial lymph node. *Ann Diagn Pathol* 2003;7:245–8.
- Altorjay A, Arato G, Adame M, et al. Synchronous multiple glomus tumors of the esophagus and lung. *Hepatogastroenterology* 2003;50:687–90.
- Yilmaz A, Bayramgürler B, Aksoy F, et al. Pulmonary glomus tumour: a case initially diagnosed as carcinoid tumour. *Respirology* 2002;7:369–71.
- Gaertner EM, Steinberg DM, Huber M, et al. Pulmonary and mediastinal glomus tumors-report of five cases including a pulmonary glomangiosarcoma: a clinicopathologic study with literature review. *Am J Surg Pathol* 2000;24:1105–14.
- Koss MN, Hochholzer L, Moran CA. Primary pulmonary glomus tumor: a clinicopathologic and immunohistochemical study of two cases. *Mod Pathol* 1998;11:253–8.
- Alt B, Huffer WE, Belchis DA. A vascular lesion with smooth muscle differentiation presenting as a coin lesion in the lung: glomus tumor versus hemangiopericytoma. *Am J Clin Pathol* 1983;80:765–71.
- Tang CK, Tokar C, Foris NP, et al. Glomangioma of the lung. *Am J Surg Pathol* 1978;2:103–9.



## Glomangioma of the lungs: a rare differential diagnosis of a pulmonary tumour

M Rössle, W Bayerle and U Löhrs

*J Clin Pathol* 2006 59: 1000  
doi: 10.1136/jcp.2005.031237

---

Updated information and services can be found at:  
<http://jcp.bmj.com/content/59/9/1000.1.full.html>

---

### References

*These include:*

This article cites 8 articles  
<http://jcp.bmj.com/content/59/9/1000.1.full.html#ref-list-1>

Article cited in:  
<http://jcp.bmj.com/content/59/9/1000.1.full.html#related-urls>

### Email alerting service

Receive free email alerts when new articles cite this article. Sign up in the box at the top right corner of the online article.

---

### Notes

---

To request permissions go to:  
<http://group.bmj.com/group/rights-licensing/permissions>

To order reprints go to:  
<http://journals.bmj.com/cgi/reprintform>

To subscribe to BMJ go to:  
<http://group.bmj.com/subscribe/>