



Case report

Ankylosing Spondylitis and Sarcoidosis - Coincidence or Association? Case Report and Review of the Literature

G. STUCKI, A. VON FELTEN*, R. SPEICH*, B.A. MICHEL

Summary We report a 25-year-old woman presenting with sarcoidosis and bilateral sacroiliitis. Her sarcoidosis related symptoms (malaise, cough and dyspnoea) improved dramatically under treatment with steroids but severe back pain persisted. Only seven similar cases have been described over the last 40 years and the question of a possible association between the two diseases has been raised. However, prevalence data from the literature and the apparent lack of genetic links are better arguments for coincidence than for association.

Key words Ankylosing Spondylitis, Sacroiliitis, Sarcoidosis, HLA-B27, HLA-B8, HLA-DR3.

INTRODUCTION

Since 1951, when Verstraeten (1) reported a first case with both sacroiliitis and sarcoidosis, six similar cases have been described in the literature, including only one female patient. Already Verstraeten and later Martin (2), Deshayes (3), Cabanel (4), Blanchon (5) and Gerster (6) raised the question about a possible association between the two diseases. We report another case of a 25-year-old woman presenting typical findings of sarcoidosis and a six-month history of bilateral iliosacral pain. The probability of an association between the two diseases is discussed.

CASE REPORT

The personal history of the 25-year-old female patient revealed a single episode of lumbar pain on motion irradiating to both legs in 1985; X-rays showed a spondylolisthesis of L5 on S1. Being in good health until February 1990, the patient then noted pain in her mid-back and in the area of the right sacroiliac joint irradiating to the right buttock. Maximum pain regularly interrupted her sleep between one and three o'clock in the

morning. And low back stiffness was present for about two hours after rising. Further symptoms included recurrent fever up to 38°C, poor appetite, and weight loss of 10 kilos within a six-month period. In March 1990 ankylosing spondylitis was diagnosed by a practicing rheumatologist based on symptoms, clinical findings and inflammatory erosive X-ray changes of both sacroiliac joints (Fig. 1). HLA-B27 was positive, an ileocolonoscopy including biopsy and histology examinations of both the ileum and colon were normal, the erythrocyte sedimentation rate (ESR) was 16 mm after 1 hour (Westergren). There was no evidence of presence of another form among the seronegative spondyloarthropathies. In June 1990 the patient was referred to our inpatient clinic for evaluation because of severe general malaise and increasing pain resistant to NSAID's (indomethacin, diclofenac, ibuprofen, phenylbutazone). Upon admission the patient reported severe low back pain irradiating to the buttocks, dyspnoea and palpitation when climbing two flights of stairs, and a nonproductive cough. The clinical examination revealed limited painful motion of both lumbar (Schober Index 10/11 cm) and thoracic spine in all directions. The thoracic excursion was limited to 80/83 cm. The sacroiliac provocation tests were strongly positive on both sides. No other significant findings were present. Laboratory screening showed an ESR of 34 mm after 1 hour, a C-reactive protein of 36.1 mg/l (upper limit 10 mg/l), a slight thrombocytosis of 443 ×

Department of Rheumatology and Physical Therapy, *Department of Internal Medicine, University Hospital, Zurich, Switzerland.

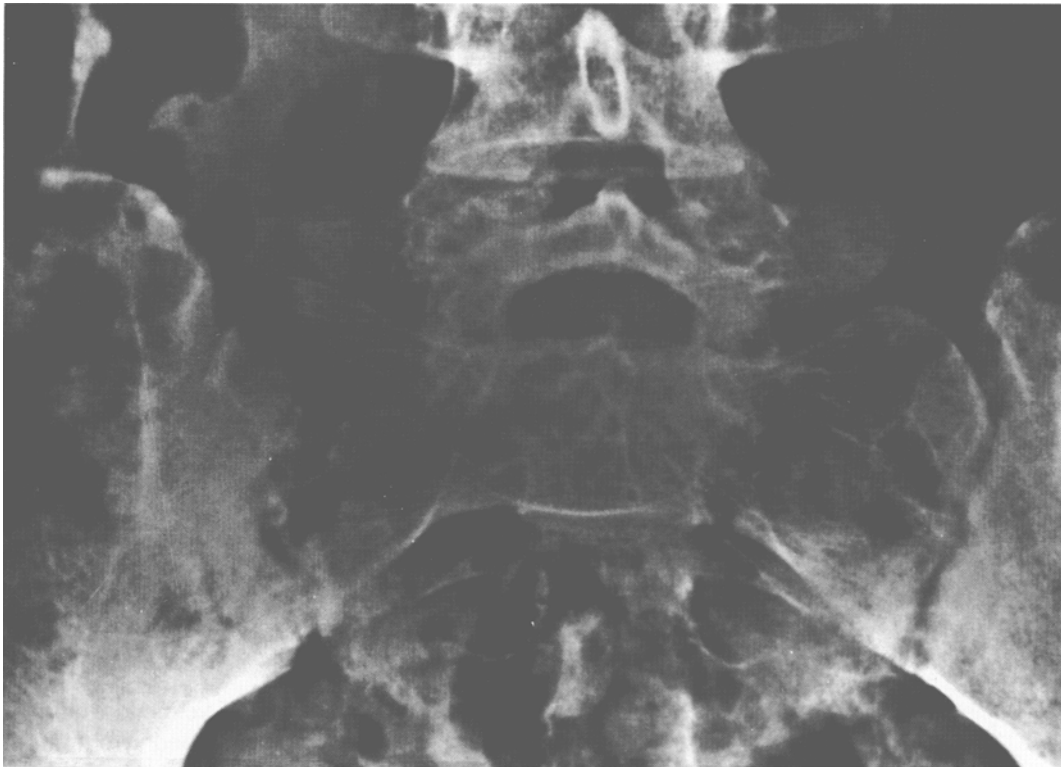

Fig. 1: Bilateral sacroiliitis on ap view.

Table 1: Case reports with both ankylosing spondylitis and sarcoidosis

Author (year of publication)	Sex	Age	Musculoskeletal symptoms (age at onset)	Manifestations of sarcoidosis (age at onset)	Time interval (months)	Therapy	Course
Verstraeten (1951)	m	36	ankylosing spondylitis (30)	bihilar lymphadenopathy (36)	72	none	?
Martin (1953)	m	58	ankylosing spondylitis (45 ?)	bihilar lymphadenopathy (38)	84(?)	none	subsequent pulmonary fibrosis
Deshayes (1965)	m	48	ankylosing spondylitis (40)	bihilar lymphadenopathy, pulmonary fibrosis (40)	?	prednisolone	less back pain under steroids
Brun (1966)	f	34	left sacroiliitis (34)	bihilar lymphadenopathy, pulmonary fibrosis (33)	8	steroids, chemotherapy	?
Cabanel (1973)	m	40	bilateral sacroiliitis (24)	bihilar lymphadenopathy, pulmonary fibrosis (24)	0 (?)	chemotherapy, phenylbutazone	subsequent oligoarthritis (knee, hip) and ankylosing spondylitis
Blanchon (1976)	m	24	left sacroiliitis (21)	pulmonary fibrosis, parotitis, peripheral lymphadenopathy (18)	12	prednisone	subsequent bony cysts (hand, feet), skin ulceration, epididymitis
Gerster (1981)	m	27	bilateral sacroiliitis, relapsing uveitis (24)	bihilar lymphadenopathy, erythema nodosum, arthritis left ankle (25)	6	phenylbutazone	subsequent bihilar lymphadenopathy; left ankle arthritis and erythema nodosum disappear; low back pain persists.

$10^3/\mu\text{l}$ and normocalcaemia (the reported incidence of hypercalcaemia in sarcoidosis varies from 2 to 63%, (7)). The angiotensin converting enzyme level was also within normal limits (44% of patients with bihilar lymphadenopathy but normal lung parenchyma have angiotensin converting enzyme levels within normal limits, (8)). On

chest X-ray (Fig. 2) a bihilar lymphadenopathy and a normal lung parenchyma were found and confirmed by computerized tomography. Pulmonary function tests revealed a moderate restrictive lung disease with a mild obstructive component, and a slightly decreased carbon monoxide diffusing capacity. Transbronchial biopsy

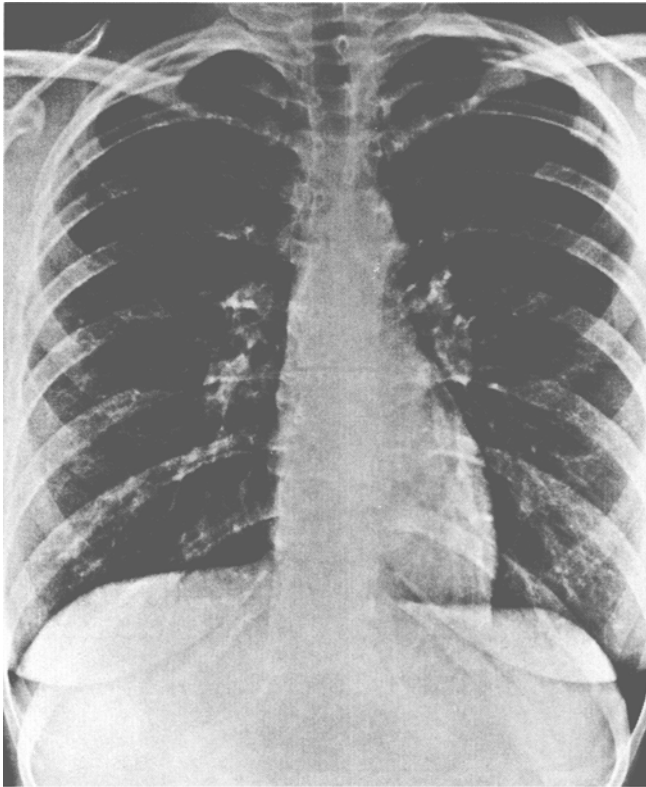


Fig. 2: Chest roentgenogram showing bilateral hilar lymphadenopathy.

showed multiple noncaseating granulomas with epithelioid and multinucleated giant cells (Fig. 3), and bronchioalveolar lavage yielded an increased helper T-cell to suppressor T-cell ratio of 4.5 : 1 (a ratio of over 3.5 : 1 yielded a sensitivity of 53.2% and a specificity of 92.8% in accord with reference 9). The ratio in the blood was 2.1 : 1. All acid-fast and fungal stains and cultures were negative. Electrocardiogram, echocardiography, and ophthalmologic examination were normal. Under treatment with prednisone starting at 50 mg per day, general malaise, dyspnoea and cough disappeared, and ESR (6 mm/1 hour), C-reactive protein (16 mg/l), pulmonary function tests and bilateral lymphadenopathy returned to normal. After a follow-up of one year, however, the patient still suffers from severe low back pain exacerbating at night despite high doses of indomethacin. A tissue typing for the HLA antigens revealed the following results : A1, - ; B8, 27 ; DR3, 4 (DRw52, 53 ; DQw2, 3).

DISCUSSION

This is a report of a 25-year-old woman with ankylosing spondylitis who developed symptomatic pulmonary sarcoidosis. Despite prompt improvement of the sarcoidosis related malaise, dyspnoea and cough as well as the ESR under treatment with prednisone, persistent in-

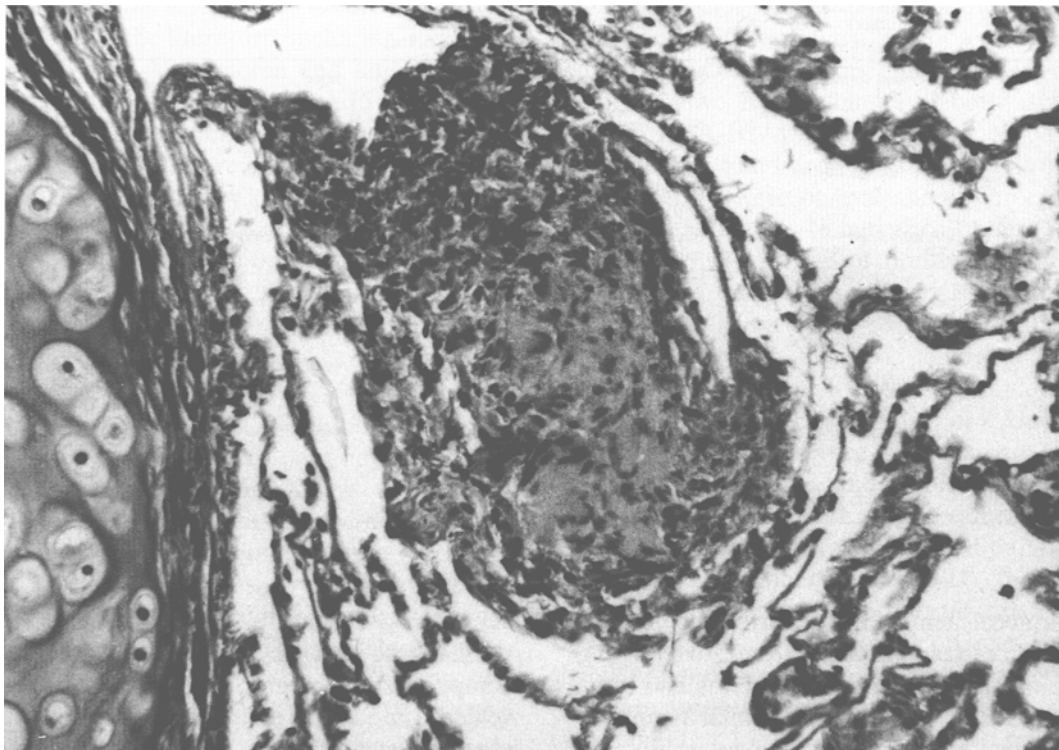


Fig. 3: Transbronchial biopsy showing noncaseating granuloma with epithelioid cells including a multinuclear giant cell.

inflammatory back pain was noted despite additional NSAID therapy. This difference between the therapeutic responses of pulmonary and musculoskeletal symptoms suggests the presence of different pathogenetic mechanisms involved in the two disorders. Based on epidemiological data there is no reason to assume an association of the two entities each having a relatively high prevalence. The prevalence of ankylosing spondylitis is reported as 1 per 1000 population (10), and the prevalence of sarcoidosis varies from 0.04 in Spain to 64 per 1000 population in Sweden (11). Therefore, based on pure coincidence, prevalence data for the two disorders are to be expected in the order of 0.00004 to 0.064 per 1000, the numbers being even higher if association of the two diseases is assumed. In the literature, however, only seven similar cases were reported over a period of 39 years indicating the lack of an association between sarcoidosis and ankylosing spondylitis ((1-6,12), Table I). A genetically-determined predisposition to develop ei-

ther sarcoidosis or ankylosing spondylitis has been noted in certain groups of patients. HLA-DR5 was significantly increased in an endemic cluster of patients with sarcoidosis in Germany (13,14), and HLA-B8 has been associated with acute sarcoidosis - related arthritis (15) and with spontaneous resolution (16). HLA-B8 and HLA-DR3 have been associated with acute onset of sarcoidosis with arthritis (17,18). On the other hand, there is a clear association of ankylosing spondylitis with HLA-B27 (19). However, no common genetic links have been identified for the two disorders. Interestingly, in our patient we found HLA-B27 as well as HLA-B8 and HLA-DR3 to be positive. The presence of the typical HLA specificities for both diseases may indicate the coexistence of two independent disease processes.

In conclusion, response to therapy, prevalence data from the literature and the apparent lack of genetic links are better arguments for coincidence than for association.

REFERENCES

1. Verstraeten, J.M., Bekaert, J. Association de spondylite ankylosante et de sarcoidose. *Acta Tuberc Belg* 1951, 42, 149-151.
2. Martin, E., Fallet, G.H. Pneumopathies chroniques et rhumatisme. *Schweiz Med Wochenschr* 1953, 83, 776-782.
3. Deshayes, P., Desseauve, J., Hubert, J., Lemerrier, J.P., Geoffroy, Y. Un cas de polyarthrite au cours d'une sarcoidose. Un cas de spondylarthrite ankylosante au cours d'une sarcoidose. *Rev Rhum* 1965, 32, 671-674.
4. Cabanel, G., Jacquot, F., Phelip, X., Gras, J.P., Mouries, D. Les formes articulaires de la sarcoidose. *Sem Hôp Paris* 1973, 49, 3051-3060.
5. Blanchon, P., Paillas, J., Lauriat, H., Tominez, G. Localisations pelvi-rachidiennes et rachidiennes de la sarcoidose de B.B.S.. *Ann Med Interne* 1976, 127, 843-848.
6. Gerster, J.C., Chappuis, P. Association d'une sarcoidose aiguë et d'une spondylarthrite ankylosante. *Schweiz Rundschau Med* 1981, 70, 2356-2359.
7. Goldstein, R.A., Israel, H.L., Becker, K.L., Moore, C.F. The infrequency of hypercalcemia in sarcoidosis. *Am J Med* 1971, 51, 21-30.
8. Studdy, P.R., Lapworth, R., Bird, R. Angiotensin converting enzyme and its clinical significance-a review. *J Clin Pathol* 1983, 36, 938-947.
9. Costabel, U., Teschler, H., Guzman, J., Kroegel, C. Bronchoalveoläre Lavage: Zwischenbilanz nach zehn Jahren klinischer Anwendung. *Med Klin* 1990, 85, 367-387.
10. Carter, E.T. Epidemiology of ankylosing spondylitis in Rochester, Minnesota, 1935-1973. *Arthritis Rheum* 1979, 22, 365-370.
11. Teirstein, A.S., Lesser, M. Worldwide distribution and epidemiology of sarcoidosis. In: *Sarcoidosis and Other Granulomatous Diseases of the Lung* Vol 20. Ed.: Fanburg, B.L., Marcel Dekker, Inc 1983, 101-134.
12. Brun, J., Pozzetto, H., Buffat, J.J., Soustelle, J., Vauzelle, J.L., Patin, R. Sarcoidose vertébrale et sacro-iliaque avec image de pseudo-abscess pottique. *Presse Med* 1966, 74, 511-515.
13. Nowack, D., Goebel, K.M. Genetische und diagnostische Bedeutung der HLA-Merkmale bei der Sarkoidose. *Schweiz Med Wschr* 1986, 116, 1479-1480.
14. Nowack, D., Goebel, K.M. Genetic aspects of sarcoidosis. *Arch Intern Med* 1987, 147, 481.
15. Brewerton, D.A., Cockburn, C., James, D.C., James, D.G., Neville, E. HLA antigens in sarcoidosis. *Clin Exp Immunol* 1977, 27, 227-229.
16. Smith, M.J., Turton, C.W.G., Turner-Warwick, M., Morris, L.M., Lawler, S.D. Association of HLA B8 with spontaneous resolution in sarcoidosis. *Thorax* 1981, 36, 296-298.
17. Hedfors, E., Lindström, F. HLA-B8/DR3 in sarcoidosis. Correlation to acute onset disease with arthritis. *Tissue Antigens* 1983, 22, 200-203.
18. Kremer, J.M. Histologic findings in siblings with acute sarcoid arthritis: Association with the B8, DR3 phenotype. *J Rheumatol* 1986, 13, 593-597.
19. Khan, M.A. HLA and ankylosing spondylitis. In: *Ankylosing Spondylitis - New Clinical Applications* Vol. I. Editor: Calabro, J.J., Dick C, Lancaster (England) MTP Press Limited 1987, 23.

Received: 2 December 1991; Revision-accepted: 24 March 1992
 Correspondence to: G. STUCKI, M.D.,
 Department of Rheumatology, University Hospital, Gloriastr. 25,
 CH-8091 Zurich.