

452-10


Volume 151

January 1994

Number 1

The Journal of UROLOGY®

Official Journal of the American Urological Association, Inc.
Founded In 1917 By Hugh Hampton Young



Annual Meeting, American Urological Association, Inc., San Francisco, California, May 14-19, 1994

78

The Journal of UROLOGY®

Volume 151

January 1994

Number 1

CLINICAL UROLOGY

State of Art Article

- Urologists on Tightrope: Coping With Changing Economy. *E. T. Goluboff and C. A. Olsson* 1

Original Articles

- Effect of Alkaline Citrate Therapy on Clearance of Residual Renal Stone Fragments After Extracorporeal Shock Wave Lithotripsy in Sterile Calcium and Infection Nephrolithiasis Patients. *E. Cicerello, F. Merlo, G. Gambaro, L. Maccatrozzo, A. Fandella, B. Baggio and G. Anselmo* 5
- Management of Atherosclerotic Renal Artery Disease in Younger Patients. *A. Fergany, A. C. Novick and D. A. Goldfarb* 10
- Complications of Intracavitary Bacillus Calmette-Guerin After Percutaneous Resection of Upper Tract Transitional Cell Carcinoma. *G. C. Bellman, P. Sweetser and A. D. Smith* 13
- Content of Urokinase-Type Plasminogen Activator and Tumor Recurrence in Superficial Bladder Cancer. *Y. Hasui, K. Marutsuka, S. Nishi, S. Kitada, Y. Osada and A. Sumiyoshi* (Editorial Comments by M. J. Droller, J. M. Kozlowski and E. M. Messing) 16
- Megadose Vitamins in Bladder Cancer: Double-Blind Clinical Trial. *D. L. Lamm, D. R. Riggs, J. S. Shriver, P. F. vanGilder, J. F. Rach and J. I. DeHaven* 21
- Intravesical Mitomycin C and Doxorubicin Sequential Therapy for Carcinoma In Situ of Bladder: Longer Followup Result. *H. Sekine, I. Fukui, T. Yamada, F. Ohwada, M. Yokokawa and H. Ohshima* 27
- Radical Cystectomy for Stages Ta, Tis and T1 Transitional Cell Carcinoma of Bladder. *C. L. Amling, J. B. Thrasher, H. A. Frazier, R. K. Dodge, J. E. Robertson and D. F. Paulson* (Editorial Comments by M. J. Droller, H. W. Herr and G. Sufrin) 31
- Deoxyribonucleic Acid Content and Survival Rates of Patients With Transitional Cell Carcinoma of Bladder. *H. Al-Abadi and R. Nagel* 37
- P-Glycoprotein Expression in Bladder Cancer. *J. Park, N. Shinohara, M. Liebert, L. Noto, A. Flint and H. B. Grossman* 43
- Editorial:** Bladder Cancer. *M. J. Droller* 47
- High Association of Oncogenic Human Papillomaviruses With Carcinomas of Female Urethra: Polymerase Chain Reaction-Based Analysis of Multiple Histological Types. *J. S. Wiener and P. J. Walther* 49
- Impotence and Its Medical and Psychosocial Correlates: Results of Massachusetts Male Aging Study. *H. A. Feldman, I. Goldstein, D. G. Hatzichristou, R. J. Krane and J. B. McKinlay* 54
- Possible Ontogenic Etiology for Idiopathic Left Varicocele. *H. U. Braedel, J. Steffens, M. Ziegler, M. S. Polsky and M. L. Platt* 62
- Deoxyribonucleic Acid Ploidy in Seminomas With and Without Syncytiotrophoblastic Cells. *G. Baretton, J. Diebold, T. DePascale, R. Bussar-Maatz, L. Weissbach and U. Löhns* 67
- Primary Chemotherapy for Stage II Nonseminomatous Germ Cell Tumors of Testis. *A. Horwich, A. Norman, C. Fisher, W. F. Hendry, J. Nicholls and D. P. Dearnaley* (Editorial Comments by J. P. Richie, J. P. Donohue and A. Yagoda) 72
- Management of Benign Prostatic Hyperplasia by Transurethral Laser Ablation in Patients Treated With Warfarin Anticoagulation. *D. M. Bolton and A. J. Costello* 79
- Urinary Prostate Specific Antigen Levels After Radical Prostatectomy. *T. K. Takayama, R. L. Vessella, M. K. Brawer, L. D. True, J. Noteboom and P. H. Lange* 82
- Use of Prostate Specific Antigen and Prostate Specific Antigen Density in Diagnosis of Prostate Cancer in Community Based Urology Practice. *F. M. Rommel, V. E. Agusta, J. A. Breslin, H. W. Huffnagle, C. E. Pohl, P. R. Sieber and C. A. Stahl* 88
- Measurement of Serum Prostate Specific Antigen Using IMx Prostate Specific Antigen Assay. *G. G. Klee, L. A. Dodge, H. Zincke and J. E. Oesterling* 94
- Systematic Sextant Biopsies in 651 Patients Referred for Prostate Evaluation. *P. Hammerer and H. Huland* 99
- Editorial:** Prostate Cancer. *W. H. Cooner* 103
- Ciprofloxacin as Prophylaxis for Urinary Tract Infection: Prospective, Randomized, Cross-Over, Placebo Controlled Study in Patients With Spinal Cord Lesion. *F. Biering-Sørensen, N. Høiby, A. Nordenbo, M. Ravnborg, B. Bruun and V. Rahm* 105

Contents continued on page A9

Urologists At Work

Acute Hemostasis During Laparoscopic Procedures: Method for Intraoperative Application of Hemostatic Material. *K. Kerbl and R. V. Clayman* 109

Urological Neurology and Urodynamics

Prospective Evaluation of Terazosin for Treatment of Autonomic Dysreflexia. *M. B. Chancellor, M. J. Erhard, I. H. Hirsch and W. E. Stass, Jr.* 111

Endocrine Profiles and Semen Quality of Spinal Cord Injured Men. *N. L. Brackett, C. M. Lynne, M. S. Weizman, W. E. Bloch and M. Abae* 114

Case Reports

Spontaneous Rupture of Adrenal Pheochromocytoma. *K. Tanaka, S. Noguchi, T. Shuin, Y. Kinoshita, Y. Kubota and M. Hosaka* 120

Laparoscopic Treatment of Stone-Filled, Caliceal Diverticulum: Definitive, Minimally Invasive Therapeutic Option. *H. C. Ruckle and J. W. Segura* 122

Gas in Hepatic Veins: Rare and Critical Presentation of Emphysematous Pyelonephritis. *K.-W. Chen, J.-J. Huang, M.-H. Wu, X.-Z. Lin, C.-Y. Chen and M.-K. Ruaan* 125

Xanthogranulomatous Pyelonephritis in Renal Allografts: Report of 2 Cases. *E. A. Elkhammas, K. H. Mutabagani, D. D. Sedmak, R. J. Tesi, M. L. Henry and R. M. Ferguson* 127

Acquired Cystic Disease and Renal Adenocarcinoma Following Renal Transplantation. *L. A. Levine and B. M. Gburek* 129

Metastatic Renal Cell Carcinoma to Right Cardiac Ventricle Without Contiguous Vena Caval Involvement. *J. C. Carroll, C. C. Quinn, J. Weitzel and G. R. Sant* 133

Laparoscopic Retroperitoneal Renal Cystectomy. *L. C. Munch, I. S. Gill and J. W. McRoberts* (Editorial Comment by L. R. Kavoussi) 135

Retroperitoneal Hemorrhage From Ruptured Renal Artery Aneurysm With Spontaneous Resolution. *R. Chen and A. C. Novick* 139

Ureteritis Cystica With 17-Year Followup. *T. K. Duffin, J. B. Regan and J. M. Hernandez-Graulau* 142

Extracorporeal Shock Wave Lithotripsy Induced Stimulation of Obturator Nerve. *A. S. Cass, C. D. Doce and R. R. Ugarte* 144

Special Considerations in Technique of Laparoscopic Ureterolithotomy. *G. C. Bellman and A. D. Smith* ... 146

Ureteropelvic Junction Obstruction Secondary to Periureteral Lipoma. *E. M. Smith and M. I. Resnick* ... 150

Hemorrhagic Cystitis Associated With Herpes Simplex Virus. *C. McClanahan, M. M. Grimes, E. Callaghan and J. Stewart* 152

Malignant Fibrous Histiocytoma of Bladder With Focal Rhabdoid Tumor Differentiation. *S. Egawa, T. Uchida, K. Koshihara, Y. Kagata and K. Iwabuchi* 154

Benign Testicular Tumor Associated With Klinefelter's Syndrome. *J. Baniel, J. M. Perez and R. S. Foster* 157

Segmental Infarction of Testicle: Atypical Presentation of Testicular Mass. *D. P. Han, R. R. Dmochowski, M. H. Blasser and J. R. Auman* 159

Malignant Melanoma of Scrotum: Report of 2 Cases. *M. M. Konstadoulakis, N. Ricaniadis and C. P. Karakousis* 161

Femoral Neuropathy Following Major Pelvic Surgery: Etiology and Prevention. *A. L. Burnett and C. B. Brendler* 163

Suggestions for Consultants 166

PEDIATRIC UROLOGY

Foreword. *R. D. Walker* 168

Wilms Tumor: Problem of Diagnostic Accuracy in Children Undergoing Preoperative Chemotherapy Without Histological Tumor Verification. *G. Zoeller, A. Pekrun, M. Lakomek and R.-H. Ringert* 169

Urological Aspects of Intra-Abdominal Desmoplastic Small Round Cell Tumor of Childhood: Preliminary Report. *J. C. Carroll, G. T. Klauber, C. S. Kretschmar, A. Ucci and M. Cendron* 172

Lower Urinary Tract Dysfunction in Children With Benign Sacrococcygeal Teratoma. *T. M. L. Boemers, J. D. Van Gool, T. P. V. M. de Jong and K. M. A. Bax* 174

Prospective Evaluation of Leak Point Pressure, Bladder Compliance and Clinical Status in Myelodysplasia Patients With Tethered Spinal Cords. *E. E. Houser, T. H. Bartholomew, M. S. Cookson, A. E. Marlin and N. A. Little* (Editorial Comment by S. Bauer) 177

Iliac Osteotomy: Model to Compare Options in Bladder and Cloacal Exstrophy Reconstruction. *P. H. McKenna, A. E. Khoury, G. A. McLorie, B. M. Churchill, P. B. Babyn and J. H. Wedge* (Editorial Comment by J. P. Gearhart, R. D. Jeffs and P. D. Sponseller) 182

Importance of Urinary Tract Infection in Evaluation of Incontinent Child. *M. A. Williams, H. N. Noe and R. A. Smith* 188

Changing Concepts of Hypospadias Curvature Lead to More Onlay Island Flap Procedures. *L. S. Baskin, J. W. Duckett, K. Ueoka, J. Seibold and H. M. Snyder, III* 191

INVESTIGATIVE UROLOGY

Experimental Hypercholesterolemia in Rabbits Induces Cavernal Atherosclerosis With Endothelial and Smooth Muscle Cell Dysfunction. *J. H. Kim, M. L. Klyachkin, E. Svendsen, M. G. Davies, P.-O. Hagen and C. C. Carson, III* 198

In Vitro Cytotoxicity of Urine From Patients With Interstitial Cystitis. <i>R. Beier-Holgersen, G. G. Hermann, S. O. Mortensen and K. Steven</i>	206
Angiotensin II Receptor Subtypes in Human Renal Cortex and Renal Cell Carcinoma. <i>D. A. Goldfarb, D. I. Diz, R. R. Tubbs, C. M. Ferrario and A. C. Novick</i>	208
Vaginal Immunization of Monkeys Against Urinary Tract Infection With Multi-Strain Vaccine. <i>D. T. Uehling, W. J. Hopkins, L. J. James and E. Balish</i>	214
Antitumoral Effects of Liarozole in Androgen-Dependent and Independent R3327-Dunning Prostate Adenocarcinomas. <i>G. A. Dijkman, R. J. A. Van Moorselaar, R. Van Ginckel, P. Van Stratum, L. Wouters, F. M. J. Debruyne, J. A. Schalken and R. de Coster</i>	217
Influence of Growth Factors on In Vitro Invasiveness and Type IV Collagenolysis of Human Renal Cell Carcinoma Cells. <i>N. Otani, T. Tsukamoto, N. Masumori, I. Saiki, J. Yoneda and Y. Kumamoto</i>	223
Fertility After Cryptorchidism: Comparative Analysis of Early Orchiopexy With and Without Concomitant Hormonal Therapy in Young Male Rat. <i>R. M. Friedman, F. J. López, J. A. Tucker, L. R. King and A. Negro-Vilar</i>	227
Nitric Oxide Mediates Penile Erection in Cats. <i>R. Wang, F. R. Domer, S. C. Sikka, P. J. Kadowitz and W. J. G. Hellstrom</i>	234
Electromyographic Study on Urethral Rhabdosphincter in Normal and Chronically Rhizotomized Cats: Analysis of Electrical Potentials Evoked by Sympathetic Nerve Stimulation. <i>H. Kakizaki, T. Koyanagi, Y. Shinno, S. Kobayashi, K. Matsumura and M. Kato</i>	238
Micturition and Premicturition Contractions in Unanesthetized Rats With Bladder Outlet Obstruction. <i>Y. Igawa, A. Matiasson and K.-E. Andersson</i>	244
Micturition Patterns After Spinal Trauma as Measure of Autonomic Functional Recovery. <i>M. B. Chancellor, D. A. Rivas, B. Huang, G. Kelly and S. K. Salzman</i>	250
Effects of Shock Waves on Mouse Fetus. <i>K. Ohmori, T. Matsuda, Y. Horii and O. Yoshida</i>	255
Anoxia and Corporal Smooth Muscle Dysfunction: Model for Ischemic Priapism. <i>G. A. Broderick, D. Gordon, J. Hypolite and R. M. Levin</i>	259
Effect of Glutathione and Its Related Enzymes on Chemosensitivity of Renal Cell Carcinoma and Bladder Carcinoma Cell Lines. <i>H. Ahn, E. Lee, K. Kim and C. Lee</i>	263
Ureteral Response to Placement of Metallic Stents: Animal Model. <i>A. M. Thijssen, S. F. Millward and K. T. Mai</i>	268

UROLOGICAL SURVEY

Benign and Malignant Neoplasms of Prostate. <i>P. C. Walsh</i>	272
Imaging. <i>S. M. Goldman</i>	285
Pediatric Urology. <i>J. S. Elder</i>	292
Perioperative Care. <i>C. B. Brendler</i>	301
Urinary Tract Infection. <i>A. J. Schaeffer</i>	309

News and Announcements	313
---	-----

DISCLAIMER

The statements and opinions contained in the articles of JOURNAL OF UROLOGY are solely those of the individual authors and contributors and not of the American Urological Association, Inc. or Williams & Wilkins. The appearance of the advertisements in the Journal is not a warranty, endorsement or approval of the products or services advertised or of their effectiveness, quality or safety. The American Urological Association, Inc., and the Publisher disclaim responsibility for any injury to persons or property resulting from any ideas or products referred to in the articles or advertisements.

SINGLE POTENTIAL ANALYSIS OF CAVERNOUS ELECTRICAL ACTIVITY IN SPINAL CORD INJURY PATIENTS

C. G. STIEF, C. HÖPPNER, D. SAUERWEIN AND U. JONAS

From the Departments of Urology, Medizinische Hochschule Hannover, Hannover and W. Wicker Clinic, Bad Wildungen, Germany

ABSTRACT

Introduced in 1988, cavernous electromyography and its evolution, single potential analysis of cavernous electrical activity (SPACE), seem to be promising diagnostic methods in the evaluation of erectile dysfunction. The aim of our study was to determine the influence of a centrally disturbed autonomic supply on SPACE recordings. SPACE was performed in 35 male patients with complete and 2 with incomplete spinal cord lesions at a cervical or thoracic level. Simultaneous recording was done with concentric needle electrodes in both cavernous bodies with a frequency range of 0.5 to 100 Hz. All patients underwent a full neurological and urological evaluation, including cystometry. The lesion was cervical in 12 patients and thoracic in 22. Three patients underwent sacral deafferentation and bladder pacemaker implantation. One of 12 patients with cervical and 10 of 22 with thoracic lesions reported full rigid reflexogenic erections, while 3 of 12 patients with cervical lesions were not evaluable due to grounding failure.

Of these patients 31 were eligible for our study. No patient had an entirely normal SPACE. Four of 9 patients with cervical and 19 of 22 with thoracic lesions had a normal, silent basic electric (less than 5 μ v.) oscillation, while the remainder had a baseline oscillation of up to 100 μ v. Normal potentials were found in 2 of 9 and 10 of 22 patients, respectively. Low frequency, high amplitude potentials were found in 6 of 9 and 21 of 22 patients, respectively, while low frequency, low amplitude potentials occurred in 8 and 8, respectively, and high frequency potentials occurred in 5 and 1, respectively. Our results show that abnormal autonomic input induces abnormal SPACE findings in patients with (presumably) normal cavernous tissue.

KEY WORDS: spinal cord injuries, evoked potentials, penile erection

The diagnostic evaluation of patients with erectile dysfunction faces a fundamental crisis, since one of its mainstays, the evaluation of the peripheral arterial supply by Doppler, duplex or color duplex sonography,^{1,2} may not be able to discriminate between normal and abnormal findings³ in a significant proportion of the patients. This incapacity is not due to an incorrect arterial signal evaluation but to the minimal or nonexistent differences between age and disease matched normal subjects and patients with erectile dysfunction (our unpublished results)³ regarding penile arterial flow.

The registration of cavernous electrical activity was introduced in 1988 as a possible diagnostic method for the evaluation of erectile dysfunction.⁴⁻⁶ The registration of the electrical activity of the cavernous smooth muscles was done in analogy to that of other smooth muscles,⁷⁻⁹ resulting in recordings comparable to electromyography of smooth muscle activity of the stomach, ureter and uterus. A different data processing allowing a more refined interpretation of the recordings, the single potential analysis of cavernous electrical activity (SPACE),¹⁰ seems to allow for diagnosis of the cavernous autonomic innervation and cavernous smooth muscle intactness.

When SPACE was presented, doubts were raised if it really registered electrical activity of the cavernous smooth muscle. Recently, basic research^{11,12} and clinical studies^{13,14} showed that SPACE registers cavernous smooth muscle activity and that it is reproducible. We examine a possible effect of a defined autonomic (spinal) lesion on cavernous electrical activity in the presence of a presumably intact cavernous tissue.

PATIENTS AND METHODS

Cavernous electrical activity was registered in 35 patients with a complete and 2 with an incomplete spinal lesion at a

cervical or thoracic level. Selection criteria were a duration of at least 1 year since the lesion, intact penile skin, no signs of general or localized infection and informed consent. All patients were extensively informed about the procedure itself and the experimental character of the study. The study was approved by the university ethical committee.

Cavernous electrical activity was measured with 2 concentric, bilaterally inserted needle electrodes (Dantec 13L51). After appropriate disinfection of the skin, each electrode was placed with the tip about 1.5 cm. deep into the center of the proximal cavernous body.¹⁰ In case disinfection of the skin or needle insertion induced an erectile response, recording was begun only 15 minutes after the erectile response subsided. For this study we used needle electrodes, since surface electrode recording may be influenced by skin potentials.¹³ Data were processed with a modified Neuromatic 2000 M (Dantec) unit. Frequency range was 0.5 to 100 Hz. with the printer being able to reproduce the fast frequencies. Amplification was times 5,000. For continuous recording the paper speed was 0.5 cm. per second. Recording of cavernous electrical activity was begun 15 minutes after needle insertion to avoid artifacts by the needle insertion itself.

All patients underwent a complete neurological and urological evaluation before registration of cavernous electrical activity. A careful history was obtained with emphasis on bladder and erectile function. Erectile responses mentioned hereafter are the result of the patient report; no erectile response measurements were done in this study. Data acquisition was facilitated by a questionnaire for micturition and erectile capacities.

For comparison, the recordings of cavernous electrical activity (SPACE) done in 82 normal subjects with subjectively normal erectile function were chosen. In these patients (with a few exceptions¹⁰) cavernous electrical activity showed the following characteristics. Phases of electrical silence with an isoelectric baseline that lasted from 20 seconds to several minutes were interrupted by phases of pronounced electric

Accepted for publication July 9, 1993.

Supported in part by a grant from the Deutsche Forschungsgemeinschaft DFG Sti 96/2-2+3.

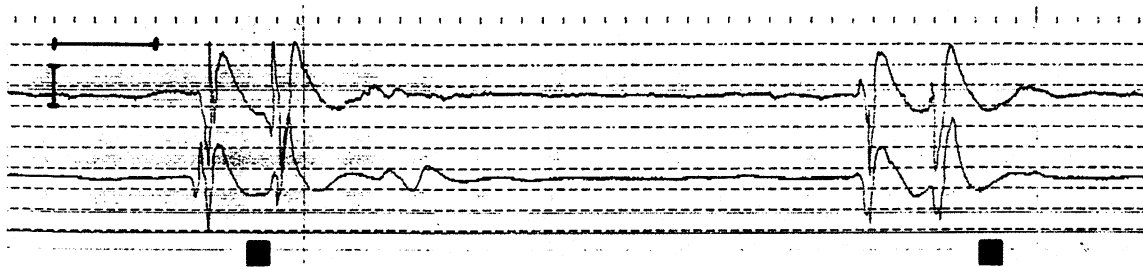


FIG. 1. SPACE recording in normal subject shows phases of electrical silence interrupted by phases of electrical activity, that is potentials. Electrical activity is synchronized in right (upper tracing) and left (lower tracing) cavernous bodies. Horizontal bar is 5 seconds. Vertical bar is 100 μv .

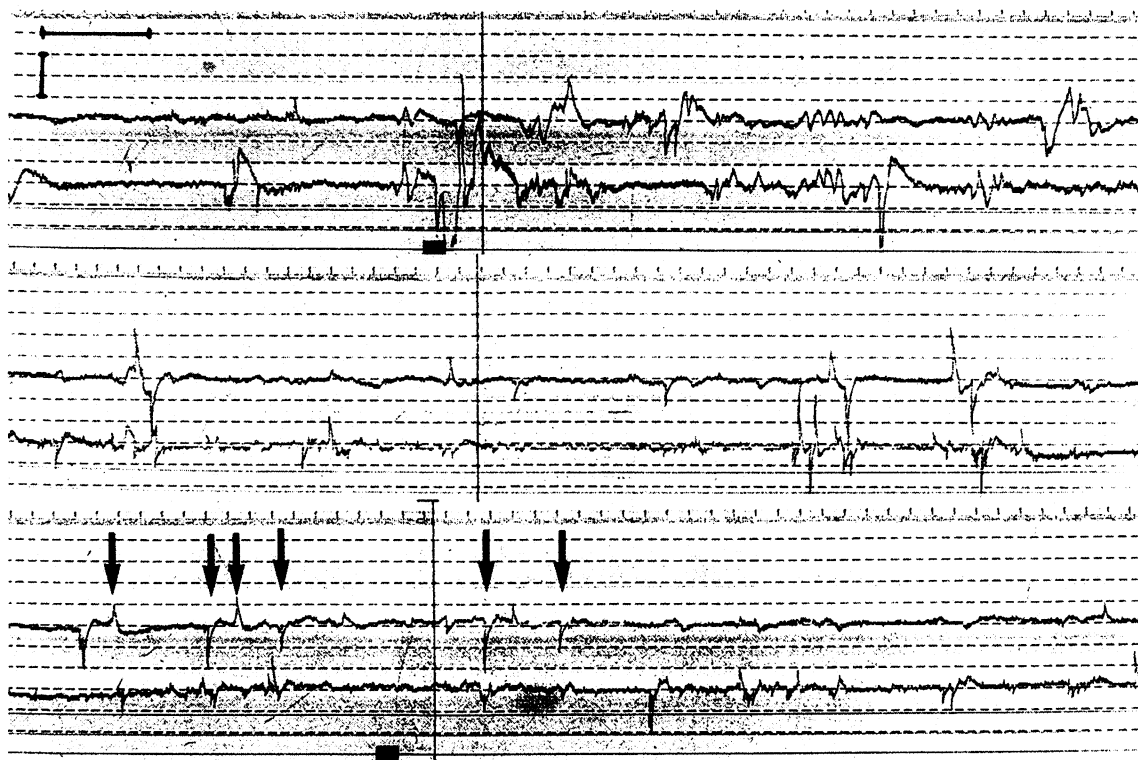


FIG. 2. SPACE recording in 58-year-old patient with incomplete cervical lesion at C6 level shows irregular baseline with high frequency oscillations. Arrows denote whips in lower tracing. Horizontal bar is 5 seconds. Vertical bar is 100 μv .

activity, that is the potentials. These potentials were of frequency range-dependent duration and amplitude. With the aforementioned parameters duration was from 5 to 15 seconds and amplitude was approximately 250 to 750 μv . The potentials were synchronous in both cavernous bodies (fig. 1).¹⁰

As described previously, there was a specific electrical activity pattern within the phases of electrical silence between the potentials. However, in many patients with presumably neurogenic autonomic lesions at least 1 other typical form of electrical activity was found, which was observed only in a few normal men and only occasionally. These electrical events show a sharp depolarization phase, followed by a concave phase of repolarization (figs. 2 to 4). During electromyography of the striated muscle there is an electrical event with a similar shape but a much faster speed, the so-called sharp wave. To avoid semantic confusion with the established term 'sharp wave' in the classical electromyography description, we chose another term for this (regarding the shape) electrical event in smooth muscle electromyography and named it the 'whip'. Due to the wide variety of different findings and the relatively small patient group (in absolute numbers), no statistical data analysis was done to avoid the improper impression of (statistical) significance in insignificant (biological) differences and vice versa.

RESULTS

Of the patients 12 had cervical and 22 thoracic lesions, and sacral deafferentation¹⁵ was done in 3. Due to the small group size, data from the latter 3 patients are not reported. Patient age, duration since the injury, level of the complete cervical or thoracic lesion, and erectile ability are shown in tables 1 and 2. Due to an incorrect grounding (hardware problem with broken grounding plate), correct recording of cavernous electrical activity was impossible in 3 patients with cervical lesions. In the remaining 31 patients SPACE was interpretable. In none of these patients was completely normal cavernous electrical activity found.

A silent electrical baseline, similar to that in normal subjects, was found in 4 of 9 patients with cervical lesions and 19 of 22 with thoracic lesions, while 5 and 3, respectively, showed high frequency, irregular oscillations of the baseline with an amplitude of up to 100 μv . (type 1 findings, fig. 2). In 2 of 9 patients with cervical and 10 of 22 with thoracic lesions normal monophasic, biphasic or triphasic potentials of typical smooth muscle shape were found (normal potentials, fig. 3). Low frequency, synchronized and/or unsynchronized potentials of high amplitude (greater than 250 μv .) were noted in 6 and 21 patients, respectively (type 2 findings, fig. 4). Low frequency, unsyn-

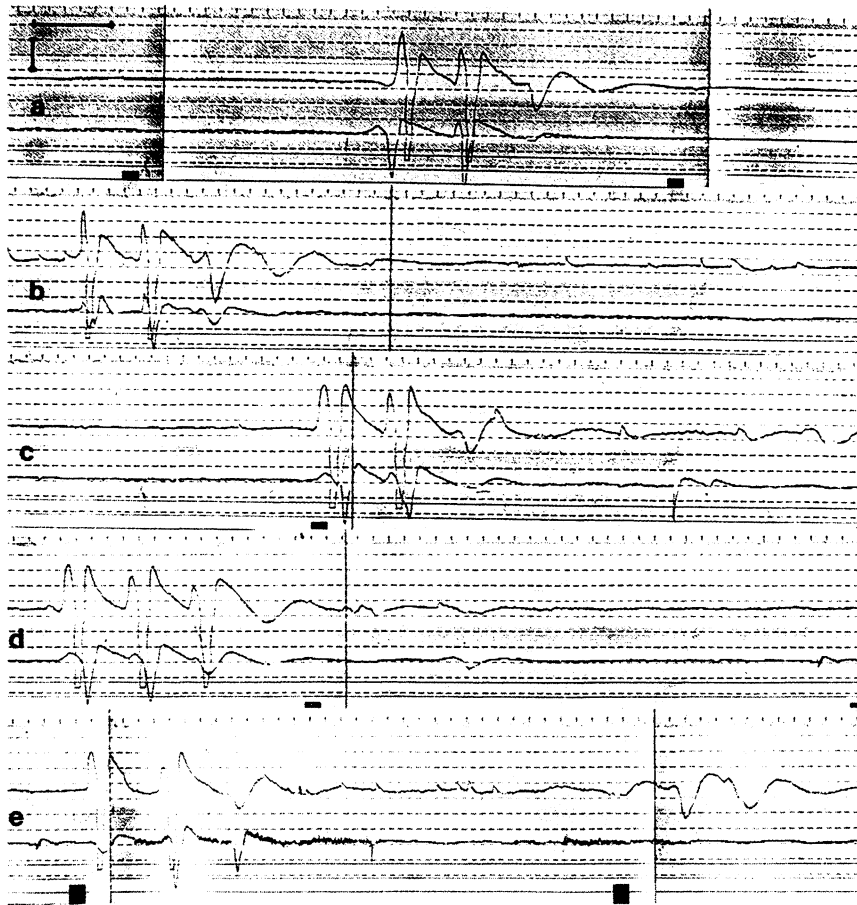


FIG. 3. Continuous recording in 49-year-old patient with complete T12 lesion demonstrates normal potentials as well as whips. Horizontal bar is 5 seconds. Vertical bar is 100 μ v.

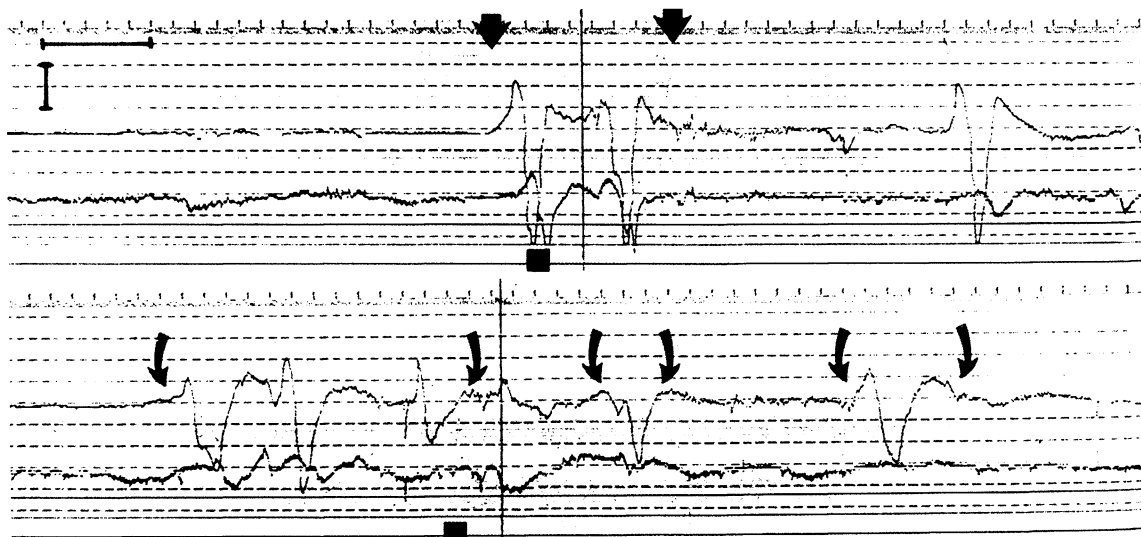


FIG. 4. Low frequency, synchronized and unsynchronized potentials of high amplitude (greater than 250 μ v.) were noted in 56-year-old patient with complete T12 spinal lesion. In upper recording, arrows indicate synchronized potential. In lower recording curved arrows indicate asynchronous, low frequency potentials. Horizontal bar is 5 seconds. Vertical bar is 100 μ v.

chronized potentials of low amplitude (less than 250 μ v.) were noted in 8 and 8 patients, respectively (type 3 findings). High frequency, irregular and unsynchronized potentials of low amplitude (less than 250 μ v.) were found in 5 and 1 patients, respectively (type 4 findings, fig. 5). Whips¹⁰ were found in only 1 patient with an incomplete C3/4 lesion and in 8 of the 22 patients with thoracic lesions. The individual cavernous electrical activity findings are noted in tables 1 and 2.

DISCUSSION

Our results with abnormal cavernous electric activity in all spinal cord injury patients show that an abnormal cavernous autonomic supply results in an abnormal cavernous electrical activity. Since patients are younger, with 11 of 37 reporting erections sufficient for intercourse (which does not represent normal erectile function), it may be justified to assume that the cavernous tissue is normal or that the cavernous tissue was

TABLE 1. *Level of the complete cervical lesion, patient age, duration since the lesion and erectile response to sexual stimulation*

Level	Pt. Age	Duration	Erectile Response (intercourse possible)	Electrical Activity*				
				Baseline	Type 1	Type 2	Type 3	Type 4
3/4	44	20	Tumescence without rigidity (no)	Irregular	Absent	Present	Present	Present
3/4 incomplete	29	12	Tumescence with rigidity (yes)	Irregular	Absent	Present	Absent	Present
4/5	22	3	Tumescence without rigidity (no)	Silent	Absent	Present	Present	Absent
5	36	14	Tumescence without rigidity (no)	Silent	Absent	Absent	Present	Present
5	25	3	Tumescence without rigidity (no)	—	Absent	Absent	Absent	Absent
5/6	30	5	Tumescence without rigidity (no)	Irregular	Absent	Absent	Present	Present
6	20	5	Tumescence without rigidity (no)	Silent	Present	Present	Present	Absent
6	30	2	Tumescence without rigidity (no)	Silent	Present	Present	Present	Absent
6	58	32	Tumescence without rigidity (no)	Irregular	Absent	Present	Present	Present
6/7	22	2	Tumescence without rigidity (no)	—	Absent	Absent	Absent	Absent
7	47	20	Tumescence without rigidity (no)	—	Absent	Absent	Absent	Absent
7	35	16	Tumescence without rigidity (no)	Silent	Absent	Absent	Present	Absent

* The individual findings of cavernous electrical activity (recordings of patients 5, 10 and 11 were not interpretable due to incorrect grounding) are given. The electrical baseline is described as well as typical patterns of electrical activity (type 1—high frequency, irregular oscillations of the baseline, type 2—low frequency potentials of high amplitude, type 3—low frequency, unsynchronized potentials of low amplitude and type 4—high frequency, irregular and unsynchronized potentials of low amplitude).

TABLE 2. *Level of complete thoracic lesion, patient age, duration since the lesion and erectile response to sexual stimulation*

Level	Pt. Age	Duration	Erectile Response (intercourse possible)	Electrical Activity*				
				Baseline	Type 1	Type 2	Type 3	Type 4
3	26	5	Tumescence without rigidity (no)	Silent	Absent	Present	Absent	Absent
3	26	22	Tumescence with rigidity (yes)	Silent	Absent	Present	Absent	Absent
4	37	20	Tumescence with rigidity (yes)	Silent	Absent	Present	Absent	Absent
5	23	17	Tumescence with rigidity (yes)	Silent†	Present	Present	Absent	Absent
5	37	17	Tumescence with rigidity (yes)	Silent	Absent	Present	Present	Absent
7	28	5	—	Silent†	Absent	Present	Absent	Absent
7	31	11	Tumescence with rigidity (yes)	Silent	Absent	Present	Present	Absent
8	45	7	—	Irregular	Absent	Absent	Present	Present
8	63	22	Tumescence without rigidity (no)	Irregular†	Absent	Present	Absent	Absent
8	34	1	Tumescence without rigidity (no)	Silent†	Present	Present	Present	Absent
9	27	4	Tumescence with rigidity (yes)	Silent	Absent	Present	Absent	Absent
9	52	24	Tumescence with rigidity (yes)	Silent	Present	Present	Absent	Absent
10	34	12	Tumescence without rigidity (no)	Silent	Absent	Present	Absent	Absent
12	45	21	Tumescence with rigidity (yes)‡	Silent†	Present	Present	Absent	Absent
12	33	14	Tumescence with rigidity (yes)	Silent†	Present	Present	Present	Absent
12	52	32	Tumescence without rigidity (no)	Silent	Present	Present	Absent	Absent
12	56	26	Tumescence with rigidity (yes)	Silent	Present	Present	Present	Absent
12	49	9	—	Silent†	Present	Absent	Absent	Absent
12	52	20	Tumescence with rigidity (yes)‡	Irregular	Present	Present	Present	Absent
12	43	14	—	Silent	Absent	Present	Present	Absent
12-L3	38	1	—	Silent†	Absent	Present	Absent	Absent
12-L4	40	15	Tumescence with rigidity (yes)	Silent	Absent	Present	Absent	Absent

* Individual findings of cavernous electric activity are given. The electrical baseline is described as well typical patterns of electrical activity (type 1—high frequency, irregular oscillations of the baseline, type 2—low frequency potentials of high amplitude, type 3—low frequency, unsynchronized potentials of low amplitude and type 4—high frequency, irregular and unsynchronized potentials of low amplitude).

† Whips present.

‡ Erection less rigid than "during the last time."

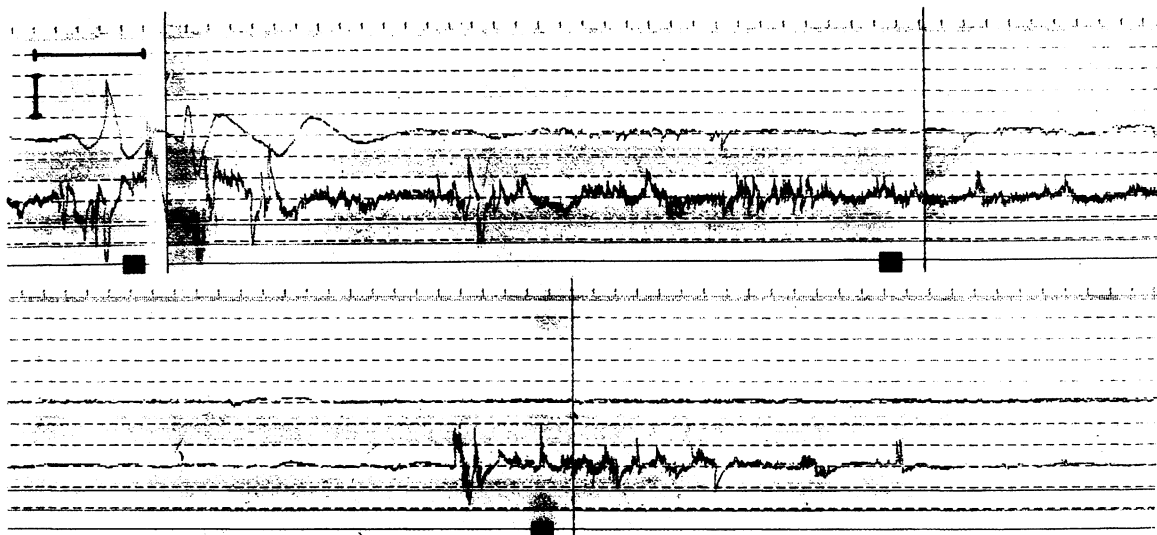


FIG. 5. High frequency, irregular and unsynchronized potentials of low amplitude (less than $250 \mu\text{v}$.) were found in 44-year-old patient with complete C5/6 lesion. Horizontal bar is 5 seconds. Vertical bar is $100 \mu\text{v}$.

normal before the neurological lesion. In both cases the abnormal recordings of cavernous electric activity in these patients are directly related to the neurological lesion.

The impact of autonomic lesions on cavernous electrical activity may be 2-fold. Besides a direct impact of the abnormal autonomic supply resulting in an abnormal cavernous electrical activity in a normal cavernous tissue, disruption of the autonomic supply seems to induce cavernous smooth muscle degeneration as recently suggested.¹⁶ Then, cavernous smooth muscle degeneration itself will result in an abnormal cavernous electrical activity. These findings are analogous with the findings of striated muscle electromyography, in which neurological and myogenic lesions may be detected.

Furthermore, our results show that there is no possibility for a clear-cut differentiation of cervical or thoracic lesions by SPACE. Nonetheless, there is an obvious trend in subjective reports of the patients and objective recording of cavernous electrical activity. Whereas only a minority of the patients (1 of 12) with cervical lesions (and in this case the lesion was incomplete since he had sensory functions in the genital, perineal and anal regions) reported erections sufficient for intercourse, almost half of the patients with thoracic lesions (10 of 22) reported erections sufficient for intercourse. These subjective patient reports are supported by the objective SPACE findings with normal potentials in only 2 patients with cervical and 10 with thoracic lesions. Other obvious findings are the occurrence of high frequency, irregular and unsynchronized potentials of low amplitude (less than $250 \mu\text{v}$.) in more than half of the patients with cervical but only 1 of 22 patients with thoracic lesions. Similarly, low frequency, synchronized and/or unsynchronized potentials of high amplitude (greater than $250 \mu\text{v}$.) were noted in 6 of 9 patients with cervical and in almost all (21 of 22) patients with thoracic lesions.

This trend of different subjective and objective findings in patients with cervical and thoracic lesions may have its explanation in the anatomy of the autonomic nervous system. The efferent sympathetic fibers are leaving the spinal cord at the C7 level supplying the sympathetic trunk with central information. Thus, a spinal cord lesion above or at the C7 level completely disrupts the cavernous tissue from its autonomic supply. A spinal cord lesion below the C7 level, leaving the sympathetic trunk outside the spinal canal intact, should allow autonomic central information to reach the cavernous tissue. Whether this central information is pure sympathetic supply or mixed sympathetic-parasympathetic supply after posttrau-

matic autonomic reorganization is speculative and deserves further investigation. The importance of this route of central information to the cavernous tissue is underlined by our findings with no erections sufficient for intercourse in patients with complete spinal lesions above the C7 level. The effect of this central autonomic input may be multiple. Autonomic reorganization may support the reflexogenic erections induced by the sacral parasympathetic center. Centrally mediated reduction of the sympathetic input may further support the reflexogenic erection. Disruption of the sympathetic supply may result in an over reactivity of cavernous smooth muscle cells to adrenergic substances in the circulating blood.¹⁷ Finally, disruption of the sympathetic supply may result in cavernous smooth muscle degeneration.¹⁶

Our results showed that disturbances of the autonomic cavernous supply in an otherwise healthy cavernous tissue results in an abnormal cavernous electrical activity. Further studies must elucidate whether this abnormal cavernous electrical activity is due not only to the abnormal autonomic input but also to secondary changes of the cavernous smooth muscle itself induced by the abnormal autonomic innervation. The results strongly support a major role of SPACE for the diagnosis of cavernous autonomic dysfunction.

REFERENCES

1. Jevtich, M. J.: Non-invasive vascular and neurogenic tests in use for evaluation of angiogenic impotence. *Int. Angio.*, **3**: 225, 1984.
2. Lue, T. F., Hricak, H., Marick, K. W. and Tanagho, E. A.: Evaluation of arteriogenic impotence with intracorporeal injection of papaverine and the duplex ultrasound scanner. *Sem. Urol.*, **3**: 43, 1985.
3. Meuleman, E. J. H., Bemelmans, B. L. H., Doesburg, W. H., van Asten, W. N. J. C., Skotnicki, S. H. and Debruyne, F. M. J.: Penile pharmacological duplex ultrasonography: a dose-effect study comparing papaverine, papaverine/phentolamine and prostaglandine E1. *J. Urol.*, **148**: 63, 1992.
4. Wagner, G. and Gerstenberg, T.: Human in vivo studies of electrical activity of corpus cavernosum. *J. Urol.*, part 2, **139**: 327A, abstract 659, 1988.
5. Gerstenberg, T. C., Nordling, J., Hald, T. and Wagner, G.: Standardized evaluation of erectile dysfunction in 95 consecutive patients. *J. Urol.*, **141**: 857, 1989.
6. Wagner, G., Gerstenberg, T. and Levin, R. J.: Electrical activity of corpus cavernosum during flaccidity and erection of the human penis: a new diagnostic method? *J. Urol.*, **142**: 723, 1989.
7. Wagner, G.: Contractility of myometrial transplants. In: *Physiology and Genetics of Reproduction, Part B*. Edited by E. M.

- Coutinho and F. Fuchs. New York: Plenum Publishing Corp., chapt. 42, p. 203, 1976.
8. Couturier, D.: Gastric electromyography: its place in experimental research and clinical investigation. In: *Clinical Investigation of Gastric Function*. Edited by C. Scarpignato and G. Bianchi Porro. New York: S. Karger, p. 297, 1990.
 9. Kondo, T., Tamura, K., Onoe, K., Takahira, H., Ohta, Y. and Yamabayashi, H.: In vivo recording of electrical activity of canine tracheal smooth muscle. *J. Appl. Physiol.*, **72**: 35, 1992.
 10. Stief, C. G., Djamilian, M., Schaebdsau, F., Truss, M. C., Schlick, R. W., Abicht, J. H., Allhoff, E. P. and Jonas, U.: Single potential analysis of cavernous electric activity—a possible diagnosis of autonomic impotence. *World J. Urol.*, **8**: 75, 1990.
 11. Mandrek, K. and Golenhofen, K.: The myogenic basics of smooth muscle motility in the corpus cavernosum peni. In: *Cavernous Smooth Muscle Electromyography*. Edited by K. Buchhauser. Gebele: Planegg/Germany, pp. 7–19, 1992.
 12. Bührle, C. P. and Jünemann, K. P.: Recording and computer-aided evaluation of corpus cavernosum electromyograms. In: *Cavernous Smooth Muscle Electromyography*. Edited by K. Buchhauser. Gebele: Planegg/Germany, pp. 50–63, 1992.
 13. Merckx, L. and Keuppens, F.: Penile electromyography: normal values and early experience in the evaluation of penile autonomic innervation and smooth muscle function. In: *Cavernous Smooth Muscle Electromyography*. Edited by K. Buchhauser. Gebele: Planegg/Germany, pp. 20–29, 1992.
 14. Uhlemann, H.: The use of transcutaneous registration of cavernous electrical activity in the diagnosis of the cavernous autonomic innervation with SPACE. In: *Cavernous Smooth Muscle Electromyography*. Edited by K. Buchhauser. Gebele: Planegg/Germany, pp. 43–49, 1992.
 15. Brindley, G. S., Polkey, C. E., Rushton, D. N. and Cardozo, L.: Sacral anterior root stimulators for bladder control in paraplegia: the first 50 cases. *J. Neurol. Neurosurg. Psychiatr.*, **49**: 1104, 1986.
 16. Paick, J.-S., Goldsmith, P. C., Batra, A. K., Nunes, L. L., Padula, C. A. and Lue, T. F.: Relationship between venous incompetence and cavernous nerve injury: ultrastructural alteration of cavernous smooth muscle in the neurotomized dog. *Int. J. Impoten. Res.*, **3**: 185, 1991.
 17. Diederichs, W., Stief, C. G., Lue, T. F. and Tanagho, E. A.: Sympathetic inhibition of papaverine induced erection. *J. Urol.*, **146**: 195, 1991.