

OSTEOMORPHOLOGICAL DIFFERENCES IN THE APPENDICULAR SKELETON OF *ANTIDORCAS MARSUPIALIS* (ZIMMERMAN, 1780) AND *ANTIDORCAS BONDI* (COOKE & WELLS, 1951) (MAMMALIA: BOVIDAE) WITH NOTES ON THE OSTEOLOGY OF *ANTIDORCAS BONDI*

I. PLUG
Transvaal Museum, Pretoria

J. PETERS
Institut für Palaeoanatomie, Universität München

Plug, I. and Peters, J., 1991. Osteomorphological differences in the appendicular skeleton of *Antidorcas marsupialis* (Zimmerman, 1780) and *Antidorcas bondi* (Cooke & Wells, 1951) (Mammalia: Bovidae) with notes on the osteology of *Antidorcas bondi*. *Annals of the Transvaal Museum* 35(17): 253-264.

Skeletal remains of two springbok species, *Antidorcas marsupialis* (Zimmerman, 1780) and *Antidorcas bondi* (Cooke & Wells, 1951) are frequently found in Southern African Pleistocene and early Holocene deposits. To date only cranial features have been used to distinguish between the two species although postcranial remains are often more abundant and often also better preserved in assemblages than cranial elements. Numerous osteomorphological differences were found in the appendicular skeletons of the two species. Certain individual features, for example of the ulna, proximal radius, os carpi, phalanges, metapodials and distal humerus, can be used to reliably distinguish between the two species. Features of the distal radius, femur, and tibia are not always reliable when considered singly, and should rather be used in combination. The osteology of *A. bondi* indicates that this animal was shorter and sturdier than *A. marsupialis*.

Keywords: Southern Africa, Pleistocene, Holocene, Mammalia, Bovidae, *Antidorcas marsupialis*, *Antidorcas bondi*, osteomorphology, osteology.

INTRODUCTION

Cranial and postcranial remains of *Antidorcas marsupialis* (Zimmerman, 1780) and *Antidorcas bondi* (Cooke & Wells, 1951) are occasionally found in Pleistocene and early Holocene deposits in Southern Africa (Klein, 1983, 1984a,b; Brain, 1981; Brown and Verhagen, 1985). To date the identification of the two species has been based mainly on teeth (Vrba, 1976, 1973; Brain, 1981; Brown and Verhagen, 1985). Although postcranial remains are sometimes listed (Brain, 1981), no morphological differences in the postcranial skeletons of these two species have been documented. In this paper we present descriptions of a variety of features to facilitate the identification of postcranial remains of the two species.

Differential attrition, chemical and mechanical destruction, post-depositional transportation, as well as human, carnivore and rodent activity, are some of the factors that play a role in the disarticulation, fragmentation and loss of skeletal elements (Plug, 1988). As a result, no complete skeletons of *A. bondi* exist and the elements used

in this study are those that survived post-depositional attrition. The skeletal elements that are preserved are usually the same in all antelope and large mammal species, and are bones that are relatively dense and/or compact. These are also the bone fragments that are most commonly represented in archaeological deposits. Although this study is based on fragmented material, and the selection of elements biased by preservation, the results should still be of value to archaeologists and palaeontologists.

MATERIAL AND METHODS

Most *A. bondi* specimens studied are housed in the Transvaal Museum, while specimens from the National Museum, Bloemfontein, were used to confirm initial findings. Catalogue numbers of the *A. bondi* specimens studied are listed in the Appendix.

Modern *A. marsupialis* skeletons studied are

housed in various South African museums, represent different geographic localities and also included specimens donated by zoological gardens. Accession numbers of *A. marsupialis* specimens studied are listed in Peters and Brink (in preparation).

The *A. bondi* specimens in the Transvaal Museum come from Member 2 of the Swartkrans Pleistocene site. Swartkrans is situated in the Transvaal Highveld, approximately 10 km north of Krugersdorp in the Blaaubank River Valley (26° 01' S, 27° 23' E). The specimens in the National Museum are from Pleistocene levels at Florisbad (32° 46' S, 26° 04' E), northwest of Bloemfontein, Orange Free State (Brink, 1987).

Member 2 of Swartkrans has not been dated, but is estimated to be half a million years old (Brain, 1971; Brain, Churcher, Clark, Grine, Shipman, Susman, Turner, and Watson, 1988). The faunal remains from this member consist of a wide variety of animal species, but is dominated by 160 antelope individuals of which 118 fall into size class II (medium-sized bovids). Of these individuals, 70 were identified as *A. bondi* on the basis of cranial remains (Brain, 1981). We were able to sort the class II postcranial remains into groups representing *Pelea capreolus*, *Redunca* spp. and *A. australis* and/or *A. marsupialis*. The remaining elements, which constitute the bulk of the sample, were assumed to be *A. bondi* based on the large proportion of identified cranial remains of *A. bondi* and on the typical gazelle-like features of the postcranial elements.

The osteomorphological terms used in the descriptions below follow the *Nomina Anatomica Veterinaria* (1983). Ideally, only left or only right elements should be consistently illustrated. However, the preservation of the palaeontological specimens were such that this rule could not be strictly adhered to. The illustrations are composites and do not represent individual animals. In the illustrations the elements on the left are always of *A. marsupialis* and those on the right always of *A. bondi*. Measurements were taken with a dial calliper to the nearest 0,1 mm. The abbreviations used in Table 1 are consistent with those proposed by Von den Driesch (1976), and have been accepted by the International Council for Archaeozoology (ICAZ).

Not all distinguishing features are equally reliable. It should be realized that so-called 'one way' features are also recognized in osteomorphological studies. A 'one way' feature is one that is always present in species A, but may be either present or absent in species B. Absence of that feature therefore identifies species B only.

RESULTS

Characteristic features are indicated by a number in the text as well as in the figures.

Scapula

1. The synovial fossa on the glenoid cavity tends to be larger and more intrusive in *A. marsupialis* (Fig. 1, char. 1).

Humerus

1. The epicondylus medialis of the distal humerus always protrudes or extends further distally in *A. bondi*. In *A. marsupialis* this feature may or may not be developed (Fig. 1, char. 2).

2. The epicondylus lateralis of the distal humerus

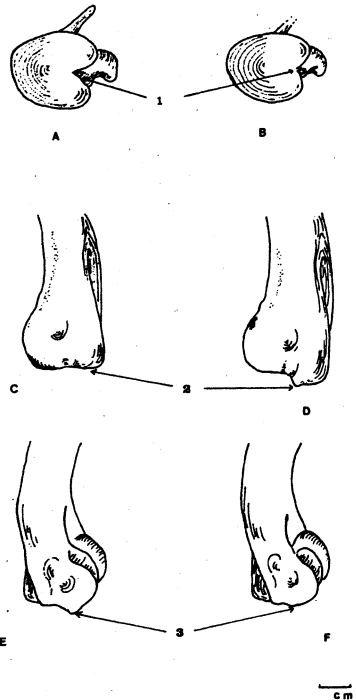


Fig. 1

A: *Antidorcas marsupialis* scapula, distal view.

B: *Antidorcas bondi* scapula, distal view.

C: *Antidorcas marsupialis* humerus, distal extremity, medial view.

D: *Antidorcas bondi* humerus, distal extremity, medial view.

E: *Antidorcas marsupialis* humerus, distal extremity, lateral view.

F: *Antidorcas bondi* humerus, distal extremity, lateral view.

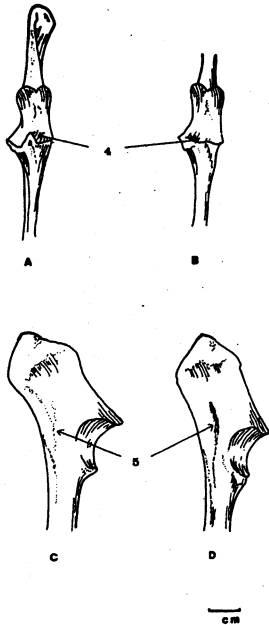


Fig. 2

- A: *Antidorcas marsupialis* ulna, proximal, cranial view.
- B: *Antidorcas bondi* ulna proximal, cranial view.
- C: *Antidorcas marsupialis* ulna, proximal, medial view.
- D: *Antidorcas bondi* ulna, proximal, medial view.

protrudes or extends further distally in *A. marsupialis* (Fig. 1, char. 3).

Ulna

1. In *A. marsupialis* the semilunar notch has a strongly developed fossa incisura lateralis where it articulates with the proximal radius. In *A. bondi* this fossa is absent or only weakly developed (Fig. 2, char. 4).
2. In most specimens of *A. bondi* the medial side of the olecranon has a strongly developed muscle ridge which is almost absent in *A. marsupialis* (Fig. 2, char. 5).

Radius

1. The radius of *A. marsupialis* is relatively longer and more slender (Fig. 3).

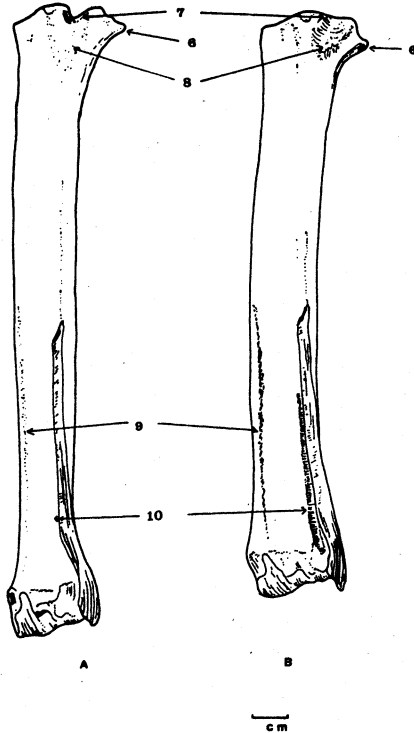


Fig. 3

- A: *Antidorcas marsupialis* radius, caudal view.
- B: *Antidorcas bondi* radius, caudal view.

2. In *A. bondi* the epicondyle of the proximal radius is more strongly developed and placed further distally (Fig. 3, char. 6).
3. To match the processus on the ulna, the incision for the lateral coronoid process at the caudal side of the caput radii is V-shaped in *A. marsupialis*. In *A. bondi* this incision is absent or only weakly developed (Fig. 3, char. 7).
4. Between the facies articularis ulnaris and the interosseus space, the rough triangular area where the interosseus ligament attaches is weakly defined in *A. marsupialis*. It is strongly developed and ridged in *A. bondi* (Fig. 3, char. 8).
5. In *A. bondi* the medial muscle attachment at the caudal side of the corpus radii is generally

strongly developed where it transgresses from the distal end proximally towards the medial edge of the bone. In *A. marsupialis* this ridge is less pronounced (Fig. 3, char. 9). In juvenile and young *A. bondi* it is not well developed.

6. In *A. bondi* a deep groove runs along the lateral side of the distal half of the corpus radii, on the medial side of the ulna. This groove is virtually absent in *A. marsupialis* (Fig. 3, char. 10).

7. The medial facet of the facies articularis carpea is broader and more strongly developed in *A. bondi* (Fig. 4, char. 13).

8. The morphology and proportions of the other facets of the distal articular surface also differ between the two species (Fig. 4, char. 11, 12, 14).

9. The ridges for the extensor tendons are very strongly developed in *A. bondi*, but weak in *A. marsupialis*.

Ossa carpi

Os carpi radiale

1. The os carpi radiale is somewhat elongated in *A. marsupialis*, but more compact or squat in *A. bondi* (Fig. 4, char. 16).
2. The laterodorsal facies articularis has a continuous facet in *A. bondi* whereas it is interrupted in *A. marsupialis* (Fig. 4, char. 17).
3. The palmar extension and distal dorsal aspects are larger and more robust in *A. marsupialis* (Fig. 4, char. 18, 19).

Os carpi intermedium

1. The mediadorsal facies articularis is continuous in *A. bondi*, but interrupted in *A. marsupialis* (Fig. 4, char. 20).
2. The dorsal facies articularis is constricted in *A. marsupialis*, but to a lesser extent in *A. bondi* (Fig. 4, char. 21).
3. The palmar protuberance is sharper and more irregularly defined in *A. marsupialis*. In *A. bondi* this feature is more rounded and irregular in shape (Fig. 4, char. 22).

Os carpi ulnare

1. The shape of the ulnar carpal is more angular in *A. marsupialis* (Fig. 4, char. 23).
2. The proximal facies articularis is more constricted in *A. bondi* than it is in *A. marsupialis* (Fig. 4, char. 24). As a result,

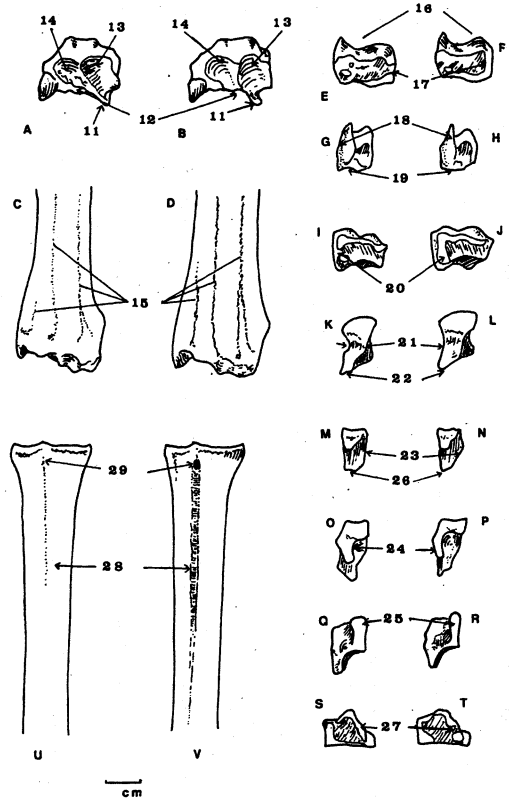


Fig. 4

- A: *Antidorcas marsupialis* radius-ulna, distal view.
 B: *Antidorcas bondi* radius-ulna, distal view.
 C: *Antidorcas marsupialis* radius-ulna, distal extremity, dorsal view.
 D: *Antidorcas bondi* radius-ulna, distal extremity, dorsal view.
 E: *Antidorcas marsupialis* os carpi radiale, lateropalmar view.
 F: *Antidorcas bondi* os carpi radiale, lateropalmar view.
 G: *Antidorcas marsupialis* os carpi radiale, palmar view.
 H: *Antidorcas bondi* os carpi radiale, palmar view.
 I: *Antidorcas marsupialis* os carpi intermedium, medial view.
 J: *Antidorcas bondi* os carpi intermedium, medial view.
 K: *Antidorcas marsupialis* os carpi intermedium, proximal view.
 L: *Antidorcas bondi* os carpi intermedium, proximal view.
 M: *Antidorcas marsupialis* os carpi ulnare, medial view.
 N: *Antidorcas bondi* os carpi ulnare, medial view.
 O: *Antidorcas marsupialis* os carpi ulnare, proximal view.
 P: *Antidorcas bondi* os carpi ulnare, proximal view.
 Q: *Antidorcas marsupialis* os carpi ulnare, laterodorsal view.
 R: *Antidorcas bondi* os carpi ulnare, laterodorsal view.
 S: *Antidorcas marsupialis* os carpale IV, medial view.
 T: *Antidorcas bondi* os carpale IV, medial view.
 U: *Antidorcas marsupialis* os metacarpale III + IV, dorsal view.
 V: *Antidorcas bondi* os metacarpale III + IV, dorsal view.

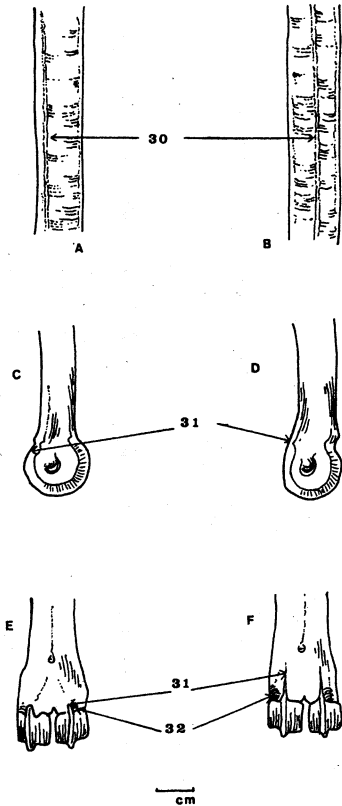


Fig. 5

- A: *Antidorcas marsupialis* os metacarpale III + IV, palmar view of shaft.
- B: *Antidorcas bondi* os metacarpale III + IV, palmar view of shaft.
- C: *Antidorcas marsupialis* os metacarpale III + IV, distal extremity, lateral view.
- D: *Antidorcas bondi* os metacarpale III + IV, distal extremity, lateral view.
- E: *Antidorcas marsupialis* os metacarpale III + IV, distal extremity, palmar view.
- F: *Antidorcas bondi* os metacarpale III + IV, distal extremity, palmar view.

the profile of this facet also differs (Fig. 4, char. 25).

3. The dorsal margin of the distal articular surface is pointed in *A. bondi*, but flat or slightly concave in *A. marsupialis* (Fig. 4, char. 26).

Os carpale II + III

No constant morphological differences were

found.

Os carpale IV

1. The medial facies articularis has a continuous facet in *A. marsupialis*, but is interrupted in *A. bondi* (Fig. 4, char. 27).

Os metacarpale III + IV

1. The habitus of the os metacarpale III + IV is longer and more slender in *A. marsupialis* (not illustrated).
2. The sulcus longitudinalis dorsalis is absent or weakly developed in *A. marsupialis*, but well developed in *A. bondi* (Fig. 4, char. 28).
3. In *A. bondi* the sulcus longitudinalis dorsalis ends proximally in a clearly developed nutrient foramen, which is absent or only sometimes weakly present in *A. marsupialis* (Fig. 4, char. 29). This nutrient foramen perforates the bone in *A. bondi*.
4. The muscle ridge on the palmar surface of the shaft runs in the middle of the shaft in *A. bondi*, but is more medially placed in *A. marsupialis* (Fig. 5, char. 30).
5. The sagittal ridges of the trochleae are long and extend further proximally on the palmar side in *A. bondi* (Fig. 5, char. 31).
6. The trochleae ossis metacarpalis III + IV are well developed in both species. However, in *A. bondi* the palmar fossulae are deeper and more strongly developed (Fig. 5, char. 32).

Ossa digitorum manus

Phalanx proximalis

1. The phalanx proximalis manus is longer and relatively more slender in *A. bondi* (Fig. 6, char. 33).
2. The muscle scars on the palmar surface of the corpus are well developed in *A. bondi*, but are absent or weakly developed in *A. marsupialis* (Fig. 6, char. 34).
3. In palmar aspect the trochleae phalangis proximalis are relatively larger and the abaxial trochleae extends more proximally in *A. marsupialis* (Fig. 6, char. 35).

Phalanx media

1. The axial side has two clearly marked indentations in *A. bondi*. These indentations are absent or weakly developed in *A. marsupialis* (Fig. 6, char. 36).
2. In *A. bondi*, the indentations on the axial side cause a constriction on the margin of the facies articularis proximalis (Fig. 6, char. 37).

Phalanx distalis

1. The processus extensorius is somewhat distally placed in the phalanx distalis of *A. marsupialis*. In *A. bondi* it is placed immediately above the facies articularis (Fig. 6, char. 38).
2. In *A. bondi* a prominent nutrient foramen is present on the axial side, close to the facies articularis, but this foramen is absent or marginally indicated in *A. marsupialis* (Fig. 6, char. 39).

Os femoris

Morphological differences between the femora of the two species are not very pronounced, but the following appear to be distinguishing features, particularly when considered in combination.

1. In *A. bondi* the caput ossis femoris is more isolated from the collum on the cranial side (Fig. 6, char. 40).
2. The condylus lateralis and the condylus medialis appear to be somewhat more slender in the distal femora of *A. bondi*.

Tibia

Morphological differences between the tibiae of the two species are indistinct, but a combination of two or more of the following features could serve to distinguish tibiae of *A. bondi* from those of *A. marsupialis*.

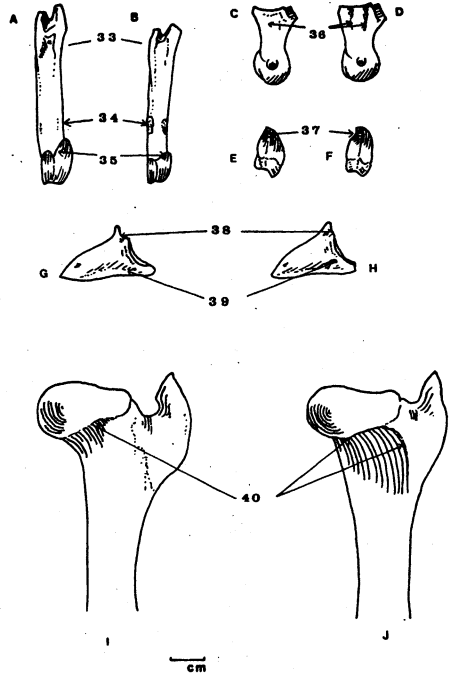
1. The condylus medialis of the facies articularis proximalis is medially indented or concave in *A. marsupialis*, but rounded or convex in *A. bondi* (Fig. 7, char. 41).
2. The proximal medial epiphyseal line is slightly convex in *A. marsupialis*, but tends to be concave in *A. bondi* (Fig. 7, char. 41).
3. The small facet on the dorsolateral side of the distal tibia does not extend as far dorsally in *A. marsupialis* as it does in *A. bondi* (Fig. 7, char. 43).
4. The dorsal margin of the medial profile of the malleolus medialis is more curved and projects further distally in *A. bondi* (Fig. 7, char. 45).
5. The medial view of the plantar margin of the distal tibia curves inward in *A. bondi*, but protrudes outward in *A. marsupialis* (Fig. 7, char. 45).

Os malleolare

No constant differences were found.

Ossa tarsi**Talus**

No constant morphological differences were found, but metric data indicate that the talus in *A. marsupialis* is somewhat more slender.

**Fig. 6**

- A: *Antidorcas marsupialis* phalanx proximalis manus, palmar view.
 B: *Antidorcas bondi* phalanx proximalis manus, palmar view.
 C: *Antidorcas marsupialis* phalanx media manus, axial view.
 D: *Antidorcas bondi* phalanx media manus, axial view.
 E: *Antidorcas marsupialis* phalanx media manus, proximal view.
 F: *Antidorcas bondi* phalanx media manus, proximal view.
 G: *Antidorcas marsupialis* phalanx distalis manus, axial view.
 H: *Antidorcas bondi* phalanx distalis manus, axial view.
 I: *Antidorcas marsupialis* os femoris, proximal extremity, cranial view.
 J: *Antidorcas bondi* os femoris, proximal extremity, cranial view.

Calcaneus

1. The lateral profile shows a slight protruberance on the plantar side of the calcanei of *A. marsupialis*. This protruberance is absent in *A. bondi* (Fig. 8, char. 46).

Os centroquartale

No constant morphological differences were found.

Os tarsale I

No constant morphological differences were found.

Os tarsale II + II

No constant morphological differences were found.

Os metatarsale III + IV

1. The habitus of the os metatarsale III + IV, as the os metacarpale is longer and more slender in *A. marsupialis* (not illustrated).
2. The synovial groove of the facies articularis proximalis is relatively deep and narrow in *A. bondi*, but shallower and wider in *A. marsupialis* (Fig. 8, char. 47).
3. The small lateroplantar facet is more strongly defined and elevated in *A. bondi* (Fig. 8, char. 48).
4. The dorsal margin of the facies articularis proximalis is convex in *A. marsupialis*, but somewhat concave in *A. bondi* (Fig. 8, char. 49).
5. The plantar side of the proximal metatarsus has a strongly developed nutrient foramen in *A. bondi*. This foramen is usually, but not always, absent in *A. marsupialis* (Fig. 8, char. 50).
6. The muscle ridges on the plantar side of the shaft are more developed in *A. bondi* (Fig. 8, char. 51).
7. In *A. bondi* the trochleae ossis metatarsalis III + IV are, as in the os metacarpale, well developed. In *A. bondi* the plantar fossulae are also deeper and more developed than in *A. marsupialis* (Fig. 8, char. 52).
8. The sagittal ridges of the trochleae are longer and extend further proximally on the plantar side in *A. bondi* (Fig. 8, char. 53).

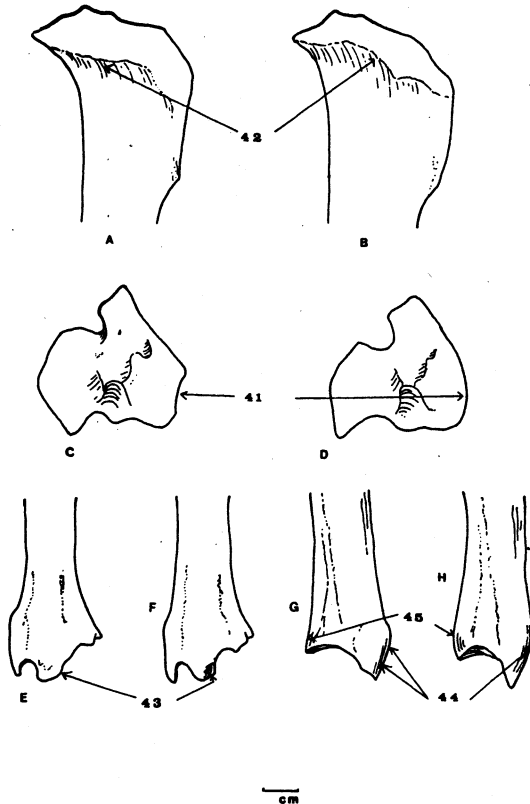


Fig. 7

- A: *Antidorcas marsupialis* tibia, proximal extremity, medial view.
 B: *Antidorcas bondi* tibia proximal extremity, medial view.
 C: *Antidorcas marsupialis* tibia, proximal view.
 D: *Antidorcas bondi* tibia, proximal view.
 E: *Antidorcas marsupialis* tibia distal extremity, dorsal view.
 F: *Antidorcas bondi* tibia distal extremity, dorsal view.
 G: *Antidorcas marsupialis* tibia, distal extremity, medial view.
 H: *Antidorcas bondi* tibia distal extremity, medial view.

Ossa digitorum pedis.

Phalanx proximalis

1. The muscle scars on the plantar surface of the shaft of the phalanx proximalis are strongly developed in *A. bondi* and present, but weakly developed, in *A. marsupialis* (Fig. 9, char. 54).
2. In plantar view the trochleae proximalis are relatively large and the abaxial trochleae extends

- further proximally in *A. marsupialis* (Fig. 9, char. 55).
3. The first phalanges of the hind foot are of comparable size in both species, but they tend to be somewhat broader in *A. bondi* (Fig. 9, char. 56). This is in contrast to the relative size of the phalanges proximalis manus, which are relatively long in *A. marsupialis*.

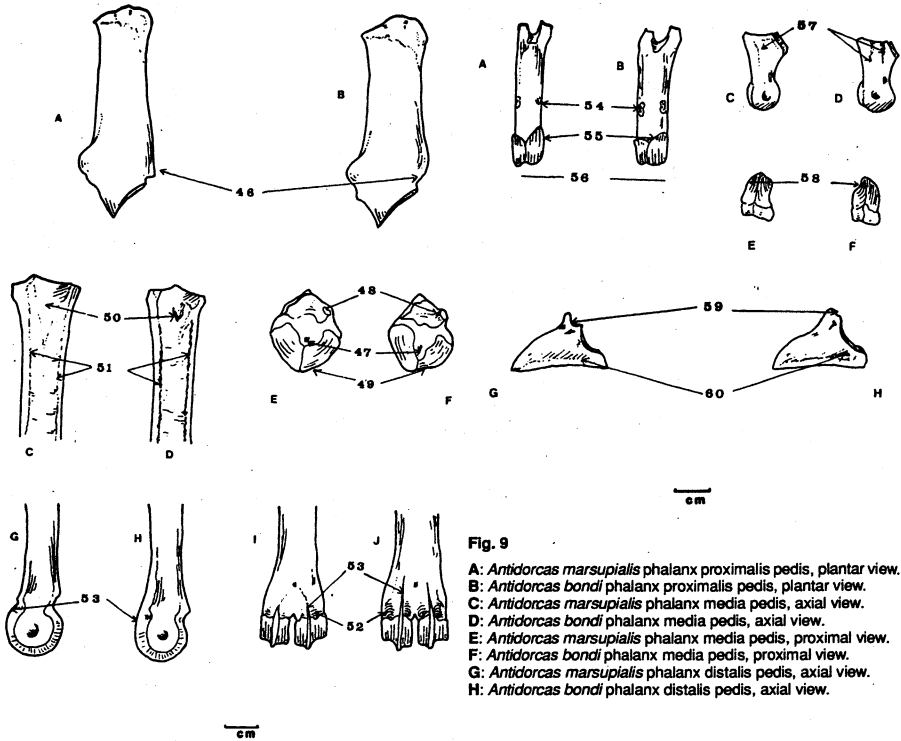


Fig. 8

- A: *Antidorcas marsupialis* calcaeus, lateral view.
 B: *Antidorcas bondi* calcaeus, lateral view.
 C: *Antidorcas marsupialis* os metatarsale III + IV, proximal extremity, plantar view.
 D: *Antidorcas bondi* os metatarsale III + IV, proximal extremity, plantar view.
 E: *Antidorcas marsupialis* os metatarsale III + IV, proximal view.
 F: *Antidorcas bondi* os metatarsale III + IV, proximal view.
 G: *Antidorcas marsupialis* os metatarsale III + IV, distal extremity, lateral view.
 H: *Antidorcas bondi* os metatarsale III + IV, distal extremity, lateral view.
 I: *Antidorcas marsupialis* os metatarsale III + IV, distal extremity, plantar view.
 J: *Antidorcas bondi* os metatarsale III + IV, distal extremity, plantar view.

Phalanx media

1. The axial side has two clearly marked indentations in *A. bondi*. These indentations are absent or weakly developed in *A. marsupialis* (Fig. 9, char. 57).

Fig. 9

- A: *Antidorcas marsupialis* phalanx proximalis pedis, plantar view.
 B: *Antidorcas bondi* phalanx proximalis pedis, plantar view.
 C: *Antidorcas marsupialis* phalanx media pedis, axial view.
 D: *Antidorcas bondi* phalanx media pedis, axial view.
 E: *Antidorcas marsupialis* phalanx media pedis, proximal view.
 F: *Antidorcas bondi* phalanx media pedis, proximal view.
 G: *Antidorcas marsupialis* phalanx distalis pedis, axial view.
 H: *Antidorcas bondi* phalanx distalis pedis, axial view.

2. In *A. bondi* the indentations on the axial side cause a constriction on the axial margin of the facies articularis proximalis (Fig. 9, char. 58).

Phalanx distalis

1. The processus extensorius is placed somewhat distally in *A. marsupialis*. In *A. bondi* it is placed immediately above the facies articularis (Fig. 9, char. 59).
2. In *A. bondi* a large prominent nutrient foramen is present on the axial side, close to the facies articularis. This feature is absent or marginally indicated in *A. marsupialis* (Fig. 9, char. 60).

Osteometry

The osteometry of *A. marsupialis* is not discussed in this paper as it is the subject of a paper by Peters and Brink (in preparation). We nevertheless present osteometric data for *A. bondi* (Table 1) because it can facilitate identification when

used in conjunction with osteomorphological characteristics.

Preliminary comparisons have shown that skeletal elements of the limbs of *A. bondi* are shorter, or fall within the lower range of variation of those of *A. marsupialis*. The radius, os carpi radiale and the phalanges proximalis manus of *A. bondi* are also relatively broad compared to their length. This suggests that *A. bondi* was on average smaller and sturdier than *A. marsupialis*. Based on the lengths of bones of the forelimb, the shoulder height of *A. bondi* could have been 65–75 cm. The shoulder height of recent *A. marsupialis* is 70–90 cm (Haltenorth, Diller and Smeenk, 1979). It should be noted that in the present study the *A. bondi* material came from two sites only, whereas the recent *A. marsupialis* skeletons (Peters and Brink, in preparation) are from various localities covering a large geographic area.

CONCLUDING REMARKS

This study has shown that osteomorphological, and also osteometric, differences exist between the skeletal elements of *A. bondi* and *A. marsupialis* and that many of the diagnostic features are preserved in fragmented material. When Swartkrans specimens were compared to those from Florisbad, the osteomorphological and osteometric distinguishing features remained the same.

The osteomorphological distinguishing features can be categorized as strongly diagnostic, moderately diagnostic, 'one way' only, and reliable only when considered in combination with other features. Strongly diagnostic characteristics are nos.

4, 7, 8, 10, 17, 20, 27, 28, 29, 30, 31, 33, 36, 37, 38, 39, 46, 48, 53, 57, 58, 59, and 60. Moderately strong diagnostic characteristics are nos. 1, 3, 5, 6, 9, 13, 15, 22, 25, 26, 32, 34, 35, 47, 49, 50, 51, 52, 54, 55, and 56. The only 'one way' feature is characteristic 2. All other characteristics are reliable only when considered in combination.

Most of the osteomorphological features that separate the two species are valid over all age groups. There are, however, a few characteristics that are present in adult, but absent in young or subadult, *A. bondi*. These include the muscle ridges on the corpus radii and those on the palmar/plantar side of the phalanges proximalis manus and pedis respectively.

Some of the morphological features could be related to function. The strongly developed lateral articular process of the ulna and its complement in the proximal radius, as well as the relatively elongated phalanx proximalis of *A. marsupialis*, suggest that the forelimbs were built differently in the two springbok species. It suggests that *A. bondi* with its shorter, less specialized articulation of the forelimb was less inclined to jump than *A. marsupialis*.

During this study a few Swartkrans Member 2 postcranial fragments referred to *A. australis* and/or *A. marsupialis* were examined. They failed to disclose features that distinguish them from modern *A. marsupialis*. *Antidorcas australis*, an extinct springbok, also represented in Pleistocene deposits of the Cape Zone (Hendey, 1974; Klein, 1983), needs to be osteomorphologically studied, as our preliminary examination of the Swartkrans material casts some doubt on its taxonomic status.

Table 1
Osteometric data of *Antidorcas bondi*.

Element	Measurements	n	Mean	SD	Max.	Min.
Scapula	SLC	3	18,7	1,4	19,6	17,1
	GLP	4	30,7	1,1	32,3	30,1
	LG	4	25,5	0,8	26,4	24,6
Humerus	BG	4	21,2	1,5	23,3	20,1
	BT	7	27,7	1,1	28,9	25,5
	Bd	7	30,8	2,1	33,6	28,3
Radius	Dmrd	7	27,1	1,2	28,7	25,2
	GL	1	167,7	—	—	—
	BFP	17	26,5	1,2	27,6	23,1
Ulna	Bp	17	28,6	1,2	30,0	26,2
	Dp	18	15,7	0,7	17,4	14,7
	Bd	9	26,4	1,3	28,9	24,7
	LO	2	42,9	1,1	43,6	42,1
	DPA	3	26,0	1,2	27,4	25,0
	BPC	11	15,6	0,9	16,5	13,4
	BIT	11	9,9	0,5	10,7	9,0

Table 1 (continued)

Os carpi radiale	GD	11	18,7	1,2	20,5	17,4
	GH	11	13,3	0,8	14,6	12,0
	Bd	11	9,6	0,7	10,4	8,0
Os carpi intermedium	GD	9	18,7	0,7	19,6	17,8
	GH	9	11,5	0,4	12,0	10,7
Os carpi ulnare	GL	10	17,4	1,2	18,8	15,8
Os carpale IV	BFd	6	10,1	0,4	10,7	9,8
	GH	6	9,8	0,3	10,2	9,2
Os metacarpale III+ IV	GL	1	170,0	—	—	—
	Bp	18	21,8	1,0	23,1	20,3
	Dp	18	16,7	1,1	18,1	14,6
	Sd	3	13,8	1,1	15,0	13,0
	DD	7	11,7	1,7	14,0	9,6
	BD	7	22,4	1,2	24,5	20,9
	Dd	7	16,5	0,6	17,0	15,3
	GLPe	34	47,1	1,9	51,1	43,5
Phalanx proximalis manus	GLAx	33	46,7	1,8	51,1	43,5
	Bp	34	10,8	0,6	12,4	9,6
	Bd	35	9,5	0,5	10,8	8,7
	Sd	37	9,1	0,6	10,3	8,0
Phalanx media manus	GL	22	23,8	1,1	26,0	21,8
	Bp	22	9,8	0,6	11,1	8,8
	Dp	21	14,4	1,2	16,4	12,7
	Bd	22	8,4	0,6	9,4	7,1
	Sd	20	7,8	0,6	8,7	6,6
Phalanx distalis cf. manus	DLS	19	25,4	0,8	26,5	24,3
	Ld	20	22,1	0,9	24,1	20,6
	HP	21	17,7	0,8	17,8	15,3
	BFp	23	7,8	0,4	8,5	7,3
Os femoris	Bp	1	47,1	—	—	—
	BT	1	21,4	—	—	—
	Bd	1	34,8	—	—	—
	DLd	1	42,1	—	—	—
	DMd	1	51,4	—	—	—
Tibia	Bp	1	41,0	—	—	—
	Dp	1	43,9	—	—	—
	Bd	23	26,9	0,8	29,1	24,9
Talus	Dd	23	21,5	1,5	26,7	19,6
	GLI	25	29,2	1,2	31,1	26,9
	GLm	25	26,8	1,0	28,8	24,7
	DI	25	17,0	0,7	18,1	15,4
	Bd	25	17,7	0,7	19,1	16,5
Calcaneus	GL	7	63,0	2,2	66,4	60,0
	GB	6	20,7	1,2	22,0	18,6
	Bp	7	14,0	0,8	15,3	13,0
	DS	6	21,6	2,2	24,8	18,9
	Dd	7	24,1	1,9	26,2	20,5
Os centroquartale	GB	1	23,9	—	—	—
	GD	1	23,9	—	—	—
Os metatarsale III + IV	GL	1	189,0	—	—	—
	Bp	21	20,6	0,9	22,6	18,9
	Dp	21	24,6	0,9	26,4	23,0
	Sd	8	12,3	0,8	14,1	11,2
	DD	14	12,6	0,9	14,4	10,9
	Bd	17	23,2	1,0	24,8	21,7
	Dd	17	17,1	0,9	18,4	15,6
Phalanx proximalis pedis	GLPe	40	38,7	1,5	42,1	36,3
	GLAx	38	37,5	1,6	41,1	35,1
	Bp	40	11,4	0,5	12,5	8,3
	Bd	49	9,8	0,6	11,4	8,3
Phalanx media pedis	Sd	51	9,4	0,6	10,5	8,1
	GL	25	22,9	0,8	24,4	21,1
	Bp	25	9,5	0,5	10,7	8,5
	Dp	25	14,4	0,6	15,5	13,2
	Bd	25	8,1	0,4	8,9	7,5
Phalanx distalis cf. pedis	Sd	23	7,6	0,5	8,5	6,6
	DLS	14	27,7	0,9	28,7	26,1
	Ld	13	23,7	1,1	25,6	21,7
	Hp	14	17,9	0,8	19,7	16,6
	BFp	16	8,5	0,4	9,1	7,5

ACKNOWLEDGEMENTS

We wish to thank Dr C. K. Brain and Mr J. Brink for allowing us access to the *A. bondi* material. We are grateful to Dr V. Watson and Ms E. de Wet for their assistance. We gratefully acknowledge

the Foundation for Research Development (FRD) for financial support.

REFERENCES

- BRAIN, C. K., 1981. *The hunters or the hunted?* University of Chicago Press, Chicago.
- BRAIN, C. K., CHURCHER, C. S., CLARK, J. D., GRINE, F. E., SHIPMAN, P., SUSMAN, R. L., TURNER, A. and WATSON, V., 1988. New evidence of early hominids, their culture and environment from the Swartkrans Cave, South Africa. *South African Journal of Science* 84: 828-835.
- BRINK, J. S., 1987. The archaeozoology of Florisbad, Orange Free State. *Memoirs van die Nasionale Museum Bloemfontein* No. 24, pp. 1-151.
- BROWN, A. J. V. and VERHAGEN, Th., 1985. Two *Antidorcas bondi* individuals from the Late Stone Age of Kruger Cave 35/83, Olifantsnek, Rustenburg District, South Africa. *South African Journal of Science* 81(2): 102.
- HALTENORTH, Th., DILLER, N. and SMEENK, C., 1979. *Elseviers gids van de Afrikaanse zoogdieren*. Elsevier, Amsterdam.
- HENDEY, Q. B., 1974. The late Cenozoic carnivora of the south-western Cape province. *Annals of the South African Museum* 63: 1-369.
- KLEIN, R. G., 1983. Palaeoenvironmental implications of Quaternary large mammals in the Fynbos region. In: DEACON, H. J. and LAMBRECHTS, J. J. N., eds, *Fynbos palaeoecology: a preliminary synthesis*, pp. 116-138. South African National Scientific Programmes Report No. 75.
- KLEIN, R. G., 1984a. Later Stone Age faunal samples from Heuningneskrans shelter (Transvaal) and Leopard's Hill Cave (Zambia). *South African Archaeological Bulletin* 39: 109-116.
- KLEIN, R. G., 1984b. The large mammals of southern Africa: Late Pliocene to Recent. In: KLEIN, R. G., ed., *Southern African prehistory and palaeoenvironments*, pp. 107-146. A. A. Balkema, Rotterdam.
- NOMINA ANATOMICA VETERINARIA, 1983. Nomina histologica. International Committee of Veterinary Gross Anatomical Nomenclature under the financial responsibility of the World Association of Veterinary Anatomists, 3rd edn. Ithaca, New York.
- PETERS, J., 1986. Osteomorphology and osteometry of the appendicular skeleton of African buffalo, *Syncerus caffer* (Sparman, 1779) and cattle, *Bos primigenius* f. *taurus* bojanus, 1827. Occasional Papers, Laboratorium voor Paleontologie. No. 1. Rijksuniversiteit, Ghent.
- PETERS, J. and BRINK, J. S., in preparation. Comparative postcranial osteomorphology and osteometry of springbok, *Antidorcas marsupialis* (Zimmerman, 1780) and grey rhebok, *Pelea capreolus* (Forster, 1790) (Mammalia: Bovidae).
- VON DEN DRIESCH, A., 1976. *A guide to the measurements of animal bones from archaeological sites*. Peabody Museum Bulletin 1, Harvard University.
- VRBA, E. S., 1973. Two species of *Antidorcas* Sundevall at Swartkrans (Mammalia: Bovidae). *Annals of the Transvaal Museum* 28(15): 287-352.
- VRBA, E. S., 1976. The fossil Bovidae of Sterkfontein, Swartkrans and Kromdraai. *Transvaal Museum Memoir* No. 21, pp. 1-166.

Postal addresses: I. Plug
Department of Archaeozoology
Transvaal Museum
P. O. Box 413
Pretoria
0001 South Africa

J. Peters
Institut für Palaeoanatomie
Universität München
10/11 Schellingstrasse
München 8000
Germany

Appendix
Antidorcas bondi material examined.
 SK = Swartkrans, FLO = Florisbad.

Scapula

SK 41984, SK 45008, SK 47340, SK 42841.

Humerus

SK 43043, SK 43820, SK 40611, SK 41528, SK 43059, FLO 3868, FLO 3629.

Radius

SK 40583, SK 41842, SK 42382, SK 41280, SK 41552, SK 41824, SK 45024, SK 42434, SK 44078, SK 42634, SK 42682, SK 45022, SK 41747, SK 44906, SK 45199, SK 47321, SK 42649, SK 42625, SK 43086, SK 43104, SK 41880, SK 44809, SK 42683, SK 41079, SK 42645.

Ulna

SK 47238, SK 41324, SK 41088, SK 41885, SK 40714, SK 42665, SK 43263, SK 42693, SK 44429, SK 41321, SK 43125.

Os carpi radiale

SK 41779, SK 43021, SK 43193, SK 41765, SK 41886, SK 41896, SK 41517, SK 44409, SK 44413, SK 45294, SK 43147.

Os carpi intermedium

SK 47371, SK 45338, SK 43140, SK 42750, SK 41519, SK 45370, SK 47261, SK 45336, SK 44435.

Os carpi ulnare

SK 44416, SK 44418, SK 44411, SK 44440, SK 45097/18, SK 47282, SK 42518, SK 45215, SK 41058/4, SK 45320/7.

Os carpale IV

SK 41094, SK 43116, SK 41104, SK 43934, SK 44432, SK 42863/2.

Os metacarpale III + IV

SK 42366, SK 41541, SK 41060, SK 44904, SK 43303, SK 47229, SK 47293, SK 40724, SK 40719, SK 41731, SK 41058/6, SK 44238/6, SK 40702, SK 40717, SK 40718, SK 44084, SK 41734, SK 40709, SK 42343, SK 44882, SK 44876, SK 41766, FLO 3622, FLO 3796.

Phalanx proximalis manus

SK 44837, SK 44836, SK 42405, SK 43257, SK 43940, SK 44386, SK 43167, SK 41303, SK 42782, SK 42763, SK 41521, SK 41867, SK 40751, SK 41823, SK 44853, SK 42292, SK 41788, SK 45001, SK 45127, SK 44377, SK 43945, SK 43943, SK 44389, SK 45221, SK 41902, SK 44833, SK 47833, SK 47332, SK 44847, SK 45256, SK 41282, SK 43944, SK 41208, SK 44835, SK 43309, FLO 56557777.

Phalanx media manus

SK 43034, SK 45350, SK 40774, SK 41821, SK 42300, SK 44776, SK 42287, SK 44367, SK 45350, SK 43001, SK 42438, SK 44778, SK 43148, SK 41795, SK 44842, SK 41510, SK 45305, SK 43269, SK 44383, SK 45004, FLO 3685, FLO 3712.

Phalanx distalis cf. manus

SK 43756, SK 47275, SK 42458, SK 44773, SK 44361, SK 44775.

SK 44358, SK 47254, SK 46046, SK 44111, SK 40766, SK 40770, SK 43037, SK 44931, SK 43959, SK 44104, SK 41809, SK 41059, SK 45384/21, SK 45384/14, SK 42863/14, FLO (no number, two specimens).

Os femoris

SK 44880, SK 44444.

Tibia

SK 41940, SK 41344, SK 43788, SK 45264, SK 42650, SK 41311, SK 43779, SK 42629, SK 43778, SK 42640, SK 41084, SK 43972, SK 43782, SK 43787, SK 41322, SK 47305, SK 42631, SK 44933, SK 41538, SK 42628, SK 43189, SK 42343, SK 44943, FLO 3814.

Talus

SK 42430, SK 40729, SK 47319, SK 42440, SK 42427, SK 41892, SK 44394, SK 44395, SK 44639, SK 45006, SK 42469, SK 41312, SK 42324, SK 42417, SK 41075, SK 47240, SK 47388, SK 42973, SK 42973, SK 41913, FLO 3609, FLO 4116, FLO 3588, FLO 3745, FLO 1774, FLO 1782.

Calcaneus

SK 42524, SK 4208, SK 45015, SK 43041, SK 47, FLO 3746.

Os centroquartale

FLO 3723.

Os metatarsale III + IV

SK 41729, SK 42626, SK 42598, SK 43659, SK 43771, SK 41752, SK 41846, SK 47289, SK 47233, SK 44930, SK 42633, SK 41529, SK 41295, SK 41534, SK 42630, SK 41289, SK 42638, SK 45019, SK 43611, SK 47786, SK 42349, SK 41726, SK 44900, SK 43786, SK 44903, SK 42760, SK 42641, SK 41889, SK 41845, SK 41087, SK 42635, SK 44963, SK 41072, SK 41753, SK 47831, SK 40752, SK 43648.

Phalanx proximalis pedis

SK 42855, SK 44388, SK 40735, SK 44382, SK 45213, SK 44378, SK 45016, SK 41277, SK 44371, SK 45039, SK 43954, SK 40741, SK 47325, SK 44781, SK 44850, SK 44832, SK 42761, SK 44855, SK 45002, SK 43621, SK 42356, SK 44391, SK 42354, SK 40694, SK 44851, SK 43305, SK 45311, SK 42428, SK 43605, SK 47310, SK 42410, SK 45018, SK 41781, SK 40661, SK 45333, SK 44500, SK 41882, SK 42368, SK 47244, SK 45218, SK 41801, SK 42345, SK 44846, SK 44372, SK 45238, SK 40731, SK 447306, SK 47839, SK 44158, FLO 3551, FLO 1450.

Phalanx media pedis

SK 40739, SK 40754, SK 43259, SK 44316, SK 44392, SK 45242, SK 43103, SK 43056, SK 42310, SK 43192, SK 44366, SK 43258, SK 43962, SK 45026, SK 40753, SK 45155, SK 42947, SK 41590, SK 42382, SK 44373, SK 44838, SK 43634, SK 41364, FLO 1450, FLO 4075.

Phalanx distalis cf. pedis

SK 42420, SK 41760, SK 42763, SK 47334, SK 44360, SK 47761, SK 42429, SK 43955, SK 42827, SK 41585, SK 43958, SK 40758, SK 45271, SK 44945, SK 45235, SK 44948.

Guidelines for Authors

The *Annals of the Transvaal Museum* exist primarily for the publication of research results of Transvaal Museum scientists and their collaborators. Other contributors should write to the Editor before submitting manuscripts, outlining the scope and length of the manuscript/s that they intend to submit.

Manuscripts written only in English or Afrikaans will be considered for publication.

Editorial procedure

All manuscripts submitted for publication are reviewed internally by an Editorial Committee and by at least two external referees. The final decision as to the acceptance or rejection of a manuscript is made by the Editorial Committee.

Manuscripts are submitted to our printer on 5 1/4" double-sided double-density diskettes. WordStar 2000 Plus, run under MS-DOS 3.3, is used to edit manuscripts. This is the ideal format in which contributions should be submitted. Manuscripts processed with other WordStar versions can also be easily read into WordStar 2000. However, manuscripts generated with other word-processing packages such as MultiMate, WordPerfect or DisplayWrite, should be submitted as Revisable Format Text DCA (preferably) or ASCII files. Conversion to the latter format is supported by almost all word-processors.

Manuscript style

Authors should consult recent issues of the *Annals*, particularly articles in their field of interest, for finer points of house style.

The contents of articles should be arranged in this order: title, author/s, preferred abbreviated address/es of author/s, abstract, keywords, text, acknowledgements, references, full postal address/es, figure captions, tables (each on a separate sheet), and copies of illustrations. All manuscripts should be submitted in triplicate.

The manuscript must be typed or printed double-spaced on one side of good quality A4 (277 × 210 mm) paper. Pages must be numbered consecutively. Margins of at least 2 cm should be left around the typescript.

Spelling should follow the *Oxford English Dictionary* and Lincoln, Boxshall and Clark's (1983) *A dictionary of ecology, evolution and systematics*.

The metric system of SI units and their symbols and abbreviations should be used. The decimal comma must be used.

Time should be referred to in terms of the '24-hour clock' (13:00) and dates should be in the form '1 January 1949'.

A specific name should not stand alone. It should be preceded by the generic name or its abbreviation.

Title

In the case of zoological papers, the title should include the higher classification of the group being studied. The preferred abridged title for use as a running head should be indicated.

Abstract

Abstracts should be concise and not exceed 3% of the total length of the article.

Text

Do not right-justify text or hyphenate a word at the end of a line. Footnotes should be kept to a minimum.

All headings should be in lower case. Paragraphs should be indented.

References

All references in the text, using the author-date system, e.g., (Taylor, 1987) or (Taylor, 1987: 243–49), must appear in the References section. The full titles of scientific journals must be given. Volume numbers must be in bold, and when required, preceded by series or followed by part numbers in parentheses. If more than one publication by the same author is cited, the name must be given with each reference, and if they were published in the same year, these should be distinguished by adding 'a', 'b' etc. after the date.

The following examples show the method of reference citation (note spacing and punctuation):

Journal articles

- DUARTE-RODRIGUES, P., 1987. New species and records of lacebugs (Heteroptera: Tingidae) from southern Africa. *Annals of the Transvaal Museum* **34**(16): 349–369.
- DIPPENAAR, N. J. and RAUTENBACH, I. L., 1986. Morphometrics and karyology of the southern African species of the genus *Acomys* I. Geoffroy Saint-Hilaire, 1838 (Rodentia: Muridae). *Annals of the Transvaal Museum* **34**(6): 129–183.

Books

- ANSELL, W. F. H., 1978. *The mammals of Zambia*. National Parks and Wildlife Service, Chilanga.
- HONACKI, J. H., KINMAN, K. E. and KOEPL, J. W., eds, 1982. *Mammal species of the world*. Allen Press, Association of Systematic Collections, Lawrence, Kansas.

Articles in a book

- VRBA, E. S., 1985. Introductory comments on species and speciation. In: VRBA, E. S., ed., *Species and speciation*, pp. ix–xviii. Transvaal Museum Monograph No. 4. Transvaal Museum, Pretoria.

Tables

Each table should be typed on a separate page and should have a self-explanatory heading. Vertical rules must not be used. Table headings appear at the top of the table and should be arranged as follows:

Table 1
Cranial measurements of *Crocodyra lucina*.

The approximate position in which each table should appear in the text should be indicated in pencil on the manuscript.

Illustrations

All illustrations (line drawings, graphs, maps, half-tones) will be called figures (Fig. or Figs) and are to be numbered