



# Treatment of Pituitary Adenomas

First European Workshop on Treatment of Pituitary Adenomas at Rottach-Egern

Edited by Rudolf Fahlbusch and Klaus v. Werder  
With a Foreword by Frank Marguth

With contributions by

- |                   |                   |                   |                 |                  |
|-------------------|-------------------|-------------------|-----------------|------------------|
| H.-P. Althoff     | E. Flückiger      | U. Krause         | G. C. Nicola    | M. V. Sofroniew  |
| A. Aulich         | P. H. Forsham     | H. L. Kruskemper  | H. Nowakowski   | H. G. Solbach    |
| F. Bahner         | T. R. Fraser      | A. Kuwayama       | T. Okada        | N. Stahnke       |
| F. Banks          | U. Fricke         | S. W. J. Lamberts | L. Oliver       | H. Steinhoff     |
| J. Bansemmer      | T. Fukaya         | R. Landgraf       | G. Oppizzi      | A. Stevenaert    |
| D. Barwich        | S. M. Gaini       | A. M. Landolt     | A. E. Panerai   | K. Sugita        |
| M. Basch          | M. Giovanelli     | S. Lange          | A. Paracchi     | L. Tagliabue     |
| X. Baur           | R. Göser          | W. Lankisch       | F. Peillon      | M. Takanohashi   |
| J. M. Bayer       | A. Griner         | J. H. Lawrence    | E. F. Pfeiffer  | G. Teasdale      |
| P. Beck-Peccoz    | K. W. M. Grossart | S. Levin          | C. R. Pickardt  | L. Tharandt      |
| G. Benker         | Th. Grumme        | M. L'Hermite      | H. J. Quabbe    | C. A. Tobias     |
| J. Beyer          | C. Guiot          | J. A. Linfoot     | J. Racadot      | G. Tomei         |
| J. C. Birkenhäger | K. Hackenberg     | A. Liuzzi         | G. Ranft        | G. P. Tonnamelli |
| W. J. Bock        | W. Hadam          | V. Locatelli      | D. Reinwein     | T. Torresani     |
| B. Böttger        | J. Happ           | Ch. Lucke         | J. Resetic      | H. Traut         |
| J. L. Born        | D. Heesen         | D. Lüdecke        | H. J. Reulen    | Y. Tsujita       |
| H. J. Breustedt   | J. Herrmann       | J. Lyman          | H. K. Rjosk     | B. Tyrell        |
| P. De Camilli     | K. Hirakawa       | M. Madler         | C. Robyn        | C. Uhlig         |
| A. Caufriez       | H. Huber          | S. Manaka         | R. Rothe        | E. Vila-Porcile  |
| D. F. Child       | R. Illig          | E. Manougian      | V. Rothenbühler | E. Virasoro      |
| P. G. Chiodini    | A. Jadresic       | F. Marguth        | K. H. Rudorff   | K. H. Voigt      |
| C. Chong          | A. Jefferson      | W. Meese          | H. Ruf          | H. A. D. Walder  |
| H. E. Clar        | F. H. de Jong     | E. Meijer         | W. Saeger       | A. Weindl        |
| D. Cocchi         | G. F. Joplin      | A. Melo           | M. Samii        | S. Wende         |
| G. Colussi        | N. Kageyama       | R. Mies           | K. Sano         | K. von Werder    |
| G. Copinschi      | A. Karduck        | J. D. Miller      | U. Scherer      | W. Wiegelmann    |
| U. Cordes         | R. Kautzky        | W. Mitschke       | A. E. Schindler | O. Wilcke        |
| L. Diamant        | E. Kazner         | H. R. Montz       | K. Schöffling   | K. von Wild      |
| F. H. Doyle       | E. Keller         | E. D. F. Motti    | D. Schrader     | W. Winkelmann    |
| W. Entzian        | J. Kinnman        | D. Moussy         | W. Schuhmacher  | T. Yoshida       |
| G. U. Exner       | G. S. Kistler     | A. von zur Mühlen | K. Schürmann    | W. Zäh           |
| G. Faglia         | H. Kley           | E. E. Müller      | G. Schwinn      |                  |
| R. Fahlbusch      | J. Köbberling     | O. A. Müller      | P. C. Scriba    |                  |
| H. L. Fehm        | D. Kondo          | A. Nagamune       | G. Sell         |                  |
| C. Ferrari        | M. H. Koocheck    | M. Neubauer       | R. J. Seymour   |                  |

336 Figures, 85 Tables



Georg Thieme Publishers Stuttgart 1978

680158935

CIP-Kurztitelaufnahme der Deutschen Bibliothek

**Treatment of pituitary adenomas / 1. Europ. Workshop on Treatment of Pituitary adenomas at Rottach-Egern, October 1976.** Ed. by Rudolf Fahlbusch and Klaus v. Werder. With contributions by H.-P. Althoff ... – 1. Aufl. – Stuttgart : Thieme; Massachusetts : PSG Publishing Company, 1978.

ISBN 3-13-553801-X (Thieme)

ISBN 0-88416-236-2 (PSG)

NE: Fahlbusch, Rudolf [Hrsg.]; Althoff, H.-P. [Mitarb.]; European Workshop on Treatment of Pituitary Adenomas <01, 1976, Rottach-Egern>

680158935

Some of the product names, patents and registered designs referred to are in fact registered trademarks or proprietary names even though specific reference to this fact is not always made in the text. Therefore, the appearance of a name without designation as proprietary is not to be construed as a representation by the publisher that it is in the public domain.

All rights, including the rights of publication, distribution and sales, as well as the right to translation, are reserved. No part of this work covered by the copyrights hereon may be reproduced or copied in any form or by any means – graphic, electronic or mechanical including photocopying, recording, taping, or information and retrieval systems – without written permission of the publisher.

© 1978 Georg Thieme Verlag, Herdweg 63, P.O.B. 732, D-7000 Stuttgart 1 – Printed in Germany by Karl Grammlich, Pliezhausen

Thieme: ISBN 3-13-553801-X

PSG: ISBN 0-88416-236-2

PSG: LCCCN 77-99148

## Contents

Introductory remarks by the editors . . . . .	III
List of contributors . . . . .	IV
<b>Introduction to the workshop: F. Marguth</b>	
Foreword . . . . .	1
<b>ENDOCRINE AND MORPHOLOGICAL ASPECTS – PART I</b>	
P.C. Scriba, C.R. Pickardt, K. v. Werder: Physiology of the hypothalamo-Pituitary unit . . . . .	3
A. Weindl, M.V. Sofroniew: Morphology of the hypothalamo-Pituitary unit . . . . .	10
H.G. Solbach, W. Wiegelmann, H. Kley, K.H. Rudorff, H.L. Krüskemper: Endocrine evaluation of pituitary insufficiency . . . . .	38
H.J. Quabbe: Endocrinology of growth hormone producing tumors . . . . .	47
M. L'Hermite, A. Caufriez, E. Virasoro, A. Stevenaert, G. Copinschi, C. Robyn: Endocrinology of prolactin-producing tumors . . . . .	60
H.L. Fehm, K.H. Voigt, E.F. Pfeiffer: Endocrinology of ACTH producing pituitary tumors . . . . .	77
<b>Short contributions</b>	
W. Winkelmann, U. Fricke, W. Hadam, D. Heesen, R. Mies: Evaluation of dopaminergic and serotonergic regulation of growth hormone and prolactin in acromegaly . . . . .	87
G. Faglia, A. Paracchi, P. Beck-Peccoz, C. Ferrari: Assessment of the results of transsphenoidal hypophysectomy in acromegaly by means of TRH and L-Dopa tests . . . . .	91
J. Beyer, J. Happ, U. Cordes, G. Sell, U. Krause, M. Samii, K. Schürmann: Pituitary function after surgical treatment of pituitary adenomas . . . . .	94
K.H. Rudorff, W. Wiegelmann, J. Herrmann, H.K. Kley, H.G. Solbach, H.L. Krüskemper: Hypothalamo-pituitary dysfunction in eosinophilic granuloma . . . . .	98
<b>ENDOCRINE AND MORPHOLOGICAL ASPECTS – PART II</b>	
E. Kazner, R. Fahlbusch, W. Lanksch, R. Rothe, U. Scherer, H. Steinhoff, Th. Grumme, S. Lange, W. Meese, A. Aulich, S. Wende: Computerized tomography in diagnosis and follow-up examination of pituitary adenomas . . . . .	101
F. Peillon, J. Racadot, D. Moussy, E. Vila-Porcile, L. Oliver, O. Racadot: Prolactin-secreting adenomas. A correlative study of morphological and clinical data . . . . .	114

## VIII Contents

W. Saeger: Morphology of ACTH-producing pituitary tumors . . . . .	122
J. Kinnman: Morphology of adenomas in acromegaly . . . . .	130
A.M. Landolt, V. Rothenbühler, G.S. Kistler: Morphology of the chromophobe adenoma . . . . .	154

### Short contributions

P. De Camilli, L. Tagliabue, A. Paracchi, G. Faglia, P. Beck-Peccoz, M. Giovannelli: In vitro study on the release of GH by fragments of GH-producing human pituitary adenomas. Effect of TRH and DB cAMP . . . . .	172
D. Kondo, S. Manaka, A. Nagamune, Y. Tsujita, K. Hirakawa, K. Sano: Electrophysiological study on pituitary adenoma cells in tissue culture . . . . .	179
N. Kageyama, A. Kuwayama, T. Yoshida, T. Okada, T. Fukaya, M. Takanohashi, K. Sugita: Results of transsphenoidal operation and tissue culture studies in GH secreting pituitary adenomas . . . . .	182
K. v. Wild, H. Ruf, M. Neubauer, H.-P. Althoff, K. Schöffling: Perioperative hormone measurements in patients with pituitary adenomas and hormone replacement therapy . . . . .	186
R. Illig, T. Torresani, G.U. Exner: Plasma prolactin before and after TRH in 24 children with craniopharyngioma . . . . .	193
G. Benker, K. Hackenberg, L. Tharandt, W. Zäh, H.E. Clar, W.J. Bock, D. Reinwein: Treatment of hypothalamic-pituitary tumors: Endocrine aspects with special regard to acromegaly . . . . .	196

### OPERATIVE TREATMENT

G. Guiot: Considerations on the surgical treatment of pituitary adenomas . . . . .	202
R. Kautzky, D. Lüdecke, H. Nowakowski, D. Schrader, N. Stahnke, Ch. Lucke, H.G. Solbach, W. Wiegelmann: Transsphenoidal operation in acromegaly . . . . .	219
R. Fahlbusch, H.K. Rjosk, K. v. Werder: Operative treatment of prolactin-producing adenomas . . . . .	225
A. Jefferson: The treatment of chromophobe pituitary adenomas by means of transfrontal surgery, radiation therapy and supportive hormone therapy . . . . .	237
R.J. Seymour, S. Levin, B. Tyrell, P.H. Forsham: Long-term results of cryohypophysectomy for the treatment of acromegaly . . . . .	253
G.F. Joplin, L. Banks, D.F. Child, L. Diamant, F.H. Doyle, T.R. Fraser, A. Jadresic, M.H. Koochek: Treatment of acromegaly by pituitary implantation of 90y . . . . .	261

J.H. Lawrence, C.A. Tobias, C. Chong, J. Lyman, J.L. Born,  
 J.A. Linfoot, E. Manougian:  
 The treatment of pituitary neoplasms with heavy particles . . . . . 266

**Short contributions**

M. Giovanelli, S.M. Gaini, G. Tomei, E.D.F. Motti, P. Beck-Peccoz,  
 A. Paracchi, P. de Camilli:  
 Transsphenoidal microsurgery of hypersecreting pituitary tumors . . . . . 272

G. Teasdale, K.W.M. Grossart, J.D. Miller:  
 Comparison of cryosurgery and microsurgery in the management  
 of acromegaly . . . . . 280

O. Wilcke, D. Heesen, W. Winkelmann:  
 Experiences in 78 <sup>90</sup>Yttrium implantations in acromegaly . . . . . 284

G.C. Nicola, G.P. Tonarelli, A. Greiner:  
 Transsphenoidal surgery for secreting pituitary adenomas . . . . . 287

W. Entzian, A. Melo:  
 Transnasal-transsphenoidal approach to pituitary adenoma-extirpation:  
 effects on visual functions . . . . . 293

A. Karduck, W.J. Bock:  
 Transmaxillar-transsphenoidal hypophysectomy: Approach and  
 rhinological follow-up . . . . . 299

H.E. Clar, K. Hackenberg, D. Reinwein, W. Schuhmacher, G. Ranft:  
 Comparative results in cases of tumors of the sellar region after  
 operation by transsphenoidal and transcranial approach . . . . . 304

M. Samii, K. Schürmann:  
 Operative treatment in relation to location and extension of pituitary  
 adenomas: Results . . . . . 310

K. Schürmann, H.J. Reulen, J. Beyer:  
 A dramatic bleeding during transsphenoidal operation on an apparent  
 pituitary adenoma caused by an intrasellar aneurysm . . . . . 316

H.A.D. Walder, E. Meijer:  
 Some considerations on the differential therapy of pituitary adenomas . . . 323

**CUSHING'S SYNDROME**

D. Barwich, F. Bahner:  
 Pituitary tumors in adrenalectomized patients with Cushing's disease . . . . . 326

H. Nowakowski, H.J. Breustedt, W. Mitschke, H.R. Montz:  
 Anterior pituitary function in hypothalamic Cushing's syndrome  
 with and without ACTH-producing adenomas . . . . . 330

D.K. Lüdecke, R. Kautzky, J. Bansemmer, J. Resetic, H. Montz:  
 ACTH secretion and neurosurgical management of Cushing's disease . . . . . 333

S.W.J. Lamberts, F.H. de Jong, J.C. Birkenhäger:  
 Treatment of Cushing's disease by unilateral adrenalectomy  
 followed by external pituitary irradiation . . . . . 339

O.A. Müller, X. Baur, R. Fahlbusch, M. Madler, F. Marguth, C. Uhlig,  
 P.C. Scriba, J.M. Bayer:  
 Diagnosis and treatment of ACTH-producing pituitary tumors . . . . . 343

**MEDICAL THERAPY**

E. Flückiger:  
Pharmacology of prolactin secretion . . . . . 351

E.E. Müller, P.G. Chiodini, D. Cocchi, A.E. Panerai, G. Oppizzi,  
G. Colussi, V. Locatelli, A. Liuzzi:  
Neurotransmitter control of growth hormone secretion . . . . . 360

K. v. Werder, R. Fahlbusch, R. Landgraf, C.R. Pickardt, H.K. Rjosk,  
P.C. Scriba:  
Medical treatment of hyperprolactinemia associated with  
pituitary tumor . . . . . 377

**Short contributions**

A.E. Schindler, R. Göser, H. Traut, E. Keller:  
Ovulation induction with bromocriptine and pregnancy in  
patients with pituitary tumors . . . . . 390

H.K. Rjosk, R. Fahlbusch, H. Huber, K. v. Werder:  
Growth of prolactin-producing pituitary adenomas during pregnancy . . . . . 395

**MEDICAL THERAPY OF ACROMEGALY**

J. Köbberling, G. Schwinn:  
Medical treatment of acromegaly . . . . . 400

**Short contributions**

C. Lucke, A. von zur Mühlen:  
Evaluation of bromocriptine (CB 154) in the treatment of active  
acromegaly . . . . . 411

P.H. Althoff, M. Neubauer, M. Basch, B. Böttger, K. v. Wild,  
K. Schöffling:  
Acromegaly and bromocriptine – results of long-term treatment . . . . . 415

**DISCUSSION (Except short contributions)** . . . . . 421

**INDEX OF AUTHORS** . . . . . 438

**SUBJECT INDEX** . . . . . 440

## Medical Treatment of Hyperprolactinemia Associated with Pituitary Tumor

K. v. Werder, R. Fahlbusch, R. Landgraf, C.R. Pickardt, H.K. Rjosk and P.C. Scriba, Munich, FRG

### Summary

Forty-five female patients with prolactin-producing tumors (hPRL: 2000 to 80000  $\mu$ U/ml) and 22 male patients (hPRL: 16000 to 400000  $\mu$ U/ml) were studied. Only 25% of the females had visual field defects which were present in 70% of the males. All females had amenorrhea whereas only 31 had galactorrhea. Hypopituitarism was rarely seen in the females but was observed in most of the male patients. Twenty females and all male patients were operated upon (transsphenoidal or transfrontal hypophysectomy). Normalization of hPRL levels was achieved in only four females and in none of the males. One patient became pregnant postoperatively, four further patients after post-operative treatment with bromocriptine. Bromocriptine induced regular periods in 4 further patients operated upon by the transsphenoidal route. Eight patients with microadenomas (hPRL < 4000  $\mu$ U/ml) were treated with bromocriptine alone; two of these became pregnant. The males were also treated with bromocriptine which led to a significant fall of the hPRL level accompanied by improvement of libido, sexual potency and headaches. Two patients received radiation postoperatively, which also led to a fall of hPRL levels and improvement of visual field defects. Since hPRL levels remained low for several months after discontinuation of bromocriptine an anti-proliferative effect of this drug is suggested. Thus differential therapy for PRL-producing tumors is possible: in females selective neurosurgery alone or combined with medical therapy may normalize hPRL secretion and ovarian function. In patients with a microadenoma bromocriptine alone may be successful. In patients with inoperable large tumors radiation should be advocated. Additional bromocriptine therapy is necessary to stop tumor growth and alleviate the effects of hyperprolactinemia.

### Introduction

Since the radioimmunoassay for human prolactin (hPRL) has become available [1, 2] a large number of patients with elevated prolactin levels have been discovered. Particularly in females hyperprolactinemia with and without pituitary tumors has been shown to be a frequent cause of galactorrhea, amenorrhea or anovulatory menstrual cycles [3, 4]. But also in the male where galactorrhea is usually absent, it could be shown that many pituitary tumors formerly thought to be hormonally inactive were in fact producing prolactin [3, 5]. It seems as if the pituitary prolactinoma is the most frequent of all endocrinologically active pituitary tumors [6, 7]. In the last three years

we have been observing more than 100 patients with hyperprolactinemia in our endocrine clinic, who were treated either by surgical procedures [6], by conventional radiation, with bromocriptine, or by a combination of these therapeutic regimes [7].

## Methods

Human prolactin was measured by radioimmunoassay using the VLS-hPRL for labeling, kindly donated by the National Institute of Health. Pooled pregnancy serum served as standard; this was calibrated with the MRC-Research-Standard A-71/222 [8], kindly supplied by the National Institute for Medical Research, Holly Hill, London. 20  $\mu$ U of the MRC-Standard A-71/222 are equivalent of 1 ng VLS-hPRL from the NIH. A rabbit antiserum raised against the "little" fragment of serum hPRL served as hPRL antibody, as described previously [9]. The bound/free separation was performed by the double-antibody-procedure. No cross-reactivity with other pituitary hormones or lactogenic hormones was observed in our radioimmunoassay; the lower limit of detection was 5  $\mu$ U/ml.

Hormone determinations: human growth hormone (hGH), luteinizing hormone (LH), follicle-stimulating hormone (FSH) and thyrotropin (TSH) were measured by standard-double-antibody-radioimmunoassay [3]. Serum cortisol was also measured by radioimmunoassay, thyroxin by competitive protein-binding analysis.

Pituitary function was evaluated with the following stimulation tests:

Thyrotropin-releasing hormone (200  $\mu$ g TRH) for the stimulation of TSH and hPRL

Gonadotropin-releasing hormone (25  $\mu$ g GnRH) for the stimulation of LH and FSH.

Insulin hypoglycemia (0.15 U/kg body weight) for the stimulation of cortisol and hGH.

Anatomical evaluation in order to demonstrate a pituitary tumor: In all patients lateral skull x-rays as well as sella tomography were performed. Most of the patients had a computer tomography (CT) of the skull done on them. In all patients visual fields were examined.

## Patients

The patients investigated were referred to us because of amenorrhea and galactorrhea because of clinical evidence of pituitary insufficiency or because of visual field problems. All patients (45 females and 22 males) were admitted to the hospital before the initiation of surgical or medical therapy in order to perform the endocrine evaluation. If the patients were operated upon, pituitary function tests were repeated 6 weeks postoperatively.

## Results and Discussion

Prolactin levels in 45 female patients with amenorrhea and generally galactorrhea and pituitary tumors ranged from 1 100 to 80 000  $\mu$ U/ml (Fig. 1). As has been shown previously [6], there was a good correlation between tumor size and the amount of circulating prolactin. Thus the prolactin levels in females with amenorrhea, galactorrhea and *normal sella* did not exceed 3 500  $\mu$ U/ml (Fig. 1). Only 15% of the females with



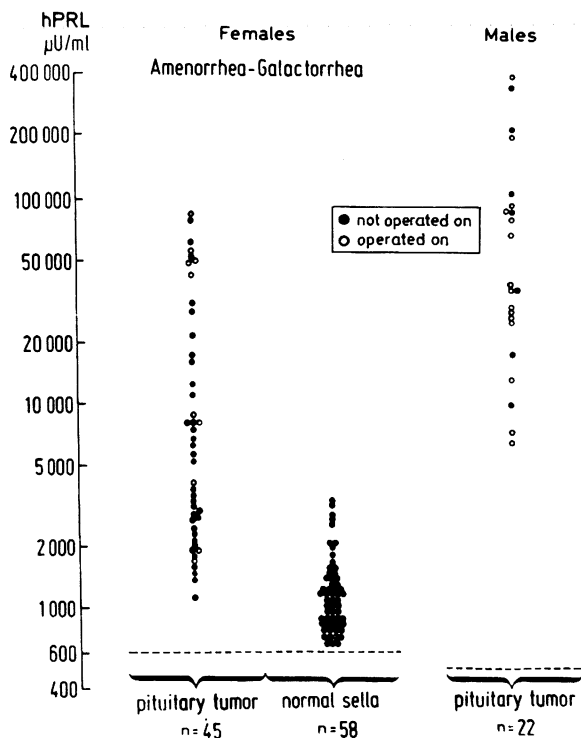


Fig. 1 Prolactin levels in 45 females and 22 males with prolactinomas compared to prolactin levels of 58 hyperprolactinemic patients with no radiological evidence of a pituitary tumor

pituitary tumors had visual field defects whereas 70% of the male patients had suprasellar extension of the tumor as documented by CT and visual field defects. Of these 22 male patients only 7 were investigated before the first operation (Fig. 1), though all had prolactin levels above 6 000  $\mu\text{U/ml}$  ranging up to 400 000  $\mu\text{U/ml}$  in one patient after several transfrontal and transsphenoidal pituitary operations; this again gives evidence for the strong correlation between tumor size and prolactin concentration. Hypopituitarism, as demonstrated by insufficient responses of pituitary hormone secretion after appropriate stimulation, was rarely seen in the females whereas most of the male patients showed lack of growth hormone and gonadotropin secretion. All patients with pituitary tumors and signs of pituitary insufficiency and/or evidence of suprasellar extension were operated upon by the transsphenoidal and sometimes transcranial route [6]. As pointed out previously [6, 10] it is extremely difficult to cure the prolactin excess by surgical means if prolactin levels are very high (Fig. 2). Thus out of 20 females with elevated prolactin levels normalization was achieved only in 6, one of whom became pregnant, whereas prolactin levels remained elevated in the other 14 patients (Fig. 2). In the male patients with the higher prolactin levels no normalization could be observed after transsphenoidal hypophysectomy, though there was a significant fall of basal prolactin levels in all of them (Fig. 2).

A typical example of a female patient with galactorrhea, amenorrhea, a pituitary tumor and chiasma syndrome is shown in Fig. 3. In this patient, who showed already impaired anterior pituitary function preoperatively together with suprasellar extension of a large prolactin-producing adenoma, operation was performed by the transsphenoidal route in addition with cryotherapy. Immediately after the operation the prolactin level levels were normalized and visual field restored to normal whereas the patient now

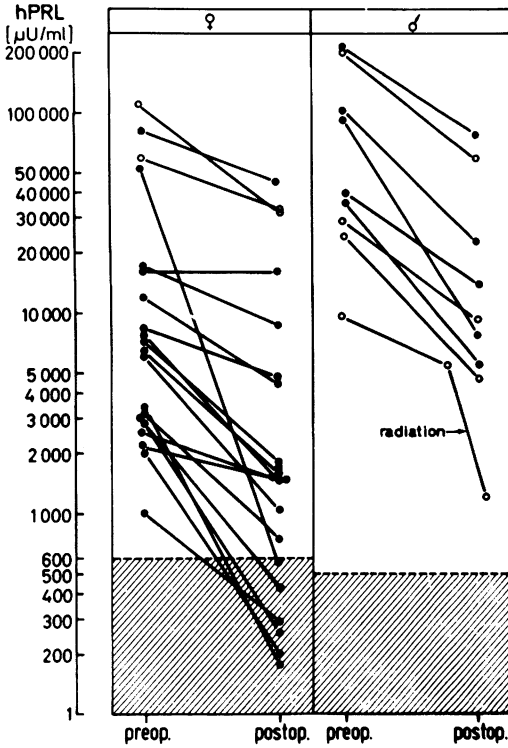


Fig. 2 Fall of hPRL levels in 20 female and 9 male patients after operation

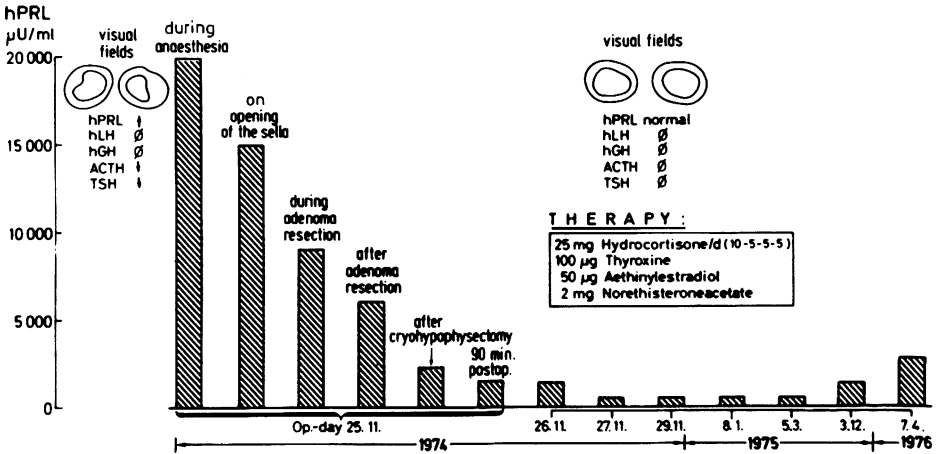


Fig. 3 Intra- and postoperative PRL levels in a patient with a large prolactinoma

showed complete anterior pituitary failure and required substitutional therapy. Though in this case a radical ablation of the pituitary had been intended and was performed, a gradual increase of prolactin levels has been observed during recent follow-up investigations, suggesting a recurrence of pituitary tumor growth [11].

Since it has been shown that prolactin levels can be effectively lowered by dopamine agonists [12, 13, 14, 15], we have treated 19 female patients with pituitary tumors with bromocriptine, which was well tolerated by all of the patients. Bromocriptine in daily dosages varying from 3 to 7.5 mg normalized prolactin levels in female patients with pituitary tumors, if the postoperative basal prolactin level did not exceed 10000 $\mu$ U/ml (Fig. 4). Four of these patients became pregnant after bromocriptine administration and had a completely normal pregnancy, delivering healthy babies. In the females with prolactin levels above 10000 $\mu$ U/ml even larger doses of up to 30 and 40mg daily did not lead to normalization of prolactin secretion and subsequent cyclic ovarian function.

A typical example of a patient with a prolactinoma, prolactin levels above 12000 $\mu$ U/ml, visual field defects and partial pituitary insufficiency documented by inadequate responses of hGH, LH and TSH, is given in Fig. 5. Since this patient wanted to become pregnant, in contrast to the patient shown in Fig. 3, a selective adenomectomy was performed, so that after the operation pituitary function could recover or remain intact. Due to residual adenomatous tissue, the basal prolactin levels after operation fluctuated between 4000 and 7000 $\mu$ U/ml. The patient was therefore treated with 7.5 mg bromocriptine per day. After the first menstrual period she became pregnant and delivered a normal child. After an almost normal breast-feeding period she was again treated with bromocriptine and became pregnant again, giving birth to a second child in February 1977.

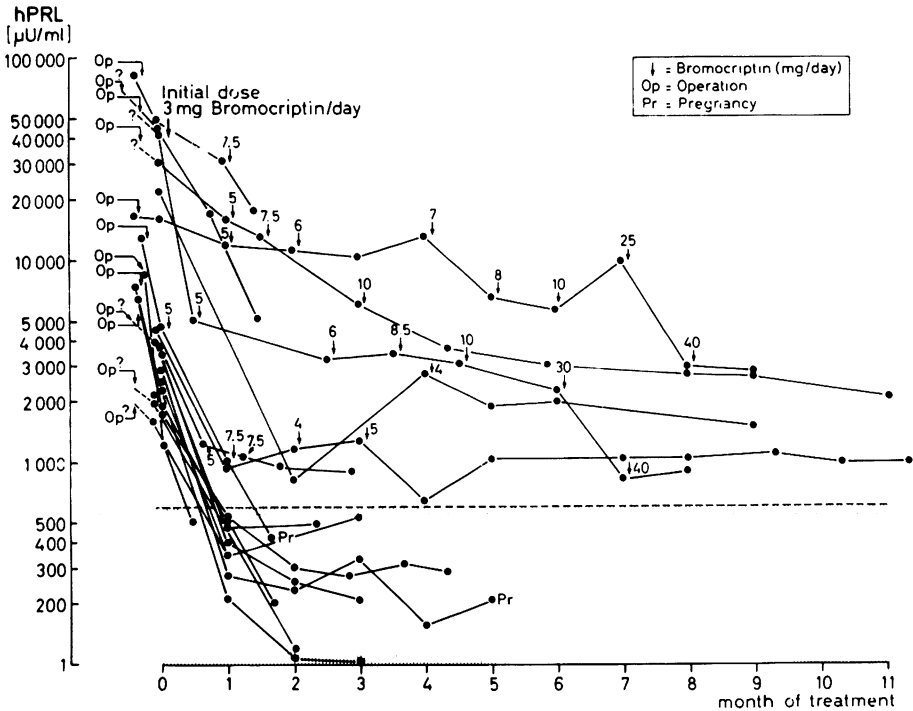


Fig. 4 Effect of long-term treatment with bromocriptine in 19 female patients with prolactinomas

B. T., 32 yrs.

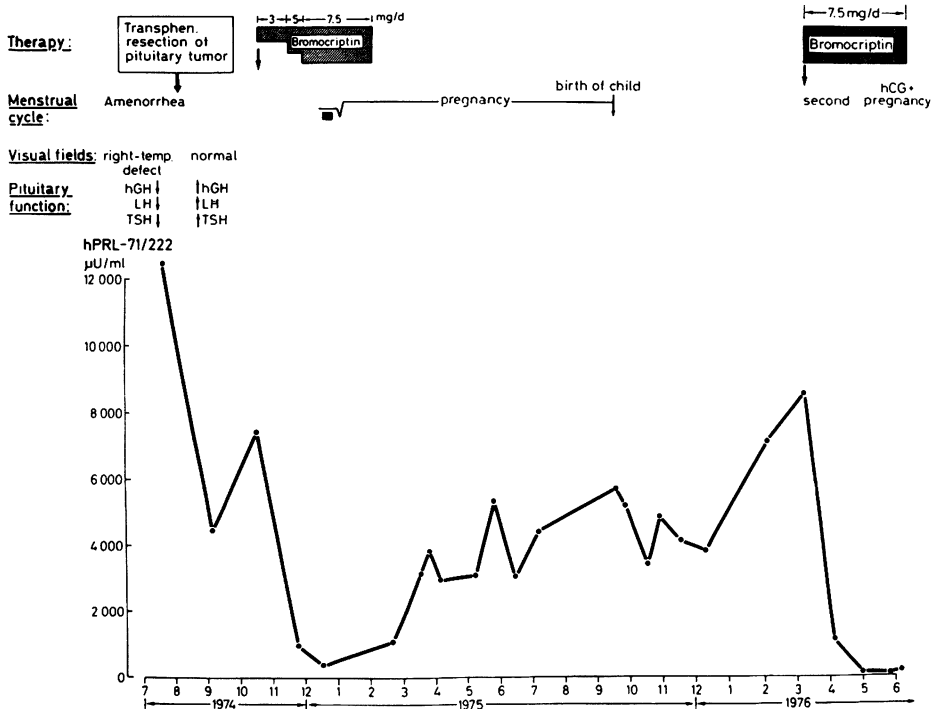


Fig. 5 Pregnancy after partial adenectomy in a patient with a prolactinoma. Normal hPRL levels were obtained only after therapy with bromocriptine

A similar case is shown in Fig. 6. After surgical resection of the pituitary adenoma without destroying residual pituitary function, the still elevated prolactin levels could be completely normalized by bromocriptine administration, leading to disappearance of the galactorrhea and normal menstrual cycles. After discontinuing the administration of bromocriptine, which had been given only for a short period, prolactin levels increased again to the initial values and galactorrhea and amenorrhea recommenced.

In cases where prolactin levels were only moderately elevated, in patients who wanted to become pregnant and the pituitary tumor was small without any evidence of pituitary dysfunction or suprasellar extension, we treated these patients with bromocriptine alone. Fig. 7 shows the course of treatment in a patient with an asymmetrically growing pituitary tumor without visual field defects and no evidence of anterior pituitary dysfunction. Prolactin levels were  $3000\mu\text{U/ml}$ . After therapy with 3 mg bromocriptine per day the prolactin levels had normalized and she ovulated regularly. She became pregnant and treatment with bromocriptine was stopped after which the prolactin levels rose again during pregnancy up  $18000\mu\text{U/ml}$ . The patient delivered a normal child and since her prolactin levels did not fall to pretreatment levels and she suffered from heavy galactorrhea she was then operated upon by the transsphenoidal route.

D. P., 27 yrs.

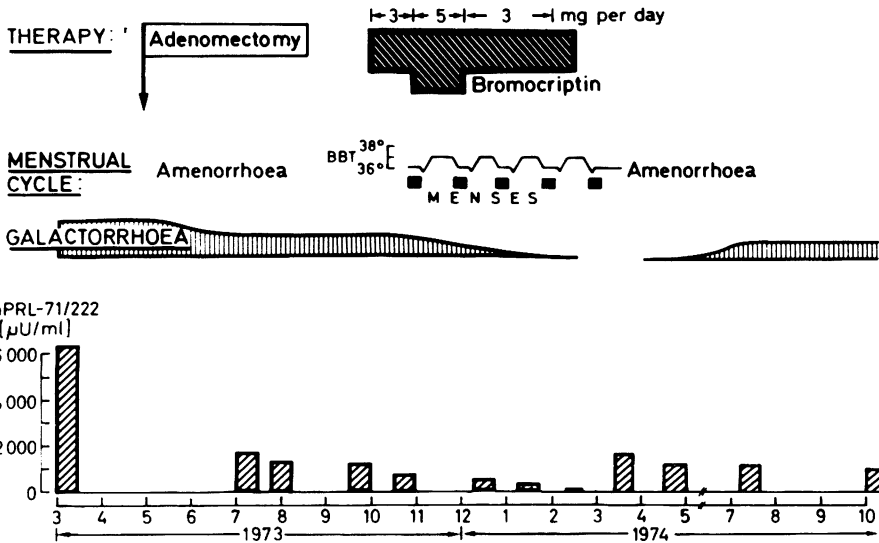


Fig. 6 Normal ovarian function after partial adenomectomy and subsequent bromocriptine therapy in a patient with amenorrhoea/galactorrhoea and pituitary tumor

B. P., 24 yrs.

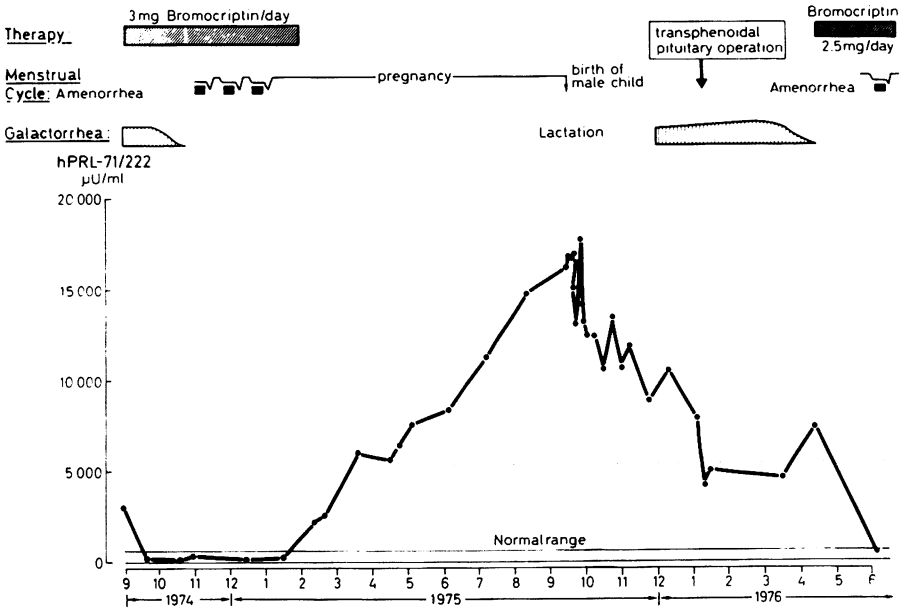


Fig. 7 Pregnancy after bromocriptine therapy alone in a prolactinoma patient. Since hPRL levels remained elevated compared to pretreatment levels she was operated upon after delivery before bromocriptine was started again

The operation was again not a radical one, because a second pregnancy was desired. Therefore her prolactin levels did not drop to normal again necessitating bromocriptine therapy which led to regular menses.

There are two reasons why the indication for bromocriptine therapy is not confined to females: the first reason for trying to normalize prolactin levels in male patients is that, in contrast to former beliefs, hyperprolactinemia exerts biological effects also in the male [3, 5, 12, 16]. Thus it is a well established clinical finding that male patients with high prolactin levels suffer from lack of libido in the presence of normal testosterone secretion or, respectively, adequate testosterone substitutional therapy [3, 5]. Since prolactin has a diabetogenic effect, a deterioration of the glucose tolerance may also be observed [16].

We treated 14 male patients who all had elevated prolactin levels postoperatively and complained of headaches, depression and, particularly, loss of libido and impotence in the presence of adequate testosterone substitution with bromocriptine (Fig. 8). In 7 patients the prolactin levels were normalized by bromocriptine whereas they remained elevated, though considerably lowered, in the other 7 patients. The fall in prolactin levels was in general accompanied by clinical improvement and a feeling of well-being. In contrast to the findings in females, prolactin levels above  $10000\mu\text{U/ml}$  in males could be normalized by bromocriptine; this may be due to the lack of estrogens with their permissive action on prolactin secretion [17]. This is also demonstrated by a male patient who had been operated upon by the transphenoidal route because of a pituitary prolactinoma which was previously thought to be hormonally inactive (Fig. 9). Postoperatively he still showed prolactin levels of more than  $12000\mu\text{U/ml}$ . He suffered from lack of libido and sexual impotence though there was no evidence of pituitary dysfunction and peripheral testosterone levels were in the normal range. He was treated with bromocriptine and on the relatively small dose of 3 mg per day prolactin secretion normalized and sexual potency as well as libido and fertility returned to normal (Fig. 9).

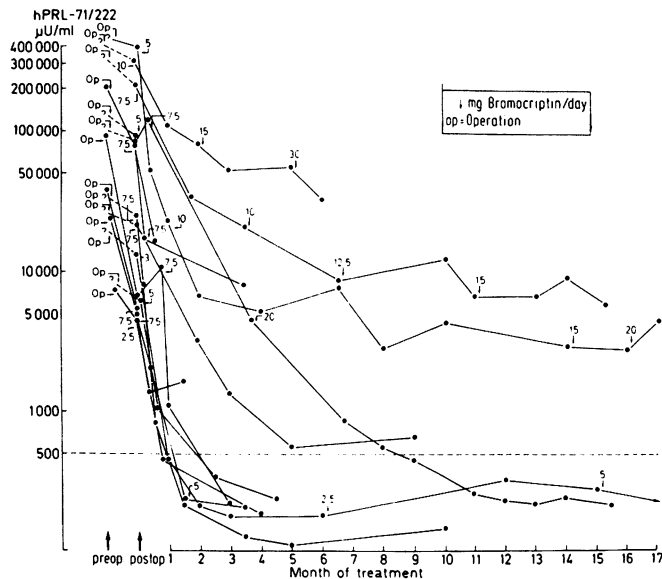


Fig. 8 Effect of long-term treatment with bromocriptine in 14 male patients after operation of a prolactinoma

W.A., ♂, 33 yrs.

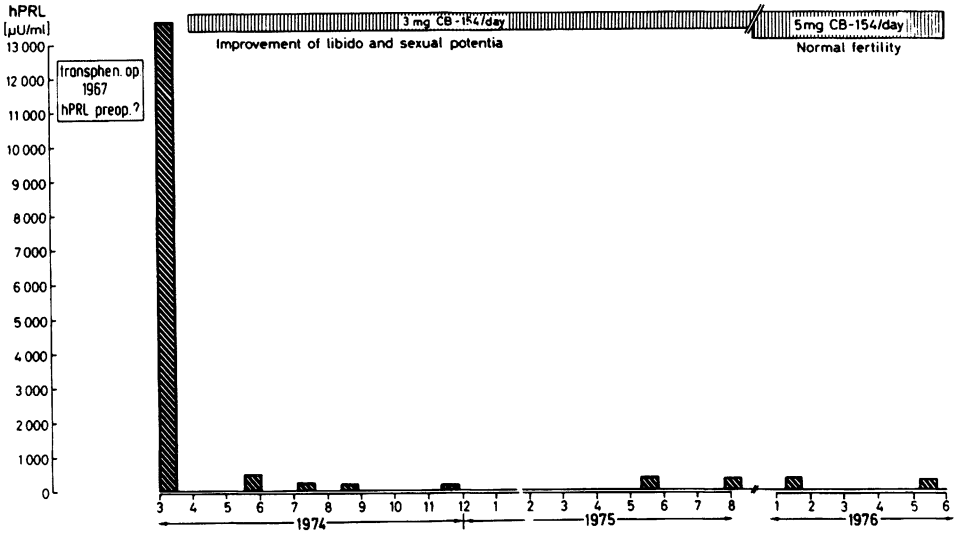


Fig. 9 Postoperative treatment with bromocriptine in a patient with remaining hyperprolactinemia and disturbance of libido and sexual potency

The other reason for treatment with bromocriptine in males and females with prolactinomas and postoperatively persisting hyperprolactinemia is evidence accumulated recently that this drug has an antiproliferative effect on lactotrophic pituitary tumor growth [18, 19].

Four patients with pituitary tumors and elevated prolactin levels were treated for 5 to 20 months with bromocriptine in dosages ranging from 5 to 40mg per day (Table 1).

Table 1 PRL Levels (µU/ml) in 4 Female Patients with Pituitary Tumors after Discontinuation of Long-term Treatment with Bromocriptine

Patient	hPRL before therapy	hPRL after discontinuation of therapy	Duration of treatment (months)	Dosage of bromocriptine (mg/day)	Time period without bromocriptine (months)
A.L.	49340	12982	12	12.5	1
J.H.	41910	15655	5	40	8
S.L.	16680	10578	13	40	11
G.G.	5237	3100	20	5	2

Bromocriptine therapy was then stopped for a period of 1 to 11 months, after which the prolactin levels were still found to be significantly lower than pretreatment levels, suggesting the antiproliferative effect mentioned above. Further evidence has been provided by a male patient with excessive hyperprolactinemia after two transfrontal and two transsphenoidal operations (Fig. 10). His prolactin levels were extremely

H. Q., ♂, 35 yrs.

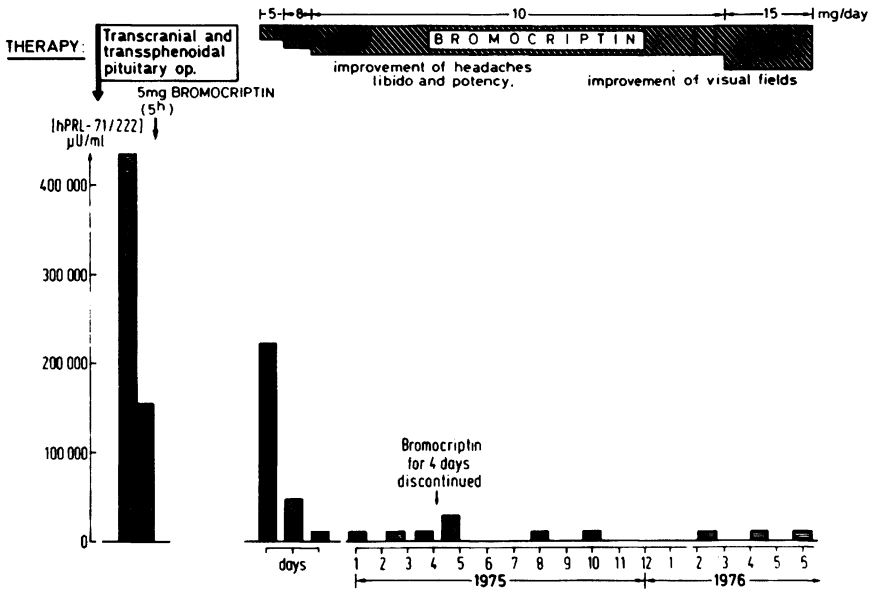


Fig. 10 Improvement of visual fields defects, headaches, lack of libido and sexual impotence in a patient with a prolactinoma after administration of bromocriptine

elevated —  $400000\mu\text{U}/\text{ml}$ , which is equivalent to  $20\mu\text{g}$  of hormone protein per ml. This patient who is now suffering from complete panhypopituitarism due to his invasively growing and inoperable prolactin-producing tumor, complained mainly of headaches, depressions, lack of libido and sexual impotence. He also had impaired visual fields. Under chronic bromocriptine therapy he feels subjectively better and the prolactin levels have fallen from  $400000$  to less than  $5000\mu\text{U}/\text{ml}$ . There is no evidence for progression of tumor growth; on the contrary, the perimetry demonstrates improvement of his visual field which suggests actual shrinking of the pituitary tumor (Fig. 10).

That prolactin levels correlate to tumor size has been mentioned before [6]. That prolactin levels correlate in individual patients also with tumor growth is documented by a patient with galactorrhea, amenorrhea and a pituitary tumor who was operated upon by the transfrontal and the transsphenoidal route because of impairment of visual fields (Fig. 11). When, after two operations, this patient was first admitted to our hospital the prolactin levels were still elevated. During follow-up examinations, deterioration of visual fields was observed due to tumor growth, accompanied by a sharp rise of basal prolactin. The patient was inoperable because of severe congestive heart failure and therefore received radiation therapy after which the prolactin levels fell and a slight improvement of her visual field was noted. She was then put on bromocriptine which led to a prompt normalization of prolactin secretion; her visual fields have remained improved.

Bromocriptine has been shown to inhibit growth-hormone secretion in patients with acromegaly [20, 21, 22, 23]. That bromocriptine may be helpful in patients with hypersecretion of hGH and hPRL has been demonstrated in the case illustrated in Fig 12.



A.R., ♀, 64 yrs..

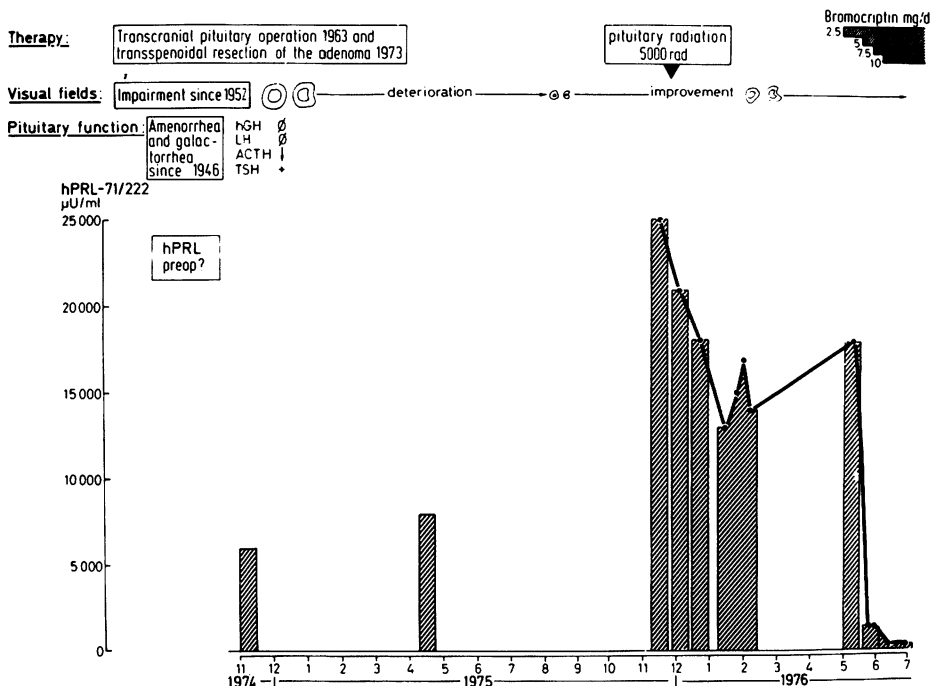


Fig. 11 Correlation of prolactin levels and pituitary tumor growth as evidenced by increasing visual field defects

This history of this unfortunate acromegalic lady demonstrates quite clearly the problems we sometimes face on managing patients with endocrine-active pituitary tumors. She was first operated on in 1969 by the transfrontal route in an outside institution. Preoperative growth-hormone and prolactin levels were not known. The indication for operation was the clinical picture of acromegaly. Because of suprasellar extension of the pituitary tumor leading to visual field disturbances she was operated on again by transfrontal approach; this operation did not lower her growth-hormone levels at all, though in 1974 when she appeared for follow-up examination her growth-hormone level was 20ng/ml and her prolactin level 10000μU/ml, demonstrating that she suffered from hypersecretion of both hGH and hPRL. Because of rapid deterioration of the visual function of her left eye, she came to our hospital again and was operated on a third time, this time by the transphenoidal route. Again there was no significant effect on growth-hormone and prolactin levels which were still very high. By computer tomography it could be demonstrated that there was pre- and suprasellar tumor growth leading to complete blindness of her left eye. Therefore we put her on bromocriptine therapy which effectively lowered growth-hormone levels and even more effectively prolactin levels. We regarded this as particularly important since in the meantime breast cancer had developed in this patient which had to be treated surgically. The connection between the occurrence of breast cancer and hypersecretion of two lactotrophic hormones is still an object of speculation [24]. In this case we think that, in

I. B., ♀, 40 yrs.

VISUAL FIELD: normal ⊙ ⊙ ⊙ ⊙ ⊙ ⊙ left eye blind

PITUITARY TUMOR: INTRASELLAR SUPRASELLAR PRE-AND SUPRASELLAR

PITUITARY FUNCTION: normal ACTH ↓ LH ↓ TSH ↓ PANHYPOPITUITARISM

THERAPY: 1 2 TRANSFRONTAL OPERATION 3 TRANSSPHENOIDAL OPERATION OPERATION FOR BREAST CANCER +5+7.5+10+12.5+15+20+30+40 mg/day Bromocriptine

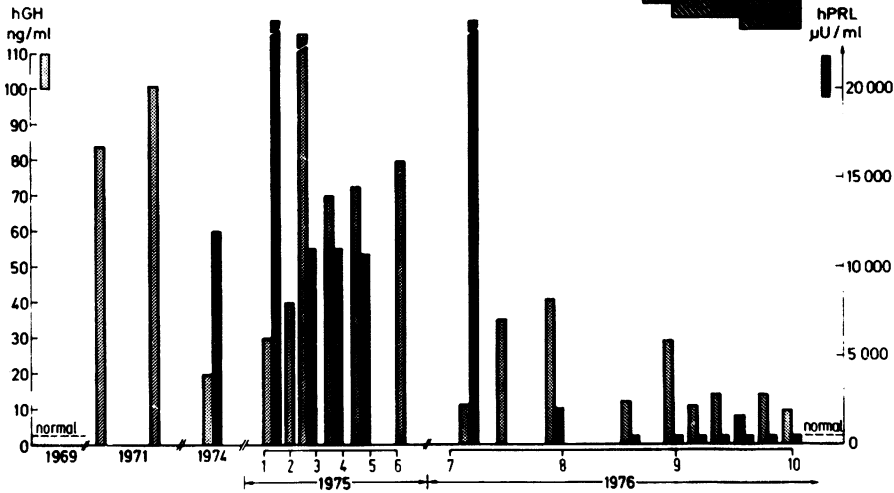


Fig. 12 Effect of multiple surgical interventions and bromocriptine treatment on hPRL and hGH levels in a patient with acromegaly and hyperprolactinemia

addition to bromocriptine therapy, radiation of the tumor will be necessary when she has recovered from the mastectomy.

That bromocriptine can inhibit two hormones secreted by pituitary tumor has also been shown in a case recently reported by Horn et al. [25], where treatment with bromocriptine led to lowering of TSH and prolactin levels in a patient with a TSH- and prolactin-producing pituitary tumor.

**Final Conclusions**

From the findings in our 45 female and 22 male patients with pituitary tumors we can draw the following conclusions:

1. Hyperprolactinemia associated with pituitary tumor can be treated surgically, medically and by radiation.
2. All patients with visual field defects or signs of impairment of pituitary function should be operated. If operation is impossible, pituitary radiation is an alternative. If prolactin levels are not normalized after operation or radiation, particularly in cases where these patients suffer from depression, lack of libido or impotence despite adequate testosterone levels, treatment with bromocriptine is indicated.
3. In females with prolactin levels above 5000 μU/ml who want to become pregnant, a gentle neurosurgical procedure should induce normalization or lowering of prolactin secretion without disturbing gonadotropic function, so that postoperative bromocriptine therapy can lead to normal ovulatory cycles.

4. In patients with small pituitary tumors and hyperprolactinemia who do not show any evidence of pituitary insufficiency or visual field defects, treatment by bromocriptine alone is indicated. In case of pregnancy these patients have to be monitored very carefully since the enhanced estrogen production during pregnancy can activate pituitary tumor growth.
5. Patients with endocrine-active pituitary adenomas secreting two different hormones seem to be responsive to bromocriptine therapy which leads to the abolition of both hormone excesses.
6. There is good evidence that bromocriptine exerts an antiproliferative effect on pituitary tumor growth. It remains to be seen whether consistent postoperative treatment with bromocriptine can prevent recurrence of pituitary tumor growth in every patient.

References

- 1 Hwang, P., H. Guyda, H. Friesen: A radioimmunoassay for human prolactin. *Proc. Nat.Acad.Sci. USA* 68:1902, 1971
- 2 Sinha, Y.N., F.W. Selby, U.J. Lewis, W.P. Vanderlaan: A homologous radioimmunoassay for human prolactin. *J.Clin. Endocr.* 36:509, 1973
- 3 von Werder, K.: Wachstumshormone and Prolaktinsekretion des Menschen. Urban & Schwarzenberg, München-Berlin-Wien, 1975
- 4 Rjosk, H.K., K. von Werder, R. Fahlbusch: Hyperprolaktinämische Amenorrhoe. Klinische Bedeutung, endokrine Befunde, Therapie. *Geburtsh.Frauenheilk.* 36:575, 1976
- 5 Thorner, M.O., A.S. McNeilly, C. Hagan, G.M. Besser: Long-term treatment of galactorrhea and hypogonadism with bromocriptine. *Brit.Med.J.* 2:419, 1974
- 6 Fahlbusch, R., H.K. Rjosk, K. von Werder: Operative treatment of prolactin-producing adenomas. This volume, p. 225
- 7 von Werder, K., F. Fahlbusch, R. Landgraf, H.K. Rjosk: Differential therapy of hyperprolactinemia associated with pituitary tumors. *V. Internat. Congr.Endocr., Hamburg 1976*, Abstract 101
- 8 Cotes, P.M.: Research standard A for human prolactin (in ampoules coded 71/222). In: *Human prolactin*, ed. by J.L. Pasteels, C. Robyn. *Excerpta medica*, Amsterdam, 1973
- 9 von Werder, K., C. Clemm, W. Kerner, P.C. Scriba: A hPRL-RIA using antibodies against the "little" component of serum-hPRL. *Endocrinology Suppl.* 96:358, 1975
- 10 Guiot, G.: Indications for transcranial and transphenoidal operation. This volume, p. 202
- 11 Fahlbusch, R., H.K. Rjosk, K. von Werder: Perioperative prolactin levels in patients with prolactinomas. *Acta endocr. (Kbh.) Suppl.* 208:46, 1977
- 12 Forsyth, I.A., C.R.W. Edwards: Human prolactin: Its isolation, assay and clinical applications. *Clin.Endocr.* 1:293, 1972
- 13 Del Pozo, E., H. Friesen, P. Burmeister: Endocrine profile of a specific prolactin inhibitor: Br-ergocryptine (CB 154). *Schweiz.med.Wschr.* 103:847, 1973
- 14 Del Pozo, E., L. Varga, H. Wyss, G. Tolis, H. Friesen, R. Wenner, L. Vetter, A. Uettwiler: Clinical and hormonal response to bromocriptin (CB 154) in the galactorrhea syndromes. *J.Clin.Endocr.* 39:18, 1974
- 15 Del Pozo, E., R. Brun del Re, L. Varga, H. Friesen: Inhibition of prolactin secretion in man by CB 154 (2-Br-alpha-ergocryptine). *J.Clin.Endocr.* 35:768, 1972
- 16 Landgraf, R., M.M.C. Landgraf-Leurs, A. Weissmann, R. Hörl, K. von Werder, P.C. Scriba: Prolactin: A diabetogenic hormone. *Diabetologia.* 13:1, 1977
- 17 Frantz, A.G.: The regulation of prolactin secretion in humans. In: *Frontiers in Neuroendocrinology 1973*, ed. by W.F. Ganong, L. Martini. *Oxford Univ.Press*, London, Toronto 1973
- 18 Besser, G.M., M. Thorner, J.A.H. Wass: Amenorrhoe-galactorrhea; medical treatment. *V. Internat.Congr.Endocrinology, Hamburg 1976*, *Excerpta Medica*, in press
- 19 Friesen, H.: Lactogenic hormones. *V. Internat.Congr.Endocrinology, Hamburg 1976*. *Excerpta medica*, Amsterdam, Oxford, 1977
- 20 Chiodini, P.G., A. Liuzzi, L. Botalla, G. Oppizzi: Stable reduction of plasma growth hormone (hGH) levels during chronic administration of 2-brom-alpha-ergocriptine (CB-154) in agromegalic patients. *J.clin. Endocr.* 40:705, 1975
- 21 Liuzzi, A., P.G. Chiodini, L. Botalla, G. Cremascoli, E.E. Müller, F. Silvestrini: Decreased plasma growth hormone (GH)