

Official Organ of the Anatomische Gesellschaft

ANNALS OF ANATOMY

ANATOMISCHER ANZEIGER

Managing Editor:

W. Kühnel, Lübeck

Editors:

D. Drenckhahn, Würzburg

J. Fanghänel, Greifswald

Ch. Heym, Heidelberg

A. F. Holstein, Hamburg

W. Linß, Jena

W. Platzer, Innsbruck

B. Tillmann, Kiel

K. Unsicker, Heidelberg

L. Vollrath, Mainz

K. Zilles, Düsseldorf

E. van der Zypen, Bern



**GUSTAV
FISCHER**
JENA · STUTT GART · NEW YORK

**Volume 174
1992**

Contents

Editorial (W. Kühnel)	1
In memory	
In memoriam Edward C. Roosen-Runge (F. Holstein)	3
In memoriam: Prof. Dr. med. Otto Bucher (1913–1991) (R. Krstić, T. Pexieder)	271
In memoriam des Anatomen und Embryologen Erich Blechschmidt (1904–1992) (K. Hinrichsen)	479
Original articles	
Akita, K.: An anatomical investigation of the muscles of the pelvic outlet in Iguanas (Iguanidae <i>Iguana iguana</i>) and Varanus (Varanidae <i>Varanus (dumerillii)</i>) with special reference to their nerve supply	119
Akita, K.: An anatomical investigation of the muscles of the pelvic outlet in Japanese salamander (Cryptobranchidae <i>Megalobatrachus japonicus</i>) with special reference to their nerve supply	235
Anderhuber, F., Weiglein, A.: Zur Nomenklatur der Nierengefäße	229
Baljet, B., Heyke, G. C. M.: Zur Geschichte der Klassifikationssysteme der Doppelmißbildungen unter besonderer Berücksichtigung des Klassifikationssystems von Louis Bolk (1866–1930)	361
Barberini, F., Vizza, E., Montanino, M., Marcoccia, S., Montanino, G.: Vaginal reconstruction by skin grafts: A scanning electron microscopic evaluation	517
Beier, H. M.: Die molekulare Biologie der Befruchtungskaskade und der beginnenden Embryonalentwicklung	491
Bergmann, R. A., Cassell, M. D., Sahinoglu, K., Heidger, P. M. Jr.: Human doubled renal and testicular arteries	313
Bopp, S., El-Hifnawi, El-S., Laqua, H.: Lectin binding pattern in human retinal pigment epithelium	279
Brenner, E.: Die laterale Gelenkfläche des Os cuneiforme mediale für das Os cuneiforme intermedium	223
Bryk, S. G., Orlandini, S. Z., Gheri, G., Sgambati, E.: Development of the chick tongue. A scanning electron microscopical investigation	531
Christ, B., Wilting, J.: From somites to vertebral column	23
Clemen, G., Opolka, A.: Ultrastructure and histochemical aspects of the oropharyngeal epithelium of Siren intermedia Le Conte	535
Csillik, B.: Anatomie in Ungarn und die Anatomische Gesellschaft	19
Csillik, B., Knyihár-Csillik, E.: Structural and molecular plasticity in the dorsal horn: A genuine model for neuronal and synaptic group selection	76
El-Hifnawi, E., Kühnel, W., Orün, C., Haug, H., Laqua, H.: Die Wirkung von Cyclooxygenasehemmern auf den Verlauf der hereditären Netzhautdystrophie bei RCS-Ratten	251
Fritsch, H.: The connective tissue sheath of uterus and vagina in the human female fetus	261
Frotscher, M.: Specificity of interneuronal connections	377
Fujii, K., Kobayashi, H.: FMRamide-like immunoreactivity in the brain and pituitary of the goldfish, <i>Carassius auratus</i>	217
Geiger, R., Störmer, R., Hummel, G., Goller, H.: Zur Feinstruktur der Raphekerne von Schaf und Ziege	327
Gilani, S., Persaud, T. V. N.: Embryonic development in the chick following exposure to ethanol, acetaldehyde and cyanamide	305
Hansmann, I., Pabst, B.: Nondisjunction by failures in the molecular control of oocyte maturation	485
Hess, E., Elmagd, A. A.: Eine seltene Variation im Bereich der Arteria carotis	317
Inoue, N., Sakai, H., Margari, S., Sakanaka, M.: Distribution and possible origins of substance P-containing nerve fibers in the rat liver	557
Isotupa, K. P., Carlson, D. S., Mäkinen, K. K.: Influence of asymmetric occlusal relationships and decreased maxillary width on the growth of the facial skeleton in the guinea pig	447

Isotupa K. P., Mäkinen, K. K., Carlson, D. S.: Proteinase, phosphatase and glucuronidase activities in the growing mandible and temporomandibular joint of the guinea pig	441
Iwahori, N., Nakamura, K., Mameya, C.: Differentiation of the brain stem structures in the Salamander, <i>Hynobius nebulosus</i>	461
Iwasaki, S.-I.: Fine structure of the dorsal lingual epithelium of the domestic, newborn kitten, <i>Felis catus</i>	293
Iwasaki, S.-I.: Fine structure of the dorsal lingual epithelium of the crab-eating monkey, <i>Macaca irus</i>	523
Kitamura, S., Nagase, Y., Nishiguchi, T., Shigenaga, Y.: An HRP study of the location of the motoneurons supplying the tensor veli palatini muscle of the rabbit	353
Kogerman-Lepp, E.: August Rauber	6
Krammer, H.-J., Kühnel, W.: Immunohistochemistry for intermediate filaments in the enteric nervous system of the porcine small intestine	275
Krause, W. J., Sherman, D. M.: Immunohistochemical localization of relaxin in the reproductive system of the female opossum (<i>Didelphis virginiana</i>)	341
Kummer, B.: Biomechanische Probleme der aufrechten Haltung	33
Kummer, W.: Neuronal specificity and plasticity in the autonomic nervous system	409
Lavelle, C. L. B.: A preliminary study of craniofacial classification	561
Lolova, I., Davidoff, M.: Age-related changes in cholinergic and noradrenergic transmission in the rat cerebellum. A histochemical and immunocytochemical study	453
Luque, E., Pena, J., Alonso, P. J., Jimena, I.: Microvascular pattern during growth of regenerating muscle fibers in the rat	245
Mendoza, A. S., Krishna, A., Endler, J., Kühnel, W.: Die Regio olfactoria der Fledermaus <i>Scotophilus heathi</i> . Licht- und elektronenmikroskopische Studien	207
Müller, W., Firsching, R.: Differentiation of oxytalan fibres with reagents for detection of magnesium	357
Müller-Gerbl, M.: Die Rolle der Wirbelgelenke für die Kinematik der Bewegungselemente	48
Nägerl, H., Kubein-Meesenburg, D., Fanghänel, J.: Elements of a general theory of joints. 7. Mechanical structures of the relative motion of adjacent vertebrae	66
Neiss, W. F., Lichius, O. G., Angelov, D. N., Gunkel, A., Stennert, E.: The hypoglossal-facial anastomosis as model of neuronal plasticity in the rat	419
Ocal, M. K., Ozer, M.: The circulus arteriosus cerebri in the guinea pig	259
Persaud, T. V. N., Sam, G. O.: Prenatal influence of alcohol following a single exposure in two inbred strains of mice	301
Plishka, J., Bardack, D.: Bending strength of upper canine tooth in domestic dogs	321
Putz, R.: The detailed functional anatomy of the ligaments of the vertebral column	40
Quacci, D., Dell'Orbo, C., Diaz, G.: Collagen fibril ultrastructure alters after glycanolytic digestion	569
Reimann, R., Lax, S.: Recessus und Bursae synoviales an den Lumbosakralgelenken	201
Roberts, W. H.: Anomalous course of the median nerve medial to the trochlea and anterior to the medial epicondyle of the humerus	309
Schulze, C.: Interaktionen zwischen Leydigzellen – peritubulären Zellen – Sertolizellen und ihre Bedeutung für die Steuerung der Spermatogenese	509
Sottovia-Filho, D., Taga, R.: Ultrastructure of the exocrine pancreas in the snake <i>Waglerophis merremii</i> (Wagler)	345
Spanel-Borowski, K., Kuhri, P., Kühnel, W.: Endothelial cell helix in small arterioles of human ureters. A study by scanning electron microscopy (SEM)	213
Sturrock, R. R.: Stability of neuron number in the lateral part of the nucleus of the solitary tract in the ageing mouse brain	335
Sturrock, R. R.: Stability of neuron number in the ageing mouse paraventricular nucleus	337
Szabó, K., Horváth, S., Csányi, K., Palkovits, M.: Vascular ontogeny of the septal region in rats	467
Teofilovski, G., Filipovic, B., Bogdanovic, D., Trpinac, D., Rankovic, A., Stankovic, G., DiDio, L. J. A.: Myocardial bridges over coronary arteries in <i>Cercopithecus</i>	435
Thiel, W.: Die Konservierung ganzer Leichen in natürlichen Farben	185
Thiel, W.: Eine Arterienmasse zur Nachinjektion bei der Konservierung ganzer Leichen	197

Unsicker, K., Engels, S., Hamm, C., Lüdecke, G., Meier, C., Renzing, J., Terbrack, H.G., Flanders, K.: Molecular control of neural plasticity by the multifunctional growth factor families of the FGFs and TGF- β s	405
Vasconcellos, H. A. de, Prates, J. C., Belo de Moraes, L. G.: A study of human foot length growth in the early fetal period	473
Wassilev, W., Kühnel, W.: Struktur und Funktion der Zwischenwirbelscheibe	54
Weihe, E.: Neurochemical anatomy of mammalian spinal cord. Functional implica- tions	89
Wiltling, J., Christ, B.: A morphological study of the rabbit corneal assay	549
Wolff, J. R., Missler, M.: Synaptic reorganization in developing and adult nervous systems	393
Zidorn, T., Tillmann, B.: Morphological variants of the suprapatellar bursa	287
Zilles, K.: Neuronal plasticity as an adaptive property of the central nervous system	383

Conferences

Heym, Christine: Grußworte zur 87. Versammlung der Anatomischen Gesellschaft in Mainz, 23. bis 26. März 1992	369
Heym, Christine: Eröffnungsrede	371
Orlandini, G., Göncz, A., Surján, L., Lipai, P., Szilárd: Grußworte zur 86. Versammlung der Anatomischen Gesellschaft zusammen mit dem 7. Kongreß der Ungarischen Gesellschaft der Anatomen, Histologen und Embryologen, Szeged, 2. bis 5. April 1991	11
Orlandini, G.: Eröffnungsrede	15
Kühnel, W.: Kurzfassungen (Abstracts) der Beiträge der 9. Arbeitstagung der Anatomischen Gesellschaft in Würzburg vom 2. bis 4. Oktober 1991	130

Laudations

Prof. Hans Frick zum 70. Geburtstag (R. Putz)	86
Professor Klaus V. Hinrichsen zum 65. Geburtstag (B. Christ)	269
Andreas Oksche. In honor of his 65th birthday (K. Unsicker)	85
Professor Karlheinz Rosenbauer zum 65. Geburtstag (K. Zilles, H.-G. Hartwig)	477
Information	184, 267, 352, 475, 575
Buchbesprechungen	212, 228, 244, 250, 286, 304, 312, 316, 320, 334, 392, 404, 408, 418, 434, 452, 516, 530, 568

Indexed in CURRENT CONTENTS

Alle Rechte vorbehalten
Printed in Germany

Anat. 36
Titelband

Official Organ of the Anatomische Gesellschaft

ANNALS OF ANATOMY

ANATOMISCHER ANZEIGER

Managing Editor:
W. Kühnel, Lübeck

Editors:

- D. Drenckhahn, Würzburg
- J. Fanghänel, Greifswald
- Ch. Heym, Heidelberg
- A.F. Holstein, Hamburg
- W. Linß, Jena
- W. Platzer, Innsbruck
- B. Tillmann, Kiel
- K. Unsicker, Marburg
- L. Vollrath, Mainz
- K. Zilles, Düsseldorf
- E. van der Zypen, Bern

ISSN 0940-9602
Ann. Anat.
Iena 174 (1992) 1
p. 1-88



1

Volume 174
Number 1
February 1992

ANNALS OF ANATOMY

ANATOMISCHER ANZEIGER

Begründet von Karl von Bardeleben (1886)

Annals of Anatomy – Anatomischer Anzeiger – is open to original papers of research in anatomy, and of papers dealing with various aspects of the organization of biological structure, including papers from the field of comparative and experimental cell and tissue research.

Papers may be sent to any of the editors

Managing Editor

Prof. Dr. W. Kühnel: Institut für Anatomie der MUL, Ratzeburger Allee 160, D - W - 2400 Lübeck 1 (Deutschland), FAX: 00 49-(0)4 51-5 00 40 34

Editors

Prof. Dr. D. Drenckhahn: Anatomisches Institut, Koellikerstraße 6, D - W - 8700 Würzburg (Deutschland), FAX: 00 49-(0)9 31-1 59 88

Prof. Dr. J. Fanghänel: Institut für Anatomie, Friedrich-Loeffler-Straße 23 c, D - O - 2200 Greifswald (Deutschland)

Prof. Dr. Ch. Heym: Institut für Anatomie und Zellbiologie, Im Neuenheimer Feld 307, D - W - 6900 Heidelberg (Deutschland), FAX: 00 49-(0)62 21-56 31 11

Prof. Dr. A. F. Holstein: Anatomisches Institut, Martinistraße 52, D - W - 2000 Hamburg 20 (Deutschland), FAX: 00 49-(0)40-4 68 49 66

Prof. Dr. W. Linß: Institut für Anatomie, Teichgraben 7, D - O - 6900 Jena (Deutschland)

Prof. Dr. W. Platzer: Institut für Anatomie, Müllerstraße 59, A-6010 Innsbruck (Österreich), FAX: 0 04 35 12-5 07 23 35

Prof. Dr. B. Tillmann: Anatomisches Institut, Olshausenstraße 40, D - W - 2300 Kiel 1 (Deutschland), FAX: 00 49-(0)4 31-8 80 15 57

Prof. Dr. K. Unsicker: Institut für Anatomie und Zellbiologie, Robert-Koch-Straße 6, D - W - 3550 Marburg/Lahn (Deutschland), FAX: 00 49-(0)64 21-28 57 83

Prof. Dr. L. Vollrath: Anatomisches Institut, Saarstraße 19–21, D - W - 6500 Mainz (Deutschland), FAX: 00 49-(0)61 31-39 37 19

Prof. Dr. K. Zilles: Anatomisches Institut, Moorenstraße 5, D - W - 4000 Düsseldorf 1 (Deutschland), FAX: 00 49-(0)2 21-4 78 40 95

Prof. Dr. E. van der Zypen: Anatomisches Institut, Bühlstraße 26, CH-3012 Bern 9 (Schweiz), FAX: 00 41 31-24 54 49

ANNALS OF ANATOMY ANATOMISCHER ANZEIGER

Contents

Editorial	1
In memoriam Edward C. Roosen-Runge (F. Holstein)	3
Kogerman-Lepp, E.: August Rauber	6
Orlandini, G., Göncz, A., Surján, L., Lipai, P., Szilárd: Grußworte zur 86. Versammlung der Anatomischen Gesellschaft zusammen mit dem 7. Kongreß der Ungarischen Gesellschaft der Anatomen, Histologen und Embryologen	11
Orlandini, G.: Eröffnungsrede	15
Csillik, B.: Anatomie in Ungarn und die Anatomische Gesellschaft	19
Christ, B., and Wilting, J.: From somites to vertebral column	23
Kummer, B.: Biomechanische Probleme der aufrechten Haltung	33
Putz, R.: The detailed functional anatomy of the ligaments of the vertebral column	40
Müller-Gerbl, M.: Die Rolle der Wirbelgelenke für die Kinematik der Bewegungselemente	48
Wassilev, W., und Kühnel, W.: Struktur und Funktion der Zwischenwirbelscheibe	54
Nägerl, H., Kubein-Meesenburg, D., and Fanghänel, J.: Elements of a general theory of joints. 7. Mechanical structures of the relative motion of adjacent vertebrae	66
Csillik, B., and Knyihár-Csillik, E.: Structural and molecular plasticity in the dorsal horn: A genuine model for neuronal and synaptic group selection	76
Andreas Oksche. In honor of his 65th birthday (K. Unsicker)	85
Prof. Hans Frick zum 70. Geburtstag (R. Putz)	86

Indexed in CURRENT CONTENTS

Annals of Anatomy

Publishing house: Gustav Fischer Verlag Jena GmbH, Postfach 176, Villengang 2, D-O-6900 Jena; Telefon (003778) 27332, Telefax (003778) 22638.

Managing editor: Prof. Dr. W. Kühnel, Institut für Anatomie der Medizinischen Universität, Ratzeburger Allee 160, D-O-2400 Lübeck 1.

Type setting, printing, binding: Druck- und Verlagshaus Jena GmbH, Spitzweidenweg 17/19, D-O-6900 Jena.

Advertising sales: Gustav Fischer Verlag Jena GmbH, Anzeigenverwaltung, Frau A. Schütz, Postfach 176, Villengang 2, D-O-6900 Jena; Telefon (003778) 27332, Telefax (003778) 22638.

The price list from January 1st, 1992 is effective at present.

Distribution and subscription agency: Gustav Fischer Verlag Jena GmbH, Zeitschriftenvertrieb, Frau B. Dressler, Postfach 176, Villengang 2, D-O-6900 Jena; Telefon (003778) 27332, Telefax (003778) 22638.
For the USA and Canada only: VCH Publishers, Inc., Distribution Center, 303 N.W. 12th Avenue, Deerfield Beach, FL 33442-1788; Telefon (305) 4285566, Telefax (305) 4288201.

Terms of delivery (1992): 1 volume consisting of 6 issues.

Subscription rate (1992): Within Germany DM 550.-; outside Germany DM 553.- (incl. postage). Single issue price: DM 100.- (plus postage). Preference-price for members of the „Anatomische Gesellschaft“ DM 360.- (plus postage).

Subscription information: Please, send your order to your scientific bookshop, to your hitherto dealer or directly to our publishing house. If not terminated the subscription will be effective until recalled. If no discontinuance is given until October, 31st the delivery of the journal will be continued.

Banking connections: Postgiroamt Leipzig, Konto-Nr. 1492 49-903, BLZ 860 10090; Deutsche Bank, Konto-Nr. 39076 56, BLZ 82070000; Commerzbank AG, Filiale Jena, Konto-Nr. 25811 22, BLZ 82040000.

Copyright: The articles published in this Journal are protected by copyright. All rights are reserved. No part of the Journal may be reproduced in any form without the written permission of the publisher.

Printed in Germany

© Gustav Fischer Verlag Jena GmbH 1992

The detailed functional anatomy of the ligaments of the vertebral column*

Reinhard Putz

Anatomische Anstalt, Ludwig-Maximilians-Universität, Pettenkoferstraße 11,
D - W - 8000 München 2, Deutschland

Introduction

The general acceptance of the term „motion segment“ (Bewegungssegment), introduced by Junghanns (1930, 1977), has influenced both the morphological and functional approach to the vertebral column right up to the present time. It brought about a recognition of the principle of functional segmentation of the anatomy of the column, but concentrated attention on the interdependence of form and function in the motion segment itself.

An oversimplified approach to the concept of functional regions has led, both in anatomical research and clinical practice, to imprecise and inadequate observation of regional variations in the vertebral column. The equally well-established demonstration of „regions of motion“ (Putz 1981) within the vertebral column has still not yet found its way into clinical parlance.

The necessity for continuing the discussion, which has increased with the development of the anatomy of the column to a point beyond that which can be observed with the naked eye, has also been underlined by our insufficient understanding of the pathological mechanisms, and of the related prophylactic measures against chronic diseases of the spinal column and their treatment.

Taking the ligaments as an example, an attempt is made in the following pages to analyse the significance of the single anatomical structures within the motion segment.

Ligaments of the vertebral bodies and intervertebral discs

Anterior longitudinal ligament

At first glance, the anterior longitudinal ligament appears to be a uniform structure covering the entire column ventrally from the anterior atlanto-occipital membrane above to the sacrum below. Closer observation, however, makes it clear that this ligament is particularly well-developed in the lordotic sections of the column. In the region of the thoracic kyphosis it has little substance. Both in thickness and in width, it increases from the lower thoracic vertebrae down to the lumbosacral junction (Fig. 1).

If, however, one realises that the orientation and subchondral mineralisation of the lumbosacral zygaopophyseal joints are the result of their supporting greater pressure (Putz 1990), a meaningful functional interpretation becomes immediately apparent. Obviously the anterior longitudinal ligament receives the considerable tensile stress which axial loading of the column produces in the lumbosacral region, while the shearing stress is taken up by the vertebral joints. Owing to the cushion-like structure of an intact intervertebral disc, the local pressure is equally distributed over the adjacent surface of the vertebral body (Horst 1982) – a fact which is reflected in the layout of the trabecular bone of all vertebral bodies. The end-plates of the vertebral bodies are supported by perpendicular trabeculae, which are themselves anchored by transverse spongy lamellae (Fig. 2). This functional interpretation is confirmed by the finding that the two layers of the ligament are made up of thick bundles of crossed collagen fibres arranged in different ways (Stofft 1966). The superficial layer is firmly attached to each adjacent vertebra, the fibres crossing at an angle of about 20°. This permits only limited extension. The fibres of the deeper layer, on the other hand, are anchored segmentally in

* Referat auf der 86. Versammlung der Anatomischen Gesellschaft in Szeged, Ungarn, 2. bis 5. April 1991
Herrn Prof. Dr. med. Hans Frick zum 70. Geburtstag gewidmet

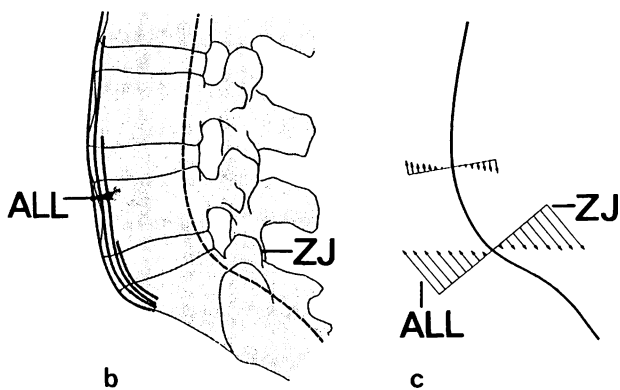
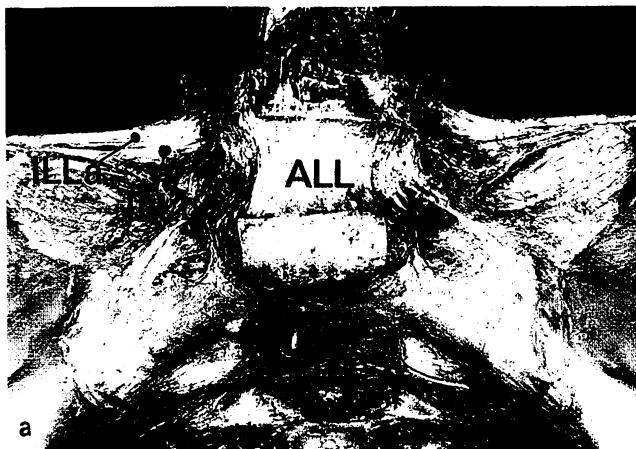

Fig. 1. Anterior longitudinal ligament (ALL) in lumbar and lumbosakral region and iliolumbar ligament (ILL).

a) Specimen viewed from in front. The lateral parts of the anterior longitudinal ligament are removed. The iliolumbar ligament consists of two parts: the superior (ILLa) shows a horizontal orientation, the inferior is orientated parallel to the frontal plane.

b) Schematic lateral representation.

c) Functional interaction between anterior longitudinal ligament and zygapophyseal joints (ZJ).

each anulus fibrosus and meet at angles of up to 80°. The superficial layer may therefore be regarded as a simple bracing system for passively maintaining the lumbar lordosis, whereas the more deeply running fibres, because of their more oblique course, are functionally related to the anuli fibrosi and may be considered as forming ligaments of single segments.

Posterior longitudinal ligament

According to our own detailed investigations (Prestar et al. 1982), the posterior longitudinal ligament is also not a uniform structure. In particular, its attachment is not confined to the posterior part of the circumference of the intervertebral discs.

The posterior longitudinal ligament consists of a superficial layer, the fibres of which extend as a long band from the anterior margin of the foramen magnum down to the inter-

vertebral disc between L3 and L4. There is also a deep layer with fibres consigned to single segments. These fibres are interlaced with the outer region of the anuli fibrosi and are attached to the margins of the vertebral end-plates in a manner which varies from segment to segment (Fig. 3). Behrsin et al. (1988) describe an additional attachment on the posterior surface of the vertebral bodies. The regional differences in the posterior longitudinal ligament are remarkable. Whereas the deeper layer at the level of the middle vertebral bodies is only a few millimetres wide, the superficial layer constitutes the entire anterior wall of the spinal canal in the cervical region, and is fused with the membrana tectoria: the deep layer of the longitudinal component of the cruciate ligament.

Both layers intermingle with those of the anuli fibrosi and extend far out laterally into the intervertebral foramen. In the dissecting room, a clear separation of the posterior longitudinal ligament from the dura mater, and from the connective tissue accompanying the dural extensions into the intervertebral foramina, is often very difficult (Hayashi et al. 1977). The structure typical for the cervical column is characteristically continued downwards as far as T2, or sometimes T3. From there onwards until L3, the superficial layer is reduced to a width of 5 to 10 mm. Greater significance can be attributed to the collagen fibre bundles of the deep layer, of which the medial fibres alone are continued in a longitudinal direction over several segments, the lateral part being properly regarded as made up of monosegmental ligaments.

The firm lateral offshoots of the deep fibres diverge from the level of the middle of a vertebral body downwards the margin of the one below it, and also towards the roots of its pedicles. They therefore provide a large part of the anterior wall of the lateral recesses and the intervertebral foramen (Fig. 3). Whereas the medial fibres are firmly united with the anulus fibrosus, a pocket is built up between the lateral fibres and the intervertebral disc, which at this point is covered by a thin sheet drawn out equally from the ligament and from the anulus.

Below the level of L3, the superficial layer is reduced to a thin ribbon which continues downwards into the sacral canal. The lateral fibre bundles of the deep layer stretch out and become increasingly more flat, reaching well into the intervertebral foramina.

On account of the arrangement of its fibres, the posterior longitudinal ligament should not be regarded as a simple longitudinal bracing system. If it fulfils this function at all, that is only true of the cervical and thoracic regions of the column, and therefore especially in the kyphotic region. The monosegmental, divergent arrangement of the fibres seems on the contrary to be more important, since as a result of this geometrical pattern, an elastic attachment of the disc to the vertebral body immediately above it is achieved. It is possible to demonstrate on a dissected specimen that ventral flexion produces extension of all the fibres, and rotation and lateral flexion tension in the lateral fibres particularly. The oblique direction of the fibres relative to the longitudinal axis makes a slow increase in tension possible in the final stages of all principal movements.

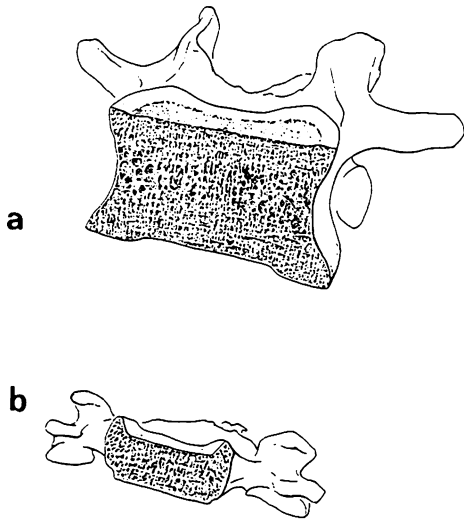


Fig. 2. Architecture of spongy bone within the vertebral body. The trabeculae are orientated perpendicular to the end-plates:
 a) 5th lumbar vertebra
 b) 6th cervical vertebra

both elastin and elaunin fibres can be demonstrated, running among the fine collagen fibres.

Even during relaxation the ligamenta flava of the lumbar vertebrae show a remarkable tension, varying from 1,500 N in young subjects down to 400 N in old people. Chazal et al. (1985) showed it as the most resistant ligament of the spine. Indeed, cutting them across in a fresh specimen, or during an operation, causes the cut ends to fly apart (Grieve 1988).

Whereas the ligamenta flava in the cervical region are relatively thin, they increase both in width and thickness as the caudal regions of the vertebral column are approached. In the lumbar region, they take up the entire interlaminar space and reach from the anterior border of the intervertebral joint to the middle of the intervertebral foramen (Fig. 4). At this point they therefore form the entire posterior wall of the lumbar lateral recesses and the corresponding foramina (Putz 1981). The bracket-like projection of the caudal attachment area is of great clinical significance, since it is precisely this part which often projects forwards right into the lateral recess, and it is here that compression of the nerve roots can arise. The shape of the lumbar vertebral foramina in cross-

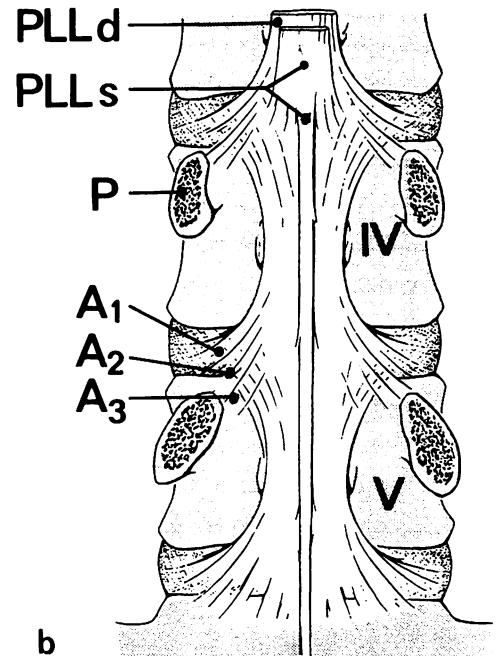
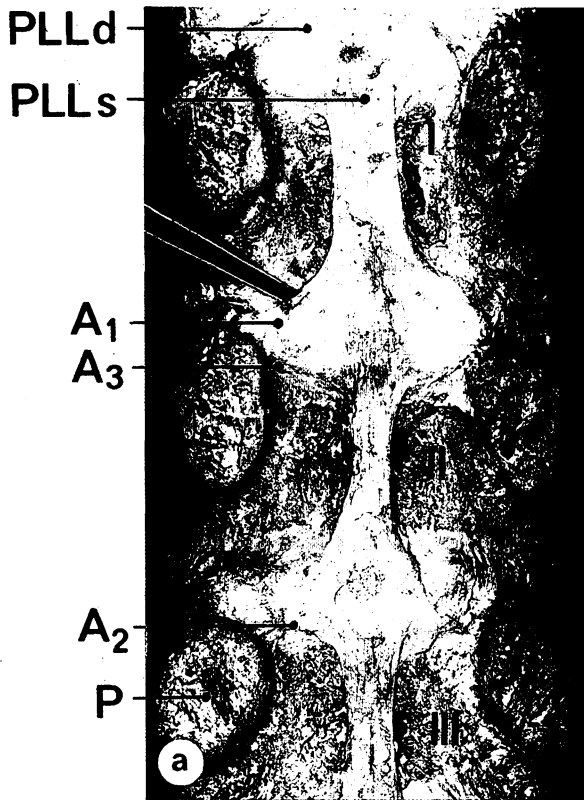


Fig. 3. Posterior longitudinal ligament (PLL) in lumbar region PLLd deep layer, PLLs superficial layer, A1 interlacement with peripheral zone of anulus fibrosus, A2 attachment on upper marginal border of vertebral body, A3 attachment on periosteum of pedicle (P):
 a) specimen viewed from behind,
 b) schematic representation from behind.

Ligaments of the vertebral arch

Ligamenta flava

The yellow ligaments of the vertebral column consist almost entirely of elastic tissue. According to Yahia et al. (1990),

section, which is of diagnostic importance, is brought about in this way.

One observation, the clinical importance of which is not yet established, is the frequently seen calcification or ossification of the attachment area of the ligamenta flava. This is

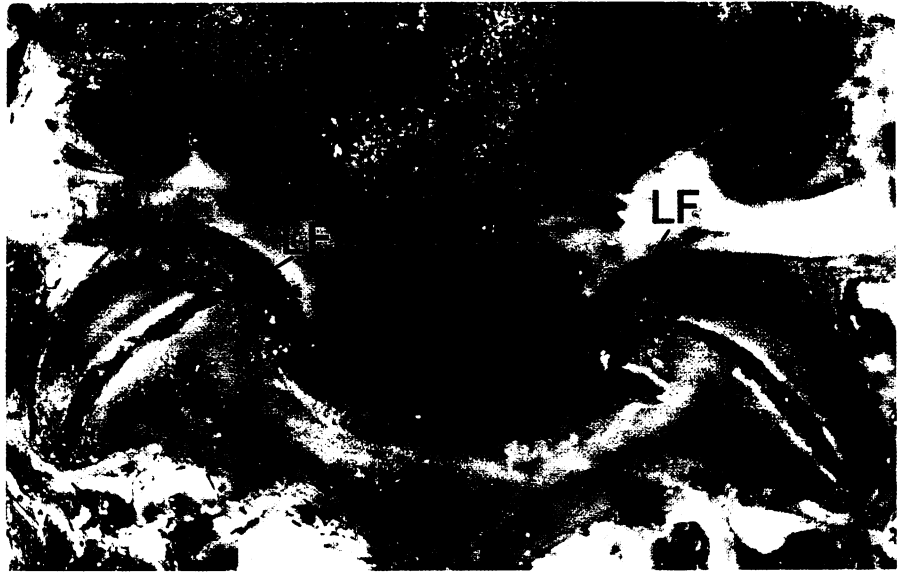

Fig. 4. Ligamentum flavum (dotted line – LF) in lumbar and lumbosakral region. Transverse section at level of middle of intervertebral foramen.

most commonly found in the lower thoracic region (Fig. 5). Biochemical experiments carried out by Sikoryn et al. (1990) have shown that the attachment area of the ligament is far from strong, the breaking strain in the lumbar column being, according to Myklebust et al. (1988), only 200 N. During ventral flexion the ligamenta flava become tense, allowing the erector trunci muscles to relax so much that, during the final stages of the movement, no activity can be detected with EMG.

In close association with the morphology of the ligamentous attachment, the question arises: is the narrowing peculiar to the lumbar lateral recesses due to an independent hypertrophy of the ligamentum flavum, or should it be attributed to changes in the vertebral arch at the point where the lamina merges with the pedicle? The high degree of subchondral mineralisation of the anterior part of the zygapophyseal joints suggests, in our opinion, that the so-called hypertrophy of the ligamenta flava probably occurs because, as a result of ageing or due to loading over a period of time, a kink has appeared in the arch near the superior articular process.

The joint capsule

In contrast to the situation in the rest of the vertebral column, the joints of the lumbar vertebrae are strengthened by a firm transverse sheet of fibres (Fig. 6). Their thickness and structure of strong collagen fibres almost justifies their separate description as „transverse ligaments“ (Putz 1981, 1985a, 1985b). Taking advantage of limited movements in the principal plane, their functional significance has been demonstrated experimentally. These “transverse ligaments” come under tension during rotation to the ipsilateral side, or when an attempt is made to push the vertebra backwards. During flexion (particularly ventral flexion) in the sagittal plane, the tension in them slowly rises as the articular processes undergo parallel displacement from the resting

position. Occasionally the opposite is found with lateral flexion (Fig. 7).

According to Adams (1988) and Panjabi (1982), the increase in tension during the end stages of dorsiflexion – particularly when the interspinous spaces are large – is associated with a significant limitation of movement. On the other hand, Bogduk et al. (1987) see this as limiting rotation.

Near the upper and lower borders of the individual lumbar zygapophyseal joints, this increase in tension is lost, so that here – as well as in the other regions of the vertebral column – the zygapophyseal joints are enclosed only by thin capsules. In the angle between the lower parts of the joint capsule and the ligamenta flava of the lumbar vertebrae a gap normally remains in which distensible connective tissue can move from the inside to the outside of the joint according to the local pressure conditions (Schwarzenberger 1990).

Interspinous ligaments

The ligaments which run between the vertebral spines vary a great deal from region to region (Prestar et al. 1985). In the cervical and upper two-thirds of the thoracic column, their course is directed towards aligning the spinous processes, and they connect and cover the margins of adjacent processes.

The interspinous ligaments of the thoracic vertebral column are made up of the membranes of parallel fibres, which run diagonally as in the cervical column and fill up the space between the spinous processes. Longitudinal bundles of fibres, some 2 to 3 mm thick, are attached dorsally, and in places bind the vertebral spines together. These longitudinal traction fibres consist of both collagen and elastic tissue. In older people, it is not uncommon to find spurs 2 to 3 mm in length in the attachment area on the caudal side of the spinous processes (Prestar et al. 1985). The interspinous spaces of the lower thoracic vertebrae, and those at the

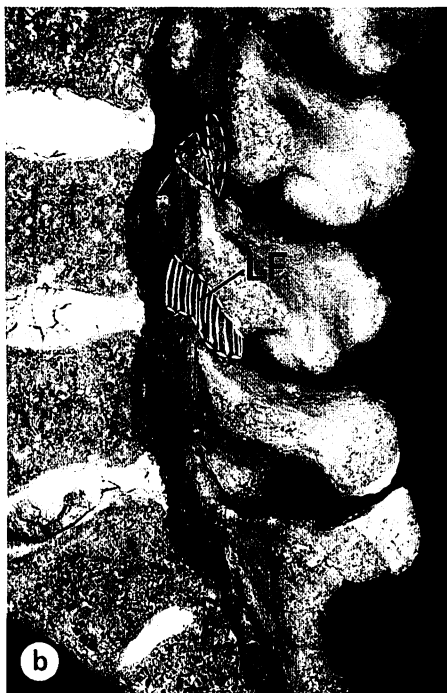
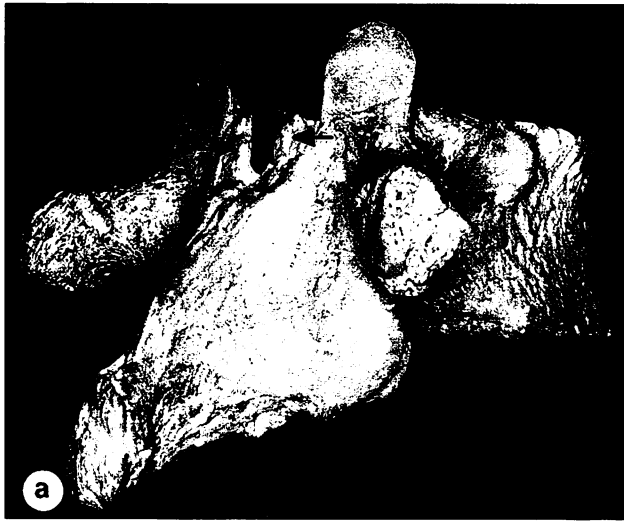


Fig. 5. Attachment areas of ligamenta flava (LF).
 a) Ossification in thoracolumbar transitional zone (arrows).
 b) Bracket-like processes of in lumbar and lumbosakral laminae (arrows). Dotted lines represent the border of attachment zones of ligamentum flavum.

junction between thoracic and lumbar regions, are filled in by a membrane, 1 to 2 mm thick, in which, however, no prevailing direction of the fibres can be recognised.

The interspinous ligaments of the lumbar vertebral column are particularly strongly developed (Fig. 8). They run downwards and forwards through the interspinous space (Heylings 1978), and are also connected with both the thoracolumbar fascia (lumbodorsal aponeurosis) and the caudal reinforcement fibres of the joint capsules (Prestar 1982; Aspden et al. 1987). The corresponding ligamentous structures in the lumbosacral segment consist of fibres of the interspinous ligament, which run dorsocranially in the same direction as

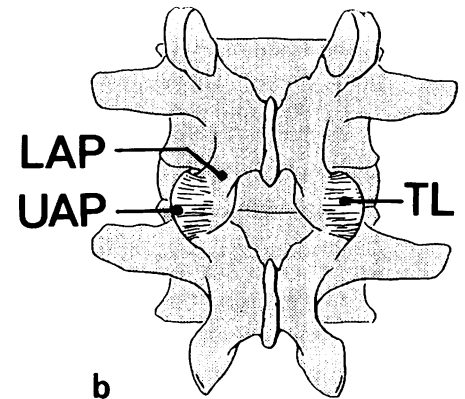



Fig. 6. Ligaments ("transverse ligaments" – TL) reinforcing the capsule of lumbar zygapophyseal joints. UAP upper articular process, LAP lower articular process.
 a) Transverse section (ligamentum flavum removed).
 b) Schematic representation from behind.

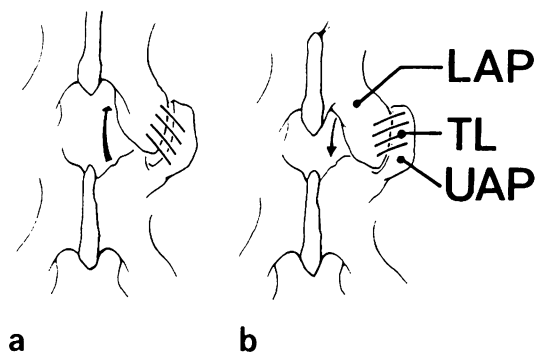


Fig. 7. Diagram illustrating function of the "transverse ligaments" of the lumbar zygapophyseal joints (viewed from behind). For further explanation see figure 6:
 a) ventral flexion,
 b) dorsal flexion.

those of the thoracolumbar fascia, together with additional fibres of that fascia streaming outwards from the tip of the spine of L5 and running obliquely downwards to their insertion on to the sacrum (Fig. 8).

The interspinous ligaments of the lumbar vertebrae consist of stout bundles of collagen fibres (Aspden et al. 1987), and

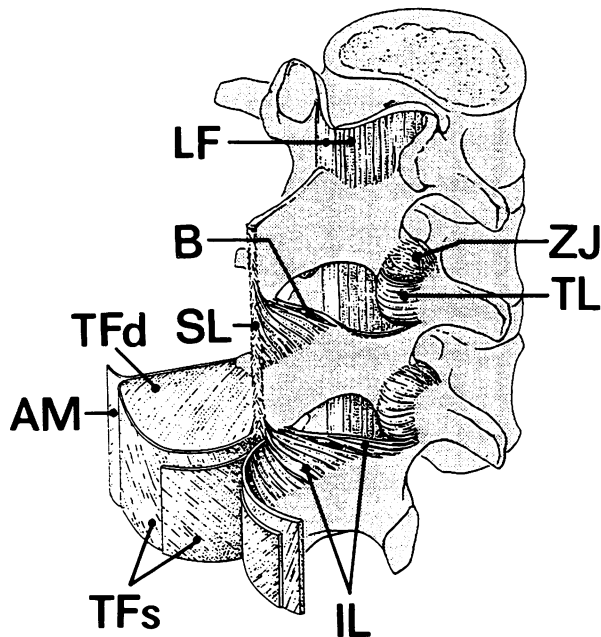


Fig. 8. Interspinous ligaments (IL) and thoracolumbar fascia (TF) of vertebral column in lumbar region (oblique lateral view). LF ligamenta flava, SL supraspinous ligament, B synovial bursa, TL „transverse ligament“, ZJ capsule of zygapophyseal joint, TFs superficial layer, TFd deep layer, AM origin of lateral abdominal muscles (internal oblique and transversus).

only contain additional elastic fibres at the lumbosacral junction. They are nevertheless in a position, because of their direction and their close association with the dorsal fascial sheets, to act as guides during flexion in the sagittal plane. Owing to their oblique course, they slowly become increasingly stretched during the final stages of both ventral and dorsal flexion, and thereby act against the accompanying shearing stress (Putz 1985). The tensile strength varies greatly from region to region. According to Myklebust et al. (1988), this is significantly less in the cervical and thoracic parts of the column than in the lumbar region, where values of 100 to 200 N can be attained.

Supraspinous ligament

The supraspinous ligament is only developed as a separate structure in the thoracic and upper lumbar column (Prestar 1982, 1985). It consists both of elastic and collagenous fibres (Chazal et al. 1985) and runs close together with the superficial fibres of the interspinous ligaments and with those of the thoracolumbar fascia. It can nevertheless be isolated as a separate thin band. In the lumbar region its tensile strength can be as much as 700 N. Although the supraspinous ligament is relatively thin, its great mechanical advantage allows it to exercise considerable turning force during the end stages of ventral flexion, thereby supplementing the action of the ligamenta flava.

Thoracolumbar fascia

In general, the thoracolumbar fascia (lumbodorsal aponeurosis) is included as a supplementary component of the deep muscles of the back. However, because its attachment reaches up as far as the middle thoracic vertebrae, and particularly because of its functional significance for the movements of the entire lower part of the vertebral column, it is also regarded as part of the ligamentous apparatus of that structure.

The thoracolumbar fascia consists of two sheets which lie very close together. Its fibres cross at an angle which can vary, rather like the struts in the gate of a lift (Prestar 1982). It is more strongly developed in the middle of the thoracic region and, reaching down to the sacrum and the medial extensions of the iliac crests, becomes remarkably thick. Both sheets arise from the tips of the spines, maintaining between these, however, a direct association with the interspinous ligaments (Fig. 8). One can even regard parts of the lower interspinous ligaments as deep components of the fascia. On account of its gate-like structure, the thoracolumbar fascia provides no longitudinal bracing system over the vertebrae, but, in spite of being constructed of collagen fibres, it slowly but increasingly limits ventral flexion only in its end stages.

Below, the thoracolumbar fascia is attached only to the sacrum and iliac crests. More cranially, it serves especially to give attachment to the internal and external oblique muscles, and to the transversus abdominis. In general, the thoracolumbar fascia constitutes the dorsal wall of an osteofibrous tube in which lie the various subdivisions of the erector spinae. Increase in pressure in this tube leads to the development of an elastic cushioning “conducting rod”, which determines the movements of the lumbar vertebrae. The active influence of the tensile load produced by the lateral abdominal muscles must be emphasised, but the importance of the osteofibrous tube itself is not open to question (Tesh 1987; Reiman 1991).

Iliolumbar ligaments

When one is considering functional analysis of the caudal fixation of the vertebral column in the region of the lumbosacral junction, the iliolumbar ligaments are particularly to be mentioned. Each ligament runs from the tip of the costal process of L5, which it encloses like a stocking, to diverge laterally towards the posterior inferior iliac spine. It is usually possible to distinguish a transverse sheet from one which angles forwards. Often there are also fibres anchored to the costal process of L4 (Boebel 1961). In small children this band may contain muscle fibres.

The iliolumbar ligament has in the past given rise to a number of different functional interpretations. One of the commonest appearing in the literature is that it prevents subluxation of L5 from the base of the sacrum (Benninghoff-Goerttler 1985; Rauber-Kopsch 1987). Our own researches with a method which employs strain gauges have, on

the contrary, demonstrated that significant tension in the iliolumbar ligaments is firstly associated with increasing ventral flexion, and secondly with extreme rotation and lateral flexion (Paul 1989). This has also been confirmed by the researches of Yamamoto et al. (1990). A simple axial load does not increase tension in the ligaments; on the contrary, it is more like to result in shortening.

As a result of these findings it is necessary, according to the basic principles of function, to include the iliolumbar ligament among the short segmental ligaments of the vertebral column. Starting with a basic tension of zero (rest position), it is, as a result of certain everyday movements, brought slowly under increasing tension. In this way it prevents the sudden appearance of tension peaks in the final stages of individual movements.

The significance of the intervertebral disc during movements of the column

It follows from the detailed description of their structure that the individual ligaments of the vertebral column are, both from the morphological and the functional point of view, to be regarded as separate units. With the exception of the anterior longitudinal ligament, the basis of their functioning consists in the fact that, because of the considerable obliquity of their fibres to the long axis of the trunk, their slowly increasing tension enables them to control and/or to limit individual movements of the vertebral column. This does not, of course, apply to the elastic ligaments, which follow their own functional laws.

The annulus fibrosus must certainly be seen as taking part in the co-operative action of the segmental ligaments, and its crossed fibrous lamellae (Fig. 9) undoubtedly follow the principles mentioned above. It is not to be regarded as a mere wrapping for the nucleus pulposus, but as a true ligamentous component of the motion segment.

To be sure, the separate functions here attributed to the fibres of the annulus and other ligaments of the motion segment

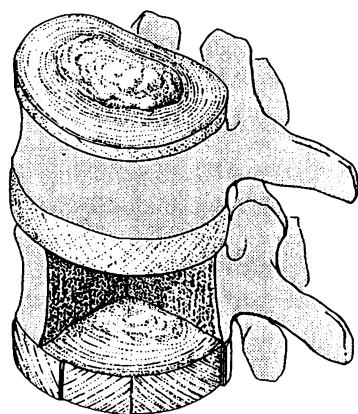


Fig. 9. Arrangement of the 11–15 lamellae and fibres of the annulus fibrosus of lumbar intervertebral discs. The dorsal part of the annulus is smaller than the ventral.

can only be carried out satisfactorily if the single fibres are already in play from the resting position onwards, which implies the existence of a certain initial tension. This initial tension is supplied by the internal pressure within the nucleus pulposus, which is therefore not required by the annulus fibrosus alone, but is also a decisive factor in determining the state of tension in the motion segment as whole. Only by means of this initial tension can a strict control of activity be achieved and jerky, haphazard movements avoided.

Should the internal pressure in the disc be decreased, jerkiness, especially at the beginning of the movement, is to be expected. This can lead to short-term tension peaks in the individual fibre bundles.

The significance of the intervertebral joints for the motion segment

The ligaments, and particularly those of the lumbar motion segment, are not by themselves able to provide protection against constant shearing stress over a long period of time. Since, according to the reports of Kummer (1982, 1983, 1991), the resultant force in the lumbar motion segment is directed obliquely downwards and forwards, it must be assumed that the principal stress in this segment tends to produce forward displacement. This is taken up by the anteromedially directed faces of the vertebral joints. On the one hand, the displacement of the upper vertebral body upon the lower is prevented; on the other, the vertebrae are compelled to act together, which in turn influences the degree of tension in most of the ligaments of the motion segment. This accounts, for instance, for the fact that the interspinous ligaments of the lumbar vertebrae are, at the end of both ventral and dorsal flexion, under tension, although they run through the interspinous space obliquely downwards and forwards.

Conclusions

Considered as a single unit, the ligaments of the motion segments – and particularly those of the lumbar motion segment – comprise a system which is able to control all phases of movement of the vertebral column (Fig. 10). Taking into account the spring-like tension in the intervertebral disc, together with the partial control exercised by the zygapophyseal joints, one must regard the lumbar motion segment as an organised ligamentous unit, the mostly non-elastic components of which – depending upon the degree of excursion present – act upon and control the movements of the vertebral column (Putz 1989). The elastic ligaments may be seen as an additional safeguard.

If one searches for morphological parallels within the passive components of the locomotor system, a large number of comparable examples are to be found. The cruciate ligaments of the knee-joint work in the same way, and so do the attachments between talus and calcaneus, acting through

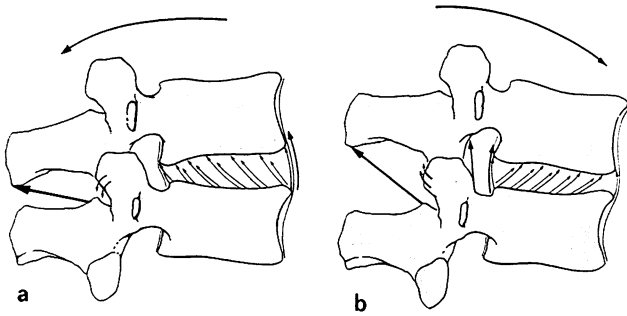


Fig. 10. Action of ligaments of the lumbar motion segment:
a) dorsal flexion,
b) ventral flexion.

the interosseous talocalcaneal ligament. Similar specialised ligaments are to be found in all the larger joints of the body.

References

- Adams MA, Dolan P, Hutton WC (1988) The lumbar spine in backward bending. *Spine* 13: 1019–1026
- Aspden RM, Bornstein NH, Hukins DWL (1987) Collagen organisation in the interspinous ligament and its relationship to tissue function. *J Anat* 155: 141–151
- Boebel A (1961) Anatomische Untersuchungen am Ligamentum iliolumbale. *Z. Orthop* 95: 131–139
- Behrsin JF, Briggs CA (1988) Ligaments of the lumbar spine: a review. *Surg Radiol Anat* 10: 211–219
- Bogduk N, Twomey LT (1987) *Clinical anatomy of the lumbar spine*. Churchill Livingstone, Melbourne Edinburgh London New York
- Chazal J, Tanguy A, Bourges M, Gaurel G, Escande G, Guillot, Vanneuville G (1985) Biomechanical properties of spinal ligaments and a histological study of the supraspinal ligament in traction. *J Biomech* 18: 167–176
- Grieve GP (1988) *Common vertebral joint problems*, Churchill Livingstone, Edinburgh London Melbourne New York
- Hayahsi K, Takeshi Y, Takahide K, Hiroyuki S, Masanobu SH, Shigeki M (1977) The anterior and the posterior longitudinal ligaments of the lower cervical spine. *J Anat* 124: 633–636
- Heylings DJA (1978) Supraspinous and interspinous ligaments of the human lumbar spine, *J. Anat* 125: 127–131
- Junghanns H (1977) *Nomenclatura columnae vertebralis*. Die Wirbelsäule in Forschung und Praxis. Bd 75, Hippokrates, Stuttgart
- Kummer B (1982) Funktionelle und pathologische Anatomie der Lendenwirbelsäule. *Z. Orthop* 119: 554
- Kummer B (1983) Welchen Beitrag leisten die Wirbelgelenke zur Tragefunktion der Wirbelsäule? In: *Biomechanik der Wirbelsäule*, Hrsg. Hackenbroch MH, HJ Refior, M. Jäger, Thieme, Stuttgart
- Kummer B (1991) Biomechanische Probleme der aufrechten Haltung, *Verh Anat Ges* 86: 158
- Myklebust JB, Pintar F, Yoganandan N, Cusick JF, Maiman D, Myers TJ, Sances A (1988) Tensile strength of spinal ligaments. *Spine* 13: 526–531
- Panjabi MM, Goel VK, Takata K (1982) Physiologic strains in the lumbar spinal ligaments. *Spine* 7: 192–203
- Paul HJ (1989) *Experimentelle Untersuchung zur Funktion des Lig. iliolumbale*. Diss Freiburg
- Putz R (1981) *Funktionelle Anatomie der Wirbelgelenke, Normale und Pathologische Anatomie*. Bd 43, Thieme, Stuttgart
- Putz R (1985) Action conjuguée des ligaments et des articulations des apophyses articulaires au niveau de la colonne lombaire dans la limitations des mouvements. *Ann Kinésithér* 12: 1–4
- Putz R (1985) The functional morphology of the superior articular processes of the lumbar vertebrae. *J Anat* 143: 181–187
- Putz R (1985) *Wirbelsäule*. In: Benninghoff-Goertler, *Makroskopische und Mikroskopische Anatomie des Menschen*. Bd 1, 14th ed, Hrsg J Staubesand, Urban & Schwarzenberg, München
- Putz R (1989) Functional morphology of the lower lumbar spine. *J. Manual Med* 4: 2–6
- Putz R (1990) Funktionelle Morphologie des lumbosakralen Überganges. In: *Wirbelsäulenchirurgie Spondylolisthesis*, Hrsg. KA Matzen, Thieme, Stuttgart
- Prestar FJ, Putz R (1982) Das Ligamentum longitudinale posterius – Morphologie und Funktion. *Morphol Med* 2: 181–189
- Prestar FJ, Frick H, Putz R (1983) Bandverbindungen der Dornfortsätze der Wirbelsäule. *Anat Anz* 159: 259–268
- Rauber-Kopsch, *Anatomie des Menschen*, Bd 1, 20th ed, Hrsg Tillmann B, Töndury G (1987) Thieme, Stuttgart
- Reimann R (1991) Hypothese zur Funktion der Rückenpresse. *Verh Anat Ges* 86: 238
- Schwarzenberger JA (1990) Über die meniskoiden Falten der kleinen Wirbelgelenke. Diss München
- Silkoryn TA, Hukins DW (1990) Mechanisms of failure of the ligamentum flavum of the spine during in vitro tensile tests. *J. Orthop Res* 8: 586–591
- Stofft E (1966) *Die funktionellen Strukturen des Ligamentum longitudinale anterius*, Diss Mainz
- Tesh KM, Dunn JS, Evans JH (1987) The abdominal muscles and vertebral stability. *Spine* 12: 501–508
- Yahia LH, Garzon S, Strykowski H, Rivard CH (1990) Ultrastructure of the human interspinous ligament and ligamentum flavum. *Spine* 15: 262–268
- Yamamoto IM, Panjabi M, Oxland TR, Crisco JJ (1990) The role of the iliolumbar ligament in the lumbosacral junction. *Spine* 15: 1138–1141