

Revue Neurologique

8 Mars 92 37(145)2

400 - P 80

Mise au point

B.T. TROOST. — Nystagmus : une mise au point clinique 417

Mémoires

M. WEBER, H. VESPIGNANI, S. BRACARD, J. ROLAND, L. PICARD, G. BARROCHE, J. AUQUE, J. LEPOIRE. — Les angiomes caverneux intracérébraux 429

J.C. GAUTIER, P. PRADAT-DIEHL, Ph. LORON, Ph. LECHAT, G. LASCAULT, J.B. JUILLARD, Y. GROSGOGÉAT. — Accidents vasculaires cérébraux des sujets jeunes. Une étude de 133 patients âgés de 9 à 45 ans 437

D. LEYS, M. STEINLING, H. PETIT, J.L. SALOMEZ, Y. GAUDET, E. OVELACQ, R. VERGNES. — Maladie d'Alzheimer : étude par tomographie d'émission monophotonique (Hm PAO Tc^{99m}) 443

J.L. GASTAUT, J.A. GASTAUT, J.F. PELLISSIER, J.B. TAPKO, O. WEILL. — Neuropathies périphériques au cours de l'infection par le virus de l'immunodéficience humaine. Une étude prospective de 56 sujets 451

F. CHAPON, F. VIADER, M. FARDEAU, F. TOME, N. DALUZEAU, Ch. BERTHELIN, J.Ph. THENINT, B. LECHEVALIER. — Myopathie familiale avec inclusions de type « corps cytoplasmiques » (ou sphéroïdes) révélée par une insuffisance respiratoire 460

Brèves communications

J. DIMITRIJEVIC, K. DZIRLO, D. STANKOVIC, Lj. SIMIC, R. BOKONJIC. — Maladie de Takayasu et hémorragie cérébro-méningée 466

J.C. ANTOINE, D. MICHEL, N. KOPP, P.M. GONNAUD, B. LAURENT. — Neuropathies périphériques chroniques d'allure hérédodégénérative, corticosensibles : deux cas 469

G. SERRATRICE, J.F. PELLISSIER, J.F. MARINI, P. VALENTIN-LECCESE. — Un cas de sciatique avec hypertrophie du mollet 474

Guy-André PELOUZE. — Plaque ulcérée emboligène de l'ostium de l'artère vertébrale 478

Document

J.M. CUBA, L. TORRES. — Huit arbres généalogiques de chorée de Huntington à Canete (Pérou) 482

Confrontation de la Salpêtrière, octobre 1987

J. BILLE, D. BRAULT, Ch. DUYCKAERTS. — Une méningite chronique chez une femme jeune alcoolique 485


Compte rendu

J.M. LEFAUCONNIER, J.M. BOURRE. — Journées d'étude « Alimentation et cerveau » 492

Actes de la Société française de Neurologie, séance des 1^{er} et 2 juin 1989 494

Analyses 495

Ouvrages reçus 498



Organe officiel de la

SOCIÉTÉ FRANÇAISE DE NEUROLOGIE

M
MASSON

Paris - Milan - Barcelone - Mexico

BITTE HIER ABZEICHNEN wenn das Heft benutzt wird			
M			

1989
VOL. 145 N°

6/7

ISSN 0035-3787
Publication périodique mensuelle

CELL GROUPS OF THE MEDIAL LONGITUDINAL FASCICULUS AND PARAMEDIAN TRACTS

J.A. BÜTTNER-ENNEVER, A.K.E. HORN and K. SCHMIDTKE

Institute of Neuropathology, University of Munich, FRG.

SUMMARY

The aim of this article is to introduce the reader to a continuum of cell clusters which may play an important role in the maintenance of eye position. They lie interspersed between the fascicles of the medial longitudinal fasciculus (MLF) and paramedian tracts in the caudal pons and medulla, and they also constitute the rostral part of the classical abducens nucleus. Previous workers showed that these 'cell groups of the paramedian tracts' (pmt cell groups) project to the flocculus, and receive afferents from several horizontal premotor cell groups. Results of neuroanatomical tracer experiments reported here demonstrate that they also receive a direct input from the vertical premotor gaze neurons in the mesencephalon (rostral iMLF and the interstitial nucleus of Cajal), as well as from some groups of oculomotor internuclear neurons. The projecting fibres descend to the cell groups of the paramedian tracts in the MLF. It is suggested that deficits in gaze-holding seen in internuclear ophthalmoplegia, for example, may result from damage to afferents of this paramedian cell continuum.

Les groupes cellulaires du faisceau longitudinal médian et des voies paramédianes.

J.A. BÜTTNER-ENNEVER, A.K.E. HORN and K. SCHMIDTKE. *Rev. Neurol. (Paris)*, 1989, 145 : 8-9, 533-539.

RÉSUMÉ

Le but de cet article est de présenter au lecteur un continuum de groupes cellulaires qui peuvent jouer un rôle important dans le maintien de la position oculaire. Ils sont situés parmi les fibres du faisceau longitudinal médian (MLF) et des voies paramédianes dans la partie caudale du pont et le bulbe, et ils constituent aussi la portion rostrale du classique noyau abducens. D'autres auteurs ont montré que ces « cell groups of the paramedian tracts (pmt cell groups) » projettent sur le flocculus, et reçoivent des afférences de plusieurs groupes cellulaires prémoteurs impliqués dans le regard horizontal. Les résultats d'expériences avec des traceurs neuroanatomiques, qui sont rapportés ici, montrent qu'ils reçoivent aussi des afférences des neurones prémoteurs du regard vertical, dans le mésencéphale (noyau rostral iMLF et noyau interstitiel de Cajal), et des afférences de quelques groupes de neurones oculomoteurs internucléaires. Les fibres de projection descendent sur les groupes cellulaires des voies paramédianes par le MLF. Il est suggéré que les troubles de la statique oculaire, observés par exemple dans l'ophtalmoplégie internucléaire, peuvent être dus à l'atteinte des afférences de ce continuum paramédian de cellules.

INTRODUCTION

The medial longitudinal fasciculus (MLF) is a phylogenetically stable fibre tract which can be found in all vertebrates. It extends from the rostral mesencephalon to the medulla, and lies close to the midline. At some levels groups of neurons can be found between the fascicles of the MLF : in the mesencephalon there is the rostral interstitial nucleus of the MLF (rostral iMLF), the interstitial nucleus of Cajal (iC), and cell clusters of the oculomotor nucleus which extend far out into the MLF. Further caudally at the pontomedullary junction and in the medulla oblongata a continuum of cells which project to the flocculus has been

described. The cells lie in and around the fascicles of the descending fibre tracts (Blanks *et al.*, 1983 ; Langer *et al.*, 1985a). At the pontomedullary junction a large component of MLF fibres crosses the midline and terminates in the abducens region ; the fascicles of the MLF become intermingled with fibres of tectal and reticular origin. In the medulla the prominent central fibre pathway is composed of many different tracts, including 'the MLF' : so in this region we use the general descriptive term *the paramedian tracts* here, after Langer *et al.* (1985a). In this article the nomenclature, the connectivity, and possible functional role of these different cell groups associated with the MLF and the paramedian tracts will be described.

ROSTRAL INTERSTITIAL NUCLEUS OF THE MLF

Some descending components of the MLF originate from a cell group in the dorsomedial border of the Fields of Forel. This cell group has been outlined in the monkey and man (Büttner-Ennever and Büttner 1978; Büttner-Ennever *et al.*, 1982), and shown to contain vertical burst neurons of the saccadic system, which project directly to the oculomotor and trochlear nuclei. It was called the rostral interstitial nucleus of the MLF (rostral iMLF), but the names the nucleus of the prerubral fields, and nucleus of the fields of Forel have been used by Graybiel (1977) in cat and monkey. However the vertical burst neurons only form a part of the fields of Forel. The cell group can be recognized, with some practice, by its characteristic cytoarchitecture: regularly-spaced medium-sized cells, lying caudal to the mammillothalamic tract, and rostral to the tractus retroflexus, the posterior thalamo-subthalamic artery forming a natural dorsal border. These features enable the rostral iMLF to be recognized in all vertebrates so far studied, including birds.

The descending rostral iMLF fibres travel in and around the MLF, and are also known to terminate in the abducens nucleus, vestibular nuclei, the nucleus prepositus hypoglossi, and some may extend down to the spinal cord (Langer *et al.*, 1986; Mabuchi and Kusama, 1970; personal observation). It appears to be a slightly more caudal population of neurons, not the rostral iMLF, that supply the spinal efferents from the mesencephalon (Holstege, 1988).

INTERSTITIAL NUCLEUS OF CAJAL

The interstitial nucleus of Cajal (iC) lies just ventral to the periaqueductal gray, while the MLF fibres encapsulate it on all sides. The tractus retroflexus roughly marks the rostral border of iC. The fibres originating from rostral iMLF pass caudally through iC, and collaterals of many such fibres terminate on the iC neurons (Highstein personal communication). Neurons of iC project ipsilaterally, and contralaterally via the posterior commissure, to the oculomotor nucleus and also give rise to fibres which descend in the most medial fascicles of the MLF. The descending pathways are known to terminate in the abducens area (Langer *et al.*, 1986), the vestibular nuclei and many travel further caudally to the spinal cord (for review see Fukushima, 1987; Holstege, 1988).

OCULOMOTOR NUCLEUS

Moving caudally from iC the MLF passes along the lateral and ventral border of the oculomotor nucleus. The

motoneurons lying in the ventral part of the oculomotor nucleus innervate the medial rectus muscle, the so-called A-group of Büttner-Ennever and Akert (1981). This subgroup is particularly pronounced in the monkey, where 'fingers' of the oculomotor nucleus extend out into the MLF. In the cat and rabbit these 'fingers' containing the medial rectus motoneurons are reduced to isolated groups of neurons lying ventral to the main body of the oculomotor nucleus amongst the fascicles of the MLF (Akagi, 1978; for review see Evinger, 1988). In the monkey many of the neurons in the 'fingers' are oculomotor internuclear neurons which can be retrogradely labelled by injections into the abducens region (Maciewicz *et al.*, 1975; Büttner-Ennever, 1981a; for review see Evinger, 1988). However we have found that in the monkey these internuclear neurons in subgroup 'A' of Büttner-Ennever and Akert (1981) are retrogradely filled from an area slightly rostral to the abducens nucleus, which did not contain the abducens internuclear neurons, nor lateral rectus motoneurons.

CELL GROUPS OF THE PARAMEDIAN TRACTS (PMT CELL GROUPS)

At the level of the trochlear nucleus the MLF is a compact bundle, and remains so until the caudal pons. As the MLF reaches the abducens nucleus its ventral border adjoining PPRF becomes invaded with a distinctive set of medium-sized chromatophilic neurons. They are intermingled ventrally with the excitatory burst neurons of PPRF and merge caudally into the abducens nucleus itself (Langer *et al.*, 1985a). In the monkey Langer *et al.* (1986) have shown that these cells cannot be filled with retrograde traces injected into the lateral rectus muscle, nor into the oculomotor nucleus: that is they are neither motoneurons nor internuclear neurons. They must be considered as a third group of neurons in the abducens nucleus, and it will be shown below that they form part of a continuum of cells which lie between and around the fascicles of the paramedian tracts, and all project to the floccular region.

Brodal (1953 and 1957) defined three subdivisions of the nucleus reticularis paramedianus in the cat: the accessory, dorsal and ventral subgroups (review: Brodal 1981 (*fig. 5.22*)). The same divisions have been outlined in the monkey (Somana and Walberg 1978; Brodal and Brodal, 1983; Brodal, 1983). They lie medial (accessory) and lateral (dorsal and ventral) to the fascicles of the paramedian fibre tracts at the level of the hypoglossal nucleus, and just rostral to it, in the medulla. The cell groups are interconnected via cellular bridges crossing the paramedian tracts. The accessory subdivision merges into the nucleus of Roller caudally. Olszewski and Baxter (1954) described a well developed set of neurons in the medulla in man, which would include the homologue of Brodal's accessory subdivision of the nucleus reticularis paramedianus: they were called nuclei paraphales. The suggestion of Olszewski and

Baxter that these neurons should be considered as displaced pontine nuclei may turn out to be a useful concept.

It has long been known that these paramedian medullary cell clusters project to the cerebellum (Brodal and Torvik, 1954; Somana and Walberg, 1978; Brodal and Brodal, 1983): but they have only recently attracted the attention after a retrograde study of the *floccular region* (flocculus and adjacent paraflocculus) by Blanks *et al.* (1983) in the rat, and by Langer *et al.* (1985a) in the monkey. They both showed that a whole continuum of cells could be retrogradely filled from the flocculus. The neurons were interspersed between the fascicles of the MLF, or paramedian tracts, at levels both rostral and caudal to the abducens nucleus, i.e. further rostral and much more widespread than originally described by Brodal (1957).

Blanks *et al.* (1983) considered the cells to be part of a continuum, and called the 2 major cell clusters which lie just rostral and caudal to the abducens nucleus, the intermediate and caudal interstitial nuclei of the MLF, respectively. In the monkey Langer *et al.* (1985a and 1986) found this system to be more highly differentiated in primates. They denoted the individual clusters of this 'continuum' as: the interfascicular nuclei of the preabducens area, the rostral cap of the abducens nucleus (which forms an impressively large proportion to the classical abducens nucleus), nucleus supragenualis (considered by Brodal 1983 as part of the perihypoglossal complex), the dorsal medullary interfascicular nucleus (*Brodal's accessory division* of the paramedian reticular nucleus), the ventral medullary interfascicular nucleus and nucleus paraphales. The latter was shown by Olzsewski and Baxter (1954) to be highly developed in man. McCrea *et al.* (1986, 1987a and b) have adopted the initial nomenclature that Blanks used for the rat, but it may turn out to be useful to subdivide the continuum of cell groups even more than this, as Langer has in the monkey. The location of the cell clusters are shown by stars in *fig. 1*.

A cytoarchitecturally-distinct cell cluster, lying rostral to the abducens nucleus and close to the MLF, was described by Strassman *et al.* (1986a) and McCrea *et al.* (1987a and b) in the monkey. They refer to it as the '*dorsal PPRF*'; and it includes Langer's 'interfascicular nuclei of the preabducens area', and should also be considered part of this continuum. Earlier reports of inputs to all these newly outlined cell groups of the paramedian tract may well be confused with those to the adjacent nuclei: for example 'nucleus paraphales' mistaken for nucleus raphe obscurus, or the floccular projecting 'rostral cap of the abducens nucleus' mistaken for the motoneuron component of the abducens nucleus.

A projection from the rostral iMLF and iC to the abducens nucleus is certainly not compatible with the current hypotheses on the role of rostral iMLF in the generation of the vertical saccadic component (Langer *et al.*, 1986; for review see Büttner-Ennever and Büttner, 1988), nor indeed with the role of iC in the control of vertical eye and head position (Fukushima, 1987). In

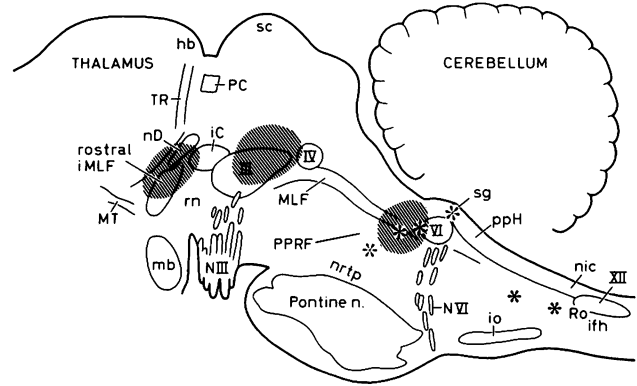


FIG. 1. — Sagittal view of a primate brain showing the location of the structures considered in the text. The asterisks mark the position of some of the cells groups of the MLF and paramedian tracts of the medulla, which project to the flocculus. The rostral shaded area involving rostral iMLF and iC represents a deposit of tritiated leucine. The shaded areas over the caudal oculomotor nucleus (III), and the rostral cap of the abducens nucleus (VI) represent deposits of the retrograde and anterograde tracer substance WGA-HRP complex.

Vue sagittale d'un cerveau de primate montrant la localisation des structures considérées dans le texte.

Les astérisques marquent la position de quelques-uns des groupes cellulaires du MLF et des voies paramédianes du bulbe, qui projettent sur le flocculus. La zone rayée rostrale intéressant le noyau rostral iMLF et iC représente un dépôt de leucine tritiée. Les zones rayées sur le noyau du III et l'extrémité rostrale du noyau abducens (VI) représentent les dépôts du complexe WGA-HRP, traceur rétrograde et antérograde.

experiments where tritiated leucine is injected into the rostral mesencephalon of the macaque monkey (*fig. 1*) we found heavy terminal labelling over the parts of the floccular projecting continuum of the paramedian tracts described above: the interfascicular nucleus of the preabducens region, the rostral cap of the abducens nucleus (but not the more caudal regions of the nucleus containing lateral rectus motoneurons and the internuclear neurons), the nucleus paraphales, and the interfascicular nucleus of the medulla (*fig. 2a-d*). In addition, a dorsal part of the caudal raphe pontis, and a region of the prepositus nucleus and the subjacent medullary reticular formation which also project to the floccular region were labelled. The nucleus supragenualis and the nucleus paramedianus dorsalis were not labelled.

This result shows that the vertical burst neurons in the mesencephalon do not project to the lateral rectus motoneurons but to the paramedian cell clusters with project to the flocculus. Another input to these groups can be demonstrated by a large injection of WGA-HRP (a retrograde and anterograde tracer substance) into the caudal oculomotor nucleus (*fig. 1*). This injection retrogradely fills the great majority of internuclear neurons in the contralateral abducens nucleus (*fig. 2e*), and also anterogradely labels the efferent fibres from the oculomotor internuclear neurons. These enter the MLF ipsilaterally and descended to the level of the abducens nucleus where they decussate. A fine distinctive dust-like deposit of tracer which indicates

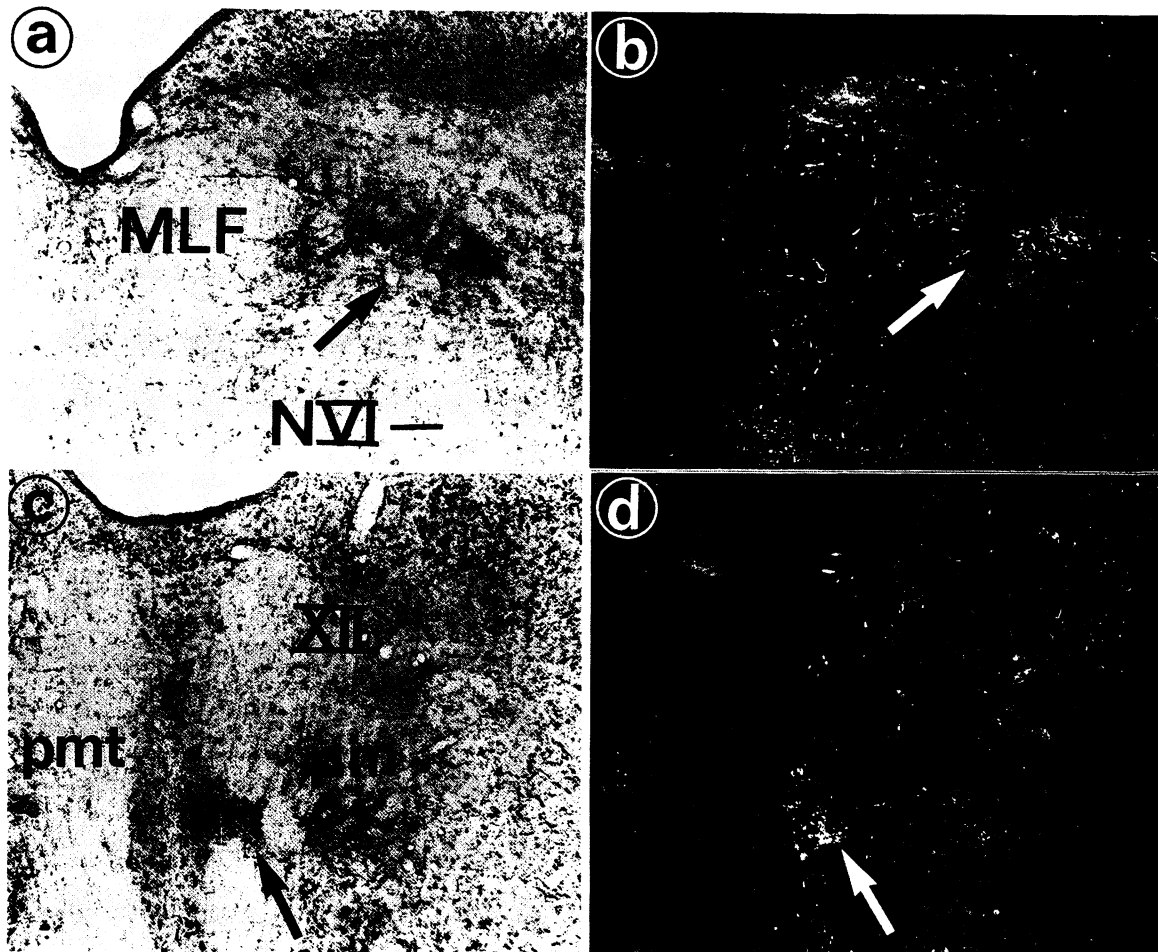


FIG. 2a-d. — Photographs of Nissl-stained transverse sections taken from an experiment in which tritiated leucine was injected into rostral iMLF and iC, on the right side. See Fig. 1 for the location of the injection site.

a) Light field photograph of the rostral cap of the abducens nucleus of the right side. To aid the comparison with b) a blood vessel is marked with an arrow.

b) A dark field photograph of the same regions as in a). Silver grain deposits, indicating the location of axon terminals, lie over the interfascicular neurons of MLF and cell groups of the paramedian tracts which project to the flocculus, but there is no labelling over the motoneuron region.

c) A light field photograph of the caudal medulla, at the level of the hypoglossal nucleus (XII). The arrow points to the dorsal medullary interfascicular nucleus of Langer (i.e. Brodal's accessory subdivision of pm) which lies close to the midline spreading laterally into the paramedian tracts, and joining the nucleus reticularis paramedianus (pm) with bridges of cells.

d) A dark field photograph of c): the arrow indicates silver grain deposits over the floccular-projecting cell group.

Photographies de coupes transversales après coloration de Nissl. De la leucine tritiée a été injectée dans le rostral iMLF et iC du côté droit. Voir la fig. 1 pour la localisation du site d'injection.

a) Photographie de l'extrémité rostrale du noyau abducens du côté droit. Pour faciliter la comparaison avec b) un vaisseau sanguin est marqué par une flèche.

b) Photographie à fond noir de la même région que dans a). Des grains d'argent, indiquant la localisation des terminaisons axonales, siègent dans les neurones interfasciculaires du MLF et dans les groupes cellulaires des voies paramédianes qui projettent sur le flocculus, mais il n'y a pas de marquage de la région des motoneurones.

c) Photographie de la partie caudale du bulbe, au niveau du noyau hypoglosse (XII). La flèche indique le noyau interfasciculaire bulbaire dorsal de Langer (c'est-à-dire la subdivision accessoire de Brodal du pm), qui est situé près de la ligne médiane, s'étendant latéralement dans les voies paramédianes et rejoignant le nucleus reticularis paramedianus (pm) par des travées cellulaires.

d) Photographie à fond noir de c): la flèche indique les grains d'argent sur le groupe cellulaire projetant sur le flocculus.

labelled axon terminals, lay predominantly over the cells embedded in the MLF just rostral to the abducens nucleus (bilaterally), the rostral cap of the abducens nucleus, the nucleus supragenualis (fig. 2e and f) and also over other cell groups of the paramedian tracts in the medulla, but not

over abducens motoneurons. All these labelled cell groups belong to a continuum of cells that project to the floccular region described above.

Since their definition in 1983 by Blanks *et al.* in the rat, and separately by Langer *et al.* (1985a) in the monkey, the




FIG. 2e-f. — Non-counterstained sections of the rostral (e), and the caudal (f), abducens nucleus on the left side, showing the pattern of labelling after a WGA-HRP injection into the oculomotor nucleus, in the right side (see fig. 1). The majority of abducens internuclear neurons are retrogradely filled. A fine dust-like tracer deposit indicating anterogradely labelled axon terminals, arising from oculomotor internuclear neurons at the injection site, can be seen most clearly in the dorsomedial portion of the rostral abducens nucleus and in the nucleus supragenualis (arrows in e) : i.e. around the floccular-projecting cell groups of the paramedian tracts. The section in f) is not counterstained and the fine anterograde deposit is more clearly visible, especially over sg. Calibration 200 μ .

Coupes non-contrecolorées de la partie rostrale (e) et caudale (f) du noyau abducens du côté gauche, montrant le marquage après injection de WGA-HRP dans le noyau du III du côté droit (voir fig. 1). La majorité des neurones internucléaires du noyau abducens sont marqués de façon rétrograde. Un dépôt de traceur en fin amas, indiquant les terminaisons des axones marqués de façon antérograde et venant des neurones internucléaires du noyau du III, peut être le plus nettement vu dans la portion dorsomédiale de la partie rostrale du noyau abducens et dans le nucleus supragenualis (flèches) dans e) : c'est-à-dire aux alentours des groupes cellulaires des voies paramédianes projetant sur le flocculus. La coupe en f) n'est pas contre-colorée et le dépôt antérograde fin est plus clairement visible, surtout sur sg. Calibration de 200 μ .

cell groups of the paramedian tracts have now been shown to receive inputs from abducens internuclear neurons (McCrea *et al.*, 1986), horizontal excitatory and inhibitory burst neurons of the saccadic system (Strassman *et al.*, 1986 a and b), secondary vestibular neurons related to vertical and horizontal canals (McCrea *et al.*, 1987a and b) and nucleus prepositus hypoglossi (Blanks and Torigce, 1983). We describe here two further inputs, arising from rostral iMLF and iC, and from the oculomotor internuclear neurons (see fig. 2e and f). These connections are all from premotor nuclei : they are summarized in fig. 3. It is perhaps wise at this point to remember that although the only known output of the continuum is at present the flocculus, Somana and Walberg (1978) found that parts of it (the accessory subgroup of the paramedian reticular nucleus) projected strongly to the mid-vernal region as well as to the flocculus. Both these regions are involved in the control of gaze (Büttner, this volume).

The unit activity of floccular projecting neurons in the medial caudal pons (PPRF) was recorded by Nakao *et al.* (1980). They showed that units, active during horizontal nystagmus, could be classified as shortlead, longlead, and burst-tonic types. The burst-tonic units were found most dorsally and probably reflect the activity of the paramedian cell continuum. There are several reports of vertical burst neurons of the saccadic system in the medulla below the

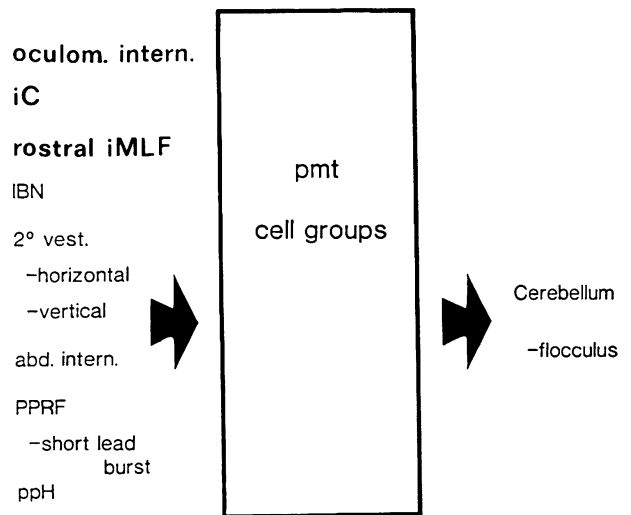


FIG. 3. — A summary of the afferent and efferent connections of the cell groups of the paramedian tracts (pmt cells).

Résumé des connexions afférentes et éfférentes des groupes cellulaires des voies paramédianes (cellules pmt). Abréviations page suivante.

nucleus prepositus hypoglossi (Delgado-Garcia *et al.*, 1988). These are certainly related to the projections from rostral iMLF and iC to the paramedian cell groups of the medulla.

The function of the continuum is not known, but it is now clear that it receives afferents from all areas that contain direct premotor neurons of the oculomotor system. In other words it relays burst-tonic information of both vertical and horizontal saccades and eye position to the flocculus. The cytochrome oxidase content in the interfascicular neurons of the MLF is very high and provides supportive evidence for their high level of tonic activity (Büttner-Ennever *et al.*, 1988). Burst-tonic activity encoding the saccadic burst as well as eye position has been recorded in the floccular region by Noda and Suzuki (1979) and Miles *et al.* (1980). This type of information is essential for any structure involved in gaze-holding and smooth pursuit eye movements. Bilateral lesions of the floccular region result in the loss of vertical and horizontal gaze-holding, as well as deficits in smooth pursuit eye movements (Zee *et al.*, 1981). It seems probable that the information essential for the maintenance of eye position is relayed to the cerebellum from the groups of the paramedian tracts. How the floccular region in turn would influence the oculomotor nuclei to stabilize eye position, is not known. Its efferents relay almost exclusively in the vestibular nuclei (Langer *et al.*, 1985b) and so presumably any circuit including the cell groups of the paramedian tract would influence the oculomotor nuclei via the floccular region, the vestibular nuclei, then via the well known vestibular-oculomotor pathways in the MLF to the motoneurons of the extraocular eye muscles (for reviews see Büttner-Ennever, 1981b; Highstein and McCrea, 1988).

The information from both the oculomotor internuclear neurons and from the vertical premotor burst neurons to the paramedian continuum travels in the MLF. Therefore damage to this pathways should lead to a disturbance of gaze holding in the horizontal and vertical plane. Exactly these features have been shown in both experimental lesions of MLF (Evinger *et al.*, 1977), and in clinical cases of MLF damage, e.g. internuclear ophthalmoplegia (for review see Leigh and Zee, 1983; Zee *et al.*, 1987). The hypothesis that the gaze-holding deficits seen in internuclear ophthalmoplegia was caused by damage to the floccular-projecting cell groups lying within the MLF, was proposed sometime ago by Zee (personal communication; and independently by Pierrot-Deseilligny (1988). It is now possible to support this suggestion with anatomical data. Finally, midline lesions of the caudal medulla can cause loss of gaze-holding in the vertical plane (upbeat nystagmus: Baloh, this volume), it is possible that damage to the 'cell groups of the paramedian tract' is the cause of this phenomenon.

Acknowledgements. — This work was supported by the German Research Council SFB 220/D8. The authors are very grateful to Professor ten Bruggencate for providing facilities, Professor Mehraein for continuous support, and to Mojgan Djaschni for technical assistance.

ABBREVIATIONS

III	oculomotor nucleus
IV	trochlear nucleus
VI	abducens nucleus
XII	hypoglossal nucleus
fn	fastigial nucleus
hb	habenular complex
IBN	inhibitory burst neurons
iC	interstitial nucleus of Cajal
ifh	intrafascicular hypoglossal nucleus
io	inferior olive
mb	mammillary body
MLF	medial longitudinal fasciculus
MT	mammillothalamic tract
NVI	abducens nerve
NVII	facial nerve (genu)
nD	nucleus Darkschewitsch
nic	nucleus intercalatus
nntp	nucleus reticularis tegmenti pontis
PC	posterior commissure
pm	nucleus reticularis paramedianus
pmt	paramedian tracts
ppH	nucleus prepositus hypoglossi
PPRF	paramedian pontine reticular formation
rn	red nucleus
Ro	nucleus of Roller
rostral iMLF	rostral interstitial nucleus of the MLF
sc	superior colliculus
sg	nucleus supragenualis
TR	tractus retroflexus

ABRÉVIATIONS

III	noyau du nerf moteur oculaire commun
IV	noyau trochléaire
VI	noyau abducens
XII	noyau hypoglosse
fn	noyau fastigial
hb	complexe habénulaire
IBN	neurone phasique inhibiteur
iC	noyau interstitiel de Cajal
ifh	noyau hypoglosse intrafasciculaire
io	olive inférieure
mb	corps mammillaire
MLF	faisceau longitudinal médian
MT	voie mammilo-thalamique
NVI	nerf abducens
NVII	nerf facial (genou)
nD	noyau de Darkschewitsch
niC	noyau intercalé
nntp	nucleus reticularis tegmenti pontis
PC	commissure postérieure
pm	noyau réticulaire paramédian
pmt	voies paramédianes
ppH	nucleus prepositus hypoglossi
PPRF	formation réticulaire pontique paramédiane
rn	noyau rouge
Ro	noyau de Roller
rostral iMLF	noyau rostral interstitiel du MLF
sc	colliculus supérieur
sg	nucleus supragenualis
TR	tractus rétroflexus

REFERENCES

- AKAGI Y. (1978). The localization of the motor neurons innervating the extraocular muscles in the oculomotor nuclei of the cat and rabbit using HRP. *J Comp Neurol*, 181: 745-762.
- BLANKS R.H.I., PRECHT W., TORIGOE Y. (1983). Afferent projections to the cerebellar flocculus in the pigmented rat demonstrated by retrograde transport of horseradish peroxidase. *Exp Brain Res*, 52: 293-306.
- BLANKS R.H.I., TORIGOE Y. (1983). Two neuronal groups associated with the medial longitudinal fasciculus (MLF) of cat and rat that convey vestibular impulses to the cerebellar flocculus. *Soc Neurosci Abstr*, 9, 608.
- BRODAL A. (1953). Reticulo-cerebellar connections in the cat. An experimental study. *J Comp Neurol*, 98: 113-154.
- BRODAL A. (1957). The reticular formation of the brain stem. Anatomical aspects and functional correlations. The William Ramsay Henderson Trust Lectures No XVIII. *Oliver & Boyd, Edinburgh*.
- BRODAL A. (1981). Neurological anatomy. *Oxford Univ Press, Oxford*.
- BRODAL A. (1983). The perihypoglossal nuclei in the macaque monkey and the chimpanzee. *J Comp Neurol*, 218: 257-269.
- BRODAL A., BRODAL P. (1983). Observations on the projection from the perihypoglossal nuclei onto the cerebellum in the macaque monkey. *Arch Ital Biol*, 121: 151-166.
- BRODAL A., TORVIK A. (1954). Cerebellar projection of paramedian reticular nucleus of medulla oblongata in cat. *J Neurophysiol*, 17: 484-495.
- BÜTTNER-ENNEVER J.A. (1981a). Anatomy of medial rectus subgroups in the oculomotor nucleus of the monkey. In: Fuchs A.F., Becker W. (Eds.). *Progress in Oculomotor Research*. Elsevier, Amsterdam.
- BÜTTNER-ENNEVER J.A. (1981b). Vestibular-oculomotor organization. In: Fuchs A.F., Becker W. (Eds.). *Progress in Oculomotor Research*. Elsevier, Amsterdam 361-370.
- BÜTTNER-ENNEVER J.A. and BÜTTNER U. (1978). A cell group associated with vertical eye movements in the rostral mesencephalic reticular formation of the monkey. *Brain Res*, 151: 31-47.
- BÜTTNER-ENNEVER J.A., BÜTTNER U. (1988). The reticular formation. In: Büttner-Ennever J.A. (Ed.). *Neuroanatomy of the Oculomotor System (Reviews of Oculomotor Research Vol. 2)*. Elsevier, Amsterdam, 119-176.
- BÜTTNER-ENNEVER J.A., AKERT K. (1981). Medial rectus subgroups of the oculomotor nucleus and their abducens input in the monkey. *J Comp Neurol*, 197: 17-21.
- BÜTTNER-ENNEVER J.A., BÜTTNER U., COHEN B., BAUMGARTNER G. (1982). Vertical gaze paralysis and the rostral interstitial nucleus of the medial longitudinal fasciculus. *Brain*, 105: 125-149.
- BÜTTNER-ENNEVER J.A., COHEN B., PAUSE M. and FRIES W. (1988). A raphe nucleus of the pons containing omnipause neurons of the oculomotor system in the monkey. *J Comp Neurol*, 267: 307-321.
- DELGADO-GARCIA J.M., VIDAL P.P., GOMEZ C., BERTHOZ A. (1988). Vertical eye movement related signals in antidromically identified medullary reticular formation neurons in the alert cat. *Exp Brain Res*, 70: 585-589.
- EVINGER C. (1988). Extraocular motor nuclei: Location, morphology and afferents. In: Büttner-Ennever J.A. (Ed.). *Neuroanatomy of the Oculomotor System (Reviews for Oculomotor Research Vol. 2)*. Elsevier, Amsterdam, pp. 81-117.
- EVINGER L.C., FUCHS A.F., BAKER R. (1977). Bilateral lesions of the medial longitudinal fasciculus in monkeys: effects on horizontal and vertical components of voluntary and vestibular induced eye movements. *Exp Brain Res*, 28: 1-20.
- FUKUSHIMA K. (1987). The interstitial nucleus of Cajal and its role in the control of movements of head and eyes. *Progress in Neurobiology*, 29: 107-192.
- GRAYBIEL A.M. (1977). Organization of oculomotor pathways in the cat and rhesus monkey. In: control of gaze by brain stem neurons. In: Baker R., Berthoz A. (Eds.). *Control of Gaze by Brain Stem Neurons. Developments in Neuroscience*. Elsevier, Amsterdam, 1: 79-88.
- HIGHSTEIN S.M., MCCREA R.A. (1988). The anatomy of the vestibular nuclei. In: Büttner-Ennever J.A. (Ed.). *Neuroanatomy of the Oculomotor System (Reviews of Oculomotor Research Vol. 2)*. Elsevier, Amsterdam, pp. 177-202.
- HOLSTEGE G. (1988). Brainstem - spinal cord projections in the cat related to control of head and axial movements. In: Büttner-Ennever J.A. (Ed.). *Neuroanatomy of the Oculomotor System (Reviews of Oculomotor Research Vol. 2)*. Elsevier, Amsterdam, pp. 431-470.
- LANGER T., FUCHS A.F., SCUDDER C.A., CHUBB M.C. (1985a). Afferents to the flocculus of the cerebellum in the rhesus macaque as revealed by retrograde transport of horseradish peroxidase. *J Comp Neurol*, 235: 1-25.
- LANGER T., FUCHS A.F., CHUBB M.C., SCUDDER C.A., LISBERGER S.G. (1985b). Floccular efferents in the rhesus macaque as revealed by autoradiography and horseradish peroxidase. *J Comp Neurol*, 235: 26-37.
- LANGER T., KANEKO C.R.S., SCUDDER C.A., FUCHS A.F. (1986). Afferents to the abducens nucleus in the monkey and cat. *J Comp Neurol*, 245: 379-400.
- LEIGH R.J., ZEE D.S. (1983). The neurology of eye movements. (Contemporary Neurology Series Vol. 23). *F.A. Davis Company, Philadelphia*.
- MABUCHI M., KUSAMA T. (1970). Mesodiencephalic projection to the inferior olive and the vestibular and perihypoglossal nuclei. *Brain Res*, 17: 133-136.
- MACIEWICZ R.J., KANEKO C.R.S., HIGHSTEIN S.M., BAKER R. (1975). Morphophysiological identification of interneurons in the oculomotor nucleus that project to the abducens nucleus in the cat. *Brain Res*, 96: 60-65.
- MCCREA R.A., STRASSMANN A., HIGHSTEIN S.M. (1986). Morphology and physiology of abducens motoneurons and internuclear neurons intracellularly injected with horseradish peroxidase in alert squirrel monkeys. *J Comp Neurol*, 243: 291-308.
- MCCREA R.A., STRASSMANN A., MAY E., HIGHSTEIN S.M. (1987a). Anatomical and physiological characteristics of vestibular neurons mediating the horizontal vestibulo-ocular reflex in the squirrel monkey. *J Comp Neurol*, 264: 547-570.
- MCCREA R.A., STRASSMANN A., HIGHSTEIN S.M. (1987b). Anatomical and physiological characteristics of vestibular neurons mediating the vertical vestibulo-ocular reflexes in the squirrel monkey. *J Comp Neurol*, 264: 571-594.
- MILES F.A., FULLER J.H., BRAITMAN D.J., DOW B.M. (1980a). Longterm adaptive changes in primate vestibulo-ocular reflex. III. Electrophysiological observations in flocculus of normal monkeys. *J Neurophysiol*, 43: 1437-1476.
- NAKAO S., CURTHOYS I.S., MARKHAM C.H. (1980). Eye movement related neurons in the cat pontine reticular formation: Projection of the flocculus. *Brain Res*, 183: 291-299.
- NODA H., SUZUKI D.A. (1979). Processing of eye movement signals in the flocculus of the monkey. *J Physiol*, 294: 349-364.
- OLSZEWSKI J. and BAXTER D. (1954). Cytoarchitecture of the human brain stem. *S. Karger, Basel*.
- PIERROT-DESEILLIGNY C. (1988). Brainstem control of horizontal gaze: effect of lesions. In: *Physiological Aspects of Clinical Neuro-Ophthalmology*. Kennard C. and Clifford Rose F. (Eds.) *Chapman and Hall London*, p. 209-235.
- SOMANA R., WALBERG F. (1978). Cerebellar afferents from the paramedian reticular nucleus studied with retrograde transport of horseradish peroxidase. *Anat Embryol (Berl)*, 154: 353-368.
- STRASSMANN A., HIGHSTEIN S.M., MCCREA R.A. (1986a). Anatomy and physiology of saccadic burst neurons in the alert squirrel monkey. I. Excitatory burst neurons. *J Comp Neurol*, 249: 337-357.
- STRASSMANN A., HIGHSTEIN S.M., MCCREA R.A. (1986b). Anatomy and physiology of saccadic burst neurons in the alert squirrel monkey. II. Inhibitory burst neurons. *J Comp Neurol*, 249: 358-380.
- ZEE D.S., HAIN T.C. and CARL J.R. (1987). Abduction nystagmus in internuclear ophthalmoplegia. *Ann Neurol*, 21: 383-388.
- ZEE D.S., YAMAZAKI A., BULTER P.H., GÜCER G. (1981). Effects of ablation of flocculus and paraflocculus on eye movements in primates. *J Neurophysiol*, 46: 878-899.