

## The Anterior Tarsal Tunnel Syndrome

K.-H. Krause<sup>1</sup>, T. Witt<sup>2</sup> and A. Ross<sup>2</sup>

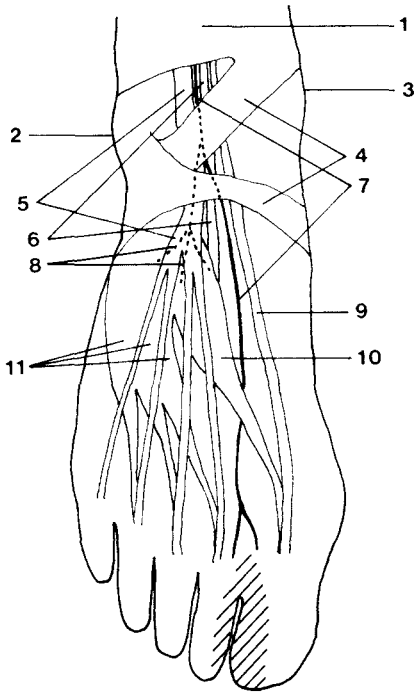
<sup>1</sup>Neurologische Universitätsklinik (Direktor: Prof. Dr. med. H. Gänshirt), Voßstraße 2, D-6900 Heidelberg, Federal Republic of Germany

<sup>2</sup>Neurologische Klinik der Universität München (Direktor: Prof. Dr. med. A. Schrader), Marchioninistraße 15, D-8000 München 70, Federal Republic of Germany

**Summary.** The anterior tarsal tunnel syndrome, first described in 1968 by Marinacci, is characterized by a compression of the deep peroneal nerve under the inferior extensor retinaculum. The patients complaint of pains on the dorsum of the foot, especially at night. Clinically result sensory deficits in the involved area between the first and second toes as well as paresis and atrophy of the extensor digitorum brevis. The distal latency of the deep peroneal nerve is increased, the EMG shows active and chronic denervation of the extensor digitorum brevis. In cases with partial anterior tarsal tunnel syndrome only the motoric branch to the extensor digitorum brevis or only the sensory branch of the deep peroneal nerve after the division under the inferior extensor retinaculum is compressed. Two cases with complete and one with partial anterior tarsal tunnel syndrome are presented, etiology, symptomatology, differential diagnosis and therapeutic possibilities are discussed.

**Key words:** Tarsal tunnel syndrome – Peroneal nerve – M. extensor digitorum brevis – Anterior tarsal tunnel syndrome.

**Zusammenfassung.** Das 1968 erstmals von Marinacci beschriebene vordere Tarsaltunnelsyndrom besteht in einer Kompression des N. peroneus profundus unter dem Ligamentum cruciatum. Subjektiv werden heftige, vor allem nachts auftretende Schmerzen im Fußrückenbereich geklagt. Klinisch resultieren sensible Ausfallserscheinungen im entsprechenden Hautareal zwischen der ersten und zweiten Zehe sowie Parese und Atrophie des M. extensor digitorum brevis. Elektroneurographisch findet sich eine erhöhte distale motorische Latenz des N. peroneus profundus, elektromyographisch ist aktive und chronische Denervierung im M. extensor digitorum brevis nachweisbar. In Fällen mit partiellem vorderen Tarsaltunnelsyndrom wird entweder nur der motorische Ast zum M. extensor digitorum brevis oder nur der sensible Anteil des N. peroneus profundus nach der Teilung unter dem Ligamentum cruciatum komprimiert. Zwei Fälle mit vollständigem sowie ein



**Fig. 1.** Anatomy of the back of the foot; 1 superior extensor retinaculum, 2 lateral malleolus, 3 medial malleolus, 4 inferior extensor retinaculum, 5 tendon of the extensor digitorum longus muscle, 6 dorsal artery of the foot, 7 deep peroneal nerve, 8 motor branches of the deep peroneal nerve, 9 tendon of the extensor hallucis longus muscle, 10 extensor hallucis brevis muscle, 11 extensor digitorum brevis muscle, ■ cutaneous sensory area innervated by the deep peroneal nerve

Fall mit partiellem vorderen Tarsaltunnelsyndrom werden vorgestellt; Ätiologie, Symptomatologie, Differentialdiagnose und therapeutische Möglichkeiten werden erörtert.

A nerve compression syndrome in the region of the tarsus was first described for the parts of the tibial nerve and its terminal branches, the medial and lateral plantar nerves, which lie in the medial malleolar region where they cross under the lig. laciniatum. In 1962 Keck [5] and Lam [6] established the term "tarsal tunnel syndrome" for this condition and in 1968 Marinacci described a further tarsal compression syndrome with entrapment of the deep peroneal nerve under the inferior extensor retinaculum [9, 10]. He differentiated the previously described medial from the anterior tarsal tunnel syndrome which he was the first to elucidate. While there are many reports about the former syndrome [1, 2, 3, 4, 5, 6, 7, 8, 11, 12], the anterior tarsal tunnel syndrome is referred to only by Marinacci. Ruprecht [14] noted the elongation of the distal motor latencies after stimulation of the deep peroneal nerve proximal to the inferior extensor retinaculum as well as electromyographically demonstrable signs of denervation in the extensor digitorum brevis muscle. A partial anterior tarsal syndrome is to be diagnosed when either the motor terminal branch or only the sensory part of the deep peroneal nerve is involved; this is thoroughly possible in consideration of the anatomical facts, because the deep peroneal nerve gives up its motor branch under the inferior extensor retinaculum (Fig. 1). Mumenthaler and Schliack [13]

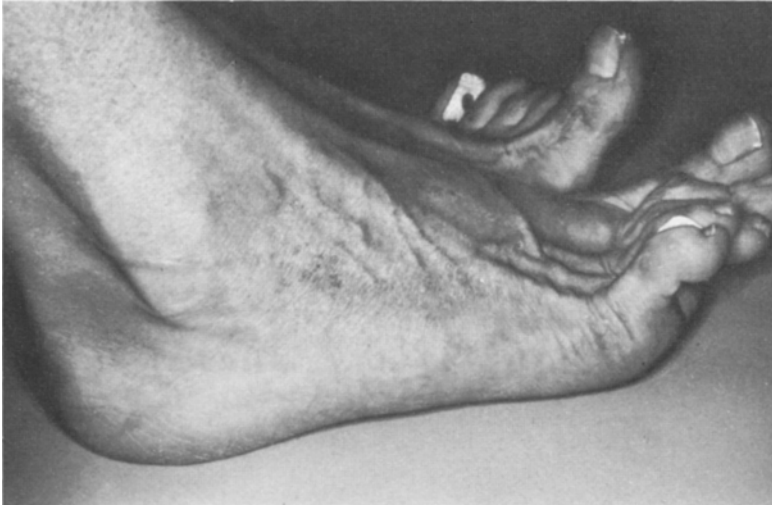mention some patients with impairment of sensory cutaneous nerve branches on the dorsum pedis, resulting in dys- and hypesthesia, caused by wearing too narrow shoes. The existence of a partial anterior tarsal tunnel syndrome with an exclusive lesion of the sensory part of the deep peroneal nerve must be considered in some of these cases. We have recently seen a female patient with a partial anterior tarsal tunnel syndrome due to an isolated lesion of the motor branch of the deep peroneal nerve, and two further cases with the clinical and electromyographic signs of a complete anterior tarsal tunnel syndrome.

*Case 1.* A woman, aged 60, sustained an injury to the right foot at the age of 15 when a wagon wheel rolled over it, but caused only temporary discomfort. Since the age of 55 she has frequently sprained the right foot, following which hematomas often appeared over the right external malleolus and dorsum of the foot. To avoid spraining she wore high, laced shoes which extended above the malleoli. For 3 years she has experienced severe spasmodic pain over the dorsum of the foot with a numb feeling on the inner side of the right big toe which usually occurred in the evening after long walks. The pain was frequently so severe that she could not sleep. She obtained some relief by applying alcohol, salves and alternating baths of hot and cold water. Temporary and slight relief of the pain followed voluntary movement of the right foot.

Examination revealed marked atrophy and weakness of the right extensor digitorum brevis, with modest loss of all sensory qualities in the sensory area of the right deep peroneal nerve. The right deep peroneal nerve was slightly sensitive to pressure in the region of the dorsum pedis under the inferior extensor retinaculum. Neurological examination revealed no other abnormalities. The electromyographic investigation showed denervation of the right extensor digitorum brevis in the form of fibrillation potentials and positive sharp waves at rest and marked rarefaction at maximal voluntary effort with increased potential duration and amplitude, as well as polyphasic potentials. A normal electromyographic state was found in several other proximal and distal muscles of the upper and lower extremities. The electroneurogram revealed a distal motor latency of the deep peroneal nerve of 7.0 msec, a proximal latency of 12.6 msec on the right side; the corresponding latencies on the left were 4.0 and 9.7 msec. The nerve conduction velocities were 51 m/sec on the right and 50 m/sec on the left side. Because of the clinical as well as the electromyographic and electroneurographic findings an anterior tarsal tunnel syndrome was diagnosed on the right side.

*Case 2.* A woman, aged 54, was treated for pyelonephritis in 1973 with penicillin and nitrofurantoin (200—300 mg daily for 3 to 4 weeks). After 1 week of the treatment she developed dysesthesia over the dorsum of the right foot to the big toe which soon became an intense burning and pulsating pain, constant at rest and while standing but relieved slightly by walking. The pain was aggravated by cold and stormy weather. She often required medicines for sleep. About 6 months after the onset of the pain in the right foot she complained temporarily of less intense pain with a stocking-like distribution over the left foot. A diagnosis of distal polyneuropathy of the lower extremities was made in April 1975 when a prolonged distal motor latency of 6.7 m/sec was found in the right deep peroneal nerve, although a biopsy of muscle and sural nerve revealed no abnormality. Some time later she was admitted to a psychiatric hospital under the assumption that her complaints were psychogenic.

Examination revealed marked atrophy (Fig. 2) and loss of strength of the right extensor digitorum brevis muscle. Hypalgesia and hypesthesia were found in the sensory area of the right deep peroneal nerve which was distinctly sensitive to pressure under the inferior extensor retinaculum. There were no other neurological abnormalities. The electromyographic examination revealed frequent fibrillation potentials and positive sharp waves in the right extensor digitorum brevis as well as a massive chronic denervation pattern on voluntary effort. The EMG also showed discrete chronic denervation of the left extensor digitorum brevis and of the flexor hallucis brevis on both sides, but the EMG findings of several other muscles were normal. Electroneurographically the nerve conduction velocities of the lower extremities were slightly decreased (deep peroneal nerve 43 m/sec on the right, 45.5 m/sec on the left; tibial nerve 40 m/sec on the right, 43 m/sec on the left) and, in accordance with this, the distal motor latencies were a little



**Fig. 2.** Atrophy of the right extensor digitorum brevis muscle in Case 2

increased with the exception of the right deep peroneal nerve. The latency for this nerve was extremely prolonged to 16.1 msec. A right anterior tarsal tunnel syndrome and a discrete distal polyneuropathy of the lower extremities were diagnosed in this case.

*Case 3.* A woman, aged 44, had a laminectomy in 1975 for the removal of a ruptured disc L<sub>4-5</sub> on the right. She complained of back pain at times so she was examined with the thought of a possible recurrence. Dysesthesia had never been noted in the left foot.

Examination revealed a discrete motor and sensory paresis corresponding to the right L<sub>5</sub> root. The extensor digitorum brevis was slightly atrophied and the strength of dorsal extensors of the toes was slightly reduced on the left. The left deep peroneal nerve was not sensitive to pressure on the dorsum of the foot. There was no sensory deficit of the foot. The neurological state was otherwise normal. The EMG revealed denervation of the left extensor digitorum brevis in form of high frequency discharge and chronic denervation potentials on voluntary effort. The EMG of the right leg and some muscles of the arms was not pathological with the exception of the signs of the radicular lesion of the extensor longus, extensor digitorum brevis and triceps surae muscles. The electroneurographic examination revealed a distal motor latency of 8.4 msec for the left and of 4.3 msec for the right deep peroneal nerve. The nerve conduction velocities were within normal ranges. Because of these findings, a partial left anterior tarsal tunnel syndrome with isolated compression of the motor branch of the deep peroneal nerve was diagnosed in addition to the old L<sub>5</sub> lesion on the right.

## Discussion

### *1. Complaints of the Patients*

The complaints of medial and anterior tarsal tunnel syndrome are different. While pains on the sole of the foot are mentioned with the medial tarsal tunnel syndrome, which—caused by the direct local irritation of the plantar nerves—often increase during walking, Cases 1 and 2 had the most intense pains at rest, often leading to severe disorder of sleep. Thus the anterior tarsal tunnel syndrome in this relation resembles the carpal tunnel syndrome. Similarities between the

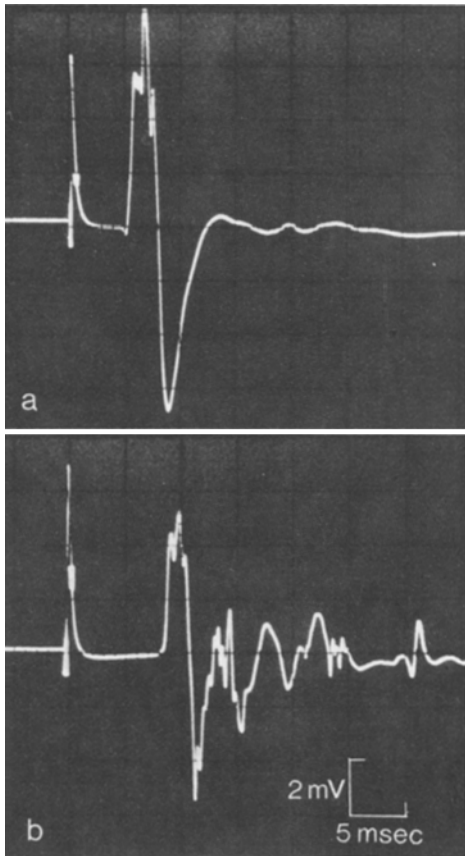


Fig. 3. Distal motor latency of the deep peroneal nerve in Case 3, a right side, b left side

carpal and anterior tarsal tunnel syndrome further consist in the fact that shaking movements bring some relief, at least for a short time. In addition to the pain our patients described a temporary, sometimes longer persisting feeling of numbness on the dorsum of the foot up to the first and second toe corresponding to the sensory area of the nerve, which is also characteristic of other entrapment neuropathies. The complaints manifested themselves especially under conditions which stress the circulation, such as foehn and bodily strain as occurs with other entrapment syndromes. Case 3 had no subjective complaints because no sensory parts of the deep peroneal nerve were afflicted. This form of a partial anterior tarsal tunnel syndrome will usually be found by accident on clinical and especially electromyographic investigation for other reasons, since the patients are without complaints and are not seriously affected by the motor paresis.

## 2. Symptomatology

Clinical signs of advanced nerve entrapment syndromes are atrophy and loss of function of the muscles supplied by the nerves involved. Atrophy and reduced

strength of the extensor digitorum brevis were present in our cases. In the two cases with complete anterior tarsal tunnel syndrome the exclusive lesion of the deep peroneal nerve also was proved by the sensory deficits which existed in the corresponding cutaneous area. Pain upon pressure of the nerve in the region of the entrapment further indicates the underlying disease.

### *3. Electromyographic and Electroneurographic Examination*

The diagnosis will be finally established by finding a raised distal motor latency of the deep peroneal nerve. Compared to the patient of Marinacci, who found values at 9.5 and 11.2 msec, our cases also demonstrated a remarkable lengthening of the latencies with values at 16.1, 7.0 and 8.4 msec (mean  $\pm$  s. d. of 60 healthy individuals  $4.02 \pm 0.7$  msec, range 2.8—5.4 msec). The nerve conduction velocity of the deep peroneal nerve was normal in Cases 1 and 3 as in that of Marinacci; in Case 2 it was—as the other nerve conduction velocities of the lower extremities—a little decreased because of the additional polyneuropathy. Electromyographically, pathological spontaneous activity in form of fibrillation potentials, positive sharp waves or high frequency discharge are to be expected signs of active nerve compression, as found by us and by Marinacci. In addition, according to the duration of the compression, there appear signs of chronic denervation in the extensor digitorum brevis, even with a massive discharge pattern as in Case 2. In view of the distal motor latency as well as of the electromyographic state, no abnormalities are to be expected in cases of a partial anterior tarsal tunnel syndrome with an isolated lesion of the sensory part of the deep peroneal nerve.

### *4. Etiology*

Previous distortions or fractures in the region of the tarsus are often the cause of the medial tarsal tunnel syndrome, less often a ganglion, exostosis, circulatory edema, sudden loss of weight and stress resulting from long walks, but in many cases the etiology remains unclear. The possible causes of the anterior tarsal tunnel syndrome should be similar. It seems however, as emphasized by Marinacci, that the wearing of tight shoes is an especially important cause in these cases. Mumenthaler also mentions tight shoes as etiological factor for pressure lesions of sensory nerves on the dorsum of the foot. In Case 1 local irritation by repeated hematomas of the dorsum pedis and shoes, tightly laced to prevent spraining of the right foot, are probably the cause of compression of the deep peroneal nerve. In Cases 2 and 3 no direct support is given to the assumption of a mechanical irritation. But it seems noteworthy that our three patients and that of Marinacci were females, in whom a chronic nerve compression due to wearing non-physiological shoes is more likely than in males. In Case 2 the coincidence of renal disease, treated with nitrofurantoin, and the beginning of the complaints is remarkable. The interval between first taking the medicine and the complaints is very short, but there are descriptions of cases, in which even after a shorter latency and after smaller doses of nitrofurantoin, toxic polyneuropathies appeared [15]. The manifestation of latent entrapment neuropathy in the tarsal region, possibly caused by renal edema, in the course of a generalized lesion of

peripheral nerves caused by nitrofurantoin therapy, must be considered seriously in this case.

### 5. *Differential Diagnosis*

Weakness of dorsal flexion of the toes and atrophy of the extensor digitorum brevis could lead—especially in connection with severe pain—to the assumption of a radicular syndrome L<sub>5</sub>—S<sub>1</sub>. The non-radicular pattern of sensory deficit, which, on the contrary, corresponds exactly to the sensory area of the deep peroneal nerve, the absence of Laségue's sign on clinical examination as well as normal function of the remaining muscles, especially the extensor hallucis longus, should establish the diagnosis. Further in differential diagnosis a proximal paresis of peroneal nerve, caused by pressure in the region of the head of the fibula, must be excluded; this is possible by finding a normal clinical and electromyographic state in the anterior tibial and peroneal muscles. Difficulties could exist in the differentiation of a beginning polyneuropathy; here in most cases the distinct unilaterality (although one should always think of a possible bilateral anterior tarsal tunnel syndrome as in Marinacci's case) as well as the lack of a participation of other muscles than the extensor digitorum brevis, should lead to the diagnosis. In Case 2 a special diagnostic difficulty consisted in the coincidence of an additional polyneuropathy, so that the right diagnosis was found late. A beginning motor system disease could pose diagnostic difficulties with a partial anterior tarsal tunnel syndrome like our Case 3, but the distinct prolongation of the distal motor latency will clarify the diagnosis. Neural progressive muscular atrophy must be excluded because of the typical symmetrical paresis with massive delay of the nerve conduction velocities. Peripheral vascular disease as a possible etiological factor of pains of the foot is to be differentiated from anterior tarsal tunnel syndrome because of the lack of neurological deficit. Pains of static origin as well as the pain of Morton's syndrome are more to be differentiated in relation to the medial tarsal tunnel syndrome.

### 6. *Therapy*

Conservative treatment is indicated at first by avoiding too great stress to the ligaments of the tarsal region by long walks, avoiding tight shoes, elevating the lower extremities at night, antiedematous medicaments or, eventually, local injection of cortisone. In the case of Marinacci the wearing of sensible shoes with a low heel alone brought full remission within 4½ months. If conservative therapy fails an operative revision with division of the compressing ligaments and with neurolysis should be carried out, as is done for the medial tarsal tunnel syndrome, where Mosimann [11] saw full recovery in 16 of 31 operated patients and partial recovery in 11 further patients.

### References

1. diStefano, V., Sack, J. T., Whittaker, R., Nixon, J. E.: Tarsal tunnel syndrome. *Clin. Orthop.* **88**, 76—79 (1972)
2. Edwards, W. G.: The tarsal tunnel syndrome. *J. Amer. med. Ass.* **207**, 716—720 (1969)

3. Glatzel, W., Grünes, J.-U.: Klinik und Therapie des Tarsaltunnelsyndroms. Dtsch. Ges. wesen **27**, 2432—2436 (1972)
4. Goodgold, J., Kopell, H. P., Spielholz, N. I.: The tarsal tunnel syndrome. Objective diagnostic criteria. New Engl. J. Med. **273**, 742—745 (1965)
5. Keck, C.: The tarsal tunnel syndrome. J. Bone Joint Surg. **44A**, 180—184 (1962)
6. Lam, S. J. S.: A tarsal tunnel syndrome. Lancet 1962, ii, 1354—1355
7. Lam, S. J. S.: Tarsal tunnel syndrome. J. Bone Joint Surg. **49B**, 87—92 (1967)
8. Mann, R. A.: Tarsal tunnel syndrome. Orthop. Clin. North Amer. **5**, 109—115 (1974)
9. Marinacci, A. A.: Neurological syndromes of the tarsal tunnels. Bull. Los Angeles neurol. Soc. **33**, 90—100 (1968)
10. Marinacci, A. A.: Applied Electromyography. Philadelphia: Lea & Febiger 1968
11. Mosimann, W.: Das Tarsaltunnelsyndrom. Klinik und Ergebnisse der operativen Therapie anhand von 39 eigenen Beobachtungen. Schweiz. Arch. Neurol. Neurochir. Psychiat. **105**, 19—64 (1969)
12. Mumenthaler, M., Probst, Ch., Mumenthaler, A., Weber, B. G., Schnyder, J.: Das Tarsaltunnelsyndrom. Schweiz. med. Wschr. **94**, 373—382 (1964)
13. Mumenthaler, M., Schliack, H.: Läsionen peripherer Nerven. 3. Auflage, Stuttgart: Thieme 1977
14. Ruprecht, E. O.: Befunde bei Neuropathien. In: Hopf, H. C., Struppler, A. (Hrsg.): Elektromyographie. Stuttgart: Thieme 1974
15. Voigt, K., Manz, F.: Atypische toxische Polyneuropathie nach Nitrofurantoin. Nervenarzt **40**, 443—445 (1969)

*Received June 16, 1977*