

Porous Polyethylene and Proplast: Their Behavior in a Bony Implant Bed*

Alexander Berghaus¹, Günther Mulch², and Michael Handrock¹

¹HNO-Klinik und Poliklinik (Leiter: Prof. Dr. D. Zühlke), Klinikum Steglitz der Freien Universität Berlin, Hindenburgdamm 30, D-1000 Berlin 45

²HNO-Klinik und Poliklinik (Leiter: Prof. Dr. E. R. Kastenbauer), Klinikum Charlottenburg der Freien Universität Berlin, Spandauer Damm 130, D-1000 Berlin 19

Summary. A comparative animal study showed that, after implantation in skull defects in guinea pigs, porous high-density polyethylene (PHDPE) was substantially better anchored in the bone than Proplast, and had greater stability of form and structure. In Proplast, ingrowth of fibrous tissue caused partial structural dilatation and fragmentation, which could limit its suitability for use in reconstructive surgery.

Key words: PHDPE – Proplast – Bone – Animal experiment

The requirements of implants and grafts in reconstructive surgery include: adequate availability, problem-free sterilization, good formability, and form stability, good tissue tolerance and a low level of resorption. In addition, stable anchorage is necessary especially for bony implant beds.

So far, no available material – not even autogenous bone or cartilage – has fulfilled all these requirements *at one time*. Experimental and clinical investigations in this field indicate that, in principle, various porous synthetic materials are suitable for cartilaginous and osseous structures [1, 2, 5, 6, 10, 13, 18]. Porous polyethylene has been used for reconstruction of cartilaginous structures [1, 2, 14–16], but should also be suitable for bony structures, especially in light of the fact that ingrowth of bone into the pores of this material has been described repeatedly [6, 9–12, 19–21].

In the present study, we chose to do a comparison with Proplast, which is also a recently developed porous material commercially available for use in reconstructive surgery.

* Presented in part at the 54th Annual Meeting of the Deutsche Gesellschaft für Hals-Nasen-Ohren-Heilkunde, Kopf- und Halschirurgie, Travemünde, 1983

Translated from the German by Randall A. Condra

Offprint requests to: Alexander Berghaus, MD (address see above)

The primary purpose of the comparative animal experiments was to gain information about the stability of form and structure of the two materials after implantation in a bony bed in the skull.

Materials and Methods

Porous Polyethylene

Porous high-density polyethylene (PHDPE; Ruhrchemie AG, Oberhausen, FRG) is a sintered synthetic which is more elastic than the rather brittle ceramics and is more chemically resistant than porous metals. For the sintering process, a powder is used which is made from low-pressure polyethylenes with a relatively broad fusion range. This makes it possible to produce plates and tubes as well as pieces with special profiles and shapes, which can then be sawed, drilled, milled, cut, stamped, etc. and also fused or further re-formed thermoplastically. Density is about 0.6 g/cm^3 and porosity 40% [4]. Pore size ranges between 40 and $150 \mu\text{m}$, but can be $200 \mu\text{m}$ and more.

In principle, sterilization in the autoclave is possible. However, because thermoplastic deformation begins at about 110°C , we preferred to use gamma or gas sterilization.

Proplast

Proplast I consists of Teflon fluorocarbon polymer and carbon fibers, which give it a grey color (Fig. 1). Proplast II, which is now available as well, contains aluminium fibers instead of carbon fibers and is white. Porosity is 70%–90% and pore size is between 100 and $400 \mu\text{m}$ (manufacturer's data). The material is easily compressible (which can close the pores); it can be cut easily and is somewhat more brittle than porous polyethylene. The manufacturer (Vitek Inc., Houston, Texas) offers prefabricated implants, among other things for augmentation in the areas of the chin, the cheekbone and the bridge of the nose.

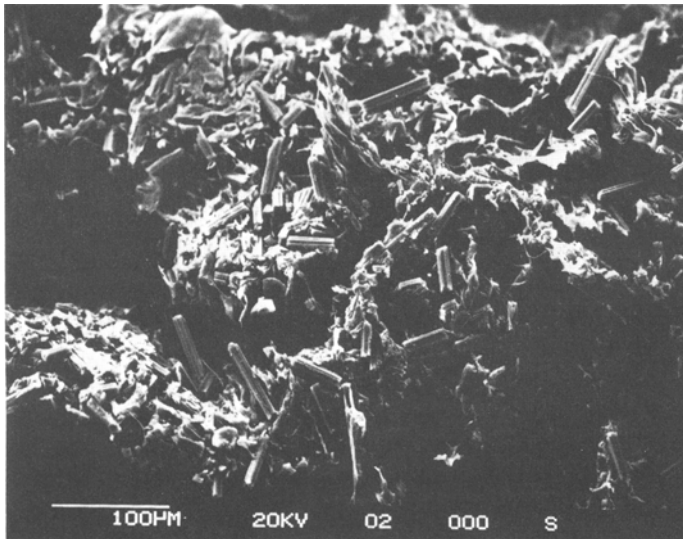


Fig. 1. Proplast I. Carbon fiber fragments embedded relatively loosely in synthetic ground substance. Scanning electron microscope, approx. $\times 200$

Furthermore, for reconstruction of the auditory ossicle chain, one can purchase alloplastic ossicles comparable to those made of porous polyethylene which are already on the market (manufacturer: Richards, Memphis, Tennessee). Comparisons of the two materials for use in the replacement of auditory ossicles can be found elsewhere [e.g., 7, 8, 17]. Proplast can be sterilized in an autoclave.

The animals used in the tests were guinea pigs weighing 300–600 g.

Under general anesthesia, predefined defects were milled into the calotte (diameter: 7 mm) and lower jaw ($5 \times 2 \times 2$ mm). In addition, the periosteum was lifted from the nasal dorsum. The defects were filled with synthetic implants of exactly corresponding size (calotte: 7 mm diameter, 1 mm thick; lower jaw: $5 \times 2 \times 2$ mm). A $9 \times 3 \times 1$ mm subperiosteal implant was placed on the nasal dorsum (Fig. 2). After a maximum observation period of 6 months, the implants and implant beds were embedded in methacrylate and stained according to Giemsa.

Evaluations were made for 55 porous polyethylene and 55 Proplast implants.

Quantitative determination of bone ingrowth into porous polyethylene is impaired by a number of difficulties [10]. We restricted ourselves to a determination of the percentage of ossification, because the main concern of this study was the stability of form and structure of the implants.

The second of three histological sections through the center of the implant served as the basis for evaluation of the degree of ossification of the pores. We recorded whether the pores recognizable in the histological section were 25%, 50%, 75%, or more than 75% filled with newly formed bone.

Results

It became clear that porous polyethylene stimulated new formation of bone substantially better than Proplast. With Proplast, even after 6 months, there was no case of more than 25% of the pore volume being filled with bone. However, with Porous polyethylene, between 50% and 75% ossification was already visible in five of 14 implants after only 1 month. After 3 months, ossification was already above 50% in 14 of 19 implants, of which seven were over 75%. However, there was no further improvement in this situation after 6 months (8 of 18 implants over 50%, of which 5 were over 75%).

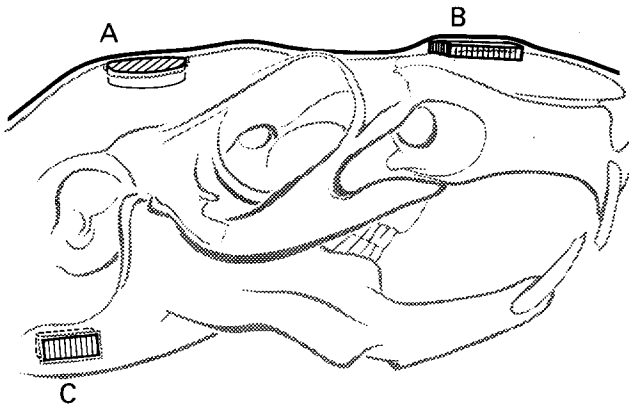


Fig. 2. Selected implant beds on the guinea pig skull. A, circular defect in the center of the calotte extending to the dura; B, subperiosteal pocket without bone defect; C, block-shaped bone defect in the lower jaw




Fig. 3. Surface of porous high-density polyethylene (PHDPE) cut with electric saw. The pores are closed. Scanning electron microscope, approx. $\times 200$




Fig. 4. Surface of PHDPE cut manually with a sharp knife. Open pores. Scanning electron microscope, approx. $\times 200$

Bone ingrowth was more marked from the narrow side of the implant, an observation which was also made by Handrock [9]. Examining the surface of the implants with a scanning electron microscope provided an explanation for this fact: the fast rotary saws used to cut the implants to size developed high temperatures, which caused the pores on the surface to fuse (Fig. 3). Therefore,

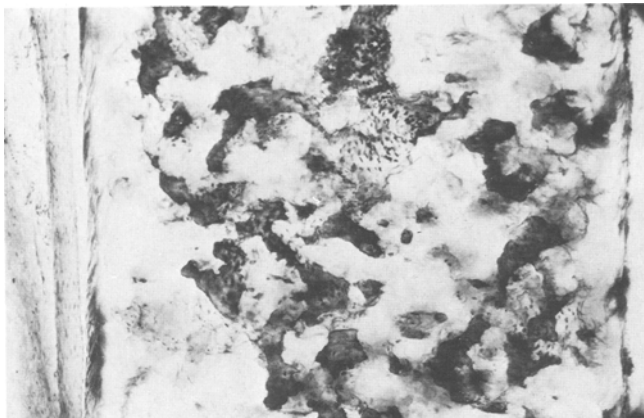


Fig. 5. PHDPE 6 months after implantation in the calotte of the guinea pig. Complete bony interpenetration of the pore system. Giemsa

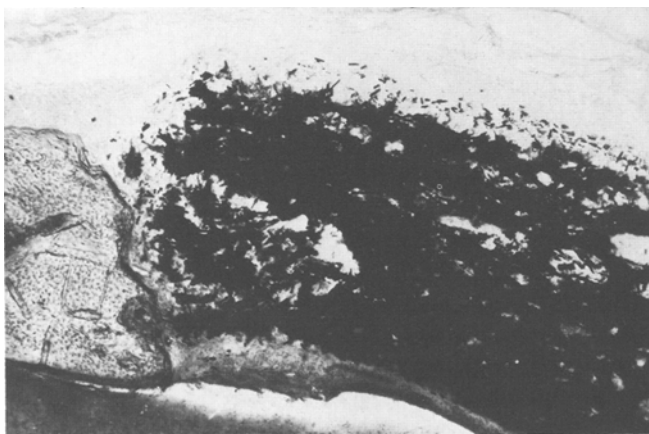

Fig. 6. Proplast 6 months after implantation in the calotte of the guinea pig. No incorporation of bone; formation of cystic cavities; deformation of the synthetic material. The edges appear “frayed”. Giemsa

in growth of tissue was no longer possible there, in contrast to the narrow sides of the implants, which had been cut manually. This permits the conclusion that ossification is more marked when fusion of pores on the surface of such implants is avoided by shaping them with sharp knives only instead of using fast rotary milling equipment (Fig. 4). However, even under the conditions of this study, some porous polyethylene implants showed ingrowth of bony tissue through their entire breadth (Fig. 5).

In contrast, with Proplast I, there was usually no newly formed bone, but only unspecific granulation tissue, and this tended to form cystic cavities in larger pores (Fig. 6). This should not be confused with the vessels which were occasionally recognizable in the ossified pores of PHDPE. Spector et al. [21]




Fig. 7. PHDPE 3 months after implantation on the bridge of the nose in guinea pigs. Sinking below the original surface level (*marked line*); encasement by newly formed bone (*b*). No penetration into the nasal cavity. Implant retains its form. Giemsa

attributed the low degree of bone ingrowth in Proplast to too narrow interconnections between the pores.

However, besides ossification of the pores, another mechanism observed in both synthetic materials was important for anchorage of the implants in the implant bed: in the implants in the calotte and lower jaw as well as the subperiosteal grafts onto the bridge of the nose, the implant was surrounded by tongue-shaped areas of bone tissue advancing along the surface of the graft. This process was much more marked in polyethylene than in Proplast. The contact between the newly formed bone lamellae and the implant surface was in part very close and immediate. On the other hand, there was occasionally a layer of fine connective tissue between the synthetic material and the bone. The enclosure described was especially marked on the surfaces of the calotte implant facing the outer skin and dura, respectively, as well as in the blocks implanted under the periosteum of the bridge of the nose. Furthermore, these last implants were regularly found to sink about 0.5 mm below the surface of the nasal bone (Fig. 7). However, none of these grafts penetrated the main nasal cavity or perforated the outer skin. In combination with the described formation of a surrounding wall of bone, we interpret this as a marked tendency of the bony implant bed to integrate the synthetic material.

Assessment of Form Stability

PHDPE. Except for slight bending in the longitudinal axis of the implants, the material retained its predetermined form macroscopically and histologically. With only a few exceptions, the corners and edges of the blocks were neither deformed nor rounded; signs of resorption were not observed (Fig. 8). Form and structure were even retained in the implants which sank into the nasal bone (Fig. 7).

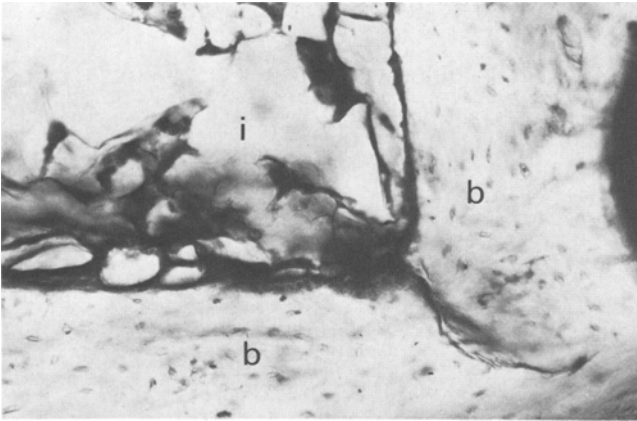


Fig. 8. PHDPE 3 months after implantation in the calotte. Bony encasement of the edge without loss of form. Close contact of the surfaces (*i* = implant; *b* = bone). Giemsa

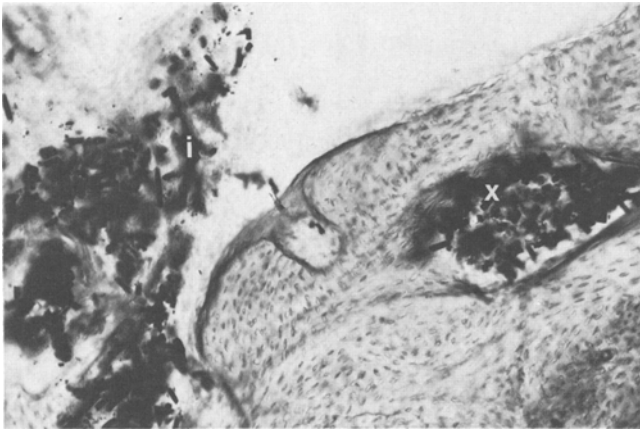


Fig. 9. Proplast 3 months after implantation in the calotte: structural deterioration of the synthetic material (*i*, implant). The material appears in bone marrow cavities (*x*). Giemsa

Proplast I. The carbon fiber fragments are embedded relatively loosely in the synthetic ground substance of the Teflon fluorocarbon polymer (Fig. 1). As we have also demonstrated for Proplast II with aluminum fibers [2], histological examination shows that the material loses varying amounts of its fibers. These fibers are then dispersed along the periphery, but are either embedded there without irritation or transported further. This situation leads to a loosening of the structure of the entire implant, which is reflected in deformation and fragmentation. Thus, we have observed substantial deformation in almost all Proplast implants. Beyond that, surface scratches are an almost regular finding. Furthermore, ingrowing tissue causes splitting of the edges, which then appear frayed (Fig. 6). For Proplast, the clearest expression of material degradation is

the appearance of fragments of the synthetic material in neighboring bone marrow cavities (Fig. 9).

The behavior described confirms the impression existing before implantation that the material was somewhat brittle. The present study could not answer the questions about possible undesirable effects resulting from the long-term presence of dispersed particles of synthetic material and carbon fiber.

Two calotte implants were rejected after 3 months. Two purulent infections were observed.

Discussion

The greater stability of porous polyethylene compared to Proplast was confirmed 6 months after implantation: the polyethylene implants retained their form almost completely, while Proplast was destabilized by the host tissue, partially fragmented, and deformed.

When predefined, artificially created defects are filled with either of the two synthetics, the bony implant bed reacts in two ways: with ingrowth of newly formed bone into the implant (PHDPE) and with encasement or encapsulation. However, only with PHDPE does this lead to adequate bony anchorage and stabilization in the predetermined form. With Proplast, the procedure is accompanied by deformation of the implant. In our opinion, this limits the suitability of Proplast for reconstructive facial surgery. With both synthetics, subperiosteal implantation on the bridge of the nose leads to "wandering" in the direction of the nasal cavity. This observation can be interpreted as a tendency of the bone to incorporate the material, because there is no penetration of the main nasal cavity, and the implant becomes anchored in the bone by simultaneous bone ingrowth and encasement. Thus, especially the form-stable PHDPE could be suitable for correction, e.g., of a saddle nose, in spite of the tendency to sink below the bone surface.

Both of the synthetic materials examined can be viewed as relatively safe from the danger of infection.

Based on the present study, porous polyethylene was selected for clinical use in correcting defects of the facial skull. In two patients with defects of the forehead and eye socket, the results were subjectively and objectively satisfactory after 1.5 and 2 years, respectively [3].

Acknowledgements. We thank the Institute of Pathology, Klinikum Steglitz, Free University of Berlin (Provisional Director: Prof. U. Gross) for assisting in the evaluation of the histological preparations.

References

1. Berghaus A, Axhausen M, Handrock M (1982) Zur Verwendbarkeit von Kunststoffen bei der Rekonstruktion der Ohrmuschel. *Arch Otorhinolaryngol* 235: 622–625
2. Berghaus A, Axhausen M, Handrock M (1983) Poröse Kunststoffe für die Ohrmuschelplastik. *Laryngol Rhinol Otol* 62: 320–327

3. Berghaus A, Mulch G, Handrock M (1983) Zur Verwendbarkeit von porösem Polyäthylen für die Korrektur von Schädeldefekten. *Arch Otorhinolaryngol* (in press)
4. Berzen J, Braun G, Spengler H (1976) Poröses Polyäthylen. *Chem Tech* 5: 351–353
5. Brown BL, Neel HB III, Kern EB (1979) Implants of Supramid, Proplast, Plasti-Pore, and Silastic. *Arch Otolaryngol* 105: 605–609
6. Cestero HJ Jr, Salyer KE, Toranto IR (1975) Bone growth into porous carbon, polyethylene, and polypropylene prostheses. *J Biomed Mater Res* 9: 1–7
7. Chüden HG (1978) Über den Wiederaufbau der Gehörknöchelchenkette mit Hilfe einer Kunststoffprothese (Shea-TORP). *HNO* 26: 57–59
8. Fisch U (1978) Zur Rekonstruktion der Gehörknöchelchenkette. *HNO* 26: 53–56
9. Handrock Ch (1979) Tierexperimentelle Untersuchungen über die Verwendbarkeit eines neuen porösen Polyäthylens im Mittelohr. Inaugural Dissertation, Berlin
10. Klawitter JJ, Bagwell JG, Weinstein AM, Sauer BW (1976) An evaluation of bone growth into porous high density polyethylene. *J Biomed Mater Res* 10: 311–323
11. Kozinn SC, Hedley A, Kim W, Urist M (1982) Observations on bone ingrowth into bone morphogenetic protein impregnated porous polyethylene implants. *Orthop Trans* 6: 273
12. Mayer RD, Moyle DD, Sauer BW (1983) Fracture of porous polyethylene-bone composite. *J Biomed Mater Res* 17: 59–70
13. Neel HB III (1983) Implants of Gore-Tex. *Arch Otolaryngol* 109: 427–433
14. Sauer BW (1976) Correction of faulty ear carriage in the dog with porous polyethylene implants. *Vet Med Small Anim Clin* 71: 1071–1075
15. Sauer BW, Lade RB (1982) Porous high density polyethylene-autogenous tissue tracheal prosthesis. *Trans Am Soc Artif Intern Organs* 28: 369–373
16. Senechal G, Mamelle G, Rodriguez J, Senechal B (1981) Reflexions sur la reconstruction du pavillon de l'oreille. *Ann Oto-Laryngol (Paris)* 98: 367–370
17. Shea JJ (1977) Über die Verwendung von Proplast- und Plastipore-Implantaten bei der Tympanoplastik. *HNO* 25: 96–98
18. Skinner HB, Shackelford JF, Lin HJ, Cutler AD (1979) Tensile strength of bone (bone/porous polyethylene) interface. *Biomater Med Devices Artif Organs* 7: 133–140
19. Spector M, Flemming WR, Sauer BW (1975) Early tissue infiltrate in porous polyethylene implants into bone: a scanning electron microscope study. *J Biomed Mater Res* 9: 537–542
20. Spector M, Flemming WR, Kreutner A (1976) Bone growth into porous high-density polyethylene. *J Biomed Mater Res* 10: 595–603
21. Spector M, Harmon SL, Kreutner A (1979) Characteristics of tissue growth into proplast and porous polyethylene implants in bone. *J Biomed Mater Res* 13: 677–692

Received February 14, 1984/Accepted March 10, 1984