

**THE RELATIONSHIPS BETWEEN CERVICAL  
VERTEBRAL MATURATION AND DENTAL  
CALCIFICATION AMONG MALAYS**

**AHMAD SALIM NASSAR**

**UNIVERSITI SAINS MALAYSIA**

**2008**

**THE RELATIONSHIPS BETWEEN CERVICAL  
VERTEBRAL MATURATION AND DENTAL  
CALCIFICATION AMONG MALAYS**

**by**

**AHMAD SALIM NASSAR**

**Thesis submitted in fulfilment of the requirement  
for the degree of  
Master of Science**

**September 2008**

## ACKNOWLEDGEMENT

First, I thank Allah the most compassionate and the most merciful whose blessings have helped me throughout, until the completion of this dissertation.

I wish to express my greatest appreciation and gratitude to my supervisor **Dr. Rozita Hassan**, for her persistent motivation, support, great knowledge of clinical work and leadership throughout my research project.

I express my sincere and special gratitude to my co-supervisors, **Dr. Zainul Ahmad Rajion** and **Dr. Mohd Fadhli Khamis** for their guidance, great knowledge, continuous support and advice throughout my study. I would like to extend my thanks to **Dr. Mohd Ayub Sadiq** for his expert analytical and mathematical contributions to this project.

My heartiest thanks go to my **parents**, my dedicated **wife** and to my two beautiful children **Rand** and **Khaled**, without whom, my postgraduate studies would not have been possible.

My respect and thanks goes to all the staff of the School of Dental Sciences- USM especially **W.Nor Azlin W.Azlan**, **Faridah Mohamad**, **Haizan Hassan**, and **Firdaus Bin Daud** for their help and support. I also extend my grateful appreciation and thanks to my colleagues, and friends for their friendship and support.

## TABLES OF CONTENTS

ACKNOWLEDGEMENT .....	ii
TABLES OF CONTENTS.....	iii
LIST OF TABLES .....	vii
LIST OF FIGURES .....	ix
LIST OF ABBREVIATIONS .....	x
ABSTRAK.....	xi
ABSTRACT.....	xiii
<b>CHAPTER ONE - INTRODUCTION .....</b>	<b>1</b>
1.1 Background of the study .....	1
1.2 Objectives.....	5
1.2.1 General .....	5
1.2.2 Specific.....	5
1.2.3 Hypotheses .....	5
<b>CHAPTER TWO - LITERATURE REVIEW .....</b>	<b>6</b>
2.1 Facial growth indicators .....	6
2.2 Somatic maturity .....	6
2.3 Sexual maturity .....	8
2.4 Skeletal maturity .....	9
2.4.1 Hand-Wrist bone .....	9
2.4.2 Cervical vertebral maturation.....	13
2.5 Dental maturity .....	26

2.5.1 Tooth calcification methods.....	28
2.5.2 Timing of Demirjian’s tooth calcification stages.....	33
2.6 Relationship between skeletal and dental maturity.....	34
2.7 Factors influencing skeletal and dental maturity .....	40
2.7.1 Genetic .....	40
2.7.2 Systemic diseases or medical syndromes .....	40
2.7.3 Environmental.....	41
2.7.4 Sex differences.....	42
<b>CHAPTER THREE - METHODOLOGY.....</b>	<b>44</b>
3.1 Study design.....	44
3.2 Population and sample .....	44
3.3 Sampling frame.....	44
3.3.1 Inclusion criteria .....	44
3.3.2 Exclusion Criteria .....	45
3.4 Sampling method .....	45
3.5 Sample size calculation.....	47
3.6 Research Tools.....	48
3.7 Data collection procedure .....	49
3.7.1 Cervical vertebral maturation analysis.....	50
3.7.2 Dental calcification analysis .....	54
3.8 Data analysis .....	58
3.9 Reproducibility of the measurements .....	59
3.10 Ethical approval .....	60

<b>CHAPTER FOUR - RESULTS</b> .....	61
4.1 Reproducibility of the measurements.....	61
4.2 Sample profile .....	61
4.3 Chronological age of cervical vertebral maturation stages.....	63
4.4 Chronological age of dental calcification stages.....	64
4.5 Relationships between the stages of cervical vertebral maturation and dental calcification stages .....	66
4.5.1 Percent distribution of dental calcification stages at each cervical maturatio stages.....	66
4.5.2 Spearman correlation coefficient .....	72
 <b>CHAPTER FIVE - DISCUSSION</b> .....	 74
5.1 Sample profile .....	74
5.2 Reliability of the method.....	74
5.3 Relationship between cervical vertebral maturation and dental calcification.....	75
5.4 Chronological age of cervical vertebral maturation stages.....	78
5.5 Chronological age of dental calcification stages.....	79
5.6 Clinical implications .....	82
5.7 Limitations of the study .....	83
 <b>CHAPTER SIX - CONCLUSIONS AND RECOMMENDATIONS</b> .....	 84
6.1 Conclusions.....	84
6.2 Recommendations for further studies .....	85

REFERENCES.....	86
APPENDICES .....	92
APPENDIX A: ETHICAL APPROVAL .....	92
APPENDIX B: CONSENT FORMS .....	93
APPENDIX C: ACADEMIC ACTIVITIES.....	99

## LIST OF TABLES

	Page
Table 3.1	Five stages of cervical vertebral maturation 53
Table 3.2	Eight stages of dental calcification 55
Table 4.1	kappa value for intra-examiner reliability 61
Table 4.2	kappa value for inter-examiner reliability 61
Table 4.3	Distribution of samples according to age for males 62
Table 4.4	Distribution of samples according to age for females 62
Table 4.5	Mean and (SD) of the chronological age for each cervical vertebral maturation stage for males 63
Table 4.6	Mean and (SD) of the chronological age for each cervical vertebral maturation stage for females 63
Table 4.7	Percent distributions of dental calcification stages for males 64
Table 4.8	Percent distributions of dental calcification stages for females 65
Table 4.9	Mean (SD) of chronological age for each tooth calcification stage for males 65
Table 4.10	Mean (SD) of chronological age for each tooth calcification stage for females 66
Table 4.11	Percent distribution of dental calcification stages at CVMS I for males 67
Table 4.12	Percent distribution of dental calcification stages at CVMS II for male 67
Table 4.13	Percent distribution of dental calcification stages at CVMS III for males 68
Table 4.14	Percent distribution of dental calcification stages at CVMS IV for males 68
Table 4.15	Percent distribution of dental calcification stages at CVMS V for males 69



Table 4.16	Percent distribution of dental calcification stages at CVMS I for females	70
Table 4.17	Percent distribution of dental calcification stages at CVMS II for female	70
Table 4.18	Percent distribution of dental calcification stages at CVMS III for females	71
Table 4.19	Percent distribution of dental calcification stages at CVMS IV for females	71
Table 4.20	Percent distribution of dental calcification stages at CVMS V for females	72
Table 4.21	Correlation coefficients between cervical vertebral maturation and dental calcification stages of Malay males	72
Table 4.22	Correlation coefficients between cervical vertebral maturation and dental calcification stages of Malay females.	73

## LIST OF FIGURES

		Page
Figure 2.1	Velocity curve for height	8
Figure 2.2	Radiographic identification of skeletal maturity indicators	12
Figure 2.3	Anatomical location of skeletal maturity indicators	13
Figure 2.4	Developmental stages of cervical vertebrae	15
Figure 2.5	Cervical vertebral maturation indicators using C3 as guide	17
Figure 2.6	Mandibular growth in each cervical vertebrae maturational	19
Figure 2.7	Areas of cervical vertebral bodies measured on lateral cephalogram	22
Figure 2.8	Stages of tooth calcification according to Nolla	29
Figure 2.9	Stages of tooth calcification according to Moorrees	30
Figure 2.10	Conceptual framework of factors influencing skeletal and dental maturity	43
Figure 3.1	Flow Chart of the study	46
Figure 3.2	Lateral cephalogram and orthopantomogram assessments using VixWin	49
Figure 3.3	Cephalometric landmarks for the quantitative analysis of the morphologic characteristics in the bodies of C2, C3, and C4	52
Figure 3.4	New improved of CVM Method	52
Figure 3.5	Cervical vertebral maturation stages (CVMS) I through (CVMS) V	54
Figure 3.6	Dental calcification stages of Demirjian's method	56

## LIST OF ABBREVIATIONS

C2	Second cervical vertebrae
C3	Third cervical vertebrae
C4	Fourth cervical vertebrae
CVM	Cervical vertebral maturation
CVMI	Cervical vertebral maturational index
CVMS	Cervical vertebral maturation stage
HUSM	Hospital Universiti Sains Malaysia
SD	Standard deviation
SPSS	Statistical Package for the Social Sciences.

## **HUBUNGAN ANTARA PERINGKAT KEMATANGAN VERTEBRA SERVIKAL DAN KALSIFIKASI GIGI DI KALANGAN ORANG MELAYU**

### **ABSTRAK**

Kajian kematangan skeletal adalah penting dalam rawatan ortodontik. Kaedah permatangan vertebra servikal terbukti sebagai satu kaedah yang efektif dalam membuat penilaian pemecutan pertumbuhan remaja bagi setiap pesakit. Tahap kalsifikasi pergigian dicadangkan sebagai satu kaedah yang boleh dipercayai untuk menentukan kematangan gigi. Jika satu perkaitan yang kuat wujud antara kematangan vertebra servikal dengan tahap kalsifikasi pergigian antara orang Melayu, tahap kalsifikasi pergigian boleh digunakan sebagai alat diagnosis tahap satu untuk menilai kematangan skeletal di kalangan orang Melayu. Tujuan kajian ini dijalankan ialah untuk menentukan kronologi umur tahap kematangan vertebra servikal tahap kalsifikasi dan kanin mandibular kiri, premolar pertama dan kedua, dan molar antara pesakit Melayu perempuan dan lelaki. Ia juga bertujuan untuk melihat hubungan antara tahap kematangan vertebra servikal dan kanin mandibular kiri, premolar pertama dan kedua, dan tahap kalsifikasi molar kedua di kalangan pesakit Melayu perempuan dan lelaki. Kajian ini adalah kajian lintang yang melibatkan seramai 215 subjek orang Melayu yang terdiri daripada 92 orang lelaki (umur antara 10-17 tahun) dan seramai 123 orang subjek perempuan (umur antara 8-15 tahun). Kaedah Baccetti et.al (2002) yang menggunakan selafogram lateral digunakan untuk menilai tahap –tahap kematangan vertebra servikal. Tahap-tahap kalsifikasi pergigian dinilai daripada radiograf ortopantomogram mengikut kaedah yang digunakan oleh Demirjian et.al (1973). Susunan kedudukan pekali kolerasi Spearman pula digunakan untuk menilai hubungan kematangan antara vertebra

servikal dengan gigi. Taburan peratusan gigi yang dikaji juga dikira untuk memahami dengan lebih jelas hubungan indeks kematangan vertebra servikal dengan umur gigi. Purata dan sisihan piawai punya umur dalam tahun untuk peringkat kematangan vertebra servikal daripada, CVMS1 ke CVMSV ialah, untuk lelaki 10.92 (SD0.55), 13.11 (SD1.41), 15.32 (SD1.08), 16.38 (SD0.51), dan 16.52 (SD0.42), untuk perempuan 9.77 (SD1.27), 11.14 (SD1.67), 13.17 (SD1.01), 14.30 (SD0.65), dan 14.53 (SD0.23). Purata dan sisihan piawai punya peringkat kalsifikasi H untuk kiri, premolar pertama dan kedua, dan molar kedua ialah lelaki 15.05 (SD1.69), 15.18 (SD 1.58), 15.25 (SD 1.59), dan 15.95 (SD 1.01), perempuan 13.31 (SD 1.32), 13.45 (SD 1.25), 13.54 (SD 1.22), dan 14.06 (SD 0.77). Pekali kolerasi antara kematangan vertebra servikal dengan tahap kalsifikasi gigi adalah signifikan secara statistik dengan julat 0.682 ke 0.772 untuk lelaki dan 0.543 ke 0.727 untuk perempuan. Bagi semua subjek lelaki dan perempuan, urutan korelasi dari terendah ke yang paling tinggi adalah kanin, premolar pertama, premolar kedua, dan molar kedua. Kebanyakan pesakit lelaki (81.5%), dan perempuan (88.2%) tidak habis peringkat kalsifikasi H di CVMS II. Ini menunjukkan bahawa kematangan vertebra servikal dengan tahap kalsifikasi gigi di kalangan orang Melayu memang mempunyai hubung kait. Ini juga mencadangkan bahawa tahap kalsifikasi gigi mungkin boleh digunakan sebagai alat klinikal pertama untuk menentukan kematangan skeletal bagi pesakit Melayu. Namun begitu, kajian lanjut disyorkan untuk sampel yang lebih besar pada masa hadapan.

# **THE RELATIONSHIPS BETWEEN CERVICAL VERTEBRAL MATURATION AND DENTAL CALCIFICATION AMONG MALAYS**

## **ABSTRACT**

Research on skeletal maturation is essential in orthodontics management. The cervical vertebral maturation method has proved to be effective in assessing the adolescent growth spurt in individual patients. Dental calcification stages are proposed as a more reliable method for determining dental maturity. The high association between cervical vertebral maturation and dental calcification stages, revealed that this method to be first level diagnostic tool to assess skeletal maturity in Malay patients. The aims of this study were to determine chronological age of the cervical vertebral maturation stages and left mandibular canine, first and second premolars, and second molar calcification stages among Malay females and males. It is also to investigate the relationship between the stages of cervical vertebral maturation and left mandibular canine, first and second premolars, and second molar calcification stages among Malay females and males. This is a cross sectional study consisted of 215 Malay subjects, 92 subjects were males (age ranged 10-17 years), and 123 subjects were females (age ranged 8-15 years). The stages of cervical vertebral maturation were assessed from lateral cephalogram according to Baccetti *et al.*, (2002) method. The dental calcification stages were assessed from orthopantomogram radiographs according to Demirjian *et al.*, (1973) method. Spearman rank order correlation coefficient was used to assess the relationship between cervical vertebral maturation and dental calcification. For a better understanding of the relationship between cervical vertebral maturation and dental calcification, percent distributions of dental calcification stages at cervical vertebral maturation stages were calculated. The mean and standard deviations of the

chronological age in years for cervical vertebral maturation stages from CVMS1 to CVMSV were, for males 10.92 (SD0.55), 13.11 (SD1.41), 15.32 (SD1.08), 16.38 (SD0.51), and 16.52 (SD0.42) respectively, and for females 9.77 (SD1.27), 11.14 (SD1.67), 13.17 (SD1.01), 14.30 (SD0.65), and 14.53 (SD0.23) respectively. The mean and standard deviations of calcification stage H for canine, first and second premolars, and second molar were in males 15.05 (SD1.69), 15.18 (SD 1.58), 15.25 (SD 1.59), and 15.95 (SD 1.01) respectively, in females were 13.31 (SD 1.32), 13.45 (SD 1.25), 13.54 (SD 1.22), and 14.06 (SD 0.77) respectively. The correlation coefficients between cervical vertebral maturation and calcification stages of the teeth, ranging from 0.682 to 0.772 for male and 0.543 to 0.727 for female, were statistically significant ( $P < 0.01$ ). For the male and female subjects, the sequence of the correlation from lowest to highest was canine, first premolar, second premolar, and second molar. Most of patient's males (81.5%) and females (88.2%) have not completed second molar stage H at the CVMS II. There is a statistically significant relationship between cervical vertebral maturation and dental calcification stages among Malay. This suggests that tooth calcification stages might be used as the first clinical tool to determine skeletal maturity in Malay patients. However, further studies are recommended in a larger sample size.

## CHAPTER ONE

### INTRODUCTION

#### 1.1 Background of the study

An understanding of growth events is important in the practice of clinical orthodontics. Maturational status can have considerable influence on diagnosis, treatment goals, treatment planning, and the eventual outcome of orthodontic treatment. Prediction of both the times and the amounts of active growth, in the craniofacial complex, would be useful to the orthodontist. This is especially true when treatment considerations are based strongly on the facial growth such as the use of extraoral traction, functional appliances, selection of orthodontic retention and orthognathic surgery (Moore *et al.*, 1990).

Many researchers indicated that chronological age is not a reliable indicator to evaluate maturity status of a child (Hunter, 1966, Fishman, 1979, Houston, 1980). As such, the maturity status of a child is best estimated relative to specific stages of physiologic maturity (Demirjian *et al.*, 1985). Physiologic age is estimated by the maturation of one or more tissue systems, and it is best expressed in terms of each system studied. Physiologic age can be estimated by somatic, sexual, skeletal, and dental maturity (Moorrees *et al.*, 1963).

Skeletal maturity refers to the degree of development of ossification in bone. During growth every bone goes through a series of changes that can be seen radiologically. The sequence of changes is relatively consistent for a given bone in every person. The timing of the changes varies because each person has his or her own biologic



clock. There are some exceptions, but the events are reproducible enough to provide a basis for comparison between different persons (Hassel and Farman, 1995).

The hand-wrist radiograph is commonly used for skeletal developmental assessment. The validity of the hand-wrist skeletal maturity in the evaluation of craniofacial growth has been confirmed by numerous studies (Bergersen, 1972, Chapman, 1972, Pileski *et al.*, 1973). However, this method requires an additional radiograph for hand-wrist in addition to the routine radiographic records required for orthodontic patients such as lateral cephalogram and orthopantomogram.

Recently, a series of investigations performed in different parts of the world have confirmed the validity of the cervical vertebral maturation (CVM) method, mostly by comparing it with the hand and wrist method (Hassel and Farman, 1995, San Roman *et al.*, 2002, Gandini *et al.*, 2006).

The CVM has proved to be effective to assess the adolescent growth peak in both body height and mandibular. The ossification events in the cervical vertebrae begin during fetal life and continue until adulthood. Therefore, maturational changes can be observed in the vertebrae during this interval, which covers the period when orthodontic treatment is typically performed in the growing patient. The CVM method eliminates radiation exposure for orthodontic patients and utilizes the lateral cephalogram, a film routinely used for diagnosis and treatment planning in orthodontic clinics (Baccetti *et al.*, 2002).

Baccetti *et al.* (2002) presented the new CVM method with five maturational stages Cervical Vertebral Maturation Stage (CVMS) I through (CVMS) V, instead of Cvs 1 through Cvs 6 in the former CVM method. The peak in mandibular growth occurs between CVMS II and CVMS III, and it has not been reached without the attainment of both CVMS I and CVMS II. CVMS V is recorded at least two years after the peak.

However, cervical vertebrae maturation method required longitudinal follow-up for accuracy. Knowing the stage does not allow a clinician to determine the timing of maturation with sufficient accuracy. This is particularly important for females because they have shorter pubertal spurts and complete their growth earlier than males (Ozer *et al.*, 2006). When CVMS I are diagnosed in the individual patient with mandibular deficiency, the clinician can wait at least one additional year for a radiographic reevaluation aimed to start treatment with a functional appliance. As CVMS II represents the ideal stage to begin functional jaw orthopedics (Baccetti *et al.*, 2002). That means orthodontic patient need more than one lateral cephalogram radiograph to assess skeletal maturity. Therefore, any method that could identify skeletal maturity is helpful to eliminate radiations dose for orthodontic patients, especially if the method can be determined without additional radiograph.

Dental maturity can be estimated by the stage of tooth emergence or tooth calcification. The tooth calcification is proposed as a more reliable criterion for determining dental maturation (Demirjian, 1978).

If a strong association exists between CVM method and dental calcification stages, the stages of dental calcification could be used as a first level diagnostic tool to estimate the timing of the adolescent growth spurt in Malays. As dental calcification stages can be assessed from periapical and orthopantomogram radiographs, in dental clinics taking a periapical and orthopantomogram radiographs is more definitive to determine caries and pathology instead of a lateral cephalogram. That is a practical reason for attempting to assess skeletal maturity from tooth calcification (Uysal *et al.*, 2004).

Many researchers have reported significant correlations between skeletal and dental maturity (Krailassiri *et al.*, 2002, Basaran *et al.*, 2007). Others have reported insignificant correlations between skeletal and dental maturity (Green 1961, So, 1997). Racial variations in the relationship between the calcification stages of individual teeth and skeletal maturity have been reported previously (Chertkow, 1980, Mappes *et al.*, 1992).

To date, little is known about this relationship among Malay subjects. The aim of this study was to investigate the relationship between the stages of cervical vertebral maturation and dental calcification among Malays. The findings from this study may establish a valid clinical tool to determine skeletal maturity in Malays by using the stages of dental calcification.

## **1.2 Objectives**

### **1.2.1 General**

To determine the stages of skeletal maturation among Malay subjects by using cervical vertebral maturation and dental calcification.

### **1.2.2 Specific**

1. To determine chronological age of the cervical vertebral maturation stages among Malay female and male.
2. To determine chronological age of left mandibular canine, first and second premolars, and second molar calcification stages among Malay female and male.
3. To investigate the relationship between cervical vertebral maturation stages and left mandibular canine, first and second premolars, and second molar calcification stages among Malay female and male.

### **1.2.3 Hypotheses**

There is a relationship between the stages of cervical vertebral maturation and left mandibular canine, first and second premolars, and second molar calcification stages.

## CHAPTER TWO

### LITERATURE REVIEW

#### 2.1 Facial growth indicators

The human body undergoes dimensional changes throughout life. Stature, for instance, is characterized by an intensive growth during adolescence until about 20 years of age (Forsberg, 1979). Facial growth is closely related to growth of the body as a whole, therefore accelerates considerably during adolescence (Ochoa and Nanda, 2004). Cephalometric studies indicated that the facial growth rate is not constant throughout the development period. The intensity, onset, and duration of the pubertal peak of facial growth have great variations among patients (Silveira *et al.*, 1992).

Therefore, various indicators to evaluate facial growth in orthodontic patients were used; these include somatic, sexual, skeletal, and dental maturity. Strong relationships among indicators imply a concordance of controlling mechanisms, which serve orthodontists in diagnosis and treatment planning. Valid associations also provide a means of prediction, allowing judgments to be based on a single examination. This is particularly important during adolescence when changes in growth rate can influence treatment results (Demirjian *et al.*, 1985).

#### 2.2 Somatic maturity

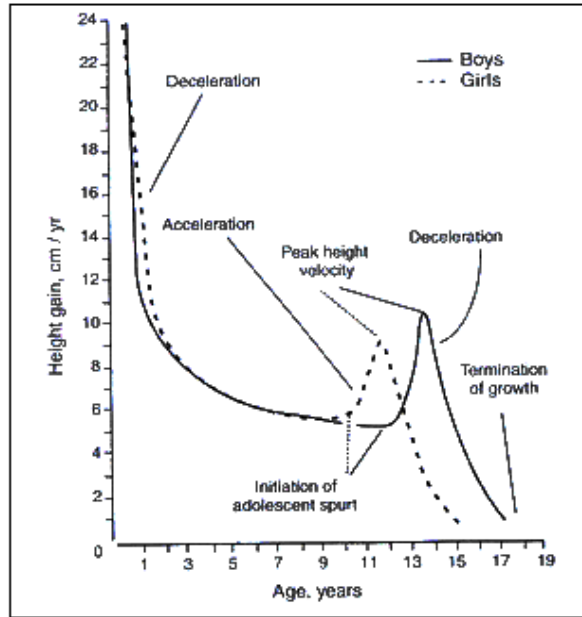
Somatic maturity is recognized by the annual growth increments in height or weight (Krailassiri *et al.*, 2002). The pattern of somatic maturity during the first two decades of human life is often categorized into four intervals infancy, childhood, adolescence, and adulthood Figure 2.1.

First interval is infancy. It is the first year of life but not including the first birthday. Second interval is childhood, which extends from the end of infancy to the start of adolescence. During infancy and childhood, the velocity of somatic maturity is decelerating (Malina *et al.*, 2004).

Third interval is adolescence from about 8 to 19 years in girls and 10 to 22 years in boys. During adolescence the velocity of somatic maturity accelerates, reaches a peak velocity and then decelerates until adulthood is achieved. Fourth interval is adulthood the velocity of somatic maturity decelerating during this interval (Malina *et al.*, 2004).

Bergersen (1972) reported that there is no difference in the onset of the adolescent growth spurt in body height, facial height (Nasion-Menton), or mandibular length (Articulare-Gnathion). Other studies have also shown an association between peak velocity of facial growth and peak velocity of stature during adolescence (Bishara *et al.*, 1981, Lewis *et al.*, 1985).

Unfortunately, peak velocity of stature recognized by several measurements repeated at regular intervals (example, every 3 months) to construct an individual curve of growth velocity, which is not practical in orthodontic clinics (Franchi *et al.*, 2000).



**Figure 2.1 Velocity curve for height (Malina *et al.*, 2004)**

### 2.3 Sexual maturity

The changes of secondary sex characteristics, breast development and menarche in girls, penis and testes (genital) development and voice changes in boys and pubic hair in both sexes are characterized as sexual maturity (Malina *et al.*, 2004).

There are close association between sexual, somatic, and skeletal maturity (Hagg and Taranger, 1982, Demirjian *et al.*, 1985). However, some girls, particularly those who are maturing much earlier or later than their peers, may deliberately give false answers when they are asked whether or not menarche has occurred. In orthodontic clinics, it is not possible to use breast development in girls, and penis and testes (genital) development in boys, because that would require a physical examination. Voice change in boys can be applied only after a serial recording, which is not practical in orthodontic clinics (Hagg and Taranger, 1982).

## **2.4 Skeletal maturity**

The assessment of skeletal maturity is an important method in the evaluation, follow up, and timing of therapy in children with growth disorders, such as constitutional growth retardation and growth hormone deficiency, as well as endocrinological diseases, such as hypothyroidism, congenital adrenal hyperplasia, and precocious puberty (Uysal *et al.*, 2004).

In orthodontic clinics, a common reason to assess skeletal maturity for patients is to evaluate craniofacial growth (Uysal *et al.*, 2004). The hand–wrist and the cervical vertebrae are commonly used to assess skeletal maturity in orthodontic clinics.

### **2.4.1 Hand-Wrist bone**

The ossification events of the hand–wrist have been the most frequently used as skeletal maturity indicator. This is due to many ossification centers available in this area that undergo changes at different times and rates (Flores-Mir *et al.*, 2004).

Two general approaches have been described to assess hand-wrist radiograph (Flores-Mir *et al.*, 2004). The first approach consists of two methods;

1. Greulich and Pyle introduced an atlas as a standard of comparison. The atlas is composed of plates of “typical” hand wrist radiographs at six-month intervals of chronological age. Each bone of the subject’s hand-wrist is compared with the corresponding bones in the atlas, and is assigned an age in months. All ages are averaged yielding the “mean skeletal age” of the individual. In clinical use, this approach is often shortened to a gross assessment to find the best match of the individual with one of the plates.



2. Tanner *et al.* (1983) method compares an individual with radiographic standards of skeletal maturity of “normal” children of similar age and sex. Individual bones are rated using a biological weighted scoring system to assign a skeletal age.

The second general approach uses specific indicators to relate skeletal maturation to the pubertal growth curve. A number of indicators have been described in the literature including onset of calcification of the sesamoid, state of calcification of the hook of the hamate, and staging of the middle phalanges of the third finger (Hunter, 1966, Bjork and Helm, 1967, Chapman, 1972, Bergersen, 1972, Pileski *et al.*, 1973, Houston, 1980, Fishman, 1982).

In this chapter, the system presented by Bjork, and Grave and Brown according to Uysal *et al.* (2004), and Fishman (1982) will be described. The two systems commonly used to assess skeletal maturity in previous studies of relationships between skeletal and dental maturity.

Uysal *et al.* (2004) evaluated skeletal maturation from hand-wrist radiographs, by using nine ossification events according to the systems of Bjork, and Grave and Brown:

Stage 1 (PP2): The epiphysis of the proximal phalanx of the index finger (PP2) has the same width as the diaphysis.

Stage 2 (MP3): Epiphysis of the middle phalanx of the middle finger (MP3) is of the same width as the diaphysis.

Stage 3 (Pisi-H1-R): Pisi, visible ossification of the pisiform. H1, ossification of the hamular process of the hamatum. R, same width of epiphysis and diaphysis of the radius.

Stage 4 (S-H2): S, first mineralization of the ulnar sesamoid bone of the metacarpophalangeal joint of the hamatum. H2, progressive ossification of the hamular process of the hamatum.

Stage 5 (MP3cap-PP1cap-Rcap): During this stage, the diaphysis is covered by the cap-shaped epiphysis. In the MP3cap the process begins at the middle phalanx of the third finger, in the PP1cap at the proximal phalanx of the thumb, and in the Rcap at the radius.

Stage 6 (DP3u): Visible union of epiphysis and diaphysis at the distal phalanx of the middle finger (DP3).

Stage 7 (PP3u): Visible union of epiphysis and diaphysis at the proximal phalanx of the little finger (PP3).

Stage 8 (MP3u): Union of epiphysis and diaphysis at the middle phalanx of the middle finger is clearly visible (MP3).

Stage 9 (Ru): Complete union of epiphysis and diaphysis of the radius.

Fishman (1982) developed a system of Skeletal Maturation Assessment (SMA). The SMA system identifies four stages of the hand–wrist bone ossification Figure 2.2. All found at six anatomical sites located on the thumb, third finger, fifth finger and radius Figure 2.3. He described eleven adolescent skeletal maturation indicators (SMI's) found on these six sites and covering the entire period of adolescent development. The SMI can be arbitrarily divided into periods of accelerating velocity (SMI 1–3), high velocity (SMI 4–7), and decelerating velocity (SMI 8–11).

Stage No. 1 Width of epiphysis as wide as diaphysis:

1. Third finger proximal phalanx (PP3 width).
2. Third finger middle phalanx (MP3 width).
3. Fifth finger middle phalanx (MP5 width).

Stage No. 2 Ossification of:

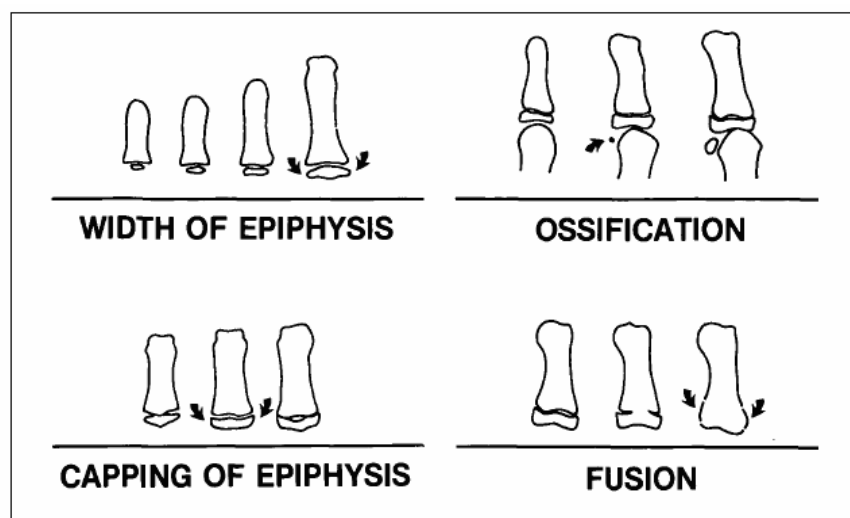
4. Adductor sesamoid of thumb (S).

Stage No. 3 Capping of epiphysis:

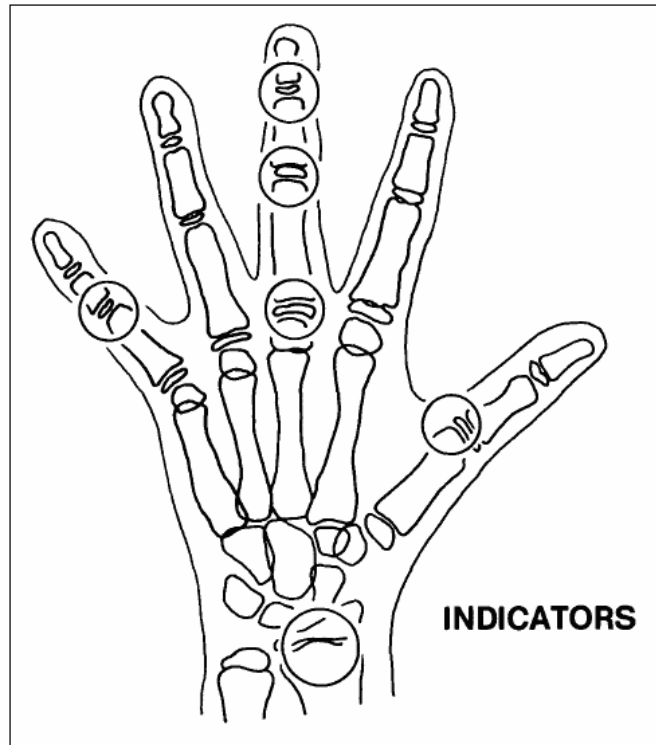
5. Third finger distal phalanx (DP3 cap).
6. Third finger middle phalanx (MP3cap).
7. Fifth finger middle phalanx (MP5 cap).

Stage No. 4 Union of epiphysis and diaphysis:

8. Third finger distal phalanx (DP3u).
9. Third finger proximal phalanx (PP3u).
10. Third finger middle phalanx (MP3u).
11. Radius (Ru).



**Figure 2.2 Radiographic identification of skeletal maturity indicators (Fishman, 1982).**



**Figure 2.3 Anatomical location of skeletal maturity indicators (Fishman, 1982).**

#### **2.4.2 Cervical vertebral maturation**

The first seven vertebrae in the spinal column constitute the cervical spine. The first two, the atlas and the axis, are quite unique; the third through the seventh have great similarity. Many anomalies of the cervical spine do not manifest themselves symptomatically until adolescence or young adulthood, and the orthodontist has the opportunity to detect some of these anomalies. If the progressively degenerative defects can be discerned early, severity of consequences can be diminished. Some anomalies seen in the cervical spines of children and adolescents are fractures, infections, polyarthritis, ankylosis, and ankylosing spondylitis (Hassel and Farman, 1995).

Baccetti *et al.* (2002) mentioned that, the maturational changes in both size and shape of the cervical vertebrae dated back to the first decades of the twentieth century. Todd and Pyle (1928), Lanier, (1939) measured dimensional growth modifications in the cervical vertebrae on lateral radiographs. There are many methods to determine the stages of CVM. In this chapter three methods will be described.

#### **a. Cervical vertebral maturation methods**

According to O'Reilly and Yanniello (1988), Lamparski (1972) created a system for skeletal assessment based on morphological changes in the cervical vertebrae. The method analyzed size and shape changes in the bodies of five cervical vertebrae from the second one through the sixth Figure 2.4. This method included the following stages;

Stage 1(Cvs 1): the inferior borders of the bodies of all cervical vertebrae are flat. The superior borders are tapered from posterior to anterior.

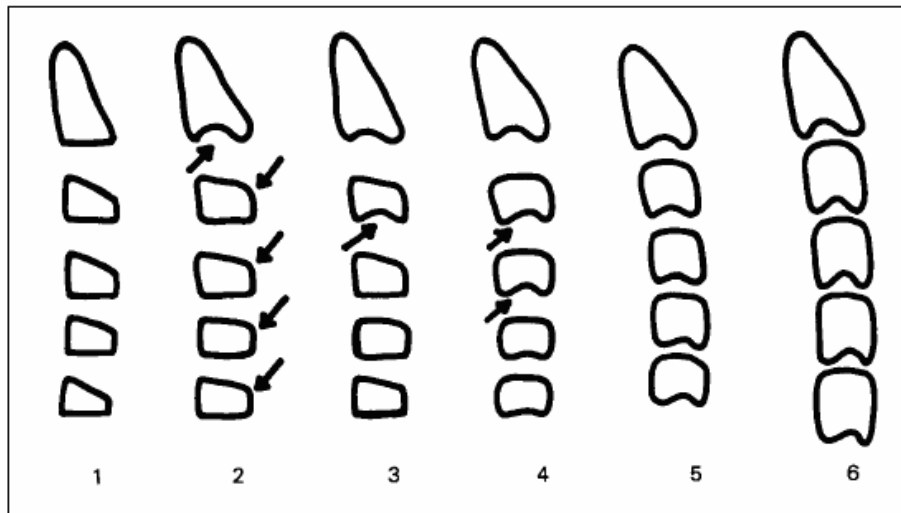
Stage 2 (Cvs 2): a concavity develops in the inferior border of the second vertebra. The anterior vertical height of the bodies increases.

Stage 3 (Cvs 3): a concavity develops in the inferior border of the third vertebra.

Stage 4 (Cvs 4): a concavity develops in the inferior border of the fourth vertebra. Concavities in the lower borders of the fifth and of the sixth vertebrae are beginning to form. The bodies of all cervical vertebrae are rectangular.

Stage 5 (Cvs 5): concavities are well defined in the lower borders of the bodies of all 5 cervical vertebrae. The bodies are nearly square in shape and the spaces between the bodies are reduced.

Stage 6 (Cvs 6): all concavities have deepened. The bodies are now higher than are wide.



**Figure 2.4 Developmental stages of cervical vertebrae (O'Reilly and Yanniello, 1988)**

Hassel and Farman (1995) developed a cervical vertebral maturational index (CVMI). They used the lateral profiles of the second, third and fourth cervical vertebrae from lateral cephalogram radiographs and evaluation hand-wrist radiograph according the system developed by Fishman. The sample size consisted of 11 groups of 10 males and 10 females (220 subjects) aged from 8 to 18 years, from the Bolton-Brush Growth Center at Case Western Reserve University. Eleven SMI (skeletal maturation index) groupings were condensed into six CVMI categories. The authors found the following observations for each category Figure 2.5:

**Category 1** was called INITIATION. This corresponded to a combination of SMI 1 and 2. At this stage, adolescent growth was just beginning and 80% to 100% of adolescent growth was expected. Inferior borders of C2, C3, and C4 were flat at this stage. The vertebrae were wedge shaped, and the superior vertebral borders were tapered from posterior to anterior.

**Category 2** was called ACCELERATION. This corresponded to a combination of SMI 3 and 4. Growth acceleration was beginning at this stage, with 65% to 85% of

adolescent growth expected. Concavities were developing in the inferior borders of C2 and C3. The inferior border of C4 was flat. The bodies of C3 and C4 were nearly rectangular in shape.

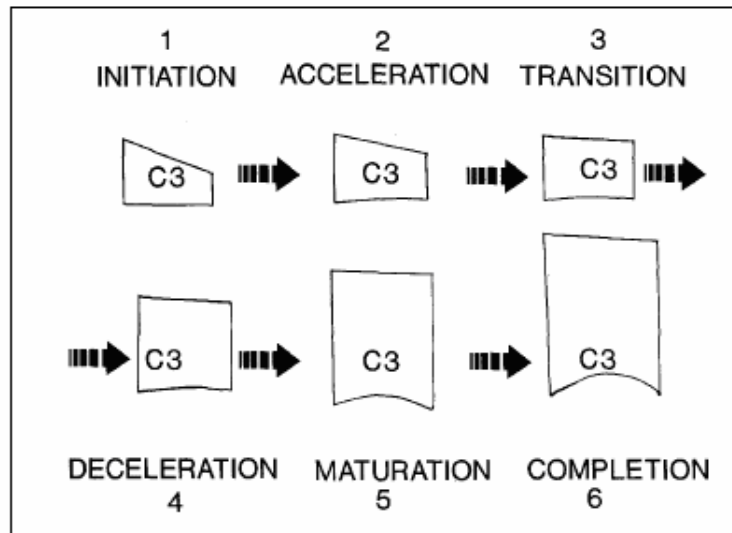
**Category 3** was called TRANSITION. This corresponded to a combination of SMI 5 and 6. Adolescent growth was still accelerating at this stage toward peak height velocity; with 25% to 65% of adolescent growth expected, distinct concavities were seen in the inferior borders of C2 and C3. A concavity was beginning to develop in the inferior border of C4. The bodies of C3 and C4 were rectangular in shape.

**Category 4** was called DECELERATION. This corresponded to a combination of SMI 7 and 8. Adolescent growth began to decelerate dramatically at this stage; with 10% to 25% of adolescent growth expected distinct concavities were seen in the inferior borders of C2, C3, and C4. The vertebral bodies of C3 and C4 were becoming squarer in shape.

**Category 5** was called MATURATION. This corresponded to a combination of SMI 9 and 10. Final maturation of the vertebrae took place during this stage, with 5% to 10% of adolescent growth expected. More accentuated concavities were seen in the inferior borders of C2, C3, and C4. The bodies of C3 and C4 were nearly square to square in shape.

**Category 6** was called COMPLETION. This corresponded to SMI 11. Growth was considered to be complete at this stage. Little or no adolescent growth was expected. Deep concavities were seen in the inferior borders of C2, C3, and C4. The bodies of C3 and C4 were square or were greater in vertical dimension than in horizontal dimension.

The authors concluded that orthodontist can evaluate skeletal maturity of the patient by using cervical vertebral.



**Figure 2.5 Cervical vertebral maturation indicators using C3 as guide (Hassel and Farman, 1995).**

Baccetti *et al.* (2002) presented an improved version of the (CVM) method to detect the peak in mandibular growth in a single lateral cephalogram. The authors studied 30 subjects (18 boys and 12 girls) from the University of Michigan elementary and secondary school growth study. The morphology of the bodies of the second (C2), third (C3), and fourth (C4) cervical vertebrae were analyzed in six consecutive cephalometric observations (T1 through T6), two during maximum mandibular growth (Co-Gn), two before, and two after. They obtained descriptive statistics for total mandibular length and for vertebral cephalometric measures at each of the six consecutive observations (T1 through T6).

The differences between the mean values for all the computed variables at the six consecutive stages were tested for significance by means of ANOVA for repeated measurements with post-hoc Scheffé's test ( $P < 0.05$ ). They found no statistically significant discrimination can be made between Cvs 1 and Cvs 2 as defined in the former CVM method. The presence of a concavity at the lower border of the second



cervical vertebra is not a distinctive feature of Cvs 2 when compared to Cvs 1. The two former stages (Cvs 1 and Cvs 2) merge into one single stage. The appearance of a visible concavity at the lower border of the third cervical vertebra is the anatomic characteristic that mostly accounts for the identification of the stage immediately preceding the peak in mandibular growth (former Cvs 3, actual CVMS II).

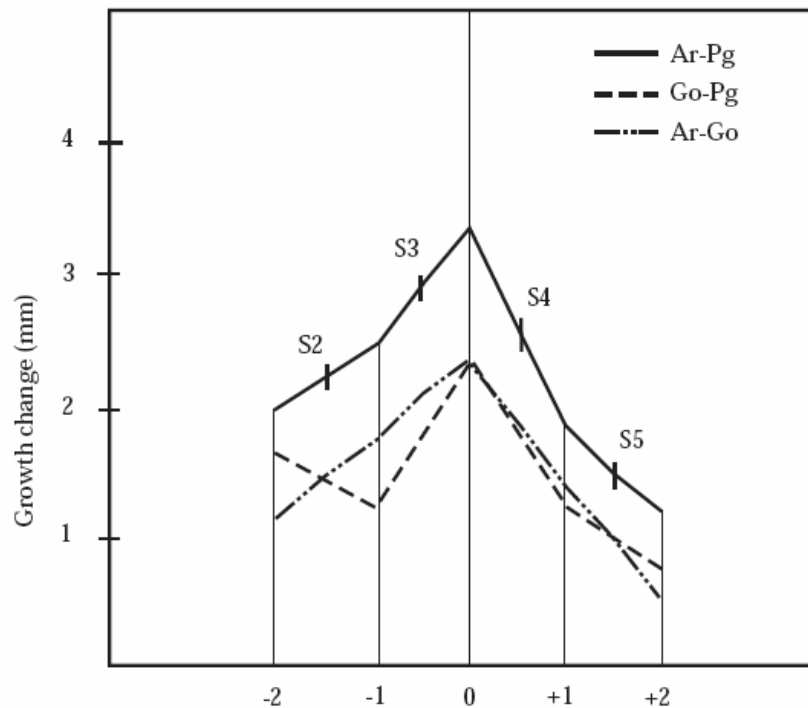
They concluded that the new CVM method presents with five maturational stages (Cervical Vertebral Maturation Stage [CVMS] I through CVMS V, instead of Cvs 1 through Cvs 6 in the former CVM method). The peak in mandibular growth occurs between CVMS II and CVMS III, and it has not been reached without the attainment of both CVMS I and CVMS II. CVMS V is recorded at least two years after the peak. They concluded that, the advantages of the new CVM version are to assess mandibular skeletal maturity through the analysis of the second, third and fourth cervical vertebra.

In the present study, the new method described by Baccetti *et al.* (2002) was chosen to assess CVM stages in lateral cephalograms. Which, when compared with the other cervical vertebral–evaluating methods, presents the following advantages: appraises three vertebrae only, restricts the stages of growth, and uses simpler and easily individuated cephalometric points. This method was used in many previous studies (Grave and Townsend, 2003a, Grave and Townsend, 2003b, Gandini *et al.*, 2006).

#### **b. Studies about cervical vertebral maturation**

O'Reilly and Yanniello (1988) evaluated lateral cephalogram radiographs taken annually of 13 Caucasian girls from 9 to 15 years of age. The authors assessed

cervical vertebrae according to Lamparski, (1972) method. The three cephalometric dimensions studied were (1) mandibular length (Articulare-Pogonion), (2) corpus length (Gonion-Pogonion), and (3) ramus height (Articulare-Gonion). They found statistically significant increases in mandibular length occurred between stages 1-2, 2-3, and 3-4, for corpus length between 1-2 and 2-3, and for ramus height between 1-2, in association with specific maturation stages in the cervical vertebrae according to the method of Lamparski. On the average, stages 1 through 3 occurred in the year prior to the peak velocity Figure 2.6.



**Figure 2.6 Mandibular growth in each cervical vertebrae maturational stage (O'Reilly and Yanniello, 1988)**

Franchi *et al.* (2000) analyzed the validity of 6 stages of cervical vertebral maturation (Cvs1 through Cvs6) as a biologic indicator for skeletal maturity. The sample consisted of 24 subjects (15 females, 9 males) age ranged 3 to 18 years, selected from the files of the University of Michigan Elementary and Secondary School Growth Study. The lateral cephalograms for each of the 24 subjects were available at

the 6 consecutive stages in cervical vertebral maturation (Cvs1 through Cvs6), the longitudinal data for statural height corresponding to the consecutive cephalograms for all the examined subjects were also available. The original method by Lamparski was used to assess cervical vertebral maturation in lateral cephalograms. The authors selected the following linear cephalometric variables (1) measurements of mandibular size, Co-Gn, Co-Goi, Goi-Gn; and (2) measurements of mandibular position in relation to other craniofacial structures, SGn, S-Goi, N-Me, ANS-Me. They found that CVM method was able to detect the greatest increment in mandibular and craniofacial growth during the interval from vertebral stage 3 to vertebral stage 4 (Cvs3 to Cvs4), when the peak in statural height also occurred. They concluded that the cervical vertebral maturation is a valid method for the evaluation of skeletal maturity and for the identification of the pubertal peak in craniofacial growth rate of individual subjects.

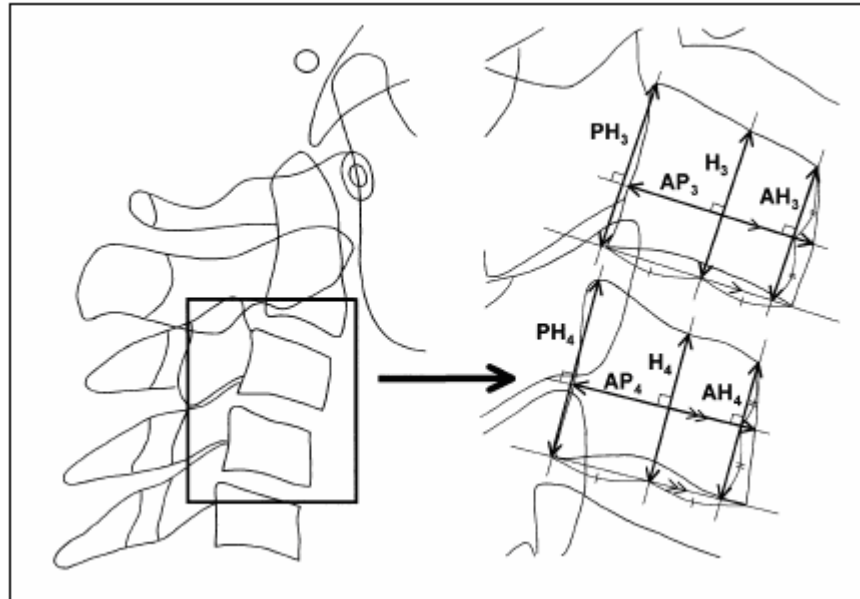
San Roman P *et al.* (2002) studied the validity of cervical vertebral maturation assessment to predict skeletal maturation. The authors assessed left hand-wrist and lateral cephalogram radiographs of 958 Spanish children from 5 to 18 years of age. The classification of Grave and Brown was used to assess skeletal maturation in the left hand-wrist radiographs. Cervical vertebral maturation was evaluated in lateral cephalogram radiographs according the stages described by Lamparski and by Hassel and Farman. In order to develop new method to evaluate skeletal maturation, they observed the following anatomical changes of cervical vertebral;

The concavity of the lower border of five vertebrae (C2-C6), the body height for two vertebrae (C3-C4), and the shape of two vertebrae (C3-C4). Pearson correlation coefficients were calculated to establish the relationship between skeletal maturation

values obtained by cervical vertebral and skeletal maturation measured at the hand – wrist. The authors found the concavity of the lower border of five vertebrae had the highest correlation with maturational stages determined from the hand-wrist radiographs, with females  $r = 0.82$  and males  $r = 0.75$ , and Hassel and Farman method was more accurate than Lamparski method. They concluded that the concavity of the lower border of five vertebrae could replace hand-wrist radiographs in assessment of skeletal maturity.

Mito *et al.* (2002) measured the shape of third and fourth cervical vertebral bodies and determined a regression formula to obtain cervical vertebral bone age. They used lateral cephalogram radiographs of 22 Japanese girls in each of 8 age groups (ages 7.0-14.9 years), for a total of 176 girls. On lateral cephalogram radiographs, they traced by pencil and measured with micrometer calipers: anterior vertebral body height (AH), vertebral body height (H), posterior vertebral body height (PH), and anteroposterior vertebral body length (AP) on the third and fourth cervical vertebrae. Figure 2.7. Parameters were measured on the third and fourth cervical vertebrae. AH3, AH4, H3, H4, PH3, and PH4 increased in an accelerated manner from 10 to 13 years of age. The ratios of these parameters were calculated. The formula for calculating cervical vertebral bone age was determined by stepwise multiple regression analysis with chronological age as a dependent variable and the ratios of these parameters as independent variables:

Cervical vertebral bone age =  $- 0.20 + 6.20 * AH3/AP3 + 5.90 * AH4/AP4 + 4.74 * AH4/PH4$ .



**Figure 2.7 Areas of cervical vertebral bodies measured on lateral cephalogram (Mito *et al.*, 2002)**

They used cephalometric and hand-wrist radiographs of another 66 girls (ages 8.0-13.9 years), to determine the reliability of cervical vertebral bone age in comparison with bone age by the Tanner-Whitehouse 2 method. The correlation coefficient for the relationship between cervical vertebral bone age and bone age (0.869) was significantly ( $P < .05$ ) higher than that for the relationship between cervical vertebral bone age and chronological age (0.705); and the difference (absolute value) between the cervical vertebral bone age and bone age (0.75 years) was significantly ( $P < .001$ ) smaller than that between cervical vertebral bone age and chronological age (1.17 years). They concluded that cervical vertebral bone age reflects skeletal maturity because it approximates bone age, which is considered the most reliable method for evaluating skeletal maturation.

Uysal *et al.* (2006) conducted study to correlate cervical vertebrae maturation with maturation indicated by hand-wrist radiographs in a Turkish population. The samples consisted of lateral cephalometric and hand-wrist radiographs of 503 subjects (213

male, 290 female; ages, 5.3-24.1 years). Cervical vertebral development was evaluated by the method of Hassel and Farman. Skeletal maturation of each hand-wrist radiograph was determined according to the method described by Björk and Grave, and Brown's system. The Spearman rank-order correlation coefficients were estimated separately for males and females to measure the relationships between cervical vertebral maturation, and the skeletal maturation measured at the hand-wrist. The authors found high correlation coefficient between hand-wrist and cervical-vertebrae maturation, 0.88 for female and 0.78 for male ( $P < .001$ ). They concluded that cervical-vertebrae maturation stages are clinically useful maturity indicators of the pubertal growth period among Turkish subjects.

Gandini *et al.* (2006) conducted study to evaluate the possible concordance between hand-wrist bone analysis and cervical vertebral analysis measured on lateral cephalograms of 30 patients 14 males and 16 females; age ranged 7–18 years. The authors' evaluated hand-wrist bone by the Bjork index, and the cervical vertebral by Baccetti *et al.* (2005) method. The authors found the comparison between the hand-wrist bone analysis and the cervical vertebral analysis revealed a concordance in 25 individuals (83.3%), the Cohen  $\kappa$  index also revealed a good concordance (0.783). They concluded that cervical vertebral analysis on a lateral cephalogram is as valid as the hand-wrist bone analysis with the advantage of reducing the radiation exposure of subjects.

Al Khal *et al.* (2008) conducted study to evaluate the validity of the cervical vertebra maturation method as an indicator of skeletal age during the pubertal growth spurt period by correlating the cervical vertebra maturation method with the hand–wrist maturation method. The sample size contains of southern Chinese subjects 200 male

and 200 female were randomly selected. The age for girls was between 10 years and 15 years and for boys it was between 12 years and 17 years, so they were within the pubertal growth spurt period. The authors assessed hand–wrist by Fishman, (1982) method, and lateral cephalometric radiographs by a method developed by Baccetti *et al.* (2005). The authors found that, the cervical vertebra maturation was significantly correlated with hand–wrist (Spearman's  $r$  boys=0.9206, girls=0.9363). The authors indicated that, the cervical vertebra maturation method is a valid indicator of skeletal age during the pubertal growth spurt period.

Baccetti *et al.* (2000) evaluated skeletal and dentoalveolar changes induced by the Twin-block appliance in two groups of subjects with Class II malocclusion treated at different skeletal maturation stages in order to define the optimal timing for this type of therapy. Skeletal maturity in individual patients was assessed from lateral cephalogram according to Lamparski method.

The early-treated group consisted of 21 subjects (11 females and 10 males) presenting with either stage 1 or stage 2 in cervical vertebrae maturation before the onset of the pubertal growth spurt. Mean age of these subjects before treatment was 9 years  $\pm$  11 months, and after discontinuation of the Twin-block appliance was 10 years 2 months  $\pm$  11 months. The late-treated group consisted of 15 subjects (6 females and 9 males) presenting with stages in cervical vertebrae maturation ranging from stage 3 to stage 5 during or slightly after the onset of the pubertal growth spurt. Mean age of this group was 12 years 11 months  $\pm$  1 year 2 months before treatment and 14 years 4 months  $\pm$  1 year 3 months after discontinuation of the Twin-block appliance. Both treated samples were compared with control samples consisting of