

Animal welfare, etológia és tartástechnológia



Animal welfare, ethology and housing systems

Volume 4

Issue 1

Gödöllő
2008



SYMPTOMS OF AGGRESSION ON ANIMAL BONES FROM ARCHAEOLOGICAL SITES

László Bartosiewicz¹, Erika Gál²

¹Institute of Archaeological Sciences, ELTE, 1088 Budapest, Múzeum körút 4/B.

²MTA Régészeti Intézet, 1014 Budapest, Úri utca 49.

bartwicz@yahoo.com, gal_erika@yahoo.com

Abstract

Archaeozoology is the identification, analysis and scientific as well as cultural interpretation of animal remains recovered from archaeological sites. It is the culture historical study of animal-human relationships. Owing to the extremely fragmentary nature of its data, archaeozoology is a multidisciplinary subject, heavily dependent on the integration of research results from related research.

Archaeozoological finds can be used in studying human or animal behaviour only to a limited extent. However, a few traumatic lesions identified on excavated animal bones may be tentatively attributed to ancient practices of animal husbandry of direct interest to archaeologists. Such symptoms, however, may not only be indicative of simple maltreatment but often result from aggression. Therefore, it should be important to recognize damage to bone caused by conflict. In addition to intraspecific aggression in a classical sense, interspecific aggression should also be considered. This latter also includes human/cultural action. While injuries inflicted by humans are most relevant to standard archaeological inquiry, the possibly safest identification of trauma caused by natural agents (e. g. during mating fights) is a prerequisite to the recognition of patterning caused by humans. This article is a review of archaeozoological examples, aimed at the tentative discussion of ethological interpretations of observations made on archaeozoological finds.

Keywords: archaeozoology, aggression, palaeopathology, traumatic bone injury



Az agresszió tünetei régészeti állatmaradványokon

Összefoglalás

A régészeti állattan a régészeti lelőhelyeken feltárt állatmaradványok meghatározása, elemzése, természet- és társadalomtudományi értelmezése, az ember-állat kapcsolat kultúrtörténeti vizsgálata. Multidiszciplináris, adatainak rendkívül töredékes volta miatt sok tekintetben szorul más tudományterületek eredményeinek hasznosítására.

Az emberi és állati viselkedés közvetlen tanulmányozására a zoológiai leletek csak korlátozottan alkalmasak. Rendkívül kis számban előfordulnak azonban rajtuk olyan gyógyult csontsérülések, amelyek utalnak a régmúlt idők állattartási szokásaira. Az ilyen tünetek nemcsak a rossz bánásmód következményei lehetnek, ezért fontos lenne a fajon belüli és a fajok közötti összetűzések által okozott károsodások elkülönítése. Az utóbbiakon belül megkülönböztethetünk az ember illetve más állat által ejtett sérüléseket. Noha a régészeti értelmezés szempontjából elsősorban az emberi tevékenység megismerése érdekes, ennek rekonstrukciója elképzelhetetlen a természetes hatások (pl. fajon belüli versengés) tüneteinek lehető legpontosabb azonosítása és kizárása nélkül. A cikk e régészeti megfigyelések viselkedéstani értelmezésének megvitatását célozza.

Kulcsszavak: régészeti állattan, agresszió, paleopatológia, csontsérülések

Introduction

Archaeozoologists use animal remains from archaeological sites in reconstructing past relationships between people and animals. Aggression resulting from conflicts between animals may be best detected on the basis of bone injuries. Palaeopathology is the study of *in vivo* lesions identified in the excavated bone material. It may be hypothesized that some such symptoms may result from trauma, inflicted during violent conflicts between individuals. Healed injuries may be identified most easily, although it is often difficult to directly attribute them to violent action as opposed to “simple”, abiotic accidents.



According to Collins' Dictionary „aggression is an attack or harmful action..., any offensive activity, practice”, that is usually interpreted in terms of human, if not political behaviour. In ethological studies it is primarily interpreted as a form of violent interaction *within* the same species. Hefty hacking marks as well as projectile points embedded in excavated human bone have attracted the attention of physical anthropologists for over a century (e. g. *Wilson*, 1901). Owing to the complexity of society, intraspecific (i.e. interpersonal) aggression in humans has had a much broader range of relatively well-understood cultural reasons (*Angel*, 1974). For example, *Wilkenson* and *Van Wagenen* (1993) cite osteological evidence (forearm injuries and depressed “pond” fractures of the skull) of what looks like violence against women, a distorted aspect of gender-related aggression between people. Recently an entire volume has been devoted to the subject (*Roksandić ed.*, 2004).

The archaeological study of human aggression is partly resulting from the fact that advanced forensic research is of great, first-hand help in these investigations. Another important aspect to be always considered, however, is taphonomy, the study of *post mortem* processes that affect the preservation, and recovery of dead organisms, the reconstruction of their biology or ecology, as well as the reconstruction of the circumstances of their death (*Haglund and Sorg*, 1997: 13). The fundamental taphonomic difference between excavated human and animal remains is that while the first are usually recovered as articulated skeletons from individuals (i. e. in their biological integrity), animal remains tend to be found as dispersed food remains, whose biological context (age, sex, health condition) is practically unknown. It is only animal burials, i. e. the study of entered animal bodies that can be compared to the palaeopathological evaluation of human remains (*Bartosiewicz*, 2002). Most evidence of aggression in archaeological animal bone assemblages, therefore, is limited to the identification of isolated symptoms of trauma on loose, disarticulated bone fragments.

Material and Method

This brief review is built on purely empirical data, based both on our personal observations and relevant cases encountered in the palaeontological and archaeozoological literature. Owing to the fundamental nature of archaeological data, our primary approach to the problem is inevitably inductive: apparently unrelated observations must be amassed, before reasonable trends may be recognized. These cannot be tested directly, since they are neither experimental (i. e. cannot ever be reproduced once excavation has destroyed the site itself), nor results of random sampling.



This latter is a special problem in archaeology: although archaeological assemblages are recognized as parts of a greater [non-excavated] entity, the “basic population” (in a statistical sense) remains unknown. In fact, one tries to draw inferences from a fragmentary excavated record relevant to a largely unknown phenomenon: *the Past*.

It is for this reason that multidisciplinary is of vital importance to archaeozoological reasoning. Archaeologists often resort to using analogy to create a better inferential structure for interpreting the residues recovered during the course of excavations. The underlying assumption is that basic patterns of behaviour have not changed through time, therefore the products of known processes (e. g. trauma caused by violence, in this case) may be recognized with great probability (*Binford, 1967*) thereby shedding light on the process itself. While thus correlating archaeological and ethnographic phenomena has been widely used (and debated) in understanding the past cultural behaviour of humans, animal bones are seldom, if ever, discussed in light of the known ethological properties of the animal species concerned.

Results and Discussion

As mentioned previously, aggression in ethology is conventionally interpreted as violent conflict between members of the same species. Since the direct sources of trauma are usually unknown in archaeozoology, the phenomena summarized in this chapter have been tentatively classified by the most likely cause of lesion. These include cases of classical intraspecific aggression and interspecific aggression with special regard to human predation on animals.

Intraspecific aggression

Intraspecific confrontations in the animal world, to a great extent, are associated with reproductive competition and/or territorial behaviour. Therefore its manifestations are more evident in the bones of wild animals. With the advancement of animal keeping, herders had a vested interest in minimizing conflicts between individuals during the mating season: clashes between competing animals not only caused damage, but was potentially dangerous for the people tending livestock. In addition, since most domesticates were selected for levels of aggression lower than those of their wild ancestors, some of this selection may have been indirect with obstreperous individuals often being isolated and culled.



Usually only a few, peculiar forms of trauma can be unambiguously attributed to intraspecific fighting. Among dogs (*Canis familiaris* L. 1758), for example, bites may cause a number of non-specific osteological symptoms. One of the few potentially relevant lesions was described by *Churcher* (1993), who noted palatal punctures in three of the specimens (SK IV, V VII) recovered from the presumably AD 3rd century dog burials from the cemetery of Ein Tirghi in the Western Desert of Egypt. As one possible explanation, he suggested "that the damage was caused during fights when the muzzle of one dog is seized by another and lower canines may be pressed against the palate of the seized dog".

This hypothesis is consonant with a healed trauma near the naso-frontal area of another specimen (SK III). As an alternative explanation, however, the author himself mentions minor injuries to the palatal dermis by bone splinters in the animal's food during gnawing.

According to the tabulated summary by *Baker and Brothwell* (1980, *Table 1*), skull injuries occur relatively frequently in Artiodactyls. In principle, some of these should be traumatic lesions related to intraspecific mating competition in the case of rams, stags and bucks. In their essay on the comparative craniology of wild sheep and goat, *Reed and Schaffer* (1972) explain, how different cornual and frontal sinus formations of male sheep and goat have evolved to offset the specific impact suffered during clashes between rams and bucks respectively. Differences in cranial morphology were elegantly linked by the authors to different forms of known intraspecific fighting behaviour characteristic of these two species. This high level of adaptation makes major head injuries less likely to occur.

On the other hand, some of the damage on the tines of red deer (*Cervus elaphus* L. 1758) antler (often mistaken for marks of manufacturing in archaeozoological assemblages), is undoubtedly caused during fights between stags and bucks respectively. Such injuries, however, are not pathological and are therefore "tolerated" by natural selection. This is in contrast to real head injuries observed on the frontal bone of a mature prehistoric stag from Snoldelev (Denmark; *Figure 1*). Although the direct reasons of his injuries remain inevitably unknown, it is most likely that the supraorbital bone lesions in the living animal were caused by many seasons of clashing with competing stags during the mating period. Healed injuries, especially pond-fractures, on the forehead and parietal bones of pig skulls (*Sus* sp.; both wild and domestic) may also partly be attributed to intraspecific aggression. In this case, however, both sexes may be affected (e.g. a Bronze Age wild sow from Parte, Ljubljana Marshland, Slovenia) since pigs clash with their heads, often fighting with their tusks. Indubitably, however, analogous symptoms may be caused by accidents involving abiotic factors. For example, pigs fleeing in a panic may sometimes crush into tree trunks and other hard objects.



The cervical vertebrae of 14 rams studied in a feral herd of modern Soay sheep (*Ovis aries* L. 1758) from the island of Hirta (Outer Hebrides, Scotland) all showed lesions, possibly relevant to mating fights. According to *Clutton-Brock et al.* (1990), the *fossa vertebrae* (that is the caudal, concave articular surface of the *corpus*) was compressed, split or distorted in some other way. In one case, even the caput vertebrae and the stout *processus transversus* were injured. Since these symptoms never occurred in females of the same herd, the authors concluded that they were caused by the impact in "shock combat" between rams. Osseous hypertrophy observed in the second cervical vertebra (*axis*) of a Copper Age sheep from Horum Höyük (Turkey) may be associated with the same type of repetitive injury (*Figure 2*).

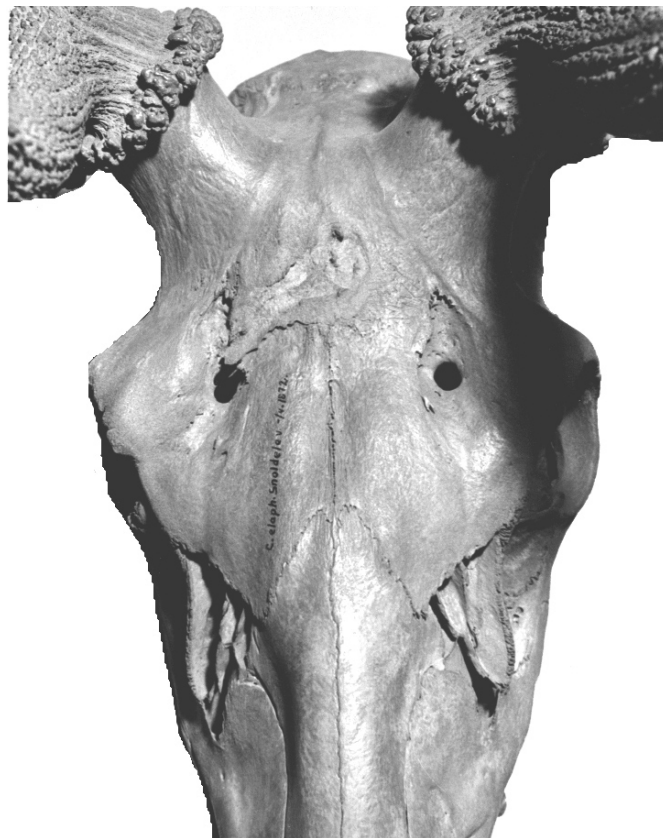

Figure 1. Healed supraorbital forehead injuries in a prehistoric mature stag from Snoldelev (Denmark, Pollen zone VIII), probably caused during intraspecific mating fights. (Courtesy by Magnus Degerbøl)

1. ábra: Homlokcsont sérülések őskori gímszarvas bika koponyáján (Snoldelev, Dánia, VIII. pollenzóna; Fénykép: Magnus Degerbøl)




Figure 2. Osseous hypertrophy in the axis of a Copper Age sheep, Horum Höyük (Turkey). Lateral and cranial views (the drawing after Schmidt 1972 represents a healthy individual)

2. ábra: Hipertrófiás elváltozás rézkori juh második nyakcsigolyáján (axis) Horum Höyük lelőhelyről (Törökország). A méretarányos rajz (Schmid 1972) az egészséges csigolya körvonalait mutatja

A very specific trauma is represented by healed baculum (*os penis*) fractures among large carnivores, known from several palaeontological assemblages. These can be rather unambiguously linked to intraspecific fighting during mating. Given the fundamentally non-anthropogenic nature of this trauma, it is understandable why bacula were not touched upon in Baker and Brothwell's 1980 book, entitled "Animal Disease in Archaeology". Never-the-less, it is one of the topics most evidently relevant to ethology: continuing fights between males during copulation must have made some animals jump, snapping the bone inside the inserted penis. It is, in fact, impossible to imagine any other source for this type of injury.



This trauma is most widely known in cave bear (*Ursus spelaeus* Rosenmüller and Heinroth). Of the 15 cases *Tasnádi-Kubacska* (1933; 1960) mentioned among others from Poland, Italy, France, Hungary and the adjacent part of western Romania. A specimen from Slovenia is shown in *Figure 3*.

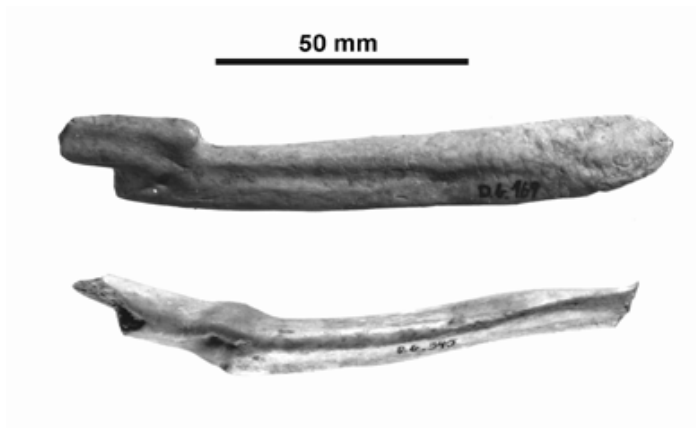


Figure 3. Healed fractures on cave bear bacula from Divje babe Cave I (Slovenia). Proximal fragment with “bayonet-like” dislocation (top) and healing in a ventral arch with a smooth fusiform callus (bottom). Courtesy by Ivan Turk

3. ábra: Gyógyult törések barlangi medve péniszcsontján a szlovéniai Divje babe I barlangból. Proximális töredék “szuronyszerű” diszliokációval (fent), enyhe ventrális ív csekély heggel (lent). Fénykép: Ivan Turk

A baculum fracture in Holocene walrus (*Odobænus* [*Trichechus*] *rosmarus* L. 1735), has been described from Saint Lawrence Island, Alaska. The break healed with a spindle-shaped callus in the bone's middle (*Capasso, 1999, Figure 1*). One of five additional bacula of late 19th century walrus from Franz Joseph Land (National Museum of Scotland in Edinburgh, Inv. No. 1996.33.30), was healed in a similar manner (*Figure 4*). Healing took place with no major complications: only a narrow but distinct callus ring is visible on the periosteum. The behavioral background of this type of trauma can be better elucidated using the measurements of intact walrus bacula (*Bartosiewicz, 2000, Table 1*). The fractured specimen remarkably gracile, thus being indicative of a young adult. Similarly, the 45 cm greatest length of the aforementioned Alaskan specimen measured by *Capasso (1999)* is indicative of a small individual. The gracile fractured bacula under discussion here suggest that young, low-ranking males were more at risk of being bullied during copulation. Similarly to the mighty cave bear, other aetiology for this type of trauma is indeed difficult to imagine, since "snapping" a massive walrus baculum does take the sometimes more than 1.2 metric ton live weight of a fully grown male (*Burt and Grossenheider, 1976: 84*).



Of domestic carnivores, it is only dog that is represented by relatively many bones in archaeological assemblages. However, not a single fractured dog baculum has been reported among the 1294 pathological cases from 79 sites representing 12 countries in Europe (Bartosiewicz, 2007). Negative evidence is worth considering in this case.




Figure 4. Nineteenth century collection of walrus bacula from Franz Joseph Land (National Museums of Scotland, Edinburgh), showing healed fracture in the lowermost specimen

4. ábra: XIX. századi rozmár péniszcsontok (National Museums of Scotland, Edinburgh), a legalsó példány gyógyult törés nyomával

Aside from the taphonomic vulnerability of this single, relatively small skeletal element (theoretically present only in 50% of dogs), scaling as well as Canid osteomorphology conspire to prevent the healing of such fractures. The baculum of a walrus is half a meter long, and it is almost half that size in cave bear (219 ± 30 mm). It can be at most 100 mm in large dogs. The fracture of a shorter bone in a species of smaller body mass seems statistically less likely. Only a single, fusiform healed fracture was described from 250 male Mustelids raised on a fur farm (Tasnádi-Kubacska, 1955).

Aside from scaling, specific morphology must be taken into consideration as well. While the baculum of seals and walrus (Pinnipedia), bears (Ursidae) and in stoats and weasels (Mustelidae) is largely round in cross-section (Tasnádi-Kubacska, 1933), in dogs a deep groove (*sulcus urethralis*) runs along the bone's ventral surface resulting in an upside-down "V"-shape cross-section (Fehér, 1980). The fracturing of dog baculum, therefore, has the potential of rupturing the urether embedded in its ventral side (Figure 5). Although the prognosis of covered baculum fracture in dogs is good in modern veterinary practice (Tamás, 1987), open fractures and resulting complications must have been fatal for many dogs in Antiquity, thereby precluding the healing observed in cave bear and walrus.

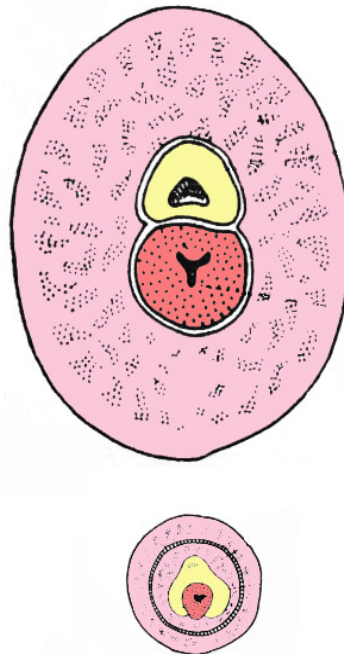


Figure 5. The largely round cross-section of walrus (Pinnipedia) penis bone marked in yellow (above) and the groove (*sulcus urethralis*) visible along the bone's ventral surface in dogs (Canidae; below). The urether is marked in red.

5. ábra: A rozmár (Pinnipedia) péniszcsont (sárga) kerek keresztmetszete (fent) és a kutya (Canidae) péniszcsont mély *sulcus urethralis*a (lent). Az urétert piros szín jelöli



While owing to a number of taphonomic reasons, bird bones are rare in most assemblages (Bartosiewicz and Gál, 2007) some injuries may be attributed to aggression in the case of this vertebrate class as well. Males of middle- and large sized galliforms, in general, often fight among themselves during the mating season when breeding hierarchy and territory are being established within the population. Males in conflict suffer injuries both on the attacking parts, like the different elements of the wing, and on the body parts exposed to hits. Others, such as the cocks of ptarmigans (*Lagopus* sp.) and grouses (*Tetrao* sp.), which often simulate fights using their beaks and legs, tend to be wounded on the chest and suffer fractures of the *furcula* (Tasnádi-Kubacska 1960, Fig. 204). Palaeontological bone evidence for lesions in the leg of ptarmigans (*Lagopus mutus* Montin 1776 and *Lagopus (lagopus) albus* Gmelin 1789) were also found in the Late Pleistocene Pilisszántó Rockshelter in North Hungary (Lambrecht 1933).

The social attitude of crows also disposes the members of this group of birds to more frequent trauma than is the case with other species. The aggressive behaviour of hooded crows (*Corvus cornix* L. 1758) is often common and conspicuous within a population near good sources of food when breeding territories are of high density (Cramp, 1998). It is likely that the small injuries displayed on two skulls from archaeological deposits uncovered in the Transdanubian region of Hungary were caused by the beak of a flock-member (Figure 6).

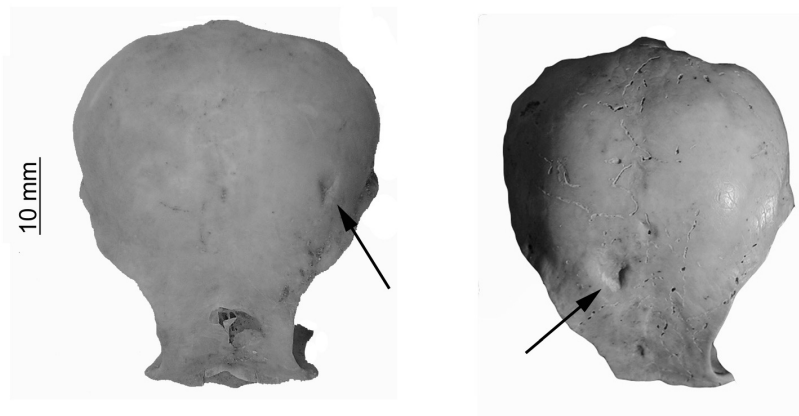


Figure 6. Traces of traumatic injury on the frontal bones of hooded crows (left: Balatonlelle – Kenderföldek, Roman Period; right: Bajcsavár, Turkish Period).

6. ábra: Sérülések nyoma dolmányos varjak homlokcsontján (balra: Balatonlelle – Kenderföldek, római kor; jobbra: Bajcsavár, török kor).



Interspecific aggression

Symptoms of intra- and interspecific aggression are not always easily distinguished. In cave bear remains canine marks combined with other head injuries can be alternatively interpreted as having been caused by fellow cave bears (*Pales*, 1958) or cave lions (*Panthera leo spelaea*; *Guérin and Patou-Mathis*, 1996; *Capasso*, 1998). It has even been argued that at least some of these injuries (such as depressions or pond fractures) may be cases of minor accidents caused by the animals living in confined caves with low ceilings (*Kurtén*, 1976).

While intraspecific aggression in animals has usually little to do with human influence, a dominant aspect of interspecific aggression forms a characteristic part of relationships between humans and animals. Hunting and slaughtering, as well as the maltreatment of domesticates have been a common sources of skeletal trauma.

Trauma inflicted during hunting

The evidence of hunting by animals is best shown by damage to the dentition of carnivores themselves. Gnawing marks on the bones of prey items can rarely be proven *perimortem* in origin. They usually represent the first step in the long taphonomic process, after the prey animal fell victim to predators. One of the few, spectacular exceptions is the juvenile Australopithecine skull fragment from the cave complex at Swartkrans (South Africa), whose injuries could be matched to the lower canines of a leopard (*Panthera pardus* L. 1758) mandible found at the same site (*Brain*, 1981).

According to *Berryman and Haun* (1996), *perimortem* trauma tends to be underreported in the archaeological literature owing to a lack of familiarity with forensic evidence and bone breakage patterns. In human palaeopathology, healing is considered the most useful indicator of *pre-mortem* fracture (*Aufderheide and Rodriguez-Martin*, 1998). However, for the fracture to show signs of healing, at least two weeks of survival are required between the traumatic accident and death (*Mann and Murphy*, 1990). On the other hand, bone starts losing its elasticity only circa two months after death.

Aside from often obscure fractures, other forms of skeletal injuries inflicted by [human] hunting are far from random. They represent a separate, varied field of interspecific violence, amply illustrated by archaeozoological finds. Such specimens also help in testing hypotheses concerning the hunters' skill, the kinds of weapons used and the types of hunting that were pursued, that is, human behaviour (*Noe-Nygaard*, 1989).



During early research into palaeopathology, traumatic cranial lesions in cave bear were invariably attributed to human predation (*Abel and Kyrle, 1931*). Since the time of earliest, palaeolithic weapon use in Europe, numerous stone chips have been found embedded in animal bones, especially the skulls and vertebrae of prey animals such as reindeer (*Rangifer tarandus* L. 1758) in Denmark and Northern Germany (*Moodie, 1923; Bratlund, 1991*). There can be little doubt that they are fragments of ancient projectile points. The paucity of skeletal trauma attributable to projectiles or blades in cave bear, however, is best explained by the suggestion that Palaeolithic people and cave bear actually exploited different ecological niches and that they had relatively few violent encounters (*Koby, 1954*). On the other hand, at least one spectacular example of brown bear (*Ursus arctos* L. 1758) hunting was described from the Grotte du Bichon (La Chaux-de-Fonds, Western Switzerland).

The evidence of this hunting accident that happened 12,000 years ago, consists of a silex projectile stuck in one of the cervical vertebrae of the bear. In addition, the remains of the hapless hunter were also found within the same deposit (*Morel, 1993*).

Artifactual evidence of hunting occurs most commonly on the bones of herbivores that provided the bulk of hunters' prey throughout history. *Hallam et al. (1973)* noticed a concentration of shot wounds associated with barbed points within the region of the thorax and the proximal segment of the forelimb in a late glacial moose. In addition to numerous scapula injuries, *Noe-Nygaard (1989)*, identified a flint arrowhead in the proximal epiphysis of the left humerus of a Mesolithic red deer (Kongemosen, Denmark). This point caused a fracture that did not heal but rather extended into a crevice. While not lethal in itself, this *perimortem* injury seems to represent a deadly barrage of arrows aimed at this body region of vital importance. Shot wounds detected on ribs, such as the flint point encapsulated under a bony bridge in a Mesolithic red deer from Denmark (*Noe-Nygaard, 1989: 470: 12*) must also have been aimed at the chest.

In Hungary, *Bökönyi (1974)* found a flint blade fragment embedded in the caudoventral surface of a large aurochs atlas recovered from the late Neolithic tell settlement of Polgár–Csőszhalom (Herpály culture). The projectile point was stuck in the caudal articular surface of the atlas, but the injury never reached the spine. Therefore the animal survived this trauma. Similar stone splinters occur relatively frequently along the spine of large game. The same trauma was observed on the lumbar vertebrae of two red deer from the Cortaillod Period, found at the lakeshore dwelling of Zürich–Mozartsrasse (Switzerland; *Gross et al., 1990*). One of these injuries was better healed than the other.



Projectile points made from bone and softer, denser antler is rarely found in association with zoological finds. A special aspect of these cases is that the projectiles themselves have little zooarchaeological information (style and function varies with the animal species/skeletal element chosen for such artifacts). *Vereschchagin* (1967) published a bison scapula from the Upper Palaeolithic of Ukraine that had been damaged by a spearhead made from reindeer antler. A bone point is known from the Swiss Neolithic, from the pile dwellings of Lake Biel, found embedded in the ventral surface of the sacral bone of a red deer (Jörg Schibler 1990, personal communication). In the absence of new bone formation, i.e. healing, this find must represent a fatal abdominal injury. As a distant chronological analogy, a crude bone projectile point was embedded in the right ilium of a young pig recovered from a 13-15th century urban deposit at Vác, Hungary (*Bartosiewicz*, 1995). This relatively blunt point ripped through the bone cortex on the latero-ventral side, creating a sharp-edged oblong opening. The wound showed no sign of healing. Similarly to the aforementioned deer sacrum, this trauma may be considered *perimortem*. It is not possible to tell whether the young pig was wild or domestic.

In the first case, the find is likely evidence of poaching for large game by city dwellers using non-sophisticated weaponry. If the young pig from Vác was domestic, it may have fallen victim to one of the fatal practical jokes that humans have enjoyed for millennia at the expense of animals. Bone projectiles have become irrelevant in hunting long before the Middle Ages. Metal arrow heads found in several 14-15th century red deer bones have been reported from the medieval royal seat in Buda, Hungary (*Zolnay*, 1982).

A metal projectile point from a crossbow, found in the rib cage of a late medieval dog skeleton in Layer E of the castle in Berlin-Köpenick (*Müller*, 1962) was interpreted as evidence for a "workshop accident" that may have occurred during hunting.

Not all hunting injuries have retained fragments of weapons that caused them. Perhaps the best known lesions of this sort were published for Danish Mesolithic red deer by *Noe-Nygaard* (1975, 1989). A dozen patterned perforations documented in the *corpora scapulae*, are consistent with the hypothesis that hunters indeed systematically aimed at the cranial half of the rib cage. Unhealed holes, located in the middle of this bone, ventrally from the spina scapulae (*fossa infraspinata*) are *perimortem* injuries. At least six scapulae, however, were perforated more toward their cranial (articular) and caudal ends respectively (*Noe-Nygaard*, 1989). The healed margins of these wounds show that they were not fatal and the deer escaped. Signs of an infected penetrating wound were found on the right scapula from a Mesolithic elk (*Alces alces* L. 1758) from Starr Carr (*Legge and Rowley-Conwy*, 1988). The neck of this scapula was almost half-way dissolved in a large inflammatory lesion on its ventral edge. No flint remains were left in the wound.



The pathological condition eventually spread to the bone's dorsal margin. The animal evidently survived the wound for at least several months with a chronic inflammation in its shoulder. More interestingly, in addition to the usual defleshing marks, a concentration of cuts around the dorsal lesion suggests that the inflamed tissue was carefully investigated once the animal had been killed.

Noe-Nygaard (1974) also discovered numerous traumatic lesions on the foreheads of Mesolithic wild pigs (*Sus scrofa* L. 1758) that occurred in both sexes and seem to be too grave to have been caused exclusively by the aforementioned intraspecific violence. Flint fragments embedded in some of these frontal bones offer direct evidence that at least part of these healed injuries were caused by hunters. They also reveal that wild pig must have often turned on their tormentors and survived the face to face combat.

Skeletal trauma in domesticates

Many forms of non-healed trauma, especially in the head and neck region of domestic animals may be interpreted as signs of slaughtering. While *perimortem* skull fractures may be difficult to tell apart from post-depositional fragmentation, cut marks tend to be unambiguously recognizable.

The identifiability of such injuries increases with the advancement of butchering techniques, that is, the use of increasingly sharp and dangerous metal tools in Europe, especially from the Roman Period onwards.

A 10 cm long hacking mark across a cow's (*Bos taurus* L. 1758) forehead in a diagonal direction at the ca. 15 - 9 BC Roman military fort of Dangstetten (Waldshut, Germany) was not deep enough to damage the brain. Thus, it may not have caused the animal's instant death, but possibly served to stun the beast prior to proper slaughtering (*Uerpmann*, 1977). A heavy-impact hack mark of similar size and shape across the nuchal region of a cattle skull from the Gaulish sacrificial site of Gournay sur Aronde in France (*Méniel*, 1994) must have cut right across the *lig. nuchodorsale*. It did not reach, however, the animal's spine. Although this trauma is also evidently *perimortem* (unhealed), it probably represents only one stage in slaughtering the animal. According to the author, this type of injury occurs systematically in coeval sacrificial assemblages. The same site also yielded two cattle skulls possibly perforated by lances of some sort in the frontal bone, largely between the *foramina supraorbitalia* (*Méniel*, 1994). Regular, square-shaped perforations on the foreheads of horses (*Equus caballus* L. 1758) from 10-12th century settlements in Hungary (Tiszalök–Rázom: *Bökönyi*, 1974; Kajárpéc–Pokolfadomb: *Takács*, 1993) may be unambiguously attributed to fatal blows delivered with a pick-like weapon.



Domestic animals suffered characteristic injuries not only at the time of slaughtering. In contrast to the aforementioned lethal blows, healed head injuries commonly occur in domestic pig (*Sus domesticus* Erxl. 1777). A deep but healed longitudinal hack mark on a pig parietale was described by *Boessneck* (1973: Taf. 18) from the site of Zendan-i Suleiman in Iran (7th century BC).

Cruel treatment and poor keeping conditions often lead to serious injuries. Although fractures in the brain skull (*fractura ossium neurocranii*) are relatively rare in modern veterinary practice (*Tamás*, 1987), smaller healed injuries on pig skulls were reported from early dynastic (2800-2700 BC) deposits at Tell Razuk, Iraq (*Boessneck*, 1987). Similar fragments are known from Agia Sophia-Magula, Thessalia (*Driesch*, 1983). Injuries in the facial portion of the skull are often accompanied by infections that lead to fistula formation. In addition to modern horse (*Tamás*, 1987), this condition was also noted between the nasalia of an Iron Age domestic pig from the hill-fort of Stična, Slovenia (*Bökönyi*, 1974).

Baker and *Brothwell* (1980) have already noted the apparently non-random distribution of healed head injuries on dog skulls from the Neolithic through the Roman Period. Many of these traumatic lesions were located on the dorsal part of the viscerocranium and around the rim of the orbita. Although the fine bones of the skull are rather fragile in dogs, the chances of surviving such trauma were reasonably good in these non-meat purpose animals.

During the analysis of animal bone fractures from the Roman provincial town of TÁC–Gorsium, Bökönyi has pointed out that dogs must always have been under one's foot, and kicks and blows aimed at the heads of these poor creatures must have played a major role in their control (*Bökönyi*, 1984). Such conflicts may be interpreted as territorial, in spite of the different species (dogs and humans) involved (*Figure 7*). According to the diagram compiled by *Baker* and *Brothwell* (1980) 12 of the 18 cranial injuries observed on dog skulls from between the Neolithic and the Roman Period, were concentrated on the lateral part of the forehead. Similar injuries, hypothetically attributed to beating, were observed on the skulls of a Neolithic pig at the site of Los Castillejos, Granada/Spain (*Ziegler*, 1990).

An unusual, healed trauma was identified in the form of a depression across the *crista sagittalis externa* on the skull of a mature wolf (*Canis lupus* L. 1758) from the Hallstatt-B Period deposit at Stillfried (*Pucher*, 1988). This injury may have been caused by a transversally directed major blow on the parietal region of the head. According to the author this animal may have died in captivity.

The exposure of dogs to head injuries is also illustrated by modern statistics. Based on several decades of veterinary record, while mandibula fractures made up only 4.88 % of all fractures in horse, this value rose to 5.44 % in dogs (*Tamás, 1987*). In addition to the smaller size of this latter species, the difference may also be resulting from differential human behaviour toward these two otherwise popular domestic animals.

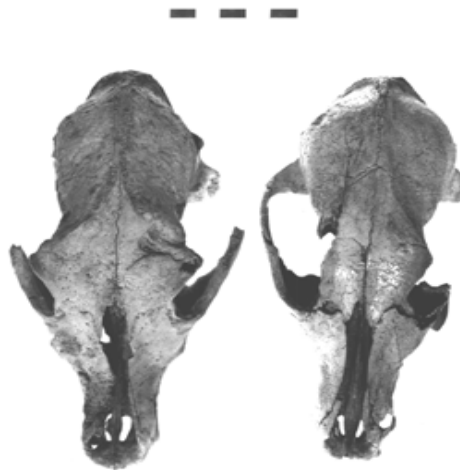


Figure 7. Skull injuries in a Bronze Age (left: Kamid el Loz, Lebanon) and a Migration Period (right: Kupeszér, Hungary) dog

7. ábra: Koponyasérülések bronz- (balra: Kamid el Loz, Lebanon) és népvándorlás-kori (jobbra: Kupeszér) kutyán

Conclusions

Archaeozoology is the historical study of relationships between animals and humans. Artefactual evidence of human behaviour (as controlled by cultural tradition), however, would be difficult to recognize without considering other sources of phenomena observed in the osteological find material. Identifying possible ethological factors behind certain archaeozoological phenomena is not only interesting in itself, but may also be of help in separating human from non-human agents.



Within the small segment of pathologically modified bone finds in numerous archaeological assemblages, some bone injuries may be tentatively linked to either animal or human behaviour. It must be emphasized, however, that the direct aetiology of such cases is usually unknown, i. e. various analogous processes may have resulted in similar bone lesions.

Empirical archaeozoological observations reviewed in this paper are summarized in *Figure 8*. While, with the exception of baculum fractures accidents caused by abiotic factors can hardly be ruled out in any of the cases, familiarity with the animals' behaviour may offer likely explanations for the various types of injuries.

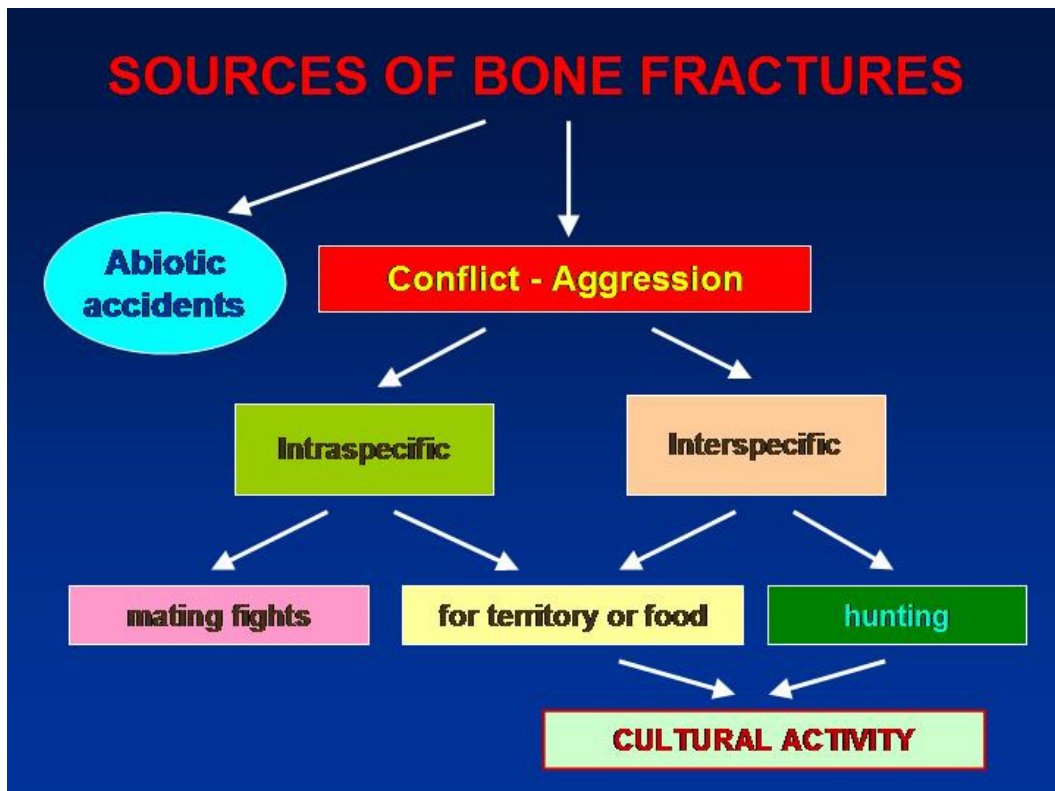


Figure 8. Sources of skeletal trauma attributed to aggressive behaviour

8. ábra: Az agresszív viselkedés csonttani tüneteinek forrásai (magyarázat a szövegben)



Those potentially attributed to aggressive behaviour, may originate from intra- or interspecific conflicts. As mentioned before, mating fights leave rather evident osteological markings, while conflicts about territoriality or food (whether intra- or interspecific) can only be tentatively identified. Hunting by animals may be appraised by carnivore dental injuries in the predator itself, while human predation is also indicated by the presence of various projectile points in the prey. This latter, culturally most interesting form of aggression is complemented by the evidence of abuse in domestic animals, especially dogs that lived in especially close proximity to humans.

The ethological interpretation of certain bone remains thus can be used in reconstructing past lifeways of both animals and humans, with special regard to their often violent interactions.

Acknowledgements

Research by Erika Gál has been supported by the Bolyai János Fellowship and OTKA Grant no. F048818. This paper was presented at the 10th, celebratory meeting of the Hungarian Ethological Society in Göd (Hungary) on 30 November, 2007. Grateful thanks are due to the conference organizers for the invitation.

References

- Abel, O., Kyrle, G. (eds.) (1931): Die Drachenhöhle bei Mixnitz. Wien: Spelaeologische Monographien Vols. 7-8.*
- Angel, J. L. (1974): Patterns of fractures from Neolithic to modern times. Budapest, Anthropológiai Közlemények 18: 9-18.*
- Aufderheide, A. C., Rodríguez-Martín, C. (1998): The Cambridge Encyclopedia of Human Paleopathology. Cambridge, Cambridge University Press.*
- Baker, J. R., Brothwell, D. (1980): Animal diseases in archaeology. London, Academic Press.*
- Bartosiewicz, L. (1995): Animals in the urban landscape in the wake of the Middle Ages. Tempus Reparatum, Oxford: 1-180.*
- Bartosiewicz, L. (2000): Baculum fracture in Carnivores: Osteological, behavioural and cultural implications. International Journal of Osteoarchaeology 10, London: 447-450.*



- Bartosiewicz, L.* (2002): Palaeopathology: similarities and differences between animals and humans. *Anthropológiai Közlemények* 43: 29-37.
- Bartosiewicz, L.* (2007): Description, diagnosis and the use of published data in animal palaeopathology. Paper delivered at the Third ICAZ Animal Palaeopathology Working Group Conference, 6-8 September 2007, Lithuanian Veterinary Academy (Kaunas, Lithuania).
- Bartosiewicz, L., Gál, E.* (2007): Sample size and taxonomic richness in mammalian and avian bone assemblages from archaeological sites. *Archeometriai Műhely* 2007/1: 37-44; http://www.ace.hu/am/2007_1/AM-2007-01-BL.pdf
- Berryman, H., Haun, S.* (1996): Applying forensic technique to interpret cranial fracture patterns in an archaeological specimen. *International Journal of Osteoarchaeology* 6:2-9.
- Binford, L. R.* (1967): Smudge Pits and Hide Smoking: The Use of Analogy in Archaeological Reasoning. *American Antiquity* 32: 1-12.
- Boessneck, J.* (1973): Tierknochenfunde vom Zendan-i Suleiman (7. Jahrhundert v. Christus). *Archaeologische Mitteilungen aus Iran, Neue Folge Band* 6: 95-111.
- Boessneck, J.* (1987): Tierknochenfunde vom Uch Tepe. *Acta Praehistorica et Archaeologica* 19: 131-163.
- Bökönyi, S.* (1974): *History of Domestic Mammals in Central and Eastern Europe*. Budapest, Akadémiai Kiadó.
- Bökönyi, S.* (1984): *Animal husbandry and hunting in TÁC–Gorsium. The vertebrate fauna of a Roman town*. Budapest, Akadémiai Kiadó.
- Brain, C. K.* (1981): *The Hunters or the Hunted? An introduction to African cave taphonomy*. Chicago, University of Chicago Press.
- Bratlund, B.* (1991): A study of lesions containing flint fragments on reindeer bones at Stelmoor, Schleswig-Holstein, Germany. In N. Barton, A. C. Roberts and D. A. Roe eds.: *The late glacial in north-west Europe: Human adaptation and environmental change at the end of the Pleistocene*. London, Council for British Archaeological Reports: 193-206.
- Burt, W. H., Grossenheider, R. P.* (1976): *A Field Guide to the Mammals of America North of Mexico*. Boston, Houghton Mifflin Company.
- Capasso, L.* (1998): Cranial pathology of *Ursus spelaeus* Rosenmüller and Heinroth from Chateau Pignon, Basque Territories (Spain). *International Journal of Osteoarchaeology* 8: 107-115.
- Capasso, L.* (1999): A healed fracture in an *Odobenus rosmarus* baculum from the Holocene of Saint Lawrence Island, Alaska. *International Journal of Osteoarchaeology* 9/4: 260-262.



- Churcher, C. S. (1993): Dogs from Ein Tirghi Cemetery, Balat, Dakleh Oasis, Western Desert of Egypt. In A. Clason, S. Payne, and H.-P. Uerpmann eds.: *Skeletons in her cupboard*. Oxford, Oxbow Monograph 34: 39-59.
- Clutton-Brock, J., Dennis-Bryan, K., Armitage, P. L., Jewell, P. (1990): Osteology of the Soay sheep. *Bulletin of the British Museum of Natural History (Zoology)* 56/1: 1-56.
- Cramp, S. (ed.) 1998. *The complete birds of the Western Palearctic on CD-ROM*. Oxford, Oxford University Press.
- Driesch, A. von den, (1983): Zur frühen Mensch-Tier-Symbiose. *Kolloquien zur Allgemeinen und Vergleichenden Archäologie Band 4*: 25-58.
- Fehér, Gy. (1980): *A háziállatok funkcionális anatómiája [The functional anatomy of domestic animals] I*. Mezőgazdasági Kiadó, Budapest.
- Gross, E., Jacomet, S., Schibler, J. (1990): Stand und Ziele der Wirtschaftsarchäologischen Forschung an Neolithischen Ufer- und Inselsiedlungen im unteren Zürichseeraum (Kt. Zürich, Schweiz). In J. Schibler, J. Sedlmeier and H.-P. Spycher eds.: *Festschrift für Hans R. Stampfli. Beiträge zur Archäozoologie, Archäologie, Anthropologie, Geologie und Paläontologie*. Helbing & Lichtenhahn, Basel: 76-100.
- Guérin, C., Patou-Mathis, M. (1996): *Les Grands Mammifères Plio-Pléistocènes d'Europe*. Masson, Paris.
- Haglund, W. D., M. H. Sorg (1997): Method and Theory of forensic taphonomy research. In Haglund, W. D. and M. H. Sorg eds.: *Forensic Taphonomy: The Postmortem Fate of Human Remains*. CRC Press LLC, Boca Raton FL. 13-25.
- Hallam, J. S., Edwards, B. J. N., Barnes, B., Stuart, A. J. (1973): A late glacial elk with associated barbed points from High Furlong, Lancashire. *Proceedings of the Prehistoric Society* 39: 100-128.
- Jörg S. (1990): personal communication.
- Koby, F. E. (1954): Les paléolithiques ont-ils chassé l'oursus des cavernes? *Actes de la Société Jurassien Emul.* 1954: 1-48.
- Kurtén, B. (1976): *The cave bear story: life and death of a vanished animal*. New York, Columbia University Press.
- Lambrecht, K. (1933). *Handbuch der Paläornithologie*. Berlin, Verlag Gebrüder Borntraeger.
- Legge, A. J., Rowley-Conwy, P. A. (1988): *Starr Carr revisited*. London, Centre for Extra-Mural Studies, Birbeck College, University of London.
- Moodie, R. L. (1923): *The antiquity of disease*. The University of Chicago Press, Chicago.



- Morel, P.* (1993): Une chasse à l'ours brun il y a 12'000 ans: nouvelle découverte à la Grotte du Bichon (La Chaux-de-Fonds). *Archäologie der Schweiz* 1993/3: 110-117.
- Mann, R., Murphy, S. P.* (1990): *Regional Atlas of Bone Disease*. Springfield, Il.: C.C. Thomas.
- Méniel, P.* (1994): Le boeuf, bête de somme & offrande en Gaule septentrionale. Aurochs, le retour. Aurochs, vaches & autres bovins de la préhistoire à nous jours. Lons-le-Saunier, Centre Jurassien du Patrimoine: 101-111.
- Müller, H.-H.* (1962): Die Säugetierreste aus der Burg Berlin-Köpenick nach den Grabungen von 1955 bis 1958. In J. Herrmann ed.: *Ergebnisse der archäologischen Stadtkernforschung in Berlin. Teil I. Köpenick. Ein Beitrag zur Frühgeschichte gross-Berlins*. Berlin, Akademie-Verlag: 81-97.
- Noe-Nygaard, N.* (1974): Mesolithic hunting in Denmark illustrated by bone injuries caused by human weapons. *Journal of Archaeological Science* 1: 217-248.
- Noe-Nygaard, N.* (1975): Bone injuries caused by human weapons in Mesolithic Denmark. In A. T. Clason ed.: *Archaeozoological studies. North Holland and American Elsevier, Amsterdam - New York*: 151-159.
- Noe-Nygaard, N.* (1989): Man-made trace fossils on bones. *Human Evolution* 4/6: 461-491.
- Pales, L.* (1958): Pathologie de l'Orsus des cavernes. *Annales de Paléontologie* 44: 3-44.
- Pucher, E.* (1988): Tierskelette aus den Urnenfelderzeitlichen Gruben von Stillfried. In F. Felgenhauer et al. eds.: *Stillfried: Archäologie - Anthropologie. Veröffentlichungen des Museums für Ur- und Frühgeschichte Stillfried, Sonderband 3*: 159-165.
- Reed, C. A., Schaffer, W. M.* (1972): How to tell the sheep from the goats. *Chicago: Field Museum of Natural History Bulletin* 43/3: 2-7.
- Roksandić, M. (ed.)* (2004): *Violent interactions in the Mesolithic. Evidence and meaning*. Oxford: British Archaeological Reports, International Series 1237.
- Takács, I.* (1993): A kajárpéc-pokolfadombi 13. századi ép lókoponya [An intact 13th century horse skull from Kajárpéc-pokolfadomb]. *Communicationes Archaeologicae Hungariae* 1993: 229-230.
- Tamás, L. (ed.)* (1987): *Állatorvosi sebészet [Veterinary surgery] 2*. Budapest, Mezőgazdasági Kiadó.
- Tasnádi-Kubacska A.* (1933): Geheilte fracturen am Penisknochen des Höhlenbären. *Wien, Palaeobiologica* 5: 159.
- Tasnádi-Kubacska A.* (1955): Der Penisknochen des Höhlenbären. *Acta Veterinaria Academica Scientiarum Hungaricae* 5: 145-152.



- Tasnádi-Kubacska A.* (1960): Az őszállatok pathológiája [The pathology of prehistoric animals]. Budapest, Medicina Könyvkiadó.
- Uerpmann, H.-P.* (1977): Schlachtereitechnik und Fleischversorgung im römischen Militärlager von Dangstetten (Landkreis Waldshut). *Regio Basiliensis XVIII/1*: 261-272.
- Vereschagin, N. K.* (1967): Primitive hunters and Pleistocene extinction in the Soviet Union. In P. S. Martin and H. E. Wright Jr. eds.: *Pleistocene extinctions - The search for a cause*. New Haven, Yale University Press: 365-398.
- Wilkenson, R. G., Van Wagenen, K. M.* (1993): Violence against women: prehistoric skeletal evidence from Michigan. *Midcontinental Journal of Archaeology* 18: 190-216.
- Wilson, T.* (1901): Arrow wounds. *American Anthropologist* 3: 513-531.
- Ziegler, R.* (1990): Neolitische und Kupferzeitliche Tierknochenfunde aus Südspanien. Los Castillejos/Los Millares. München, *Studien über frühe Tierknochenfunde von der Iberischen Halbinsel* 12.
- Zolnay, L.* (1982): Az elátkozott Buda – Buda aranykora [The cursed Buda – the Golden Age of Buda]. Budapest, Magvető Kiadó.