

CHOLEDOCHOLITHIASIS IN A DOG

COLEDOCOLITIASI IN UN CANE

VERONICA MARCHETTI, MARIO MODENATO,
SIMONETTA CITI, GRAZIA GUIDI

SUMMARY

A 14-year-old, intact male Siberian Husky was examined because of recurrence of inappetence, weakness and vomiting. Results of a CBC showed mild normocytic normochromic anaemia, hypereosinophilia with activated monocytes. Increase of ALT, AST, ALP, GGT, cholesterol and bilirubin supported a diagnosis of hepatobiliary disease. Abdominal ultrasound evaluation showed an incomplete extrahepatic biliary tract obstruction (EHBO), with suspected cholelithiasis and cholecystitis. Any evidence of radiopaque stone was showed at abdominal radiography.

A cause to the incomplete response to medical treatment with amoxicilline and clavulanic acid, ursodeoxycholic acid, vitamin E and silymarin, biliary surgery was performed, showing a hugely dilated biliary tree and several stones in the common bile duct. The choleliths were removed, using a combined approach through common bile duct, gallbladder and duodenum. During surgery a biopsy sample was collected, and histologically a diagnosis of chronic cholangitis with diffuse cholestasis and periportal fibrosis was formulated. The bacteribilia was not demonstrate to cultural and cytologic exam. Any complication was revealed in postoperative time; the clinical condition, CBC and serum biochemical profile were normal during the 8-month follow-up period.

Stones usually form in the gallbladder, but sometimes they can form directly in the common bile duct or move here from the biliary tree. Multiple small stones, causing incomplete obstruction, with a major one of 1,5x7mm, were removed from the final tract of the common bile duct in this dog.

Key words: cholelithiasis, dog, biliary surgery

RIASSUNTO

Un Siberian Husky, maschio intero di 14 anni, è stato portato alla nostra attenzione per episodi ricorrenti di disappetenza, abbattimento e vomito. L'emogramma rivelava la presenza di una lieve anemia normocitica normocromica, accompagnata da eosinofilia e monociti attivati. L'incremento di ALT, AST, ALP, GGT, colesterolo e bilirubina, evidenziabili nel profilo biochimico, supportavano l'ipotesi diagnostica di una patologia epatobiliare. L'ecografia addominale confermava la presenza di un'ostruzione incompleta delle vie biliari extraepatiche, con sospette colelitiasi e colecistite. Il radiogramma addominale non evidenziava radiopacità sospette nell'area epatica.

In seguito alla parziale risposta al trattamento medico a base di amoxicillina e acido

clavulanico, acido ursodeossicolico, vitamina E e silimarina, il paziente veniva sottoposto a terapia chirurgica. La laparotomia permetteva di confermare la dilatazione delle vie biliari e metteva in evidenza la presenza di diversi coeliti nel coledoco. I coeliti venivano rimossi con un approccio combinato attraverso il coledoco, la colecisti ed il duodeno. In sede chirurgica venivano eseguiti campionamenti biotici del fegato e della colecisti; l'esame istologico formulava diagnosi di colangite cronica con colestasi diffusa e fibrosi periportale. La bile risultava negativa per batteri sia all'esame citologico che colturale. Nel periodo postoperatorio non sono comparse complicazioni e durante il follow up di 8 mesi si è assistito ad una normalizzazione stabile dell'emogramma e del profilo biochimico.

I coeliti solitamente si formano nella colecisti, ma in alcuni casi si possono formare nel coledoco o arrivare in questa sede dalle vie biliari superiori. In questo cane, nel tratto finale del coledoco, sono stati rimossi alcuni piccoli coeliti ed un calcolo di 1,5x7 mm che causavano una incompleta ostruzione delle vie biliari.

Parole chiave: coelitiasi, cane, chirurgia biliare

INTRODUCTION

The incidence of disorders restricted to the gallbladder and the biliary tree is low, if compared with the many parenchymal hepatic conditions that occur in dogs (Center, 1996).

The extrahepatic biliary tract obstruction (EHBO) in dog is caused most frequently by pancreatic disease, biliary carcinoma, pancreatic carcinoma and intestinal neoplasia, and the biliary or intestinal inflammations are less commonly recognized. The cholelithiasis is considered an uncommon cause of EHBO, and canine bile has a very low lithogenic index, because of the low concentration of cholesterol and free Ca⁺ (Willard & Fossum, 2005; Center, 1996).

In a study (Kirpensteijn et al., 1993) about 29 cases of canine cholelithiasis, small breed aged female were overrepresented, although one case in a puppy poodle is reported (Rajaut & Diquélou, 2004).

Choleliths are often fortuitous ultrasonographic and, if radiopaque, radiographic findings (Nyland et al., 2002). Usually they do not cause any problem; nevertheless they may be associated with cholecistitis and rupture (Matthiesen & Lammerding, 1984; Duhautois, 2000). The cholelithiasis symptomatic cases generally show signs of abdominal pain, nausea and vomiting because of larger bile ducts and gallbladder rich autonomous innervation (Rothuizen, 2005; Ward, 2006). There is a limited number of reported cases of obstructive cholelithiasis in the literature.

In this report, a case of a cholelithiasis in a dog with chronic biliary inflammation is described.

CASE REPORT

A 14-year-old, intact male, vaccinated, Siberian Husky was examined because of inappetence, weakness and vomiting arising five-days before referral. The dog

was vomiting daily, sometimes with undigested food, sometimes with gastric mucus, without any relationship with feeding. Fecal aspect was normal. The owner reported that the same clinical signs were present 4 times in the last five months. These alterations were successfully treated with amoxicilline and a supportive fluid therapy for five days.

Physical examination revealed exclusively mild weakness and a body condition score of 2/5 (19 kg). A CBC (Hemat 8, Seac Diagnostics, Florence, Italy) and a serum biochemical profile (Slim, Seac Diagnostics, Florence, Italy) were performed (Tab. I and II). Mild normocytic normocromic anaemia and hypereosinophilia

Tab. I. CBC results.					
Analytes	day 0	day 20	day 40	day 100	Reference values
RBC (10 ⁶ /μL)	5.38	5.59	5.92	6.42	5.5-8
Hgb (g/dL)	12.4	12.7	14.8	14.5	12-18.5
Hct (%)	36.4	36.1	37.4	41.5	37-55
MCV (fL)	68	65	63	65	60-76
MCH (pg)	23.1	22.7	23	22.6	20-27
MCHC (g/dL)	34.2	35.2	36.3	34.9	32-38.5
RDW (%)	12.6	13.1	14.2	14.1	12-16
Anisocytosis	++		+++		
Polychromasia			+		
WBC (/μL)	10,600	6,900	14,800	7,200	6,000-16,000
Neutrophils seg (/μL)	6,780	4,420	11,250	4,750	3,000-11,500
Neutrophils bands (/μL)	0	0	0		0-300
Lymphocytes (/μL)	1,270	830	1480	2,020	800-3,600
Eosinophils (/μL)	1,700	830	1180	140	100-1,250
Monocytes(/μL)	850	830	890	290	150-1,350
Basophils(/μL)	0	0	0	0	0-100
Reactive lymphocytes			++	+	
Activated monocytes	+		+		
Platelets (/μL)	345,000	365,000	366,000	262,000	240,000-400,000
MPV (fL)	8.2	8.6	8.7	7.8	4.9-7
PDW (%)	13.3	13.1	13.5	12.4	20-50
PLT estimation	adequate	adequate	adequate	adequate	adequate
macrothrombocytes			+		

with activated monocytes were the sole alterations of CBC. The leakage enzymes (alanine aminotransferase-ALT, aspartate aminotransferase-AST) and cholestasis enzymes (alkaline phosphatase-ALP, gamma glutamyl transpeptidase-GGT) showed a marked increase with a mild increase of total bilirubin. Hypoalbuminemia and hyperglobulinemia were also present. *Leishmania infantum*, *Ehrlichia canis*, *Anaplasma phagocytophilum*, *Rickettsia Rickettsii* and *Rickettsia conorii* serology

Tab. II. Biochemical profile results.					
Analytes	day 0	day 20	day 40	day 100	Reference values
BUN (mg/dL)	25.6	24.2	28.4	68.2	20-60
Creatinine (mg/dL)	0.65	0.91	1.02	1.32	0.8-1.5
Glucose (mg/dL)	88.4	88.2	95.5	92	80-120
ALT (U/L)	506	56.9	506.3	25.6	17-53
AST (U/L)	186	33	102	23	20-34
ALKP (U/L)	4058	616.2	1452	51.9	50-130
GGT (U/L)	9.66	4.4	7.8	2.9	1.5-6.5
Tot Bilirubin (mg/dL)	0.46	0.13	0.2	0.15	0.1-0.3
Cholesterol (mg/dL)	265.6	177.6	327	253.4	150-265
Sodium (mMol/L)	141	140	143	143	140-155
Potassium (mMol/L)	3.80	4.01	3.79	3.70	3.5-5.1
Ionized calcium (mMol/L)	1.15	1.14	1.19	1.22	1.13-1.32
Total protein (g/dL)	7.01	6.12	6.61	6.92	5.5-7.7
*Albumin (%)	32	41.1	43.4	46.4	45-65
*Alfa 1 globulin	2.7	2.9	2.7	8.6	2.5-4.5
*Alfa 2 globulin	18.7	18.3	22.4	8.1	9-17
*Beta globulin	37.5	21.7	15.9	28.5	15-23
*Gamma globulin	9.1	16	15.6	8.4	6.5-12
A/G ratio	0.47	0.70	0.77	0.87	0.6-1.3
* obtained by SPE					

were negative. Results of the urinalysis were within normal limits with exception of a mild bilirubinuria.

Abdominal ultrasound showed (Figg. 1 and 2) a distended gallbladder, with thickened, irregular and hyperechoic walls; its content was strongly corpuscular, with acoustic shadowing. Intrahepatic biliary ducts were dilated and tortuous. The common hepatic duct was dilated, with the latter presenting an intraluminal hyperechoic image close to the duodenal papilla, measuring about 7 mm in diameter, with acoustic shadowing artifact.

A diagnosis of incomplete extrahepatic biliary tract obstruction (EHBO), with suspected cholelithiasis, and cholecystitis was formulated. Abdominal radiography did not show biliary mineralization. A therapy with amoxicilline and clavulanic acid (14 mg/kg per os two times daily), ursodeoxycholic acid (15 mg/kg/day divided over two doses), vitamin E (10 IU/kg/day) and silymarin (20 mg/kg/day) was begun.

On day 20, a general improvement was reported and the dog appeared vivacious and with a good appetite; no more episodes of vomiting were referred. The patient weight was 20.8 kg. The results of CBC and biochemical analysis showed a general improvement (Tab. I and II), whereas on ultrasonography the findings were unchanged.

Owing to the good response to medical treatment, the same therapy was continued; the antibiotic therapy was discontinued.

Three weeks later, on day 40 after the initial presentation, the patient was re-

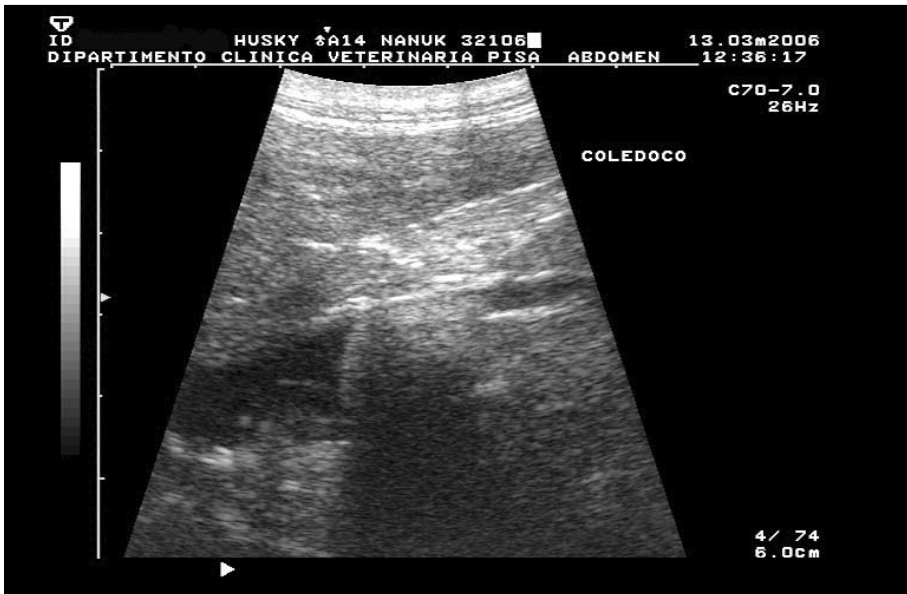

Fig. 1. Dilated common hepatic duct, with anechoic and slightly corpusculated content; in the most caudal portion a hemispheric structure, with a smooth surface, can be seen; this structure is causing a posterior acoustic shadowing

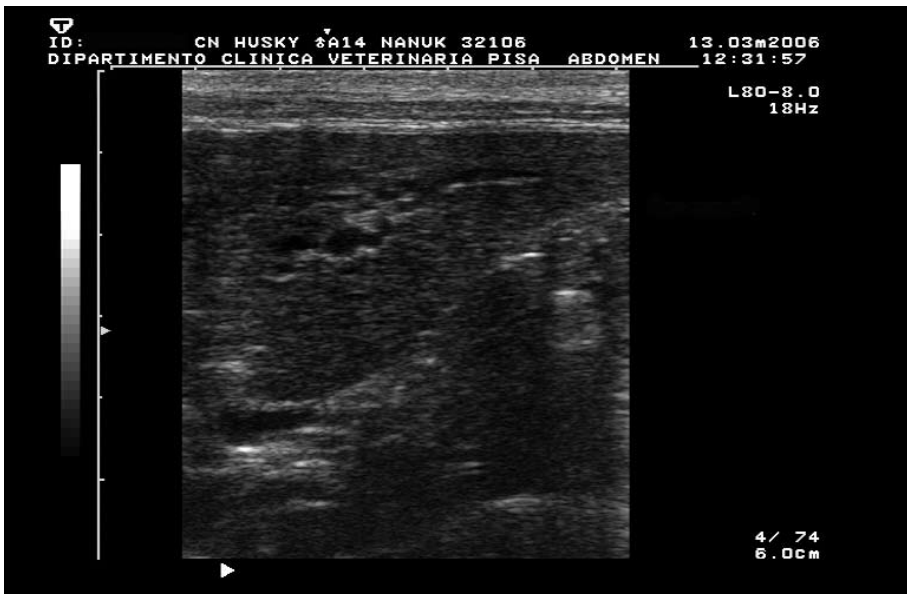


Fig. 2. Left lateral hepatic lobe: the dilated bile ducts can be visualized as anechoic structures, with hyperechoic walls and sinuous pattern.

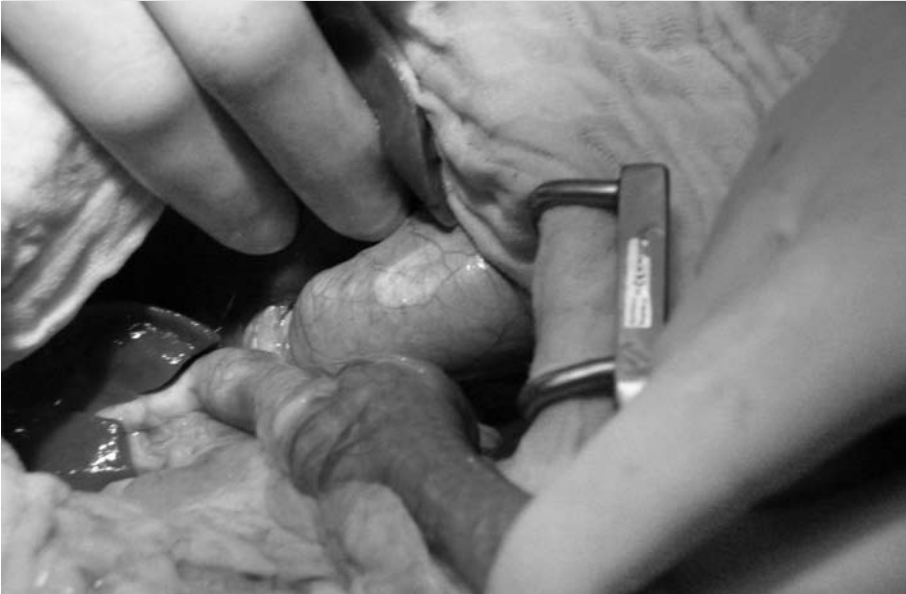

Fig. 3. Dilated biliary tree (head top); the common bile duct diameter is similar to the duodenum.

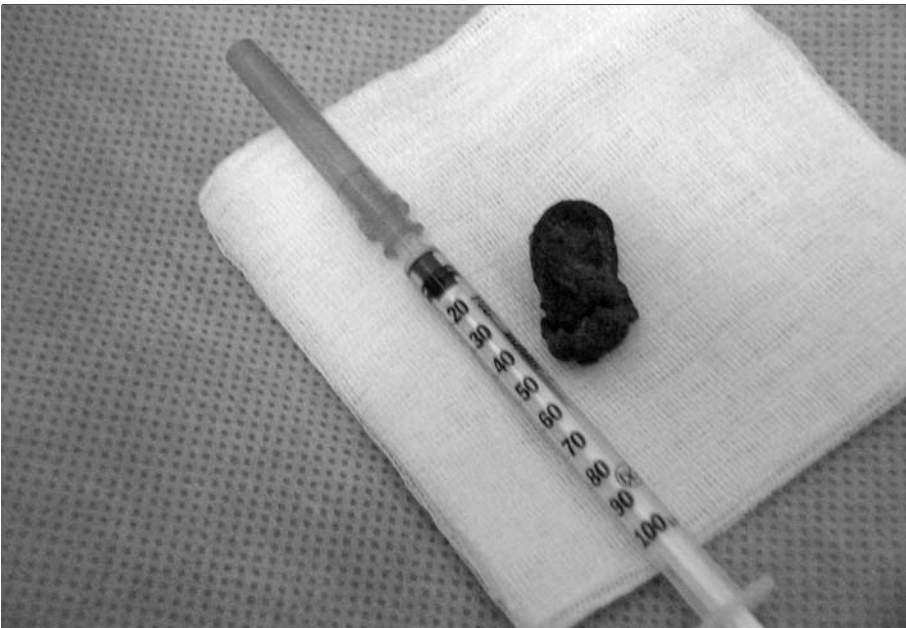


Fig. 4. The major choledochal stone.

examined for poor appetite. The physical examination showed good conditions with further weight gain (21.5 kg); moreover the dog was mildly depressed. On the basis of CBC, biochemical profile (ALT, AST, ALP increased and hypercholesterolemia) and imaging results (unchanged), a surgical treatment was proposed. Prothrombin time and Partial Prothrombin time were done prior to surgery and were both within normal reference ranges.

The liver, the gallbladder and the biliary tree, and the descending duodenum were exposed via a median laparotomy. The gallbladder and the liver appeared grossly normal. A big cholelith, with several smaller other choleliths, were found in the distal part of the common bile duct. The common bile duct and the cystic duct appear hugely dilated (more than 1,5 cm) (Fig. 3). The big cholelith was mobile, but many attempts to move it toward the gallbladder were unsuccessful. A combined approach to the gallbladder, the common bile duct and the sphincter of Oddi was decided, to ensure the possibility to remove all the choleliths and to control the bile duct patency. A bile sample was collected by fine needle aspiration (22G) for bacteriologic and cytologic examination.

After the choledochotomy and the major cholelith (a brownish and soft stone of 2,5x1cm, Fig. 4) removal, the gallbladder was incised to aspirate and flush all the remaining bile and smaller choledocholiths. Then a small duodenotomy, made at the level of the sphincter of Oddi, was performed and the sphincter and the common bile duct cannulated with a soft 12F catheter, to verify the sphincter patency and irrigate to guarantee the complete removal of the smaller choleliths from the distal common bile duct tract. The duodenum, the common bile duct and the gallbladder were closed with 4/0 polygliconate, in a simple layer interrupted pattern the duodenum and the common bile duct, in a double layer continuous pattern the gallbladder. Two biopsy forceps samples from the liver were collected. The abdomen was then copiously flushed with warm saline solution and the abdominal wall closed in a routine manner.

At histology, the liver architecture was maintained; at low magnification, a periportal fibrosis was revealed; in these areas chronic inflammation infiltrate, constituted by non degenerate neutrophils, rare eosinophils and small lymphocytes was present. Histopathological examination of the gallbladder was unremarkable.

A diagnosis of chronic cholangitis with diffuse cholestasis was formulated.

The bile was negative for bacteria at cytologic and cultural exam. The cholelith analysis was not performed. No complications were reported in the postoperative period, and therapy with the same antibiotic and hepato-protectors was continued, for 15 days and 30 days respectively.

Two months after surgery, the CBC and biochemical abnormalities were normalized (Tab. I and II) and the dog showed good general condition. The last clinical evaluation was performed 8 months from the date of surgery and the dog appeared to be sound.

DISCUSSION

The pathogenesis of cholelithiasis in dogs is unknown. Proposed cause for formation of choleliths include trauma, biliary stasis, diet alterations, cholecystitis and parasitic

or bacterial biliary infection (Kirpensteijn et al., 1993). Cholelithiasis was found in a dog with biliary neoplasia (Brömel et al., 1998), metastatic liver hemangiosarcoma (Jacobs & O'Brien, 1997) and hyperadrenocorticism (Huang et al., 2002).

Choleliths in dogs, as in human, have been classified as cholesterol, pigment or mixed. The stones appear usually dark brown or black, and soft, as described in our case (Rothuizen, 2005). Mixed or cholesterol choleliths contain more than 70% cholesterol monohydrate plus an admixture of calcium salts, bile acids and pigments, proteins, fatty acids and phospholipids. Pigment stones contain <10% cholesterol and are primarily composed of calcium bilirubinate, and appear radiopaque. In dog the prevalence of radiopaque stones is higher (48%) than in human (15%) (Kirpensteijn et al., 1993). In this dog, the stone was not radiopaque and presumed to be composed of cholesterol or mixed.

The presence of bacteria predisposes to calcium-bilirubinate stones. Some bacteria produce β -glucuronidase that deconjugates soluble bilirubin glucuronide to insoluble unconjugated bilirubin and glucuronic acid. Unconjugated bilirubin may then form insoluble calcium-bilirubinate (Kirpensteijn et al., 1993). Moreover, recent sensitive polymerase chain reaction techniques have shown the presence of bacterial DNA also in pure or mixed cholesterol stones, suggesting that bacteria may be related to the formation of any kind of gallstones (Lee et al., 1999).

In our case the bacteremia was not demonstrated by cultural exam and the mineralization was not identified. It is possible that bile was sterile at the moment, also due to the antibiotic therapy (stopped 20 days before surgery), but stones formation in aseptic biliary stasis is also possible. During the stasis within the biliary tree, the bile becomes progressively thicker as water is absorbed, and secondary inflammation induced by bile acids can provoke mucin secretion. Hypersecreted gallbladder mucin is well known to be precursor in both cholesterol and pigment stone formation (Hong-Ja et al., 2003). Also the impaired gallbladder motility can contribute to gallstone precipitation (Center, 1996).

The chronic inflammation in our patient was present and supported by various clinical-pathological data. Hypereosinophilia without leucocytosis, the activated monocytes and the mild normocytic normochromic anemia related to chronic gastroenteric inflammation (Schultze, 2000). Hyperglobulinemia suggests a persistent inflammation and the moderate hypoalbuminemia is compatible with hyperglobulinemia inducing down-regulation of synthesis and, improbably, also with a lesser production by liver. The hyperbilirubinemia supports the cholestasis alteration with hyperphosphatemia, the increase of GGT and hypercholesterolemia, because the excretion of bilirubin into the canalicular lumen is against a high concentration gradient and is the rate-limiting step in its elimination (Meyer & Harvey, 1998).

The ALT and AST increase supports the parenchymal involvement due to toxic effects of bile acids, also if an exclusively degenerative pattern was evidenced at histopathologic exam. The mild hepatocytes alteration agrees with the good output of this case, whereas a fibrosis in the portal areas was present.

Ultrasonography resulted an indispensable and the most informative method to examine the presence and the nature of this biliary disorder.

Gallbladder stones can easily be detected sonographically when they have both

distinct echogenicity and discrete posterior acoustic shadowing, becoming more evident as the size and calcium content of the calculus increase. In the gallbladder the stones shift to the dependent portion when the animal is repositioned. Calculi in the extrahepatic ducts or common hepatic duct are difficult to detect because of interference from bowel gas (Nyland et al., 2002). Their identification can be tempted by detection of the twinkling artifact, which appears as a quickly fluctuating mixture of Doppler signals with an associated characteristic spectrum of noise (Weichselbaum et al., 2000; Louvet, 2006).

In the present case, we have not been able to detect the twinkling artifact, because of the presence of gastric gas, which allowed only brief imaging of the stone; furthermore, it has to be noted that there is a grade of correlation between the biochemical composition of biliary stones and the grade of twinkling artefact.

In the absence of a definitive diagnosis, CT is considered necessary.

We suspected that the stone in the common hepatic duct was causing biliary obstruction or sub-obstruction because we could visualize dilated intrahepatic bile ducts; these can be differentiated from portal veins by their sudden changes in lumen caliber, irregular walls, and absence of signal to Doppler evaluation. The gold standard for biliary ducts obstruction is hepatobiliary scintigraphy, which allows a functional study of the biliary system (Head & Daniel, 2005).

The poor calcified aspect of the cholelith and the signs of incomplete obstruction induced to defer the surgery. Non-calcified stones may resolve in response to oral medication with ursodeoxycholic acid (Rothuizen, 2005), that modulate the toxic bile acid pool, shows choleric effect, decrease the hepatic production and secretion of cholesterol; the sylimarin and the vitamin E reduce the liver oxidant damage. The antibiotic used is excreted in therapeutic concentration in the bile and is active against gram-negative bacteria, since most of the bacteria isolated reported in literature were enterococci (Kirpenstenijn et al., 1993). The absence of pure cholesterol choleliths and the dimensions of this stone may explain the failure of medical treatment. In humans, where gallstone dissolution has been intensely studied, stones dissolve no faster than approximately 1 mm of diameter per month (Senior et al., 1990).

Surgical options for the cholelithiasis in dog are represented by cholecistotomy, choledochotomy and, finally, by cholecistectomy and biliary diversion (Martin, 1993; Fossum, 2002; Mehler & Bennet, 2006).

Although the gallbladder is the site of formation of most choledocholiths, stones can form primarily in the duct, as in our case. In the choledocholithiasis, our preferred method for choleliths removal is represented by cholecistotomy, after retrograde dislocation of the choledocal stones into the gallbladder; this is usual accomplished by digital retropulsion or by retrograde catheterization via the sphincter of Oddi, approached with a small antimesenteric duodenotomy. We prefer this surgical option every time retropulsion is possible, especially when the choledocal diameter is less than 5mm, with possible postsurgical stenosis

Although the parietal healing of the gallbladder is sometimes critical, cholecistotomy shows a reduced postoperative morbidity with respect with choledochotomy or biliary diversion (Mehler & Bennet, 2006).

The choledochotomy is usually adopted when the choledocal diameter is more

than 5mm, because the possibility of postsurgical stenosis is high, even when the suture is made transversely on a longitudinal incision.

All the techniques of biliary diversion are associated with high postsurgical morbidity, and are reserved to those cases where neoplastic involvement of the region, fibrotic reaction around the sphincter, or severe bile tree ruptures make anatomic restoration impossible (Fossum, 2002).

In our case, retropulsion was attempted without success, so choledochotomy represented the unique choice. Since many small stones were present, we prefer to perform a combination of the choledochotomy with cholecystotomy and duodenotomy to ensure complete removal of all stones, and contemporarily to verify the sphincter patency and to flush all the biliary tree. The big choledocal diameter (more than 1cm) and the healthy appearance of the gallbladder made us comfortable with this approach, with minimal postsurgical risks of strictures or bile leakage or suture dehiscence.

There are a limited number of reported cases of obstructive cholelithiasis in the literature.

BIBLIOGRAFIA

- BRÖMEL C., SMEAK D.D., LEVEILLE R. (1998). Porcelaine gallbladder associated with primary biliary adenocarcinoma in a dog. *J Am Vet Med Assoc*, 213(8): 1137-1139.
- CENTER S. (1996). Diseases of the gallbladder and biliary tree. In: Strombeck's Small Animal Gastroenterology, Guilford, Center, Strombeck, Williams, Meyer, third ed. W.B. Saunders Company, Philadelphia, 860-888.
- DUHAUTOIS B. (2000). Rupture of the gall bladder secondary to cholelithiasis and necrotising cholecystitis. *Prat Med Chir Anim Comp*, 35: 581-584.
- FOSSUM T.W. (2002). Surgery of the extrahepatic biliary system. In Fossum T.W.: *Small Animal Surgery*, 2nd ed., Mosby, St.Louis.
- HEAD L.L., DANIEL G.B. (2005). Correlation betweenhepatobiliary scintigraphy and surgery or post-mortem examination findings in dogs and cats with extrahepatic biliary obstruction, partial obstruction or patency of the biliary system: 18 cases (1995-2004). *JAVMA*, 227: 1618-1624.
- HONG-JA K., SUNG-KOO L., MYUNG-HWAN K., DONG-WAN S., YOUNG-II M. (2003). Cyclooxygenase-2 mediates mucin secretion from epithelial cells of lypopolysaccharide-treated canine gallbladder. *Dig Dis Sci*, 41(12): 2423-2432.
- HUANG H., LIEN Y., CHANG P., YAN C. (2002). Case report: concurrent cholelithiasis and hyperadrenocorticism in a dog. *Taiw Vet. J.*, 28(4): 266-271.
- JACOBS T.M., OBRIEN R.T. (1997). What is your diagnosis? Hepatomegaly and cholelithiasis with mineralization of the biliary tract. *JAVMA*, 211: 291-292.
- KIRPENSTEIJN J., FINGLAND R.B., ULRICH T., SIKKEMA D.A., ALLEN S.W. (1993). Cholelithiasis in dogs: 29 cases (1980-1990). *JAVMA*, 202: 1137-1142.
- LEE D.K., TARR P.I., HAIGH W.G., LEE S.P. (1999). Bacterial DNA in mixed cholesterol gall stones. *Am. J. Gastroenterol.*, 94: 3502-3506.
- LOUVET A. (2006). Twinkling artefact in small animal Color-Doppler sonography. *Vet. Radiol. Ultrasound*, 47(4): 384-390.
- MATTHIESEN D.T., LAMMERDING J. (1984). Gallbladder rupture and bile peritonitis secondary to cholelithiasis and cholecystitis in a dog. *JAVMA*, 184: 1282-1283.
- MARTIN R. (1993). Liver and biliary system: surgical diseases and procedures. In Slatter D.: *Textbook of Small Animal Surgery*, 2nd ed., W.B.Saunders, Philadelphia.

- MEHLER S.J., BENNETT R.A. (2006). Canine extrahepatic biliary tract disease and surgery. *Comp. Cont. Ed.*, 30(4): 302-314.
- MEYER D.J., HARVEY J.W. (1998). Evaluation of hepatobiliary system and skeletal muscle and lipid disorders. In: *Veterinary laboratory medicine – Interpretation & diagnosis*, Meyer DJ, Harvey JW, W.B.Saunders Company, Philadelphia, 157-186.
- NYLAND T.G., MATTOON J.S., HERRGESELL E.J., WISNER E.R. (2002). Urinary tract. In: *Nyland TG, Mattoon JS: Small animal diagnostic ultrasound, 2nd ed.* W.B. Saunders, Philadelphia.
- RAJAUT F., DIQUELOU A. (2004). Colelitiasi e colecistite in un cucciolo. *Summa*, 4: 61-64.
- ROTHUIZEN J. (2005). Diseases of the biliary system. In: *BSAVA Manual of canine and feline gastroenterology*, Hall EJ, Simpson JW, Williams DA, 2nd ed, BSAVA, 269-278.
- SENIOR J.R., JOHNSON M.F., DETURCK D.M. (1990). In vivo kinetics of radiolucent gallstone dissolution by oral dihydroxy bile acids. *Gastroenterol.*, 99: 243-251.
- SHULTZE E.A. (2000). Interpretation of canine leukocyte responses. In: *Schalm's Veterinary Hematology*, Feldman BF, Zinkl JG, Jain NC, Lippincott Williams & Wilkins, Philadelphia, 366-380.
- WARD R. (2006). Obstructive cholelithiasis and cholecystitis in a keeshond. *Can. Vet. J.*, 47: 1119-1121.
- WEICHELBAUM R.C., FEENEY D.A., JESSEN C.R., OSBORNE C.A., DREYTSER V., HOLTE J. (2000). Relevance of sonographic artifacts observed during in vitro characterization of urocystolith mineral composition. *Vet. Radiol. Ultrasound*, 41: 438-446.
- WILLARD M.D., FOSSUM T.W. (2005). Diseases of the gallbladder and extrahepatic biliary system. In: *Textbook of veterinary internal medicine*, Ettinger SE, Feldman EC, sixty ed., Elsevier Saunders, St. Louis, Missouri, 1478-1482.

