



## Središnja medicinska knjižnica

**Popović A, Demirović A., Spajić B., Štimac G., Krušlin B., Tomas D.  
(2010) *Expression and prognostic role of syndecan-2 in prostate cancer*. *Prostate Cancer and Prostatic Diseases*, 13 (1). pp. 78-82.  
ISSN 1365-7852**

<http://www.nature.com/pcan>

<http://dx.doi.org/10.1038/pcan.2009.43>

<http://medlib.mef.hr/892>

University of Zagreb Medical School Repository

<http://medlib.mef.hr/>

EXPRESSION AND PROGNOSTIC ROLE OF SYNDECAN-2  
IN PROSTATE CANCER

Alek Popović MD<sup>1</sup>, Alma Demirović MD<sup>2</sup>, Borislav Spajić MD, PhD<sup>1</sup>,  
Goran Štimac MD<sup>1</sup>, Božo Krušlin MD, PhD<sup>2,3</sup>, Davor Tomas MD, PhD<sup>2,3</sup>

<sup>1</sup>University Department of Urology and <sup>2</sup>University Department of Pathology, Sestre milosrdnice University Hospital; <sup>3</sup>School of Medicine, University of Zagreb, Zagreb, Croatia

Short title: Syndecan-2 in prostate cancer

Correspondence to:

Davor Tomas, MD, PhD

University Department of Pathology

Sestre milosrdnice University Hospital

HR-10000 Zagreb, Croatia

E-mail: [dtomas@kbsm.hr](mailto:dtomas@kbsm.hr)

Tel: +385 1 3787 465

Fax: +385 1 3787 244

## ABSTRACT

Syndecans are a four-member family of transmembrane heparan sulfate proteoglycans that have different functions in cell signalling, adhesion, cytoskeleton organization, migration, proliferation and angiogenesis. Several studies investigated the role of syndecan-2 (SDC2) in different carcinomas, however, only one being focused on SDC2 in prostate cancer.

SDC2 expression and relationship with established prognostic features were assessed in a cohort of 86 patients treated with radical prostatectomy for clinically localized prostate adenocarcinoma.

SDC2 expression was present in the majority of prostate cancers and absent in only 11.6% of cases. SDC2 expression was also recorded in cells of prostatic intraepithelial neoplasia, whereas normal prostatic epithelial tissue and stroma did not express SDC2. SDC2 overexpression in prostate cancer was significantly associated with established features indicative of worse prognosis such as higher preoperative PSA ( $p=0.011$ ), higher Gleason score ( $p<0.001$ ), positive surgical margins ( $p<0.003$ ), and extraprostatic extension of disease ( $p<0.003$ ). Moreover, expression of SDC2 was also associated with biochemical disease progression on univariate analysis ( $p<0.001$ ).

Study results supported the potential role of SDC2 in prostatic carcinogenesis and cancer progression. Moreover, SDC2 could serve as an additional prognostic marker that might help in further stratifying the risk of disease progression in patients with prostate cancer.

**Key words:** syndecan-2, prostate cancer, prognosis

## INTRODUCTION

Syndecans are a four-member family of transmembrane heparan sulfate proteoglycans expressed on the surface of many different adherent and non-adherent cells. Syndecans are composed of a short C-terminal cytoplasmic domain, an N-terminal signal peptide, an ectodomain containing several consensus sequences for glycosaminoglycan attachment, and a transmembrane domain with a putative protease cleavage site at the proximal side.<sup>1,2</sup>

Within the family, the extracellular domain sequences are molecule specific, but the transmembrane and cytoplasmic domain are highly conserved, implying the possibility of conserved biological role. Despite the high homology observed in the cytoplasmic domain, each syndecan has its own unique function that is attributed to differences in amino acid sequences in the middle of the cytoplasmic domain.<sup>2-5</sup>

Syndecans have different functions ranging from cell-cell and cell-extracellular matrix adhesion to the regulation of heparan sulfate-binding growth factor activity and tyrosine kinase signalling pathway as well as cytoskeleton organization, migration, proliferation and angiogenesis.<sup>1-6</sup>

Syndecan-2 (SDC2) was originally biochemically characterized as one of the major heparan sulfate glycosaminoglycans containing cell surface proteins expressed in lung fibroblasts.<sup>7</sup> Early recognizable role of SDC2 was cell adhesion and migration but recently SDC2 has also been implicated in the tyrosine kinase signalling pathway activation, cancer progression and angiogenesis.<sup>8-12</sup> Several studies investigated the role of SDC2 in different carcinomas<sup>13-15</sup>, however, only one was focused on SDC2 in prostate cancer.<sup>16</sup>

SDC2 expression and relationship with established prognostic features were assessed in a cohort of 86 patients treated with radical prostatectomy for clinically

localized prostate adenocarcinoma, in order to determine the expression and prognostic value of SDC2 in prostate cancer.

## PATIENTS AND METHODS

### Patients

The study included 86 consecutive patients, median age 65.0 (range 52-74, interquartile range 61-68) years, treated with radical retropubic prostatectomy and bilateral lymphadenectomy for clinically localized prostate adenocarcinoma at University Department of Urology, Sestre milosrdnice University Hospital, Zagreb, between January 1, 2002 and December 31, 2003. All patient identifiers were removed and replaced by unique study numbers, linked to the original identifiers by a single file kept under high security. A minimum of 60 months of follow up and the retrieval of archival tissue block was conducted under institutional review board approval.

After radical prostatectomy, patients were scheduled for clinical examination and serum prostate specific antigen (PSA) evaluation every three months for the first year, semi-annually from the second year, and annually thereafter. The study end point (time of recurrence) was defined as two consecutive rising serum PSA values greater than 0.2 ng/mL.

Overall follow up ranged from 6 to 84 (median 64.5, interquartile range 28-72) months. Thirty of 86 (34.9%) patients had biochemical disease progression with a median time of progression of 18.5 (range 6-63, interquartile range 9-30) months.

Preoperative PSA ranged from 4.2 to 24.4 ng/mL (median 8.65, interquartile range 6.6-12.3), and PSA of biochemical disease progression ranged from 0.3 to 3.2 ng/mL (median 0.99, interquartile range 0.6-1.7).

The clinical stage was assigned by the operative surgeon according to the criteria of the International Union against Cancer.<sup>17</sup> The Gleason distribution with Gleason patterns is shown in Table 1. Overall, 22 of 86 (25.6%) patients had extraprostatic extension of disease; 12 (54.4%) of them had extension through the capsule, 5 (22.8%)

had seminal vesicle invasion, and 5 (22.8%) had both extension through the capsule and seminal vesicle invasion. Only two patients had metastases to lymph nodes. None of the patients was treated with hormone or radiation therapy before or after radical prostatectomy, and none had secondary cancer.

## Methods

Specimens were fixed in 10% buffered formalin, embedded in paraffin, cut at 5-mm thickness, and routinely stained with haematoxylin and eosin. The diagnosis of adenocarcinoma was histologically confirmed in all cases. All slides submitted to immunohistochemistry analysis were so chosen that Gleason patterns in the slides most closely recapitulated postoperative Gleason score and also contained areas of non-neoplastic prostate tissue.

Deparaffinization and immunohistochemical staining were performed following the Microwave Streptavidin ImmunoPeroxidase (MSIP) protocol on a DAKO TechMate™ Horizon automated immunostainer (DAKO, Copenhagen, Denmark). We used primary monoclonal antibodies to syndecan-2 ((1F10/B8): sc-73516, dilution 1:100, Santa Cruz Biotechnology, Inc., CA, USA). Colon cancer tissue served as a positive control and removal of the primary antibody was used as a negative control.

To evaluate the intensity of SDC2 expression in prostate cancer, the percentage of positively stained carcinoma cells was examined in the whole amount of tumour on the chosen slide. The staining intensity was graded on a 0-3 scale and expressed as 0, up to 10% of positive carcinoma cells; low, more than 10%-25% of positive carcinoma cells; moderate, more than 25%-50% of positive carcinoma cells; and high, more than 50% of positive carcinoma cells. We applied a scanning system similar to that used in previous studies of syndecan-1 (SDC1) expression in prostate cancer, where an at least

moderate staining intensity was required in more than 10% of tumour cells to define SDC2 overexpression.<sup>18,19</sup> All samples were examined independently by three observers (A. D., B. K. and D. T.), and any difference was resolved by a joint review.

Statistical analysis was performed using Mann-Whitney U test, Kruskal-Wallis test,  $\chi^2$ -test, Kaplan-Meier test and Cox proportional-hazards regression test. The levels of statistical significance were set at least at  $p < 0.05$ .



## RESULTS

Syndecan-2 was overexpressed in 66 (76.7%) prostate cancer (Fig. 1A). Twenty one (24.4%) had low, 18 (20.9%) moderate and 27 (31.4%) high intensity of overexpression. Immunohistochemical reaction was membranous and intracytoplasmatic, granular (Fig. 1B). Twenty (23.3%) prostate cancers showed no overexpression, and 10 (11.6%) of them showed no reaction for SDC2. In benign glands, expression was not observed but some glands with prostatic intraepithelial neoplasia (PIN) showed reaction to SDC2 (Fig. 1C). Prostate stromal cells did not express SDC2, and any staining in the stroma was considered background immunoreactivity.

Patient age was not significantly different between the patients with and without SDC2 overexpression ( $p=0.499$ ).

The patients with SDC2 overexpression had a significantly higher level of preoperative PSA ( $p=0.011$ ). Preoperative PSA positively correlated with the intensity of SDC2 expression ( $p=0.048$ ).

Gleason score was significantly higher in patients with SDC2 overexpression ( $p<0.001$ ). Among patients with Gleason score 7, those with score 7 (4+3) had a higher rate of SDC2 overexpression than those with score 7 (3+4) ( $p=0.045$ ). Comparison of Gleason score and intensity of SDC2 overexpression showed no correlation ( $p=0.061$ ).

All 22 (100%) patients with extraprostatic extension and 44 (68.7%) patients without extraprostatic extension of disease had SDC2 overexpression. Extraprostatic extension of disease was more frequently observed in patients with SDC2 overexpression ( $p<0.003$ ), in particular those with high intensity of overexpression ( $p<0.021$ ). Disease extension through the capsule correlated with SDC2 overexpression ( $p=0.011$ ), whereas extension to seminal vesicles showed no such correlation ( $p=0.064$ ).

None of the patients without SDC2 overexpression had biochemical disease progression. Disease free period was significantly reduced with the intensity of SDC2 overexpression and patients with moderate SDC2 overexpression had shortest disease free period on univariate analysis ( $p < 0.001$ ) (Fig. 2).

On multivariate analysis, SDC2 overexpression was not associated with disease free period ( $p = 0.96$ ), while the most significant prognostic factors for biochemical disease progression were preoperative PSA ( $p = 0.013$ ) and extraprostatic extension of disease ( $p < 0.001$ ).

## DISCUSSION

Several studies investigated syndecans in prostate cancer, but were mostly focused on syndecan-1 (SDC1)<sup>18-21</sup>, and only one addressed expression of SDC2.<sup>16</sup> Contreras *et al.*<sup>16</sup> found SDC2 to be expressed in normal prostate tissue, benign prostatic hyperplasia (BPH), PIN and prostate cancer. In BPH, SDC2 was expressed in plasma membrane of epithelial cells, in particular basal cells, and in the basolateral zone of secretory cells. In PIN regions, a high intensity staining was found in basal cells. In prostate cancer, membrane and granular cytoplasmic staining was observed in most cases.<sup>16</sup>

In our study, SDC2 was expressed in the membrane and cytoplasm of the majority of prostate cancer cases, with only 11.6% of cases showing no expression, which is similar to the study conducted by Contreras *et al.*<sup>16</sup> SDC2 expression was also observed in some epithelial cells of PIN lesions but normal prostatic epithelial tissue and prostatic stroma did not express SDC2. These results are opposite to those reported by Contreras *et al.*<sup>16</sup>, where reaction in PIN was located in basal cells, whereas nonmalignant epithelial cells also showed SDC2 reactivity in a somewhat similar pattern as described for SDC1 by Chen *et al.*<sup>21</sup>

Our results on SDC2 expression in prostate were consistent with previous reports on SDC2 expression in colon carcinoma cells. Normal colon epithelial cells did not express SDC2, whereas colon carcinoma cells showed SDC2 up regulation resulting in an increased SDC2 expression that proved crucial for tumorigenicity.<sup>9,11,14</sup> Park *et al.*<sup>14</sup> demonstrated SDC2 to be necessary for cell cycle progression and cell-matrix interaction in colon cancer cells. Moreover, an increased level of SDC2 led to a less adhesive phenotype and loss of contact inhibition.<sup>12,13</sup> These results could point to two conclusions; first, normal colon epithelial cells might acquire SDC2 expression

activities during carcinogenesis, and second, expression of SDC2 is necessary for tumourigenic activity.<sup>9,12</sup>

Syndecan-2 may function in colon cancer cells by at least two different mechanisms. First, increased expression of SDC2 may be related to the loss of cell-extracellular matrix interaction and contact inhibition. Second, SDC2 may be necessary for tumour angiogenesis, acting as a co-receptor for signalling molecules important for vascular proliferation, such as VEGF, EphB2 or FGF-2. Both mechanisms could contribute to tumour growth and metastatic potential of cancer cells.<sup>2,9-12</sup>

A similar role of SDC2 could be proposed in prostate cancer because normal epithelial cell did not express SDC2, whereas its expression appeared in cells of PIN lesions and carcinoma, indicating SDC2 activities during carcinogenesis.

In our study, SDC2 overexpression in prostate cancer was significantly associated with established features indicative of worse prognosis such as higher preoperative PSA, higher Gleason score, positive surgical margins, and extraprostatic extension of the disease. Moreover, SDC2 expression was also associated with biochemical disease progression on univariate analysis.

Contreras *et al.*<sup>16</sup> report a decreased SDC2 expression in carcinoma with high Gleason score (>7). This result could indicate better prognosis for patients with SDC2 expression. Our results were somewhat different, as the expression of SDC2 positively correlated with Gleason score and was an indicator of worse prognosis.

Similar results have been previously reported for SDC1.<sup>18,19,21</sup> Zellweger *et al.*<sup>18</sup>, Shariat *et al.*<sup>19</sup> and Chen *et al.*<sup>21</sup> found SDC1 expression to be decreased in prostate cancer compared with the adjacent normal cells. However, within prostate cancer areas, SDC1 expression was associated with established features that indicated worse prognosis such as higher preoperative PSA levels, higher Gleason score, metastases to

regional lymph nodes, extraprostatic extension of disease and shorter biochemical disease free period.<sup>18,19,21</sup> Conversely, Kiviniemi *et al.*<sup>20</sup> and Contreras *et al.*<sup>16</sup> found an inverse correlation between SDC1 expression and Gleason score in their small study samples of 23 and 45 patients, respectively.

A recent study by Shimada *et al.*<sup>22</sup> showed that silencing of SDC1 in prostate cancer cell caused significant inhibition of vascular endothelial growth factor and tumour angiogenesis. Moreover, SDC1 was also involved in the process of androgen-dependent to androgen-independent conversion in prostate cancer and could be a new target molecule for hormone resistant prostate cancer therapy.<sup>22</sup>

To our knowledge, prognostic utility of SDC2 was only analyzed in oesophageal squamous cell carcinoma, where altered SDC2 expression was associated with lymph node metastasis, TNM stage and patient survival time, and served as an independent prognostic factor for survival.<sup>15</sup>

Our results supported the potential role for SDC2 in prostatic carcinogenesis and cancer progression. Moreover, SDC2 could serve as an additional prognostic marker that might help in further stratifying the risk of progression in patients with clinically localized prostate cancer. Additional studies are necessary to identify SDC2 function in prostatic carcinogenesis and its prognostic role in prostate cancer. Better understanding of the biological effect of this proteoglycan may help develop targeted therapeutics to block its function, thus to ensure normal cellular differentiation and interaction in prostatic tissue.

## CONFLICT OF INTEREST STATEMENT

The authors declare no conflict of interest.

## REFERENCES

1. Rapraeger AC. Syndecan-regulated receptor signaling. *J Cell Biol* 2000; **149**: 995-998.
2. Essner JJ, Chen E, Ekker SC. Syndecan-2. *Int J Biochem Cell Biol* 2006; **38**: 152-156.
3. Simons M, Horovitz A. Syndecan-4-mediated signaling. *Cell Signal* 2001; **13**: 855-866.
4. Woods A, Couchman JR. Syndecan-4 and focal adhesion function. *Curr Opin Cell Biol* 2001; **13**: 578-583.
5. Choi S, Lee E, Kwon S, Park H, Yi JY, Kim S *et al.* Transmembrane domain-induced oligomerization is crucial for the functions of syndecan-2 and syndecan-4. *J Biol Chem* 2005; **280**: 42573-42579.
6. Noguero O, Villena J, Lorita J, Vilaro S, Reina M. Syndecan-2 downregulation impairs angiogenesis in human microvascular endothelial cells. *Exp Cell Res* 2009; **315**: 795-808.
7. Marynen P, Zhang J, Cassiman JJ, Van den Berghe H, David G. Partial primary structure of the 48- and 90-kilodalton core proteins of cell surface-associated heparan sulfate proteoglycans of lung fibroblasts. Prediction of an integral membrane domain and evidence for multiple distinct core proteins at the cell surface of human lung fibroblasts. *J Biol Chem* 1989; **264**: 7017-7024.
8. Tkachenko E, Rhodes JM, Simons M. Syndecans: new kids on the signaling block. *Circ Res* 2005; **96**: 488-500.
9. Han I, Park H, Oh ES. New insights into syndecan-2 expression and tumorigenic activity in colon carcinoma cells. *J Mol Histol* 2004; **35**: 319-326.

10. Huang JW, Chen CL, Chuang NN. P120-GAP associated with syndecan-2 to function as an active switch signal for Src upon transformation with oncogenic ras. *Biochem Biophys Res Commun* 2005; **329**: 855-862.
11. Kim Y, Park H, Lim Y, Han I, Kwon HJ, Woods A *et al.* Decreased syndecan-2 expression correlates with trichostatin-A-induced morphological changes and reduced tumorigenic activity in colon carcinoma cells. *Oncogene* 2003; **22**: 826-830.
12. Choi S, Kim Y, Park H, Han IO, Chung E, Lee SY *et al.* Syndecan-2 overexpression regulates adhesion and migration through cooperation with integrin alpha2. *Biochem Biophys Res Commun* 2009; **384**: 231-235.
13. Gulyas M, Hjerpe A. Proteoglycans and WT1 as markers for distinguishing adenocarcinoma, epithelioid mesothelioma, and benign mesothelium. *J Pathol* 2003; **199**: 479-487.
14. Park H, Kim Y, Lim Y, Han I, Oh ES. Syndecan-2 mediates adhesion and proliferation of colon carcinoma cells. *J Biol Chem* 2002; **277**: 29730-29736.
15. Huang X, Xiao DW, Xu LY, Zhong HJ, Liao LD, Xie ZF *et al.* Prognostic significance of altered expression of SDC2 and CYR61 in esophageal squamous cell carcinoma. *Oncol Rep* 2009; **21**: 1123-1239.
16. Contreras HR, Ledezma RA, Vergara J, Cifuentes F, Barra C, Cabello P *et al.* The expression of syndecan-1 and -2 is associated with Gleason score and epithelial-mesenchymal transition markers, E-cadherin and beta-catenin, in prostate cancer. *Urol Oncol* 2009 May 16. [Epub ahead of print], PMID:19450993, DOI:10.1016/j.urolonc.2009.03.018

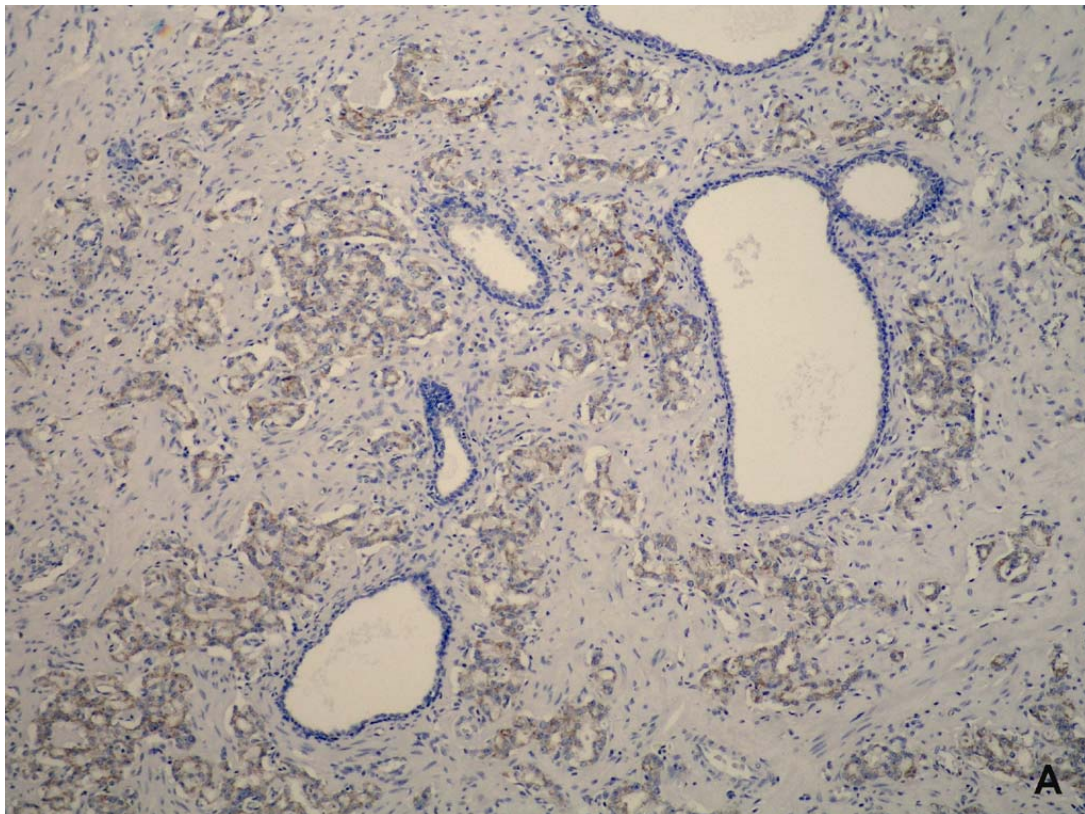


17. Sobin LH, Wittekind C (eds). International Union Against Cancer (UICC): TNM classification of malignant tumours, 5<sup>th</sup> ed. Wiley Liss: New York, USA, 1997.
18. Zellweger T, Ninck C, Mirlacher M, Annefeld M, Glass AG, Gasser TC *et al.* Tissue microarray analysis reveals prognostic significance of syndecan-1 expression in prostate cancer. *Prostate* 2003; **55**: 20-29.
19. Shariat SF, Svatek RS, Kabbani W, Walz J, Lotan Y, Karakiewicz PI *et al.* Prognostic value of syndecan-1 expression in patients treated with radical prostatectomy. *BJU Int* 2008; **101**: 232-237.
20. Kiviniemi J, Kallajoki M, Kujala I, Matikainen MT, Alanen K, Jalkanen M *et al.* Altered expression of syndecan-1 in prostate cancer. *APMIS* 2004; **112**: 89-97.
21. Chen D, Adenekan B, Chen L, Vaughan ED, Gerald W, Feng Z *et al.* Syndecan-1 expression in locally invasive and metastatic prostate cancer. *Urology* 2004; **63**: 402-407.
22. Shimada K, Nakamura M, De Velasco MA, Tanaka M, Ouji Y, Konishi N. Syndecan-1, a new target molecule involved in progression of androgen-independent prostate cancer. *Cancer Sci* 2009 Apr 21. [Epub ahead of print], PMID:19432893, DOI:10.1111/j.1349-7006.2009.01174

Table 1. Gleason distribution with Gleason patterns in 86 patients with prostate cancer

Gleason score	Number of patients
6 (3+3)	28 (32.6%)
7 (3+4)	35 (40.6%)
7 (4+3)	21 (24.4%)
8 (3+5)	1 (1.2%)
8 (5+3)	1 (1.2%)

Figure 1. (A) Syndecan-2 (SDC2) was expressed in prostate cancer while benign glands and prostatic stroma showed negative reaction for SDC2 (X100); (B) immunohistochemical reaction was membranous and granular, intracytoplasmic (X400); (C) in some glands with prostatic intraepithelial neoplasia reaction to SDC2 was also observed (X400).





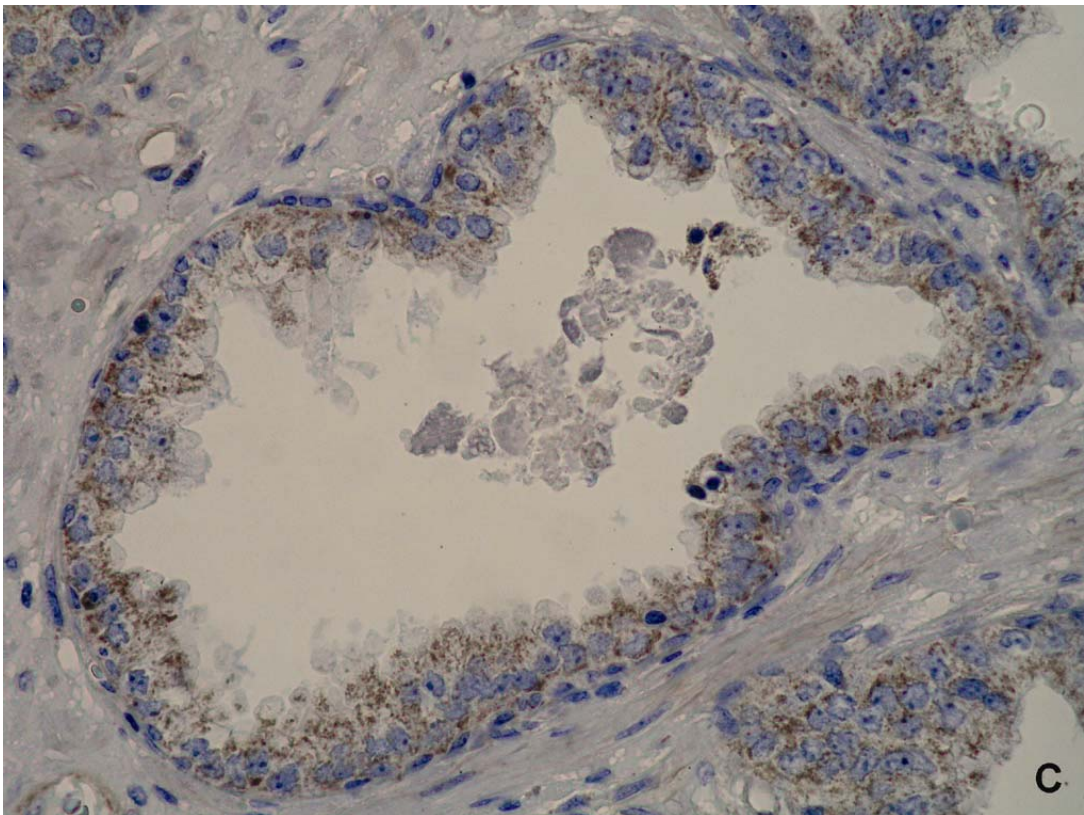
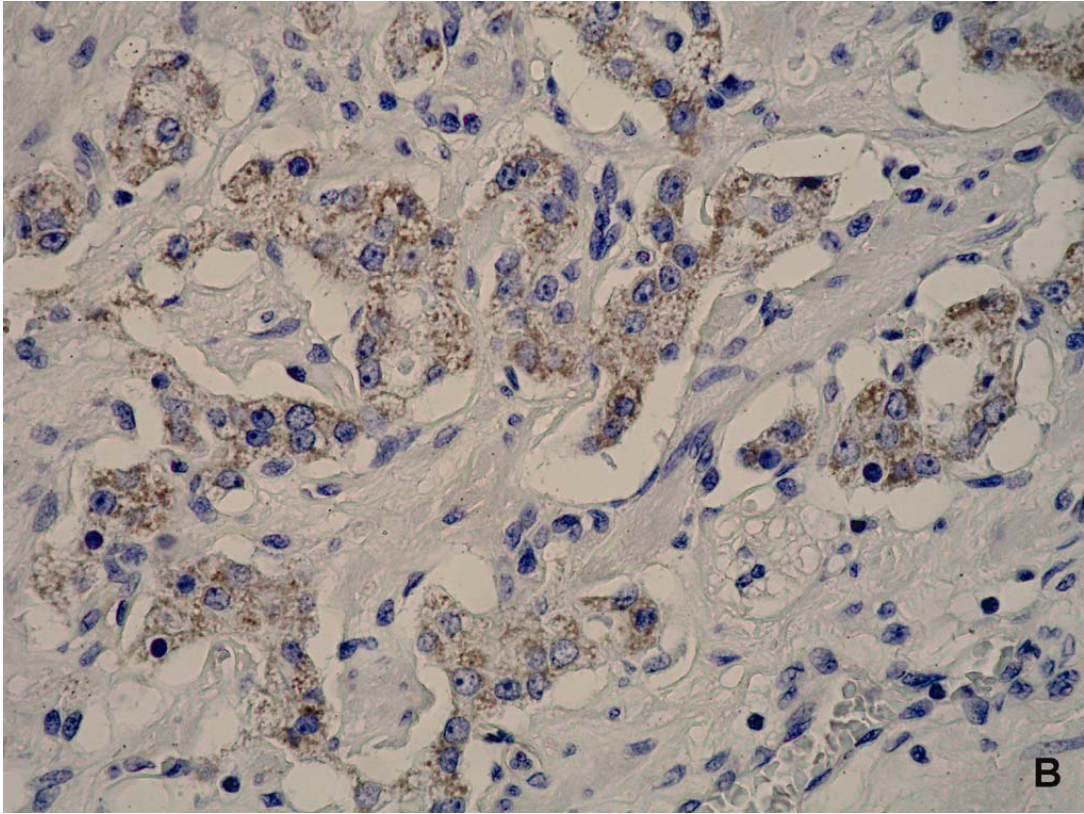


Figure 2. Impact of syndecan-2 overexpression on the disease free period in patients with prostatic carcinoma (Kaplan-Meier survival curve).

