

Cytologic Characteristics of Adenoid Cystic Carcinoma of the Cervix Uteri – Case Report

Ana Barišić¹, Vesna Mahovlić¹, Ana Ovanin-Rakić¹, Lada Škopljanac-Maćina¹, Sanda Rajhvajn¹, Danijela Jurić¹ and Damir Babić^{2,3}

¹ Department of Gynecologic Cytology, Department of Obstetrics and Gynecology, University Hospital Center Zagreb, Zagreb, Croatia

² Department of Clinical Pathology, University Hospital Center Zagreb, Zagreb, Croatia

³ University of Zagreb, School of Medicine, Zagreb, Croatia

ABSTRACT

Adenoid cystic carcinoma is a rare malignancy, usually found in the salivary glands, although this unusual tumor can be found at other sites of the body. In particular, regarding adenoid cystic carcinoma of the cervix (ACCC) most frequently reports are given for postmenopausal women. In this respect, our work is one among very few in the literature that considers a cytologic picture of this uncommon cervix carcinoma. The case of 74 year old patient with postmenopausal bleeding is described. Both Pap smear and air dried smear of the uterine cervix were analyzed. The cytologic findings revealed very few small clusters of abnormal glandular cells, as well as some amorphous eosinophilic globule-like material, with granulomatous and necrotic background. The latter includes a lot of histiocytes, multinucleated giant cells, large aggregates of epitheloid cells and lymphocytes. Histology revealed the diagnosis of ACCC. We emphasize the importance of careful screening of Pap smear that might be crucial in the case of suspicious clinical findings in postmenopausal women, when the possibility of ACCC has to be considered.

Key words: cytology, carcinoma, adenoid cystic, Pap smear

Introduction

Adenoid cystic carcinoma is an uncommon tumor most often found in the salivary glands. Most commonly, it is reported for the minor salivary glands, however it involves the nose, sinuses, upper airways, breast, prostate, vagina and cervix as well. In particular, in the case of the cervix, adenoid cystic carcinoma of the cervix (ACCC) is a rare malignancy, representing 0.4% to 1.7%^{1,2} of all carcinomas of the cervix, and some 3%³ of the primary cervical adenocarcinoma. This type of the carcinoma has been reported to be more common in postmenopausal, high parity, black women⁴, although recent studies find this type of carcinoma in younger patients with less influence of parity and race⁵. The present report is devoted to the cytologic features of this tumor in a 74 year old white woman.

Case Report

A 74 year old woman was hospitalized on October 2, 2006 in the General Hospital »Dr. Josip Benčević«, Slavonski Brod for postmenopausal bleeding. Upon physical examination, the cervix was deemed suspicious and a biopsy was taken on October 3, 2006. A computed tomographic study of the pelvis and abdomen showed the uterus of normal size, while the cervix uteri was enlarged (5.3×3.8 cm). No involvement of the lymph nodes, pelvic wall or adnexa was visible.

The pathologist sent the material (hematoxylin-and-eosin-stained slides and paraffin-embedded tissue) to the Clinical Department of Gynecologic and Perinatal Pathology, University Hospital Center Zagreb for consultation. The tumor tissue was composed of nests of small basaloid cells, with palisading of cells at the periphery of tumor nests. In the center of some nests round to oval

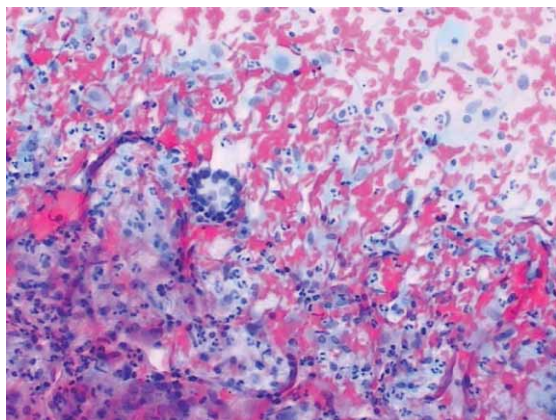


Fig. 1. Small cluster of abnormal glandular cells arranged in the rosette-like group. Inflammation and blood in background. Cervical Pap smear $\times 100$.

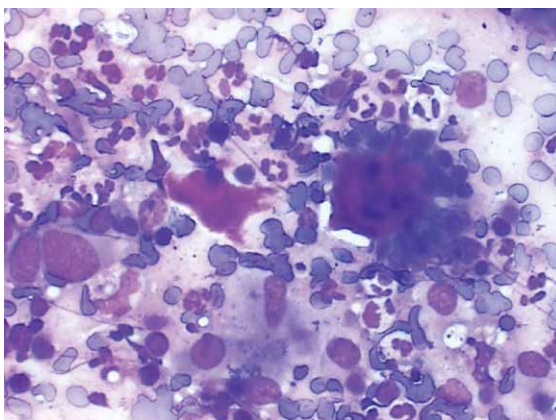


Fig. 2. Amorphous eosinophilic globule-like material surrounded by small, fairly uniform cells. Cervical smear, May-Grünwald-Giemsa (MGG) $\times 200$.

hyaline cylinders were found. According to immunohistochemical studies vimentin, pancytokeratin, S-100 and actine were positive but chromogranine was negative. The adenoid cystic carcinoma of the cervix was revealed by histopathology.

On December 6, 2006, the patient was admitted to the University Department of Gynecology and Obstetrics, University Hospital Center Zagreb. Gynecologic examination at admission revealed neoplastic tissue of 5 cm in diameter and blood in the vagina. Bimanual and rectal examination showed that the uterus and adnexal structures were normal, as was the right parametrium. On the other hand, the left parametrium was shortened. At the same time, a standard Pap smear was taken. Since we found malignant cells in the Pap smear suggestive for ACCC, the air-dried cervical smear was additionally taken for May-Grünwald-Giemsa (MGG) staining.

The slides were difficult to analyze due to the abundant inflammatory and bloody background. The cytologic findings revealed very few small clusters of abnor-

mal glandular cells (Figure 1). Abnormal cells were arranged in the rosette-like groups and spherical aggregates. Furthermore, these cells were uniform, the nuclei were monotonous, small, round and hyperchromatic, and their cytoplasm was scanty. Characteristic amorphous eosinophilic globule-like material was nicely seen in the MGG staining (Figure 2). Inflammatory and atrophic changes were found on epithelial squamous cells in the smear. In the background of the smear, which was granulomatous, necrotic and included a lot of histiocytes, multinucleated giant cells, large aggregates of epithelioid cells and lymphocytes were present. The cytologic pattern suggested a diagnosis of carcinoma, most probably adenoid cystic carcinoma.

The patient is currently being treated by irradiation, and thus far control Pap smears have been negative for epithelial cell abnormalities.

Discussion

Although adenoid cystic carcinoma of cervix (ACCC) was first reported by Paalman and Counseller⁶ in 1949, there are only few detailed and illustrated reports of cytologic findings^{7–11} that we were able to find in the literature: Grafton et al.^{7,8} described two and later three cases, while Pajtler et al.⁹, Dayton et al.¹⁰ and Ravinsky et al.¹¹ each had one case of ACCC. As Dayton et al.¹⁰ explained: »Evidence of adenoid cystic carcinoma in exfoliative cytology specimens is thought to be rare. Factors contributing to this include: (1) the rarity of the tumor itself; (2) the intact overlying mucosa, preventing exfoliation of tumor cells; and (3) the loss of the tubular pattern of the tumor calls, resulting in a deceptively benign appearance on the cytologic smears«.

In our case, we first analyzed a standard Pap smear and since we managed to find malignant cells, we also analyzed an air-dried cervical smear and stained it by MGG to compare cytologic features to the well-known picture of aspiration cytology¹² of the salivary glands. Since the routine procedure with cervical smears is Papanicolaou staining, there is no description of ACCC by MGG staining. Nevertheless, we have obtained very few, but typical spherical globules surrounded by epithelial cells with high nuclear-to-cytoplasmic ratios, meaning round to oval nuclei and scanty cytoplasm, as it is described in fine needle aspiration cytology of the salivary glands¹².

Differential diagnosis of small clusters of cells in cervical smears can be difficult and include benign endometrial stroma, well-differentiated endometrial adenocarcinoma, small cell (neuroendocrine) carcinoma, adenoid cystic carcinoma, small epidermoid carcinoma *in situ*, and intermediate epidermoid carcinoma *in situ*¹⁰.

In the case of a suspicious uterine cervix at the clinical examination, it is important to analyze the Pap smear carefully and, particularly in postmenopausal patients with a heavy, granulomatous and inflammatory background, to consider the possibility of ACCC.

REFERENCES

1. FERENCZY A, KURMAN RJ, WRIGHT TC, Carcinoma and other tumors of the cervix. In: KURMAN RJ (Ed) Blaustein' pathology of the female genital tract, (5th ed, Springer, New York, 2002). — 2. MUSA AG, HUGHES RR, COLEMAN SA, Gynecol Oncol, 22 (1985) 167. — 3. NISHIDA M, NASU K, TAKAI N, MIYAKAWA I, KASHIMA K, Int J Clin Oncol, 10 (2005) 198. — 4. FOWLER WC JR, MILES PA, SURWIT EA, EDELMAN DA, WALTON LA, PHOTOPULOS GJ, Obstet Gynecol, 52 (1978) 337. — 5. DIXIT S, SINGHAL S, VYAS R, MURTHY A, BABOO HA, J Postgrad Med, 39 (1993) 211. — 6. PAALMAN RJ, COUNSELLER VS, Am J Obstet Gynecol, 58 (1949) 184. — 7. GRAFTON WD, WILLIS GW, MARTIN JR, MATHEWS WR, J La State Med Soc, 120 (1968) 276. — 8. GRAFTON WD, KAMM RC, COWLEY LH, Acta Cytol, 20 (1976) 164. — 9. PAJTTLER M, TROŠIĆ A, MAKAROVIĆ Z, MILOJKOVIĆ M, CUGALJ B, Jugosl Ginekolog Perinatol, 28 (1988) 38. — 10. DAYTON V, HENRY M, STANLEY MW, CARSON L, TABER E, Acta Cytol, 34 (1990) 125. — 11. RAVINSKY E, SAFNECK JR, CHANTZIANTONIOU N, Acta Cytol, 40 (1996) 1304. — 12. ENEROTH CM, ZAJICEK J, Acta Cytol, 13 (1969) 59.

A. Barišić

Department of Gynecologic Cytology, Department of Obstetrics and Gynecology, University Hospital Center Zagreb, Petrova 13, 10000 Zagreb, Croatia
e-mail: ana.barac@zg.t-com.hr

CITOLOŠKE KARAKTERISTIKE ADENOID CISTIČNOG KARCINOMA VRATA MATERNICE – PRIKAZ SLUČAJA

SAŽETAK

Adenoid cistični karcinom je rijetka maligna neoplazma koju obično nalazimo u žlijezdama slinovnicama, iako se ovaj tumor pojavljuje i u drugim dijelovima tijela. U slučaju bolesti vrata maternice, adenoid cistični karcinom je izrazito rijedak, obično u postmenopauzi. U literaturi je opisano svega nekoliko slučajeva u citološkim uzorcima vrata maternice. U našem radu prikazan je slučaj 74-godišnje pacijentice s krvarenjem u postmenopauzi. Analizirani su Papa razmaz kao i obrisak vrata maternice osušen na zraku te obojen po Papenheimu. Citološki, nađene su malobrojne nakupine malignih žlijezdanih stanica, kao i nešto amorfnih eozinofilnih globula. Na nekrotičnoj pozadini prevladavala je slika granulomatozne upale s brojnim histiocitima, multinuklearnim orijaškim stanicama, velikim nakupinama epiteloidnih stanica i s dosta limfocita. Histološka dijagnoza je bila adenoid cistični karcinom. U slučajevima sumnjivog kliničkog nalaza na vratu maternice kod žena u postmenopauzi vrlo je važno pažljivo pregledati Papa razmaz te svakako treba misliti i na adenoid cistični karcinom vrata maternice.