



Središnja medicinska knjižnica

Augustin G., Korolija D., Škegro M., Jakić-Razumović J. (2009) *Suture granuloma of the abdominal wall with intra-abdominal extension 12 years after open appendectomy. World journal of gastroenterology, 15 (32). pp. 4083-4086. ISSN 1007-9327*

<http://www.wjgnet.com/1007-9327/index.jsp>

<http://dx.doi.org/10.3748/wjg.15.4083>

<http://medlib.mef.hr/671>

University of Zagreb Medical School Repository

<http://medlib.mef.hr/>

Title page

Title: Suture granuloma of abdominal wall with intra-abdominal extension 12 years after open appendectomy

Short running title: Suture granuloma of abdominal wall after appendectomy

Goran Augustin, Dragan Korolija, Mate Skegro, Jasminka Jakic-Razumovic

Goran Augustin, MD, MSc (corresponding author)
Department of Surgery, Division of Abdominal Surgery
University Hospital Center Zagreb
Kišpatičeva 12
10000 Zagreb
Croatia
E-mail: augustin.goran@gmail.com
Phone: +385915252372

Dragan Korolija, MD, PhD
Department of Surgery, Division of Abdominal Surgery
University Hospital Center Zagreb
Kišpatičeva 12
10000 Zagreb
Croatia

Mate Skegro, MD, PhD, Ass. Prof
Department of Surgery, Division of Abdominal Surgery
University Hospital Center Zagreb
Kišpatičeva 12
10000 Zagreb
Croatia

Jasminka Jakic-Razumovic, MD, PhD, Prof
Department of Pathology,
University Hospital Center Zagreb
Kišpatičeva 12
10000 Zagreb
Croatia

Abstract

Most complications after appendectomy occur within ten days; however, we report the unusual case of a suture granuloma twelve years after open appendectomy. The afebrile 75-year-old woman presented with slightly painful palpable mass in the right lower abdomen. There was no nausea and vomiting and the bowel movements were normal. She lost 10 kg during last three months before presentation. The patient had undergone an appendectomy 12 years previously. Physical examination revealed a tender mass, 10 cm in diameter, under the appendectomy scar. The preoperative laboratory findings, tumor markers and plain abdominal radiographs were normal. Multi-slice CT scan showed inhomogenous abdominal mass with minimal vascularization in the right lower abdomen 8.6 x 8 x 9 cm that communicate with abdominal wall. Abdominal wall was thickened, weak and bulging. Abdominal wall mass did not communicate with cecum and ascending colon. Complete excision of the abdominal wall mass was made via median laparotomy. Histopathological examination revealed granuloma with central abscess. This case report demonstrates that a preoperative diagnosis of abdominal wall mass after open appendectomy warrant the use of wide spectrum of diagnostic modalities and consequently different treatment options.

Key words appendectomy, postoperative complication, suture granuloma, differential diagnosis

INTRODUCTION

Appendicitis became recognized as a surgical disease when Reginald Heber Fitz correctly pointed out that the frequent abscesses in the right iliac fossa were often due to perforation of the vermiform appendix, and he referred to the condition as appendicitis^[1]. Since that discovery and the development of various incisions and appendectomy techniques, many early and late postoperative complications and coincident conditions became evident. One of them is postoperative abdominal wall mass in the region of McBurney's muscle-splitting incision. Diagnosis and management of abdominal wall masses after open appendectomy present challenges because various conditions: appendectomy-related, primary-local (appendectomy-unrelated), primary-systemic could be the causes of abdominal wall masses postoperatively. This case presents the first known case of a suture granuloma with intra-abdominal extension as a cause of abdominal wall mass after open (muscle-splitting) appendectomy.

CASE REPORT

A 75 year-old woman presented with a slightly painful palpable mass in the right lower abdomen lasting for six months. The pain in right lower quadrant was described as continuous, nonradiating, mild and nondisturbing. There was no nausea and vomiting. The body temperature was 36.8°C and bowel movements were normal. She lost 10 kg during last three months before presentation. The patient had undergone the open appendectomy (muscle-splitting incision) 12 years previously. Five years ago she had undergone vaginal hysterectomy with bilateral salphingo-oophorectomy for uterine

leiomyomata. After both operations the patient was in good health and without any symptoms and complaints. She did not take any medications. Physical examination revealed a slightly tender mass, 10 cm in diameter, under the appendectomy scar in the right lower abdomen. The swelling was elastic and poor in mobility. Other resistances could not be found, and all other parts of the physical examination showed no further anomalies.

The preoperative laboratory findings and plain abdominal radiographs were normal. Tumor markers were as follows: CEA=2.42 µg/L; AFP 1.24 µg/L; CA19.9=4.89 kU/L and CA 125=5.80 kU/L. Abdominal ultrasonography demonstrated low-echoic mass lesion 8 x 8 cm just lateral to cecum and in communication with lateral abdominal wall. No peristalsis or communication with the bowel lumen was observed.

Esophagogastroscopy revealed chronic gastritis and colonoscopy revealed sigmoid diverticulosis and normal mucosa in the cecum with normal ileocecal valve. Multi-slice CT scan showed inhomogenous abdominal mass with minimal vascularization in the right lower abdomen 8.6 x 8 x 9 cm that communicate with abdominal wall. Abdominal wall was thickened, weak and bulging (Figure 1). There was no communication between the cecum and abdominal wall also confirmed by previous colonoscopy (Figure 2). From this findings abdominal wall tumor was suspected and elective operation was performed.

After midline laparotomy and adhesiolysis, greater omentum was detached from the mass in the right lower abdomen located intraperitoneally. There was no free intraperitoneal fluid or fibrin deposits. The elastic mass was adherent to abdominal wall and there was no communication with small and large bowel, retroperitoneal or vascular structures. After partial omentectomy the mass was completely extirpated from the abdominal wall (Figure 3). Histopathological examination revealed foreign-body granuloma with central abscess (Figure 4). The patient's early postoperative course was

uneventful and she left the hospital on the 10th postoperative day. On several control examinations during the first 18 months patient was completely symptomless.

DISCUSSION

This case represents an unusual complication of suture granuloma with intra-abdominal extension as a cause of abdominal wall mass 12 years after open appendectomy. To our knowledge (Medline search 1962-2007) this is the third case of such complication after appendectomy. Abdominal wall abscesses after appendectomy was diagnosed by Matsuda *et al.* 11 years postoperatively^[2] and Ichimiya M *et al.* 25 years postoperatively^[3].

Unique feature in our case is intraabdominal extension of abdominal wall suture granuloma with central abscess which complicated definitive diagnosis.

Since the development of various incisions and appendectomy techniques, many early and late postoperative complications and coincident conditions became evident. One of them is postoperative abdominal wall mass in the region of McBurney's muscle-splitting incision. Morbidity associated with appendectomy is could be as high as 25% in complicated cases^[4]. Morbidity could be divided into early and late complications. Early complications are more common and mostly include wound hematoma, seroma, abscess or intra-abdominal abscess due to persistence of cavities between the muscle layers and the subcutaneous tissue which encourages fluid collections^[5]. These complications can turn into cystic formations or masses that can simulate a tumor of the abdominal wall, if they are not readily solved. For this reason, a meticulous surgical technique, careful haemostasis and placement of suction drains in the subcutaneous tissue is recommended, principally in obese patients^[6]. Late complications are rare and some of them include obstruction due to adhesions, postoperative hernia or progression of inflammatory bowel

disease not evident at operation for suspected appendicitis. Most of these complications could present as abdominal mass. Abdominal mass as primary pathology or postoperative finding always makes precise preoperative diagnosis difficult. Complete list of differential diagnosis of late presenting abdominal wall masses after open appendectomy is listed in Table 1.

Several points should be stressed. First, abdominal wall masses could be: 1) appendectomy-related, 2) primary, 3) posttraumatic and 4) related to other interventions in the surrounding area for other pathologic conditions. Thus history taking and physical examination are crucial. Time interval from appendectomy is essential because it determines the difference between early and late complications of appendectomy. Furthermore, symptoms and signs of unrelated diseases (local or systemic) should be confirmed or ruled out (abdominal wall tumors, extension of intra-abdominal malignancy, endometriosis, lymphoproliferative disorders etc.). Confirmation of invasive interventions in the surrounding area is very important. Open/laparoscopic surgery for intraabdominal malignancy/infectious diseases, percutaneous or laparoscopic biopsy or percutaneous fine needle aspiration for malignant hepatobiliary disease could be the cause of abdominal wall port site or incisional metastases or abscesses.

Secondly, by delineating the peritoneal line, the intraperitoneal or extraperitoneal location of the lesion could be determined. This is important for several reasons. First, the entrance into the peritoneal cavity could be avoided during operation if the lesion is located extraperitoneally. Also if abscess is the cause (acute or chronic) then extraperitoneal route avoids spillage of contents into abdominal cavity thus eliminating the possibility of intraabdominal abscess as postoperative complication.

Generally, early postoperative masses are easier to diagnose and treat while late postoperative abdominal wall masses could be of various etiologies that warrant the use

of wide spectrum of diagnostic modalities and consequently different treatment options. All these facts signify the importance of preoperative diagnosis. Thus, abdominal ultrasound, contrast-enhanced multi slice CT and other diagnostic modalities should be used according to clinical findings. Conclusion is that late postoperative abdominal wall masses after open appendectomy could be of various etiologies that warrant the use of wide spectrum of diagnostic modalities and consequently different treatment options.

REFERENCES

- 1 **Fitz RH**. Perforating inflammation of the vermiform appendix; with special reference to its early diagnosis and treatment. *Am J Med Sci* 1886; **92**: 321-346
- 2 **Matsuda K**, Masaki T, Toyoshima O, Ono M, Muto T. The occurrence of an abdominal wall abscess 11 years after appendectomy: report of a case. *Surg Today* 1999; **29**: 931-934 PMID: 10489140, DOI:10.1007/BF02482790
- 3 **Ichimiya M**, Hamamoto Y, Muto M. A case of suture granuloma occurring 25 years after an appendectomy. *J Dermatol* 2003; **30**: 634-636 PMID: 12928536
- 4 **Yagmurlu A**, Vernon A, Barnhart DC, Georgeson KE, Harmon CM. Laparoscopic appendectomy for perforated appendicitis: a comparison with open appendectomy. *Surg Endosc* 2006; **20**: 1051-1054 PMID: 16736313, DOI:10.1007/s00464-005-0342-z
- 5 **Hoehne F**, Ozaeta M, Sherman B, Miani P, Taylor E. Laparoscopic versus open appendectomy: is the postoperative infectious complication rate different? *Am Surg* 2005; **71**: 813-815 PMID: 16468525
- 6 **Haritopoulos KN**, Labruzzo C, Papalois VE, Hakim NS Abdominoplasty in a patient with severe obesity. *Int Surg* 2002; **87**: 15-18 PMID: 12144184

Figures

Figure 1. CT scan of the abdominal wall mass in the right lower abdomen protruding into abdominal cavity displacing small bowel loops.

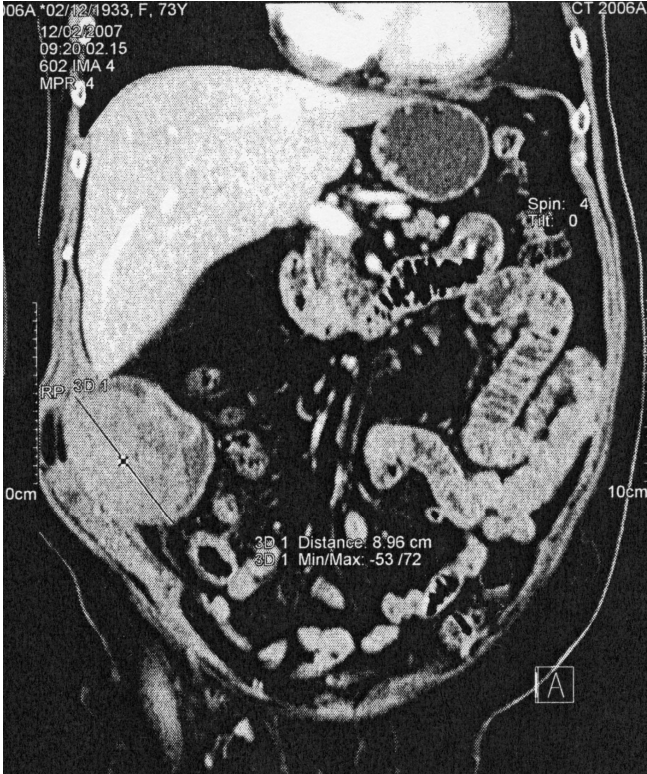


Figure 2. CT scan of the lower abdomen with abdominal wall mass with thickened and bulging abdominal wall and no communication with cecum.

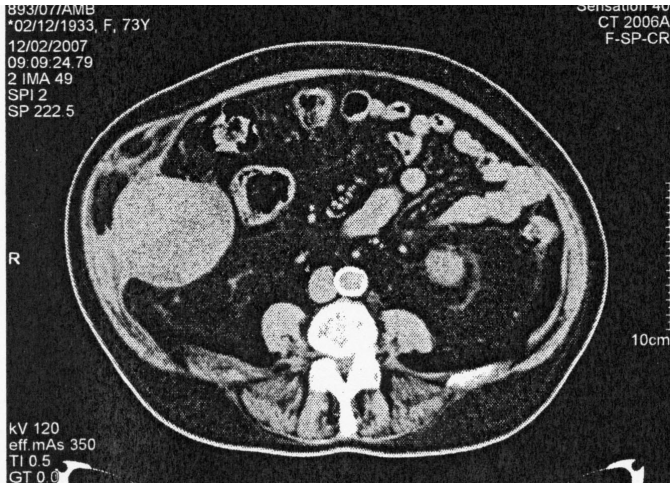


Figure 3. Excised abdominal wall mass.

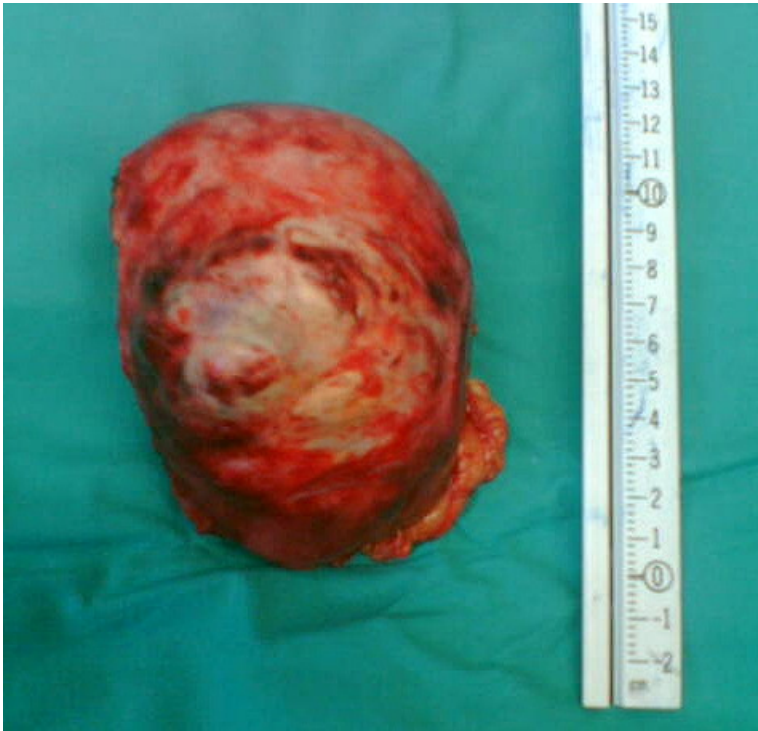

Figure 4. Histological image showing abscess with polymorphonuclear leukocytes, histiocytes and cholesterol crystals (central part of the photograph). Hematoxylin–eosin, ×400.

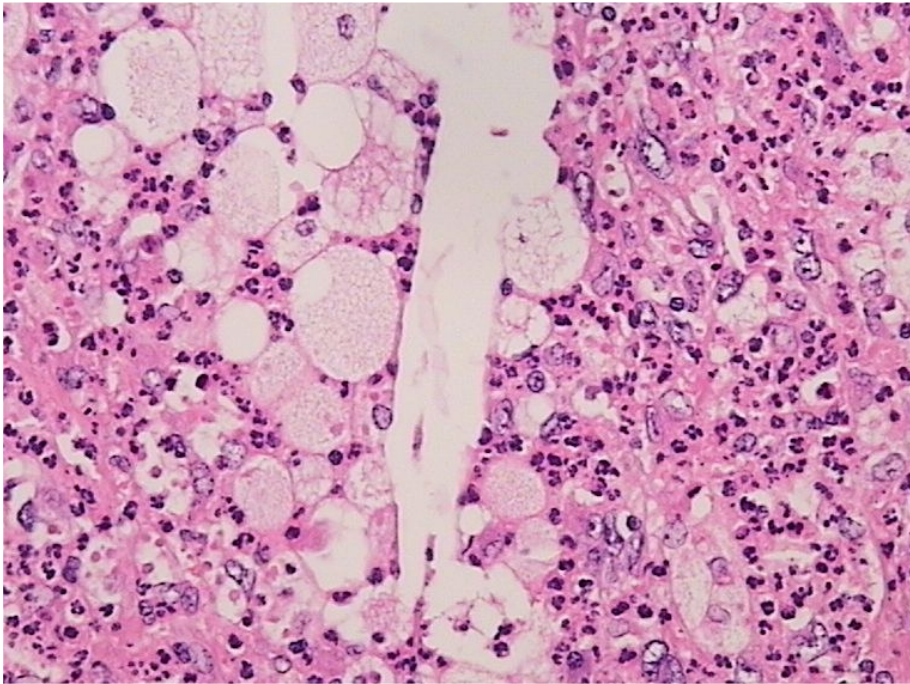


Table 1 Differential diagnosis of *late presentation* abdominal wall masses after open appendectomy

Suture granuloma
Rectus hematoma
Spontaneous
Traumatic
Postoperative
Wound hematoma (organized)
Abscess
Abdominal wall (various etiologies)
Intra-abdominal (extension)
Hernia
Incisional
Spigelian
Groin
Keloid
Traumatic neuroma
Heterotopic bone formation
Incisional
Traumatic
Abdominal wall tumors
Benign (various)
Malignant (various)
Metastatic
Hematogenous
Post-instrumentation
Port site/trocar metastases
Incisional site metastases
Percutaneous
Intra-abdominal malignancy (extension)
Urachal remnant/cyst/inflammatory mass
Uterine/extrauterine (lipo)leiomyomas
Primary
Incisional
Endometriosis
Cutaneous (primary)
Surgical scar endometriosis
Mastocytosis
Systemic juvenile xanthogranulomatosis
Lymphoproliferative disorders (congenital/acquired)
Parasitic (abscess or granuloma)
Enterobius vermicularis
Hydatid cyst
Mycetoma (endemic)
Actinomycosis
Extension from intestinal actinomycosis
Abdominal wall (hematogenous)