



Središnja medicinska knjižnica

Pećina-Šlaus, N., Nikuševa Martić, T., Tomas, D., Beroš, V., Zeljko, M., Čupić, H.
(2008) *Meningiomas exhibit loss of heterozygosity of the APC gene*. *Journal of Neuro-Oncology*, 87 (1). pp. 63-70.

The original publication is available at www.springerlink.com

<http://www.springerlink.com/content/k4g77625052h5684/>

<http://dx.doi.org/10.1007/s11060-007-9500-6>

<http://medlib.mef.hr/341>

University of Zagreb Medical School Repository

<http://medlib.mef.hr/>

Running head: APC gene in meningiomas

Meningiomas exhibit loss of heterozygosity of the APC gene

Nives Pećina-Šlaus^{1,2}, Tamara Nikuševa Martić^{1,2}, Davor Tomas³, Vili Beroš⁴, Martina Zeljko¹, Hrvoje Čupić³

¹ Laboratory of Neurooncology, Croatian Institute for Brain Research, School of Medicine University of Zagreb, Šalata 12, HR-10000 Zagreb, Croatia.

² Department of Biology, School of Medicine, University of Zagreb, Šalata 3, HR-10000 Zagreb, Croatia.

³ Ljudevit Jurak Department of Pathology, University Hospital "Sisters of Charity", Vinogradska 29, 10000 Zagreb, Croatia.

⁴ Department of Neurosurgery, University Hospital "Sisters of Charity", Vinogradska 29, 10000 Zagreb, Croatia.

.

Corresponding author: Nives Pećina-Šlaus

¹Laboratory of Neurooncology, Croatian Institute for Brain Research, School of Medicine University of Zagreb, Salata 3, HR-10000 Zagreb, Croatia, e-mail: nina@mef.hr

e-mail: nina@mef.hr, tel. +385 1 46 21 140, fax:+385 1 45 90199; +385 1 49 20 050; +385 1 45 96 942

Abstract

The molecular mechanisms and candidate genes involved in development of meningiomas still need investigation and elucidation.

In the present study thirty-three meningiomas were analyzed regarding genetic changes of tumor suppressor gene Adenomatous polyposis coli (APC), a component of the wnt signaling. Gene instability was tested by polymerase chain reaction/loss of heterozygosity (LOH) using Restriction Fragment Length Polymorphism (RFLP) method. RFLP was performed by two genetic markers, Rsa I in APC's exon 11 and Msp I in its exon 15. The results of our analysis showed altogether 15 samples with LOH of the APC gene out of 32 heterozygous patients (47%). Seven patients had LOHs at both exons, while 4 LOHs were exclusive for exon 11 and 4 for exon 15. The changes were distributed according to pathohistological grade as follows: 46% of meningothelial meningioma showed LOH; 33% of fibrous; 75% of mixed (transitional); 75% of angiomatous, and one LOH was found in a single case of psammomatous meningioma. None of the LOHs were found in atypical and anaplastic cases. Immunostaining showed that samples with LOHs were accompanied with the absence of APC protein expression or presence of mutant APC proteins ($\chi^2 = 13.81$, $df = 2$, $P < 0.001$). We also showed that nuclear localization of beta-catenin correlates to APC genetic changes ($\chi^2 = 21.96$, $df = 2$, $P < 0.0001$).

The results of this investigation suggest that genetic changes of APC gene play a role in meningioma formation.

Key words: adenomatous polyposis coli gene (APC), loss of heterozygosity, meningiomas, tumors of the CNS, wnt signaling pathway

Introduction

We investigated loss of heterozygosity of the adenomatous polyposis coli (APC) gene in human central nervous system (CNS) tumors - meningiomas. The gene (chromosome 5q21) is organized in 16 translated exons and encodes a 2843 amino acid protein that is expressed in specific (frequently post-replicative) epithelial and mesenchymal cells of a number of fetal and adult human tissues [1]. The protein product of this tumor suppressor gene plays a role as a component of the wnt signal transduction pathway [2]. It has been well documented that wnt genes and other components of wnt signaling, are implicated in tumorigenesis [3, 4] and lately also in brain tumorigenesis [5-7]. APC acts as a negative regulator of the wnt signaling, being a critical component of the beta-catenin destruction machinery heading to the proteasome. In response to wnt signaling, or under the circumstances of mutated APC, beta-catenin is stabilized, accumulates in the cytoplasm and enters the nucleus, where it finds a partner, a member of the DNA binding protein family LEF/TCF. Together they activate new gene expression programs, among others, c-myc and cyclin D1 [8].

Meningiomas account for approximately 20% of primary intracranial and intraspinal neoplasms originating from the meningeal coverings of the brain and the spinal cord. The majority of meningiomas corresponds to grade I of WHO classification of CNS tumors and thus are benign, slowly growing tumors [9, 10]. Nevertheless, there are also those who will exhibit features of malignant behavior. The majority of meningiomas suffer losses on 22q including loss of heterozygosity of the neurofibromatosis type 2 gene (NF2). Up to 60% of meningiomas carry inactivating mutations in the remaining NF2 allele. Loss of expression of NF2 protein product merlin is consistent finding in all NF2 associated meningiomas and in about half of sporadic benign cases [11]. Relevant genetic alterations of atypical and anaplastic meningiomas are still unknown. Although several molecular studies have examined alterations of other tumor suppressor genes and oncogenes in meningiomas [12], the etiology and pathogenesis of this neoplasm still need to be elucidated.

There are several reasons why we propose studying APC in meningiomas. New knowledge on wnt signaling shows that wnt proteins and other components of the wnt signaling cascade, like beta-catenin and axin regulate critical developmental processes of normal CNS development [13-16]. Although APC has been thought of primarily as a colon-specific tumor suppressor gene, its high expression in the CNS [17] and its critical involvement in particular syndromes, like the Turcot syndrome [18], which includes the

development of primary brain tumors such as medulloblastomas and gliomas [19], suggests that it performs important functions in these tissues also.

Materials and methods

Tumor specimen

Samples of 33 meningiomas together with 33 autologous blood tissues were collected from the Department of Neurosurgery, University Hospital “Sisters of Charity”, Zagreb, Croatia. Using the magnetic resonance imaging (MRI) tumor lesions were found in different cerebral regions, with the surrounding zone of perifocal oedema. During the operative procedure the tumor was maximally reduced using a microneurosurgical technique. The patients had no family history of brain tumors and did not undergo chemotherapy or radiotherapy prior to surgery. Collected tumor tissues were frozen in liquid nitrogen and transported to the laboratory, where they were immediately transferred at -75°C . The peripheral blood samples were collected in EDTA and processed immediately. All tumors were studied by pathologists and classified according to the WHO criteria [9]. There were 14 meningothelial meningiomas, 6 fibrous (fibroblastic), 4 transitional (mixed), 1 psammomatous, 4 angiomatous, 2 atypical and 2 anaplastic.

Seventeen patients were female, and sixteen male. The age of patients varied from 35 to 76 (mean age=60.4 years). The mean age at diagnosis for females was 63, and for males 58 years.

The local Ethical Committee approved our study and patients gave their informed consent.

DNA extraction.

Approximately 0.5 g of tumor tissue was homogenized with 1 ml extraction buffer (10 mM Tris HCl, pH 8.0; 0.1 M EDTA, pH 8.0; 0.5% sodium dodecyl sulfate) and incubated with proteinase K (100 $\mu\text{g}/\text{ml}$; Sigma, USA; overnight at 37°C). Phenol chloroform extraction and ethanol precipitation followed.

Blood was used to extract leucocyte DNA. Five ml of blood was lysed with 7 ml distilled water and centrifuged (15 min/5000 g). The pellet was then processed as for DNA extraction from the tissue samples.

Polymerase chain reaction

The optimal reaction mixture (25 μl) for APC's exon 11 amplification was: 10 pmol of each primer (5'-GGACTACAGGCCATTGCAGAA-3' and 5'-GGCTACATCTCCAAAAGTCAA-3'), 200-400 ng template DNA, 2.5 μl 10 X reaction

buffer II (500 mM KCl, 100 mM Tris-HCl, pH 8.3), 1 mM MgCl₂, 2.5 mM of each dNTP, 1 µl (0.5 U) of Taq polymerase. Polymerase chain reaction (PCR) conditions were: initial denaturation, 4 min/95°C; denaturation, 1 min/94°C; annealing, 2 min/58°C; extension, 1.5 min/72°C; 35 cycles. To amplify fragment of the exon 15 of the *APC* gene we used in a volume of 25 µl: 5 pmol of each primer (5-ATGATGTTGACCTTTCCAGGG-3 and 5-CTTTTTTGGCATTGCGGAGCT-3), 200 ng template DNA, 2.5 µl 10X buffer II, 1.5 mM MgCl₂, 2.5 mM of each dNTP, 1 µl (5 U) of Taq polymerase. PCR conditions were: initial denaturation, 5 min/95°C; denaturation, 30 s/95°C; annealing, 30 s/57°C; extension, 45 s/72°C; final extension, 72°C/7 min; 30 cycles. The PCR products for both markers were analyzed on 2% agarose gels.

Loss of heterozygosity

Loss of heterozygosity of the *APC* gene was detected on the basis of restriction fragment length polymorphism (RFLP) of the PCR products. Two different polymorphisms were investigated. One is an *Rsa* I polymorphic site in exon 11, and the other is an *Msp* I polymorphic site in exon 15. PCR amplification of exon 11 generated a 133- bp fragment that is cleaved to 85- and 48- bp fragments by *Rsa* I restriction if the polymorphic site is present, and remains uncut if the site is absent. The amplified fragment of exon 15 is 550 bp long and is cleaved with the *Msp* I restriction endonuclease to two 250 bp fragments if the restriction site is present. LOH/*Rsa* I was demonstrated only in informative (heterozygous) persons when the tumor DNA showed loss of either the single uncut band (133 bp) or of the two cut bands (85+48 bp) compared to autologous blood tissue. For *Msp* I polymorphism heterozygous patients demonstrated two bands (550+250 bp), while LOH was shown when either band was missing in comparison to the autologous blood tissue. PCR aliquots (10-15 µl) were digested with 6 U *Rsa* I (Gibco, USA; 12 h at 37°C) and with 6 U *Msp* I (Gibco, USA, overnight at 37°C) and were electrophoresed on Spreadex gels EL 300 in the SEA 2000 submarine electrophoresis apparatus (Elchrom scientific, Switzerland) at 120V. Temperature of the running buffer was kept constant at 55°C. The samples with LOHs were additionally electrophoresed on 15% polyacrylamide gels stained with silver.

Immunohistochemistry

Immunohistochemistry was performed in order to establish the levels of expression and cellular localization of *APC* and beta-catenin proteins. The samples were formalin-fixed, paraffin embedded, and 4-mm thick sections were placed on Capillary gap microscope slides (DakoCytomation, Denmark). The sections were immunostained using the biotin-avidin-

horseradish peroxidase method. Deparaffinized and rehydrated sections were microwaved in Dako Target Retrieval Solution (Dako Corporation, USA) three times for 5 min at 800 W to unmask epitopes. To block endogenous peroxidase activity, we fixed the cells in methanol containing 3% H₂O₂. Non-specific binding was blocked by the application of normal mouse serum for 30 min in a humid chamber. Slides were blotted and primary antibodies at optimized dilutions were applied for 30 min at room temperature. The antibodies used for APC protein detection were: APC-1 monoclonal mouse anti-human antibody that recognizes amino terminal epitope (diluted 1:50) (Calbiochem, USA) and APC-2 monoclonal rabbit anti-human antibody (ready-to-use) that recognizes carboxy terminal epitope (Spring Bioscience, USA). Monoclonals used for β -catenin detection were: monoclonal mouse anti-human antibody (diluted 1:200) from Dako Corporation, USA.

After incubation, the slides were washed three times in phosphate-buffered saline/goat serum. Secondary LINK antibody was applied for 25 min. The washing was repeated, and the slides were incubated with streptavidin horseradish peroxidase for another 25 min. All chemicals were from DakoCytomation. Negative controls were samples that underwent same staining procedure with the exclusion of the primary antibodies. Normal skin served as positive internal control. The analysis of the labeling was performed by two independent observers, i.e. blinded pathologists, experts in the field on an Olympus BH-2 microscope.

Statistical methods

All individuals were analyzed for the following features: PHD status, sex, age, APC LOH, APC and beta-catenin protein expression. Differences in the frequencies of the analyzed features were tested with the χ^2 test employing Yates correction when appropriate.

Results

The pathohistological grading of the meningioma sample analyzed is shown in Table 1.

From 33 meningioma samples 32 were informative when analyzed with both APC gene markers (97%). The results of our analysis regarding APC gene, demonstrated 15 samples with allelic losses of the APC gene out of 32 heterozygous patients (47%). This is the total number of changes analyzed by both polymorphic markers, RsaI/exon 11 and MspI/exon 15. When specifying changes to distinct gene regions, there were 11 alterations in exon 11 (39%) and 11 in exon 15 (39%). Seven meningioma samples showed both LOHs at exon 11 and 15, while 4 LOHs were exclusive for exon 11 and 4 for exon 15. LOHs of the APC gene that both markers revealed are shown in Figure 1 A (exon 11) and B (exon 15).

When distributing APC's changes to specific tumor types, we observed 6 allelic changes in 13 informative meningothelial meningiomas (46%); 2 in 6 informative fibrous (33%); 3 in 4 informative transitional (mixed) (75%); 3 in 4 informative angiomatous (75%); and 1 LOH in a single case of psammomatous meningioma.

Two atypical and two anaplastic meningiomas that we examined did not demonstrate allelic changes of APC gene tested with both markers.

In order to determine whether APC changes at the genetic level have consequences in meningiomas at the protein level, the expression of APC protein was investigated. We employed the combination of two different monoclonal APC antibodies, not only to analyze the levels of expression, but to detect truncated mutant proteins as well. Since Ab-1 recognizes the amino terminus of the protein and hence reacts with both the wild-type and mutant proteins, we were able to demonstrate lack of protein expression in 39% of our total sample. Lack of staining was confirmed with Ab-2 antibody that recognizes the carboxy terminus and reacts only with the nontruncated wild-type proteins. Only those samples positive for APC's expression with Ab-1, but negative when tested with Ab-2, revealed mutant proteins, lacking carboxy terminus. Mutant proteins were detected in 27% of our total sample. Ten out of 15 meningioma samples with APC LOH, did not express wild type APC protein (66.7%), while in the remaining 5 samples with LOH, mutant APC protein was detected. The findings on the protein levels and types are shown in Table 1.

The association between APC genetic changes and lack of protein expression or presence of mutant proteins was significant ($\chi^2=13.81$, $df = 2$, $P<0.001$) as shown in Table 2.

Our next step was to detect whether the expression and cellular localization of the main downstream signaling effector molecule, beta-catenin, correlated with LOH of APC gene. Our findings demonstrated that there is significant association ($\chi^2 =21.96$, $df = 2$, $P<0.0001$) between the LOHs of APC and the localization of beta-catenin protein (Table 3). In all cases where LOH was noted beta-catenin protein was located in cytoplasm and nucleus. At the same time in cases where APC's LOH was not detected the location of the beta-catenin protein was primarily in the membrane or was not detectable (Table 3). Immunostaining of APC and beta-catenin proteins is demonstrated in Figure 2.

When we correlated our molecular findings with the demographic variables we were unable to demonstrate that LOH was significantly associated with the analyzed age categories, although at the descriptive level, 11/15 LOHs were noted in patients over 56 years of age. The

correlation of observed LOHs to invasion was as follows: two meningiomas with LOHs infiltrated dura, one had bone invasion and another one was a case of recurring meningioma.

Due to a small number of cases in certain meningioma subtypes, the correlation of APC genetic changes to specific PHD status was not significant. Nevertheless, at the descriptive level LOH frequencies are higher in mixed and angiomatous histology (7/9, 77.8%) than in meningothelial and fibrous (8/19, 42%). Aggressive forms did not show changes. Genomic changes, the polymorphic status for both markers used, and protein expression are summarized in Table 1.

We also tested our meningioma sample to NF-2 genetic changes. We observed two LOHs by microsatellite marker D22S929 (in sample no. 4 and sample no. 14, Table 1), but those findings could not be correlated to the results with APC.

Discussion

Identification of new genes that will improve the understanding of meningioma development and eventual progression is very important.

The majority of meningiomas we analyzed were slow-growing, benign sporadic lesions with seemingly low metastatic potential. However, biologic spectrum of meningiomas is wide, heterogenic and difficult to predict [20]. Some of the histologically benign meningiomas recur unexpectedly even after complete resection and invade surrounding tissues [20]. Novel revisions of meningioma classification [9] recommend caution on benign meningioma prognosis, proposing their proliferative activity and brain invasion as important characteristics that could indicate recurrence and should be considered in diagnostics and prognosis.

The result of this study demonstrates that changes of APC gene are frequent among benign meningioma types (47%). The considerable number of allelic losses of the APC gene in our meningioma sample may be attributed to random variation in tumors, but the observed frequency led us to conclude that gross deletion of the APC gene are an important event in the mechanisms of meningioma formation. Moreover, the functional consequences of the changes were confirmed at the protein level. Our results on the significant association between APC genetic changes and lack of wild type protein expression or presence of mutant proteins ($\chi^2 = 13.81$, $df = 2$, $P < 0.001$) indicate that gross deletions are consistent to the protein findings.

Association between LOHs of APC and nuclear location of beta-catenin protein ($\chi^2 = 21,96$, $df = 2$, $P < 0.0001$) show that APC changes influence beta-catenin expression and localization, and are important in the biology of meningioma.

At the descriptive level we observed the distinction of the frequencies of LOH occurrences between meningothelial and fibrous on one side and mixed and angiomatous on the other. Mixed and angiomatous histology showed somewhat higher frequency of LOH of this gene. Changes of APC gene observed in specific meningiomas were also partially associated with their invasion into the surrounding tissues and recurrence.

No LOHs were found in atypical and anaplastic cases, but since the numbers of cases investigated was rather small it was difficult to interpret this finding.

The survey by Wrobel and co-workers [21] who observed that anaplastic meningiomas could be distinguished from benign by differential expression of a distinct set of genes, suggests that benign forms and those with greater likelihood of recurrence and aggressive behavior could be governed by different genetic profiles.

Our observations are in accordance with the findings of other authors investigating different components (direct and indirect) of wnt signaling in meningiomas. For example E-cadherin's allelic losses were observed in fibrous and angiomatous meningiomas. Since the loss of E-cadherin is a well known prerequisite for tumor cell invasion [22], the finding suggests that those meningioma types may hide future invasive behavior. Schwechheimer and coworkers [23] found that E-cadherin's expression was absent from the majority of morphologically malignant meningiomas and that the loss of its expression was correlated with tumor dedifferentiation. Utsuki et al. [24] also reported on negative E-cadherin immunostaining in all of the fibrous meningiomas they examined. Brunner et al. [25] found lack of E-cadherin's expression in 34% of meningiomas independent of their WHO grade as well as loss of membranous and positive nuclear immunoreactivity of beta-catenin. Wrobel and coworkers [21] reported on increased expression of beta-catenin and cyclin D1 in meningiomas they examined by microarray. Unfortunately they did not study APC expression profile.

The discrepancies between our results and those obtained by Lee et al. [26] who failed to detect an enhanced occurrence of LOH of the APC gene in meningiomas they examined, may be explained by several factors. Firstly, Lee and co-workers used 2 microsatellite markers that map to cytogenetic band 5q23.3 which is in proximity to APC/MCC region, while we used intragenetic markers (exon 15 and 11 of the APC gene). Genetic regions investigated in the two studies are not the same and therefore the ratios of LOHs may also

differ. Secondly, both studies analyzed relatively low number of cases for statistical interpretation. Nevertheless, Lee et al. found 1 LOH in 25 benign; and 3 LOHs in 9 atypical and malignant meningiomas, indicating that this genetic change is present in this disease.

The observed genetic changes of the APC gene were dispersed among different types of meningioma, indicating once again that APC is not likely to be the first event in the raise of this specific tumor. Mutation and or loss of NF2 gene were found in meningiomas of all malignancy grades which make NF2 gene a candidate gatekeeper gene of meningioma initiation, i.e. first genetic change in its pathogenesis [10]. Although we were unable to establish correlation of NF-2 genetic changes to the results with APC, it seems that changes of APC gene are introduced later on in genetic profile of meningioma.

We are aware that due to a small number of tumors in some of our grade subsets, conclusions should be made with caution. Nevertheless, our findings contribute to better understanding of meningioma genetic profile elucidating pathophysiological mechanisms of tumor formation, and could offer new prognostic markers for meningioma.

Acknowledgements

This work was supported by grant 108-1081870-1905 from Ministry of Science Sports and Education, Republic of Croatia.

References:

1. Groden J, Thliveris A, Samowitz W, Carlson M, Gelbert L, Albertsen H, Joslyn G, Stevens J, Spirio L, Robertson M (1991) Identification and characterization of the familial adenomatous polyposis coli gene. *Cell* 66: 589-600
2. Gordon MD, Nusse R (2006) Wnt Signalling: Multiple Pathways, Multiple Receptors, and Multiple Transcription Factors. *J Biol Chem* 281: 22429-22433
3. Peifer M, Polakis P (2000) Wnt signaling in oncogenesis and embriogenesis - a look outside the nucleus. *Science* 287: 1606-1609
4. Pecina-Slaus N, Gall-Troselj K, Slaus M, Radic K, Nikuseva-Martic T, Pavelic K (2004) Genetic changes of the E-cadherin and APC tumour suppressor genes in clear cell renal cell carcinoma. *Pathology* 36: 145-151
5. Koch A, Waha A, Tonn JC, Sorensen N, Berthold F, Wolter M, Reifenberger J, Hartmann W, Friedl W, Reifenberger G, Wiestler OD, Pietsch T (2001) Somatic mutations of WNT/wingless signaling pathway components in primitive neuroectodermal tumors. *Int J Cancer* 93: 445-449

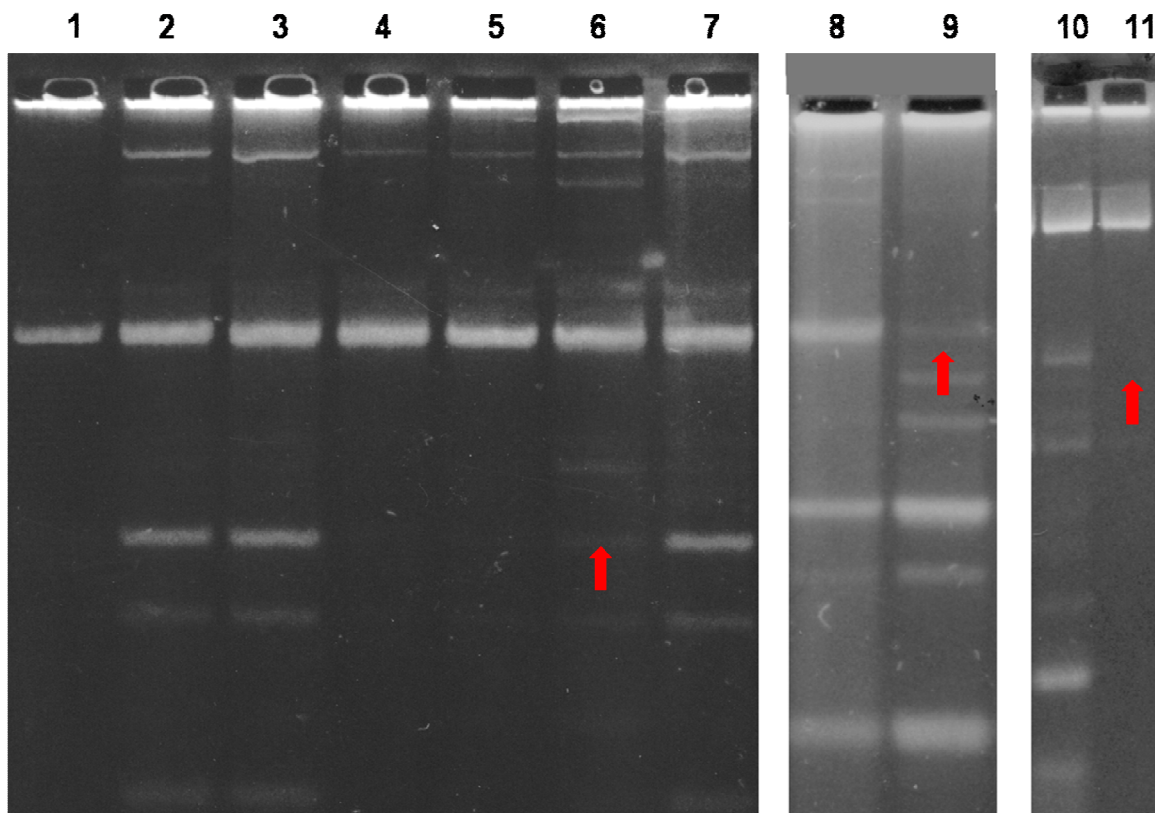
6. Howng SL, Wu CH, Cheng TS, Sy WD, Lin PC, Wang C, Hong YR (2002) Differential expression of Wnt genes, beta-catenin and E-cadherin in human brain tumors. *Cancer Lett* 183: 95-101
7. Fogarty MP, Kessler, JD, Wechsler-Reya, RJ (2005) Morphing into Cancer: The Role of Developmental Signaling Pathways in Brain Tumor Formation. *J Neurobiol* 64: 458-475
8. He TC, Sparks AB, Rago C, Hermeking H, Zawel L, da Costa LT, Morin PJ, Vogelstein B, Kinzler KW (1998) Identification of c-MYC as a target of the APC pathway. *Science* 281 1509-1512
9. Kleihues P, Louis DN, Scheithauer BW, Rorke LB, Reifenberger G, Burger PC, Cavenee WK (2002) The WHO classification of tumors of the nervous system. *J Neuropathol Exp Neurol* 61: 215-225
10. Riemenschneider MJ, Perry A, Reifenberger G (2006) Histological classification and molecular genetics of meningiomas. *Lancet Neurol* 5:1045-54
11. Fuller CE, Perry A (2005) Molecular Diagnostics in Central Nervous System Tumors. *Adv Anat Pathol* 12:180-194
12. Weber RG, Bostrom J, Wolter M, Baudis M, Collins VP, Reifenberger G, Lichter P (1997) Analysis of genomic alterations in benign, atypical, and anaplastic meningiomas: toward a genetic model of meningioma progression. *Proc Natl Acad Sci USA* 94:14719-14724
13. Hall AC, Lucas FR, Salinas PC (2000) Axonal remodeling and synaptic differentiation in the cerebellum is regulated by WNT-7a signaling. *Cell* 100: 525-535
14. Patapoutian A, Reichardt LF (2000) Roles of wnt proteins in neural development maintenance. *Curr Opin Neurobiol* 10: 392-399
15. Yu X, Malenka RC (2003) Beta-catenin is critical for dendritic morphogenesis. *Nature Neurosci* 6: 1169-1177
16. Lie DC, Colamarino SA, Song HJ, Desire L, Mira H, Consiglio A, Lein ES, Jessberger S, Lansford H, Dearie AR, Gage FH (2005) Wnt signalling regulates adult hippocampal neurogenesis. *Nature* 437: 1370-1375
17. Brakeman JS, Gu SH, Wang XB, Dolin G, Baraban JM (1999) Neuronal localization of the Adenomatous polyposis coli tumor suppressor protein. *Neuroscience* 91: 661-672
18. Mori T, Nagase H, Horii A, Miyoshi Y, Shimano T, Nakatsuru S, Nakatsuru S, Aoki T, Arakawa H, Yanagisawa A, Ushio Y (1994) Germ-line and somatic mutations of

- the APC gene in patients with Turcot syndrome and analysis of APC mutations in brain tumors. *Genes Chromosomes Cancer* 9: 168-172
19. Hamilton SR, Liu B, Parsons RE, Papadopoulos N, Jen J, Powell SM, Krush AJ, Berk T, Cohen Z, Tetu B (1995) The molecular basis of Turcot's syndrome. *N Engl J Med* 332: 839-840
 20. Perry A, Gutmann DH, Reifenberger G (2004) Molecular pathogenesis of meningiomas. *J Neurooncol* 170 :183-202
 21. Wrobel G, Roerig P, Kokocinski F, Neben K, Hahn M, Reifenberger G, Lichter P (2005) Microarray-based gene expression profiling of benign, atypical and anaplastic meningiomas identified novel genes associated with meningioma progression. *Int J Cancer* 114: 249-256
 22. Pecina-Slaus N (2003) Tumor suppressor gene E-cadherin and its role in normal and malignant cells. *Cancer Cell Int* E3: 17 (<http://www.cancerci.com/content/3/1/17>)
 23. Schwechheimer K, Zhou L, Birchmeier W (1998) E-Cadherin in human brain tumours: loss of immunoreactivity in malignant meningiomas. *Virchows Arch* 432: 163-167
 24. Utsuki S, Oka H, Sato Y, Kawano N, Tsuchiya B, Kobayashi I, Fujii K (2005) Invasive meningioma is associated with a low expression of E-cadherin and beta-catenin. *Clin Neuropathol* 24: 8-12
 25. Brunner EC, Romeike BF, Jung M, Comtesse N, Meese E (2006) Altered expression of beta-catenin/E-cadherin in meningiomas. *Histopathology* 49: 178-187
 26. Lee JY, Finkelstein S, Hamilton RL, Rekha R, King JT Jr, Omalu B (2004) Loss of heterozygosity analysis of benign, atypical, and anaplastic meningiomas. *Neurosurgery*. 55: 1163-1173

Figure legends

Figure 1. A. Loss of heterozygosity of APC gene in 3 patients with meningioma. Exon 11/RsaI/RFLP is demonstrated. Lane 1- standard DNA; lanes 2, 3- heterozygous sample (tumor and blood); lane 4, 5- uninformative homozygous sample showing uncut allele (tumor and blood); lane 6 - LOH in a meningioma patient (the digested/cut allele is missing); lane 7- informative blood sample of the same patient showing undigested/uncut allele 133 bp and cut allele (85+48 bp); lanes 8, 10 - informative blood samples; lanes 9, 11 - LOHs in the corresponding meningioma samples.

B. Loss of heterozygosity of APC gene in meningioma patients. Exon 15/MspI/RFLP is demonstrated. Lanes 1, 6, 7, 10 - heterozygous samples, both alleles, cut and uncut, are visible; lanes 2, 4, 8, 12, 14, 15 – informative blood samples; lanes 3, 5, 9, 11, 13, 16 - LOHs in the corresponding meningiomas.



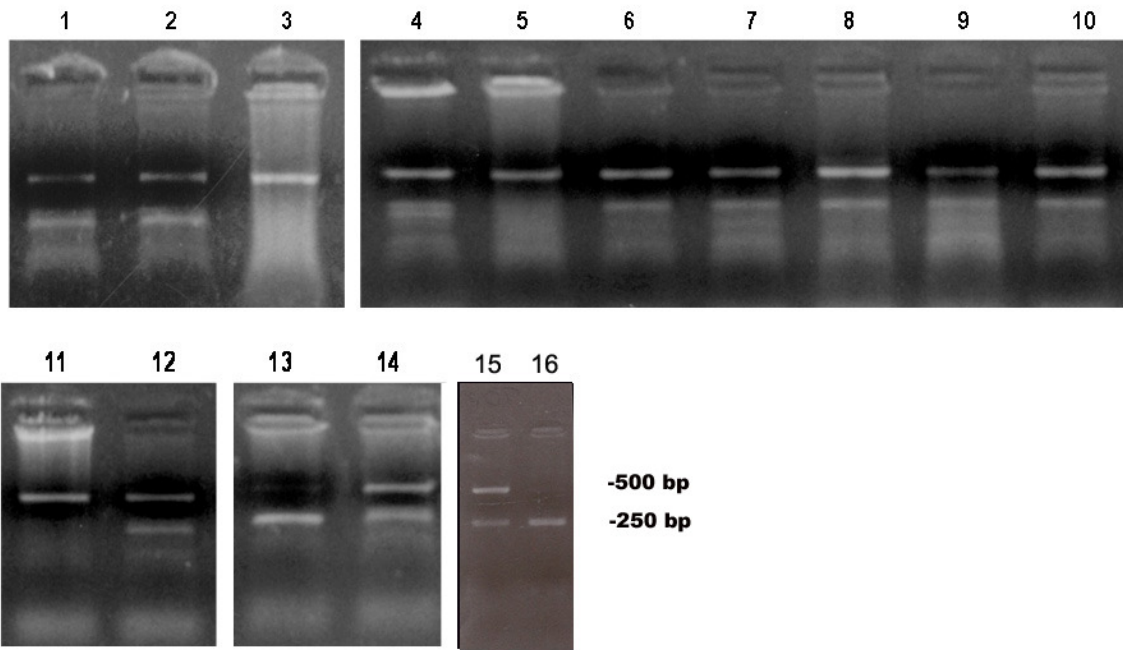


Figure 2. Meningioma samples immunohistochemically stained for the expression of APC and beta-catenin proteins. **a.** Patient with APC LOH negative for the expression of wild type APC protein (Ab-1 that recognizes the amino terminus was used). **b.** Patient without LOH positive to the expression of wild type APC protein (Ab-2 that recognizes the carboxy terminus was used). **c.** Patient with APC LOH demonstrating mutant APC protein (Ab-1 that recognizes the amino terminus was used). **d.** In same patient when tested with Ab-2, no staining was detected. **e.** Patient with APC LOH demonstrating nuclear and cytoplasmic localization of beta-catenin protein. **f.** Patient without APC LOH demonstrating membranous localization of beta-catenin protein.

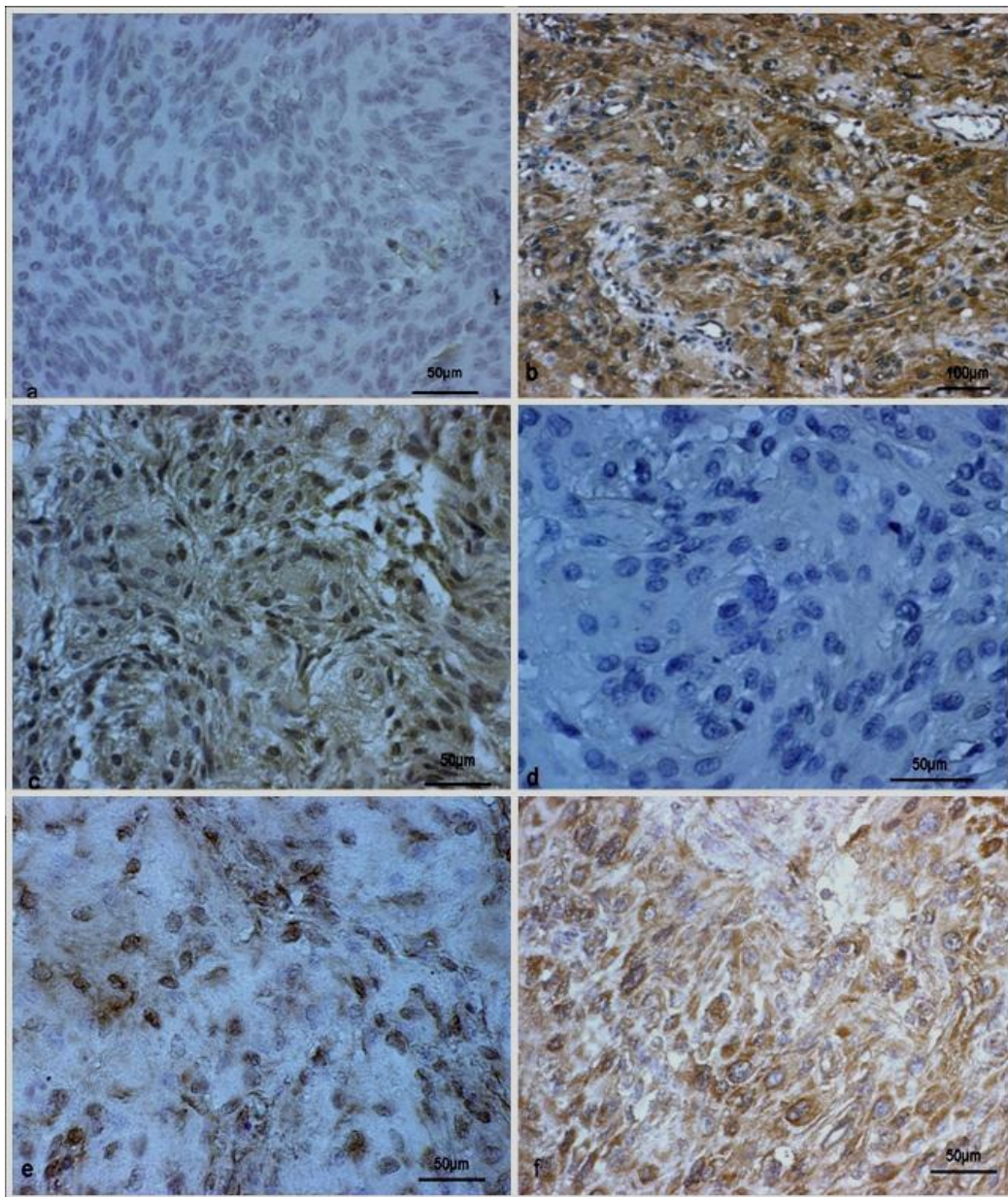


Table 1. Pathohistological grade, demographic variables, the polymorphic status for markers used, LOHs of the APC gene and expression levels of APC and beta-catenin proteins.

PAT.NO.	PHD	SEX	AGE	Rsal	MspI	APC protein expression	β-catenin expression
1	Meningothelial	M	72	HETERO	HETERO	-	-
2	Meningothelial	M	68	HETERO	HETERO	-	M(+)
3	Meningothelial	F	70	HETERO	HETERO	WT(++)	M(+)
4	Meningothelial	F	62	HETERO	HETERO	WT(++)	M(+)
5	Meningothelial ^{Dur}	M	64	LOH	HETERO	-	CN(+)
6	Meningothelial	M	65	HETERO	HETERO	-	CN(+++)
7	Meningothelial	M	35	HETERO	HETERO	WT(+)	M(+)
8	Meningothelial	F	55	HETERO	HETERO	WT(++)	MC(+)
9	Meningothelial	F	47	HOMO A	HOMO 250	WT(+)	-
10	Meningothelial ^{Bon}	M	70	LOH	HETERO	MUTANT	CN(+++)
11	Meningothelial ^{Rec}	M	54	LOH	LOH	-	C(++)
12	Meningothelial	F	69	LOH	LOH	-	CN(+++)
13	Meningothelial	M	52	LOH	HOMO 500	-	N(++)
14	Meningothelial	F	70	LOH	LOH	MUTANT	N(+++)
15	Fibrous (fibroblastic)	M	54	HOMO B	HETERO	MUTANT	-
16	Fibrous (fibroblastic)	F	63	LOH	HOMO 250	MUTANT	N(+)
17	Fibrous (fibroblastic)	F	63	HETERO	HOMO 500	MUTANT	-
18	Fibrous (fibroblastic)	M	45	HETERO	HETERO	MUTANT	-
19	Fibrous (fibroblastic)	F	51	LOH	LOH	-	N(+++)
20	Fibrous (fibroblastic)	F	73	HETERO	HETERO	MUTANT	CN(+++)
21	Transitional (mixed)	F	56	HETERO	LOH	-	N(++)
22	Transitional (mixed)	M	61	LOH	LOH	-	C(++)
23	Transitional (mixed)	M	45	HETERO	HETERO	WT(+)	MC(+)
24	Transitional (mixed) ^{Dur}	F	50	LOH	LOH	-	N(+++)
25	Psammomatous	F	60	HOMO A	LOH	MUTANT	N(++)
26	Angiomatous	M	66	LOH	LOH	-	CN(++)
27	Angiomatous	M	39	HETERO	HETERO	WT(++)	-
28	Angiomatous	F	70	HETERO	LOH	-	N(+)
29	Angiomatous	F	73	HOMO B	LOH	MUTANT	CN(++)
30	Atypical	M	76	HETERO	HETERO	WT(+)	M(+)
31	Atypical	M	56	HOMO A	HETERO	WT(++)	MC(++)
32	Anaplastic (malignant)	F	71	HETERO	HOMO 500	WT(++)	C(+)
33	Anaplastic (malignant)	F	69	HETERO	HETERO	WT(++)	MC(+)

LOH=loss of heterozygosity; HETERO =heterozygous samples; HOMO= homozygous samples; - = no expression; WT = wild type APC protein; MUTANT = truncated APC protein lacking carboxy terminus; M = membranous; C= cytoplasmic; N = nuclear localization; ^{dur}=dura invasion; ^{bon}=bone invasion; ^{rec}=recurrence.

Table 2. Crosstabulation between presence of APC LOH and the expression of the APC protein.

APC	No expression		APC protein Expression wt		Mutant protein		Total	
	O/N	%	O/N	%	O/N	%	O/N	%
No LOH	3/13	23.1	10/10	100.0	4/9	44.4	17/32	53.1
LOH	10/13	76.9			5/9	55.6	15/32	46.9
Total	13	100.0	10	100.0	9	100.0	32	100.0

O = number of observed cases

N = number of analyzed individuals

wt = wild type

Table 3. Crosstabulation between the presence of APC LOH and the expression and localization of beta-catenin protein.

APC	No expression		β-catenin Membraneous		Cytoplasmic and nuclear		Total	
	O/N	%	O/N	%	O/N	%	O/N	%
No LOH	5/5	100.0	9/9	100.0	3/18	16.7	17/32	53.1
LOH					15/18	83.3	15/32	46.9
Total	5	100.0	9	100.0	18	100.0	32	100.0

O = number of observed cases

N = number of analyzed individuals