



Središnja medicinska knjižnica

Pećina-Šlaus, N., Beroš, V., Houra, K., Čupić, H. (2006) *Loss of heterozygosity of the APC gene found in a single case of oligoastrocytoma*. *Journal of neuro-oncology*, 78 (2). pp. 213-215.

<http://www.springerlink.com/content/b117m60t3h8n2n25/>
The original publication is available at www.springerlink.com

<http://medlib.mef.hr/>

University of Zagreb Medical School Repository

<http://medlib.mef.hr/>

Running head: LOH of the APC in oligoastrocytoma

Loss of heterozygosity of the APC gene found in a single case of oligoastrocytoma

LETTER TO THE EDITOR

Nives Pecina-Slaus¹ PhD, Vili Beros² M.D., Karlo Houra² M.D., Hrvoje Cupic³ M.D.

¹ Laboratory of Neurooncology, Croatian Institute for Brain Research, School of Medicine University of Zagreb, Šalata 3, HR-10000 Zagreb, Croatia,

² Department of Neurosurgery, University Hospital "Sestre milosrdnice", Vinogradska 29, 10000 Zagreb, Croatia.

³ Ljudevit Jurak University Department of Pathology, University Hospital "Sestre milosrdnice", Vinogradska 29, 10000 Zagreb, Croatia.

Corresponding author: Nives Pećina-Šlaus

²Laboratory of Neurooncology, Croatian Institute for Brain Research, School of Medicine University of Zagreb, Šalata 3, HR-10000 Zagreb, Croatia,

e-mail: nina@mef.hr, tel. +385 1 46 21 140, fax:+385 1 45 50 744; +385 1 49 20 050; +385 1 45 66 711

Dear Editor,

this study analyses APC gene (Adenomatous polyposis coli) in a 29-year-old female patient with oligoastrocytoma. Oligoastrocytoma sample was tested for gene instability by PCR/loss of heterozygosity using RFLP method. Allelic loss of the APC gene was found in our patient. We wanted to inform you on this interesting finding which may contribute to better understanding of oligoastrocytoma genetic profile.

Key words: oligoastrocytoma, APC gene, loss of heterozygosity

Introduction

Our interest in elucidating the role of tumor suppressor gene—adenomatous polyposis coli (APC) stemmed principally from the findings that wild-type APC protein is highly expressed in the central nervous system, and upon the finding that APC protein is critically involved in particular syndromes, among which the brain tumours play a significant role [1].

Besides the structural role of the APC gene in adherens junctions [2], the protein product of the APC gene plays a signaling role as a negative regulator of the wnt pathway [3]. Components of the wnt signaling pathway, are also implicated in tumor genesis. Mutations in the adenomatous polyposis coli gene are responsible for familial adenomatous polyposis and the majority of sporadic colorectal cancers. However, a large variety of other tumors exhibit mutations of this suppressor gene [4].

The mutations of APC gene are also found in some syndromes, like the Tourcot's syndrome, which among other include the development of brain tumors such as medulloblastomas and gliomas [1, 5].

Oligoastrocytoma is a tumor which is composed of a mixture of two distinct neoplastic cell types morphologically resembling the tumor cells in diffuse astrocytoma (WHO grade II) and oligodendroglioma [6]. Oligoastrocytoma corresponds histologically to WHO grade II [7].

The molecular genetic alterations underlying the oncogenesis and progression of oligoastrocytomas appear to be more heterogeneous than those associated with ordinary astrocytomas and oligodendrogliomas.

Patient and Methods

29 years old female patient was admitted to the Department of Neurosurgery, University Hospital “Sestre Milosrdnice”, Zagreb, Croatia with manifesting symptoms of raised intracranial pressure including severe headache and nausea caused by a brain tumor.

Using the magnetic resonance imaging (MRI) we found a tumor lesion in the right parietal region, with the surrounding zone of perifocal oedema. During the operative procedure the tumor was maximally reduced using a microneurosurgical technique.

The collected tumor tissue was frozen in liquid nitrogen and transported to the laboratory, where it was immediately frozen at -75°C . The peripheral blood sample was processed immediately.

The local Ethical Committee approved our study and the patient gave her informed consent.

DNA extraction. Tumor sample for DNA isolation was the parts of obvious tumor mass (evaluated by neurosurgeon and based on macroscopic appearance and tissue color, density, and consistency on gross section). The sample was also evaluated for the percentage of tumor cells by pathologist and consisted of more than 80% of tumor cells.

Approximately 0.5 g of tumor tissue was homogenized with 1 ml extraction buffer (10 mM Tris HCl, pH 8.0; 0.1 M EDTA, pH 8.0; 0.5% sodium dodecyl sulfate) and incubated with proteinase K (100 $\mu\text{g}/\text{ml}$; Sigma, USA; overnight at 37°C). Phenol chloroform extraction and ethanol precipitation followed.

Blood sample was used to extract lymphocyte DNA. Five ml of blood was lysed with 7 ml distilled water and centrifuged (15 min/5000 g). The pellet was then processed as for DNA extraction from the tissue samples.

Polymerase chain reaction. The optimal reaction mixture (25 μl) for APC's exon 11 amplification was: 20 pmol of each primer (5'-GGACTACAGGCCATTGCAGAA-3' and 5'-GGCTACATCTCCAAAAGTCAA-3'), 200 μM of each dNTP, 200-400 ng template DNA, 1 μl (0.5 U) of Taq polymerase, 1 mM MgCl_2 , 5 μl 10 X reaction buffer II (500 mM KCl, 100 mM Tris-HCl, pH 8.3). Polymerase chain reaction (PCR) conditions were: initial denaturation, 4 min/ 95°C ; denaturation, 1 min/ 94°C ; annealing, 2 min/ 58°C ; extension, 1.5 min/ 72°C ; 35 cycles. The PCR products were analyzed on 2% agarose gels.

Restriction fragment length polymorphism. Loss of heterozygosity (LOH) of the APC gene was detected on the basis of restriction fragment length polymorphism (RFLP) of the PCR products. A Rsa I polymorphic site in exon 11 was investigated. PCR amplification of exon 11 generated a 133- bp fragment that is cleaved to 85- and 48- bp fragments by Rsa I restriction if the polymorphic site is present, and remains uncleaved if the site is absent. PCR aliquots (10–15 μl) were digested with 6 U Rsa I (Gibco, USA; 12 h at 37°C) and were electrophoresed on 15% polyacrylamide gels and on Spreadex EL 300 gels (Elchrom scientific, Switzerland), stained with

SyberGold (Molecular Probes, Netherlands). LOH/Rsa I was demonstrated only in informative (heterozygous) persons when the tumor DNA showed loss of either the single uncut band (133 bp) or of the two cut bands (85+48 bp) compared to autologous blood DNA.

Results and discussion

The histopathological diagnosis of oligoastrocytoma was based on recognition of two different glial components both of which are unequivocally neoplastic which is shown in figure 1.

Immunohistological analysis revealed strong reactivity to glial fibrillary acidic protein (GFAP) in astocytic areas of differentiation while zones with oligodendroglial differentiation contain predominantly GFAP negative cells.

The analysis of Rsa I polymorphic site in APC's exon 11 of our proband's blood sample showed that the patient was heterozygous for this polymorphism. Moreover, the oligoastrocytoma sample demonstrated LOH when compared to the patient's constitutive DNA as shown on figure 2. We performed analysis on Spreadex gel and confirmed it on 13% polyacrylamide gel stained with silver. This finding led us to conclude that our sample comprised gross deletion of the APC gene.

The mechanisms of brain tumor initiation and progression have not yet been completely investigated and elucidated. As with other tumors, the formation of brain tumors is the result of multiple consecutive genetic changes that represent a critical factor in tumor evolution [8]. No consistent genetic abnormalities have been detected that would indicate the genetic profile of oligoastrocytomas [9, 10]. Our result offers APC tumor suppressor gene as a potential candidate involved in development of oligoastrocytoma. We consider our finding a small but relevant contribution to understanding pathophysiological mechanisms of brain tumor formation.

Further investigation regarding this gene on a bigger sample should be performed in future to confirm our suggestion.

Acknowledgements

This work was supported by grant 0108 215 from Ministry of Science and Technology, Republic of Croatia.

References

1. Hamilton SR, Liu B, Parsons RE, Papadopoulos N, Jen J, Powell SM, Krush AJ, Berk T, Cohen Z, Tetu B, Burger PC, Wood PA, Taqi F, Booker SV, Petersen GM, Offerhaus JA, Tersmette AC, Giardiello FM, Vogelstein B, Kinzler KW: The molecular basis of Turcot's syndrome. *N Engl J Med* 332: 839-840, 1995
2. Sieber OM, Tomlison IP, Lamlum H: The adenomatous polyposis coli (APC) tumour suppressor - genetics, function and disease. *Mol Med Today* 6: 462-469, 2000
3. Peifer M, Polakis P: Wnt signaling in oncogenesis and embriogenesis - a look outside the nucleus. *Science* 287: 1606-1609, 2000
4. Kinzler KW, Vogelstein B: Lessons from hereditary colorectal cancer. *Cell* 87: 159-170, 1996
5. Lendahl U: Transgenic analysis of central nervous system development and regeneration. *Acta Anaesthesiol Scand* 110: 116-118, 1997
6. Kleihues P, Cavenee KW: Tumors of the Nervous System. Lyon: International Agency for Research on Cancer (IARC) Press, 2000
7. Kleihues P, Soylemezoglu F, Schauble B, Scheithauer BW, Burger PC: Histopathology, classification, and grading of gliomas. *Glia* 15: 211-221, 1995
8. Reifenberger J, Reifenberger G, Liu L, James CD, Wechsler W, Collins VP: Molecular genetic analysis of oligodendroglial tumors shows preferential allelic deletions on 19q and 1p: *Am J Pathol* 145: 1175-1190, 1994
9. Kraus JA, Koopman J, Kaskel P, Maintz D, Brandner S, Schramm S, Louis DN, Wiestler OD, von Deimling A, Shared allelic losses on chromosomes 1p and 19q suggest a common origin of oligodendroglioma and oligoastrocytoma. *J Neuropathol Exp Neurol* 54: 91-95, 1995
10. Maintz D, Fiedler K, Koopman J, Rollbrocker B, Nechev S, Lenartz D, Stangl AP, Louis DN, Schramm J, Wiestler OD, von Deimling A: Molecular genetic evidence for subtypes of oligoastrocytomas. *Neuropathol Exp Neurol* 56: 1098-1104, 1997

Legends to the figures

Figure 1. Oligoastrocytoma showing the two distinct cell population separated in different areas; oligodendroglial (left) and astrocytic (right) differentiation, (HE, x 400).

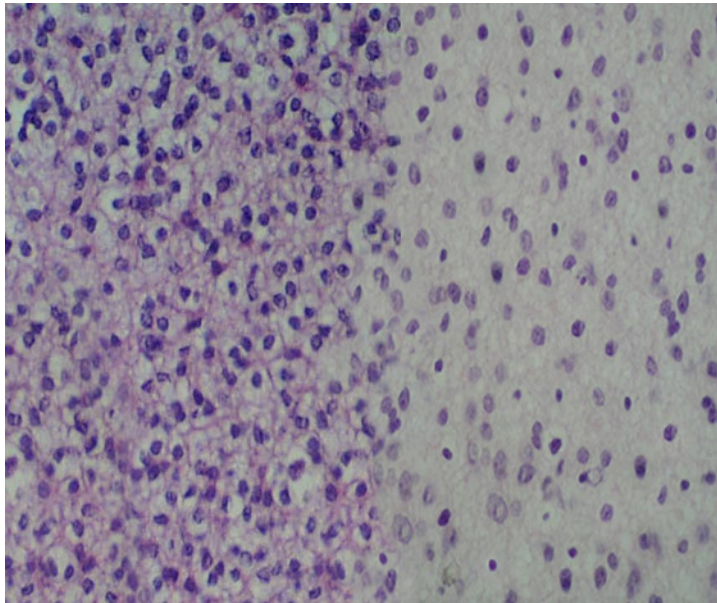


Figure 2. Loss of heterozygosity of gene APC in a 29-year-old-patient with oligoastrocytoma. Exon 11/RsaI/RFLP. Lane 1 - standard DNA/50 bp ladder; lane 2, -LOH, cut allele is missing; lane 3 – corresponding informative blood sample, both alleles, cut and uncut, are visible.

