



Središnja medicinska knjižnica

Bilić, R., Šimić, P., Jelić, M., Štern-Padovan, R., Dodig, D., Pompe van Meerdervoort, H., Martinović, S., Ivanković, D., Pećina, M., Vukičević, S. (2006) *Osteogenic protein-1 (BMP-7) accelerates healing of scaphoid non-union with proximal pole sclerosis*. *International Orthopaedics*, 30 (2). pp. 128-134

<http://www.springerlink.com/content/98821I4k6q855061/>
The original publication is available at www.springerlink.com

<http://medlib.mef.hr/151/>

University of Zagreb Medical School Repository

<http://medlib.mef.hr/>

OSTEOGENIC PROTEIN-1 (BMP-7) ACCELERATES HEALING OF SCAPHOID NON-UNION WITH PROXIMAL POLE SCLEROSIS

R Bilic¹, P Simic², M Jelic^{1,2}, R Stern-Padovan³, D Dodig⁴, H Pompe van Meerdervoort⁵, S Martinovic², D Ivankovic⁶, M Pecina¹, S Vukicevic²

Departments of ¹ Orthopedic Surgery, ² Anatomy, ³ Radiology, ⁴ Nuclear Medicine, ⁶ Medical Statistics, Epidemiology and Medical Informatics, School of Medicine, University of Zagreb, Salata 11, 10000 Zagreb, Croatia and ⁵ Stryker Biotech, Claus Sluterweg 125 B2, 2012 WS Haarlem, The Netherlands

Corresponding author:

Slobodan Vukicevic

Laboratory for Mineralized Tissues

Department of Anatomy

School of Medicine

University of Zagreb

Salata 11

10000 Zagreb

Croatia

Tel/fax: +38514566812

e-mail: vukicev@mef.hr

ABSTRACT

Bone morphogenetic proteins (BMPs) heal nonunions of long bone. In a randomized and controlled pilot study we tested the effect of osteogenic protein-1 (OP-1, BMP-7) on healing of avascular necrosis of the scaphoid proximal pole non-union.

17 patients with proximal pole bone non-union and pre-existing sclerotic bone were randomly assigned to one of three groups: (1) Autologous iliac graft (n=6), (2) Autologous iliac graft + OP-1 (n=6) and (3) Allogeneic iliac graft + OP-1 (n=5). Radiographic, scintigraphic and clinical assessment was performed throughout the follow-up period of 24 months.

OP-1 improved the performance of both autologous and allogeneic bone implants and reduced radiographic healing time to 4 weeks as compared to 9 weeks in the autologous bone only treated group. Helical CT scans and scintigraphy showed that the pre-existing sclerotic bone within proximal scaphoid poles was mainly replaced in OP-1 treated patients with well vascularized bone. Addition of OP-1 to allogeneic bone implant equalized the clinical outcome with the autologous graft procedure and enabled circumventing the second donor graft harvest procedure.

This is the first evidence that a recombinant BMP enhances radiographic healing of the scaphoid non-union and revascularization and removal of pre-existing sclerotic bone from the proximal pole avascular necrosis.

INTRODUCTION

Scaphoid fracture is the most common carpal bone fracture [4]. Approximately 5%-10% scaphoid fractures proceed to a non-union [13]. Although initially asymptomatic, most nonunions progress to produce a painful wrist with impaired function, clinically significant loss of motion, increased weakness and degenerative arthritis [18]. The treatment of scaphoid non-union still remains a problem considering its vulnerable blood supply, irregular shape, special oblique alignment across the motion plane of the mid-carpal joint and complex function linking proximal and distal carpal rows [8]. Bone graft with or without internal fixation by a screw or wires is the standard treatment for symptomatic scaphoid non-unions without osteoarthritis [10, 21, 23, 25]. Cancellous bone grafting, first described by Matti and modified by Russe is the most common surgical treatment [6], requiring approximately 13 weeks for scaphoid non-union to heal. Modified Matti-Russe procedure by Bilic, using compressed cancellous bone grafting, requires approximately 9 weeks to heal scaphoid pseudoarthroses [1]. These techniques achieve union in 70-90% of patients and the type of fracture and the vascularity of the proximal pole are important determinants of the success of therapy [9]. Recent meta analysis of scaphoid nonunion literature indicate a 94% success rate in unstable nonunions treated with a screw fixation and grafting, but only 47% in patients with concomitant avascular necrosis [15]. Therefore we have tried to improve the treatment of scaphoid bone non-union with avascular pole necrosis by use of bone morphogenetic proteins (BMPs).

Bone morphogenetic proteins (BMPs) or osteogenic proteins (OPs) are growth and differentiation factors capable of initiating the recruitment, attachment, proliferation and differentiation of mesenchymal cells, leading to new bone formation [14, 24]. Extensive clinical and preclinical research has been undertaken to investigate the role of OP-1 (BMP-7) in bone and cartilage regeneration [17]. OP-1 heals critical-sized diaphyseal defects and

nonunions of long bones, enhances bone graft incorporation and implant fixation, increases remodeling and bone ingrowth of bone grafts and bone substitutes [3, 5, 7, 14].

The aim of this pilot study was to test if the recombinant BMP-7 (osteogenic protein – 1; OP-1), a signaling molecule for initialing osteogenesis [14], could enhance radiographic and clinical healing and removal of sclerosis in scaphoid non-unions containing sclerotic bone.

MATERIALS AND METHODS

The study design

The criteria for inclusion in the study comprised male or female patients between ages of 15 and 30 years with a symptomatic proximal pole scaphoid non-union for at least 9 months of duration with no evidence of progressive healing over the previous 3 months, and a presence of 100 mm² or more pre-existing sclerotic bone in the proximal scaphoid pole as determined preoperatively by spiral CT. Study exclusion criteria comprised patients with: prior surgical treatment, carpal collapse, immature skeleton and unable or unwilling to fulfill the follow-up requirements. One hundred and thirty nine patients were screened for scaphoid non-unions in the period from January 1999 till January 2003 in the Department of Orthopedic Surgery, University of Zagreb.

Patients were randomly assigned to one of the treatment groups using a computer-generated randomization. The cohorts were defined as follows: 1. Autologous iliac graft only (n=6), 2. Autologous iliac graft + OP-1 (n=6), and 3. Allogeneic iliac graft + OP-1 (n=6). The study was performed in compliance with the Helsinki Declaration and fulfilled the consort statement requirements [16]. The bone grafts were prepared according to modified Matti-Russe procedure by Bilic [1] using compressed iliac bone, showing better compaction as compared to radial spongiosa. Surgeons were aware of the treatment group to which each patient was assigned after the random selection process. At 2 months following surgery and removal of the cast physical therapy was introduced and included active exercise of the wrist and fingers, as well as supported and passive exercise.

Demographics

The demographics of the study groups is presented in Table 1. Three randomly assigned groups of young men were similar ($P>0.05$) in many respects, including age, body mass index, duration of non-union, fracture site, direction of fracture line, and area of proximal pole

sclerosis. The mean time from original injury to treatment of scaphoid nonunion was 14 months (range 9 - 20 months). All patients had pain and weakness, loss of motion, decreased grip strength and fatigue with repetitive work. In most patients, preoperative motion was restricted and grip strength was decreased to a mean of 62%.

OP-1 Implant

The OP-1 Implant (Osigraft) composed of 3.5 mg recombinant human OP-1 (BMP-7) and 1 gram of collagen as a carrier was obtained from Stryker Biotech (Hopkinton, Massachusetts). The OP-1 implant was applied to both scaphoid fragments and subsequently autogenous or allogeneic bone implants were positioned as per Mati-Russe technique.

Methods of clinical assessment

The clinical evaluation included the presence of pain assessment by visual analogous scale during rest, at maximal grip strength and at maximal dorsal flexion of the wrist. Additionally, measurements of movements in radiocarpal joint, strength of the grip and strength of the pinch on both hands were assessed. Patients were clinically evaluated after removal of a post operatively applied cast, no later than 2 months post operatively, and thereafter at 2, 4, 5, 9, 12 and 24 months. Physical therapy started following removal of the cast. In addition, date and details of original injury, previous treatments, body mass index and smoking status were also recorded.

Radiographic analysis

1. Union was assessed on X-rays utilizing plain film in four views.

Radiographs of both hands were taken prior to surgery, of affected hand immediately following surgery, and then 1, 2, 2.5 or 3 (2.5 if the healing was more than 75% and 3 months

if less than 75%), 4, 9 and 24 months following surgery. X-rays were evaluated by two radiologists, blinded to treatment and time following the surgical procedure, assessing whether 0-33, 34-66 or 67-100 percent of the scaphoid bone surface remodeled healed. Healing of the regenerating scaphoid bone reflects a gradual replacement of the graft by newly formed and well incorporated bone, including its full mineralization in time.

Computerized tomography

Helical CT scans were used to assess preoperatively the amount of proximal pole sclerotic bone since only patients with more than 100 mm² of sclerotic bone area have been randomly included into the study. Pre-existing sclerotic bone from the proximal scaphoid pole was measured by the helical CT software (AW 4.2 General Electric Medical System – GEMS) and then manually confirmed by a planimeter on multiple CT sections taken immediately following the surgery. Bone was also tested during the surgery and was considered sclerotic and avascular by demonstration of the absence of punctuate bleeding from the fragments on exposed bone. CT of the affected hand was taken prior to surgery, immediately following surgery, and then at 3, 9, 12 and 24 months following surgery. Proximal pole sclerotic bone removal was assessed by blinded interpretation of CT scans to assess the efficacy of a single application of BMP-7 (administered with an auto- or allograft) as compared to autograft treatment alone. Sections were made at 0.6 mm intervals [19].

Three-phase bone scintigraphy

To additionally assess removal of sclerotic pre-existing bone by new blood vessels, patients were subjected to three-phase 99m Technetium-dicarboxypropane diphosphonate (99mTc-DPD) scintigraphy prior to surgery and then at 24 months following surgery. The angiographic phase (0-60 sec post injection) was acquired in dorsal projection after bolus

injection of 600 MBq ^{99m}Tc-DPD. The blood pool phase of the tracer was investigated 10-20 min following injection and bone uptake phase 3 h following injection. Bone scans of radiocarpal joint of the operated and healthy hands were obtained with a LFOV gamma-camera (Siemens, DIACAM) in the dorsal position. The affected area was measured planimetrically.

Data analysis

Distributions of all quantitative data were tested with Kolmogorov-Smirnov test. In spite of small sample sizes all distributions conform to normal distribution, hence parametric analytical procedures were applied. Demographic data and functional measurement data within the same time point were analyzed with One way ANOVA with one-sided Dunnett t post hoc test against autograft only treated patients. Sclerotic bone area changes were analyzed with two way ANOVA for repeated measurements with Shaffe post hoc test. Analysis was performed using the STATISTICA computer program, version 6.0 (StatSoft, Inc., Tulsa, OK, USA).

RESULTS

Radiographic results

One patient who received the allogeneic bone and OP-1 was lost for the follow up (Table 1). The scaphoid nonunion in the remaining 17 patients healed as assessed by conventional x-rays and CT analysis (Figure 1). Four weeks following the surgery 70%-95% of bone in autograft + OP-1 patients demonstrated radiographic bridging as compared to 60%-80% in both allograft + OP-1 and autograft only treated patients ($p < 0.05$). At 4 weeks radiographic

data could not be correlated to clinical parameters since the hand was still immobilized. At 8 weeks following surgery 90%-100% of bone in autograft + OP-1 patients showed radiographic bridging as compared to 75%-90% in both allograft + OP-1 and autograft only treated patients (not significant).

Between all follow up time points within each treatment group statistically significant decrease of sclerotic bone area has been observed (Table 2, Figure 2). Steeper loss of sclerotic bone area was demonstrated in patients treated with OP-1 as compared to autograft only in the first and last follow up period. On the contrary, between 3 – 12 months of follow up the loss of sclerotic bone area was similar in all groups of patients. At 24 months follow-up nonunion fractures healed in all 17 patients. However, the sclerotic bone almost fully disappeared in autograft and OP-1 treated patients (Table 2, Figure 2E) as compared to autograft only treated patients (Table 2, Figure 2B), indicating an accelerated process of sclerotic bone resorption following full restoration of bone integrity (Table 2, Figure 2E). In patients treated with allogeneic bone and OP-1 an increased and transient radiolucency along the graft was observed at 8 weeks following surgery (Figure 1 G-I), which did not influence the clinical outcome as evidenced by functional clinical tests (Table 3). At 24 months following surgery (Figure 2F) the pre-existing sclerotic bone of allogeneic bone and OP-1 treated patients was also significantly reduced as compared to autograft only treated patients (Table 2).

Clinical outcome

Patients in both autologous iliac bone group and autologous iliac bone and OP-1 had pain at a donor site following surgery. Those treated with allogeneic bone and OP-1 had approximately 50 ml less blood loss due to the lack of second operation and had no pain at the pelvic site. Additionally, these patients were exposed to anesthesia 95 min as compared to 140 min of patients undergoing both operations. There were no reported adverse events. Patients in all

three groups showed improvement of functional measurements and clinical outcome throughout the period of 24 months (Table 3). Four months following surgery, patients treated with autologous bone and OP-1 reached about 91% of functional values of the non-affected hand and had statistically significant improvement in functional measurements of ulnar and radial deviation, palmar and dorsal flexion, pinch strength and pain during maximal dorsiflexion and during maximal grip as compared to autograft only treated group of patients (Table 3). Patients treated with allogeneic bone and OP-1 showed about 85% of function of the healthy hand and had significantly improved radial deviation and pain during maximal grip at 4 months following surgery as compared to patients treated with autologous bone only. There were no statistically significant differences in functional tests between patients treated with autologous bone and OP-1 and those treated with allogeneic bone and OP-1. Patients treated with autologous bone graft had 75% of healthy hand function. Two years following surgery patients in all three treatment groups had good functional results. Patients treated with allogeneic bone and OP-1 had reduced pain during maximal grip as compared to autograft only treated patients.

Scintigraphic results

Patients subjected to scintigraphic analyses by ^{99m}Tc had normal perfusion during the arterial phase, without signs of infection. Blood pool image showed increased uptake in patients treated with OP-1 corresponding to formation of new vascular spaces and bone marrow, while in control patients normal blood-pool image probably corresponds with stable phase. The late bone scans showed higher tracer uptake in patients treated with OP-1 and bone graft, as compared to patients treated only with autologous bone (4.86 in autograft+OP-1, 4.57 in allograft+OP-1 and 3.26 cm^2 in autograft only treated patients, $P < 0.05$) (Figure 2), suggesting increased bone vascularity and metabolic activity in OP-1 treated scaphoids. Both

groups of patients showed increased tracer uptake in the affected hand as compared to the healthy hand (Figure 2). These results confirm that OP-1 added to both autologous and allogeneic bone graft accelerated vascular ingrowth and subsequent replacement of pre-existing sclerotic bone (Figure 2 E and F).

DISCUSSION

The results of this pilot study demonstrate that a recombinant human OP-1 (BMP-7) supports proximal pole scaphoid non-union healing via increased bone vascularization and replacement of pre-existing proximal pole sclerotic bone as a consequence of avascular necrosis. OP-1 enhances radiological healing of scaphoid non-unions in autologous bone treated patients, reducing the healing time to 4 weeks as compared to 9 weeks in the autologous bone only treated patients. Potential shortening of the immobilization period by OP-1 might considerably reduce the incidence of arthritic changes in radioscapoid and radiocarpal joints, contractures of immobilized joints and eventually the Sudeck's dystrophy. This is also a way of preventing muscular atrophy of the forearm and hand, enabling patients to return earlier to work. Patients treated with allogeneic bone implant and OP-1 showed radiographic healing 8 weeks following surgery, which was comparable to autologous bone only treated patients, suggesting that autologous bone implant could be replaced when allogeneic bone implant is used in combination with OP-1. The use of autogenous iliac graft is linked to side-effects by the nature of a donor site, leading to increased operative blood loss, postoperative pain at the donor site and increased probability of infection. Furthermore, addition of OP-1 to both autologous and allogeneic bone significantly improves functional performance of the affected hand as compared to autologous treatment only.

Despite extensive experience the treatment of scaphoid fracture is still a difficult problem. The worst healing rate has been described in patients with avascular necrosis of the proximal

fragment (47%), with an option of vascularized bone grafting implantation which leads to questionable results [15, 22]. Since OP-1 enhanced the vascular ingrowth into the scaphoid, more precursor cells became available to this specific environment resulting in accelerated removal of sclerotic bone of the proximal pole in patients treated with OP-1. Up to now, BMPs have been successfully tested in clinical trials and subsequently approved for treating long bone non-unions [7], acute fractures [12] and spinal fusions [2].

The likelihood of healing scaphoid non-unions was decreased in our patients due to delayed time between injury and the operation of the non-union, avascular necrosis of the proximal pole, which normally has a poor blood supply (Table 1). As scaphoid branches of the radial artery supply about 70-80% of bone, fractures separating the proximal pole, which is completely covered with hyaline cartilage, leads to roughly 30-40% necrosis following this type of fracture [20]. Successful outcome in these patients due to addition of OP-1 was achieved in part by increased vascular ingrowth resulting in accelerated removal of sclerotic bone from the proximal scaphoid poles. Enhanced vascularization enabled both greater number of preosteoblasts and preosteoclasts to reach this specific environment. Contrary to outcome of this study, it was reported that purified native BMP and iliac crest bone along with a biocoral or screw fixation in the treatment of scaphoid nonunions [11] resulted in poor clinical results eventually due to compromised avascular environment which prevented access of the native BMP and stem cells. This resulted in inadequate resorption of biocoral implants. The controlled dosing and pronounced angiogenic effect with recombinant human BMP as compared to purified bovine BMP may explain the different outcome in the two studies.

Timely application of OP-1 in treating scaphoid fractures may thus prevent development of avascular necrosis and subsequent osteosclerosis and help restoring normal bone structure by simulating removal and replacement of sclerotic bone.

This study has also shown that application of OP-1 with an allograft results in healing of the scaphoid non-union as well. Use of an allograft from the donor's iliac crest avoids the autograft donor site morbidity which includes less bleeding, less pain, less infection possibility and shorter procedure.

In conclusion, this clinical study demonstrated that recombinant BMP resulted in a radiological and clinical repair of a scaphoid avascular and necrotic proximal pole non-unions. The results of this study serve also as a hope for patients with avascular necrosis of the femoral head which is one of the most challenging, yet unsolved orthopedic problems.

REFERENCES

1. Bilic R, Korzinek K (1987) Results of scaphoid non-union treatment by Matti-Russe procedure using compressed cancellous bone. *Unfallchirurg* 90:134-138.
2. Burkus JK, Gornet MF, Dickman CA, Zdeblick TA (2002) Anterior lumbar interbody fusion using rhBMP-2 with tapered interbody cages. *J Spinal Disord Tech* 15:337-349.
3. Cook SD, Rueger DC (2002) Preclinical models of recombinant BMP induced healing of orthopedic defects. In: Vukicevic S, Sampath K, eds. *Bone morphogenetic proteins: From laboratory to clinical practice*. Basel, Boston, Berlin: Birkhäuser Verlag, 121-144.
4. Cooney WP, Linscheid RL, Dobyns JH, Wood MB (1988) Scaphoid nonunion: Role of anterior interpositional bone grafts. *J Hand Surg* 13A:635-650.
5. Djapic T, Kusec V, Jelic M, Vukicevic S, Pecina M (2003) Compressed homologous cancellous bone and bone morphogenetic protein (BMP)-7 or bone marrow accelerate healing of long-bone critical defects. *Int Orthop* 27:326-330.
6. Fisk GR (1984) The wrist. *J Bone Joint Surg* 66B:396-407.
7. Friedlaender GE, Perry CR, Cole JD, Cook SD, Cierny G, Muschler GF, et al (2001) Osteogenic protein-1 (bone morphogenetic protein-7) in the treatment of tibial nonunions. *J Bone Joint Surg* 83A:S151-158.
8. Gelberman RH, Wolock BS, Siegel DB (1989) Fractures and non-unions of the carpal scaphoid. *J Bone Joint Surg* 71A: 1560-1565.
9. Green DP (1985) The effect of avascular necrosis on Russe bone grafting for scaphoid nonunion. *J Hand Surg* 10A:597-605.
10. Inoue G, Shionoya K, Kuwahata Y (1997) Ununited proximal pole scaphoid fractures. Treatment with Herbert screw in 16 cases followed for 0.5-8 years. *Acta Orthop Scand* 68:124-127.

11. Kujala S, Raatikainen T, Ryhänen J, Kaarela O, Jalovaara P (2002) Composite implant of native bovine bone morphogenetic protein (BMP) and biocoral in the treatment of scaphoid nonunions-a preliminary study. *Scan J Surg* 91:186-190.
12. Lieberman JR, Daluiski A, Einhorn TA (2002) The Role of Growth Factors in the Repair of Bone : Biology and Clinical Applications *J Bone Joint Surg* 84A:1032-1044.
13. Mack GR, Bosse MJ, Gelberman RH, Yu E (1984) The natural history of scaphoid non-union. *J Bone Joint Surg* 66A:504-509.
14. Martinovic S, Simic P, Borovecki F, Vukicevic S (2004) Biology of bone morphogenetic proteins. In: Vukicevic S, Sampath K, eds. *Bone Morphogenetic Proteins: Regeneration of Bone and Beyond*. Basel, Boston, Berlin: Birkhäuser Verlag, 45-72.
15. Merrell GA, Wolfe SW, Slade JF 3rd (2002) Treatment of scaphoid nonunions: quantitative meta-analysis of the literature. *J Hand Surg* 27A:685-691.
16. Moher D, Schulz KF, Altman DG (2001) The CONSORT statement: revised recommendations for improving the quality of reports of parallel-group randomised trials. *Lancet* 1191-1194
17. Pecina M, Giltaij LR, Vukicevic S (2001) Orthopaedic applications of osteogenic protein-1 (BMP-7). *Intl Orthop* 25:203-208.
18. Ruby LK, Stinson J, Belsky MR (1985) The natural history of scaphoid non-union. *J Bone Joint Surg* 67A:428-432.
19. Sanders WE (1988) Evaluation of the humpback scaphoid by computed tomography in the longitudinal axial plane of the scaphoid. *J Hand Surg* 13A:182-187.
20. Sherman SB, Greenspan A, Norman A (1983) Osteonecrosis of the distal pole of the carpal scaphoid following fracture-a rare complication. *Skeletal Radiol* 9:189-91.

21. Stark A, Brostrom LA, Svartengren G (1987) Scaphoid nonunion treated with the Matti-Russe technique. Long-term results. *Clin Orth* 214:175-180.
22. TambeAD, Cutler L, Stilwell J, Murali SR, Trail IA, Stanley JK (2005) Scaphoid non-union: The Role of Vascularized Grafting in Recalcitrant Non-Unions of the Scaphoid. *J Hand Surg [Br]*. (Epub, ahead of print)
23. Trezies AJ, Davis TR, Barton NJ (2000) Factors influencing the outcome of bone grafting surgery for scaphoid fracture non-union. *Injury* 31:605-607.
24. Vukicevic S, Stavljenic A, Pecina M (1995) Discovery and clinical applications of bone morphogenetic proteins. *Eur J Chem Clin Biochem* 33: 661-671.
25. Warren-Smith CD, Barton NJ (1988) Non-union of the scaphoid: Russe graft vs Herbert screw. *J Hand Surg* 13B: 83-86.

Table 1. Patient demographics

	Study groups		
	OP-1 + autograft n=6	Autograft only n=6	OP-1 + allograft n=5
Non-union duration (months) ⁺	15±5	14±5	13±4
Fracture site (proximal / middle / distal)	1/3/2	1/4/1	1/3/1
Proximal pole sclerosis CT area (>100 mm ²)	6	6	5
Age (years) ⁺	23±5	22±5	19±4
Body mass index (kg/m ²) ⁺	20,1±1,5	21,3±2,1	19,8±1,3
Tobacco	3	3	2

ANOVA analysis of duration, age and body mass index was not different between patient cohorts
⁺ mean±SD

Table 2. Sclerotic bone areas as assessed by CT

	Sclerotic area (mm ²) (range)			
	Immediately following surgery	3 months following surgery	9 months following surgery	24 months following surgery
Autograft only	148.3±11.9 (136-168)	138.3±15.1 ⁽¹⁾ (122-160)	118.8±19.0 (95-141)	111.5±8.6 (103-126)
Autograft + OP-1	121.5±12.5 (111-140)	74.0±14.1 ⁽¹⁾ (59-93)	44.7±11.3 ⁽²⁾ (31-62)	31.7±6.8* (25-40)
Allograft + OP-1	133.7±9.2 (121-144)	103.6±13.2 ⁽¹⁾ (89-122)	77.2±7.8 ⁽²⁾ (69-86)	55.6±11.7* (42-69)

*p<0.05 vs. autograft only

⁽¹⁾ p<0.05 vs. before surgery

⁽²⁾ p<0.05 vs. 3 months following surgery and p<0.01 vs. before surgery

Table 3. Functional measurement of scaphoid non-union healing at 4 and 12 months following surgery

functional test	healthy hand	4 months			12 months		
		autograft only	autograft + OP-1	allograft + OP-1	autograft only	autograft + OP-1	allograft + OP-1
ulnar deviation ⁺	47±6*	38±5	49±5*	40±4	50±5	57±5	58±6
radial deviation ⁺	30±4*	20±4	29±3*	26±3*	32±3	35±4	34±3
palmar flexion ⁺	74±9*	52±6	60±6	59±6	70±7	78±8	76±9
dorsal flexion ⁺	66±7*	46±6	60±5*	55±5	67±6	69±6	68±7
grip strength [‡]	44±5*	28±4	36±4	31±3	35±4	41±5	37±3
pinch strength [‡]	9±2*	6±1	8±2*	6±1	9±2	10±2	9±2
pain in rest#	0	0	0	0	0	0	0
pain during maximal grip #	0*	5±1	0*	3±1*	6±1	3±1	0*
pain in maximal dorsiflexion #	0*	15±2	0*	11±2	11±2	6±1	3±1

⁺ degrees; [‡] kg

Patients were asked to draw a point on a line showing pain from 0 (no pain) to 100 (maximal pain); analogous measurement scale.

*p<0.05 vs autograft only, ANOVA Dunett test

FIGURE LEGEND

Figure 1. Radiograph of a patient (No. 1) treated with autologous bone implant before (A) and 8 weeks following surgery (B). CT scan at 9 months following surgery is shown in (C).

Radiograph of a patient (No. 7) treated with autologous bone and OP-1 before (D) and 8 weeks following surgery (E). CT scan at 9 months following surgery is shown in (F).

Radiograph of a patient (No. 13) treated with allogeneic bone and OP-1 before (G) and 8 weeks following surgery (H). CT scan at 9 months following surgery is shown in (I).

Figure 2. Late bone scintigraphy of a patient (No. 1) treated with autologous bone (A), patient (No. 7) treated with autologous bone and OP-1 (B) and patient (No. 13) treated with allogeneic bone and OP-1 at 24 months following surgery (C). Higher uptake of ^{99m}Tc is present in surgically treated scaphoids (arrows), as compared to opposite healthy hand (h). Increased vascular spaces in OP-1 treated patients (B, C) at 24 months following surgery indicate its permanent presence. 3D reconstruction of CT scans of a patient (No. 1) treated with autologous bone only (D), patient (No. 7) treated with autologous bone and OP-1 (E) and patient (No. 13) treated with allogeneic bone and OP-1 (F) at 24 months following surgery. Minimal amounts of sclerotic bone (OS) are present in the proximal pole of the patient (No. 7) treated with autologous bone and OP-1.

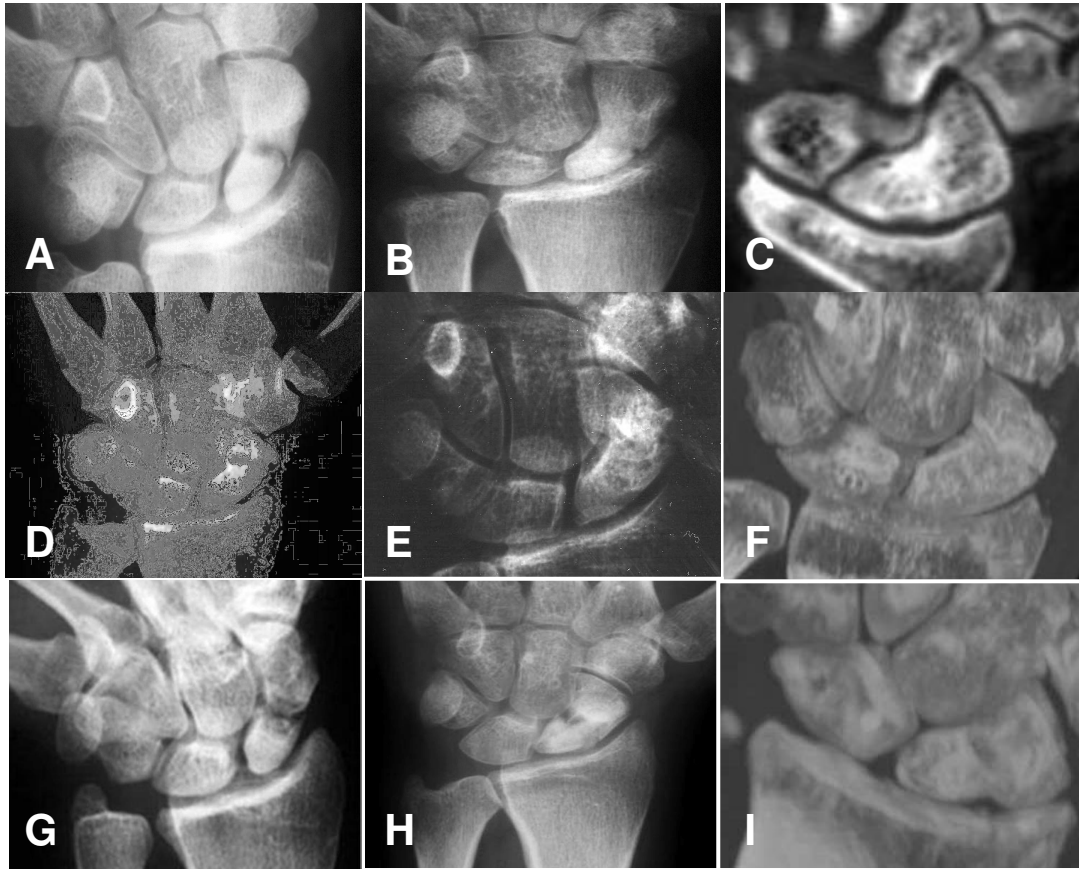


Figure 1.

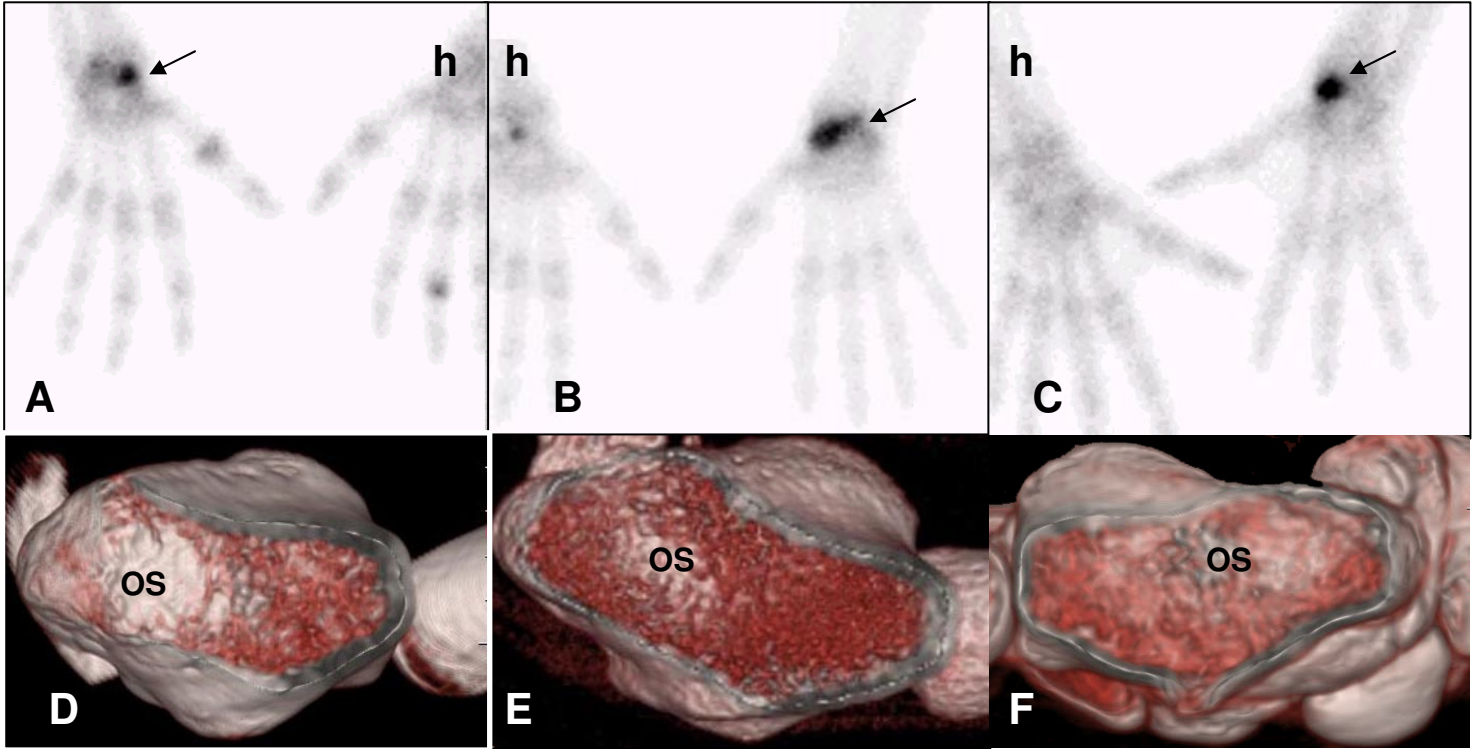


Figure 2.