



Središnja medicinska knjižnica

Pavelić, K., Dedivitis, R.A., Kapitanović, S.A., Čačev, T., Guirado, C.R., Danić, D., Radošević, S., Brkić, K., Pegan, B., Križanac, S., Kusić, Z., Spaventi, S., Bura, M. (2006) *Molecular genetic alterations of FHIT and p53 genes in benign and malignant thyroid gland lesions*. Mutation Research - Fundamental & Molecular Mechanisms of Mutagenesis, 599 (1-2). pp. 45-57.

<http://medlib.mef.hr/72/>

University of Zagreb Medical School Repository

<http://medlib.mef.hr/>

MOLECULAR GENETIC ALTERATIONS OF *FHIT* AND *p53* GENES IN BENIGN AND MALIGNANT THYROID GLAND LESIONS

Kresimir Pavelic¹, Rogerio A. Dedivitis², Sanja Kapitanovic¹, Tamara Cacev¹, Cristiano R. Guirado³, Davor Danic⁴, Senka Radosevic⁵, Kornelije Brkic⁶, Boris Pegan⁶, Simun Krizanac¹, Zvonko Kusic⁶, Sime Spaventi⁷, Miljenko Bura⁸

¹Division of Molecular Medicine, Ruder Boskovic Institute, Zagreb, Croatia,

²Department of Head and Neck Surgery, Hospital Ana Costa and Santa Casa da Misericordia, Santos, Brazil,

³Medical Academy, School of Medicine, Metropolitan University, Santos, Brasil

⁴Division of Head and Neck Surgery, General Hospital Slavonski Brod, Croatia,

⁵PLIVA d.d., Research and Development, Zagreb, Croatia

⁶Clinical Hospital "Sestre Milosrdnice", Department of Head and Neck Surgery, Zagreb, Croatia

⁷Croatian Academy of Sciences and Arts, Zagreb, Croatia

⁸Clinical Hospital Center Zagreb, Department of Otorhinolaryngology and Head and Neck Surgery "Salata", Zagreb, Croatia

Short running title: FHIT and p53 in thyroid gland lesions

Grants: This work was supported in part by grants number 0098093, 0101023 and 0098106, from the Ministry of Science and Technology, Republic of Croatia.

Address for correspondence: Professor Kresimir Pavelic, Division of Molecular Medicine, Ruder Boskovic Institute, Bijenicka 54, P.Box 180 HR-1002 Zagreb, Croatia,

telephone +385-1-4680094, telephax +385-1-4561010,

E.mail pavelic@irb.hr

ABSTRACT

Several oncogenes and tumor-suppressor genes are involved either as early or late event in thyroid gland carcinogenesis. Human *FHIT* (fragile histidine triad) gene is highly conserved gene whose loss of function may be important in the development and/or progression of various types of cancer. We undertook this study to analyze *FHIT* and *p53* gene status in different benign and malignant thyroid tumors. Status of these genes as well as intensity of apoptosis were analyzed in tumor tissues by molecular genetic methods, immunohistochemistry, and FACS-scan analysis. The majority of the malignant thyroid cancers displayed aberrant expression of *FHIT* gene, concomitant with *p53* gene inactivation. This is followed by low rate of apoptosis which may be important in the development and/or progression of thyroid cancer. We found higher incidence of *p53* mutation and aberrant processing of *FHIT* mRNA in malignant tumors (papillary, follicular, medullary and anaplastic carcinomas) and in those tumors with distant metastasis. The growth of *p53*⁻/*FHIT*⁻ follicular carcinoma of human origin was much faster in nude mice than *p53*⁺/*FHIT*⁺ follicular carcinoma, and mice had shorter survival rate. Our results show a correlation between aberrant *FHIT* and *p53* expression, low rate of apoptosis, and malignancy. Concomitant aberration of *FHIT* gene and *p53* could be responsible for development of highly malignant types of thyroid cancer and may be considered as a prognostic marker for these tumors.

Key words: *FHIT*, *p53*, apoptosis, benign thyroid gland lesions, thyroid cancer

INTRODUCTION

Thyroid gland tumors exhibit a broad spectrum of neoplastic pathology, ranging from benign colloid adenomas to fatal anaplastic carcinomas [1]. Several oncogenes (*ras*, *ret*, *trk*) and tumor-suppressor genes (*p53*, *Rb*, *p16/CDKN2*, *p21^{waf1}*) have been associated with this kind of tumors. *Ras* oncogene activation is an early event and appears to be involved in the genesis of follicular adenoma and carcinoma [2]. Three other genetic and/or epigenetic alterations play a role in PTC pathogenesis: activating mutation of *ras* genes, c-met overexpression and downregulation of E-cadherin in papillary carcinoma. Recently, another major player in papillary carcinoma etiopathogenesis has been reported: the *BRAF* gene. Papillary carcinoma is one of the human cancers displaying the highest prevalence of *BRAF* mutations, which occur almost always in the same hot spot (V600E). The finding of a high prevalence of *BRAF* mutations, together with the involvement of *ras* mutations and *ret/PTC* rearrangements in the majority of papillary carcinomas, points to the crucial role played by alterations at the *ret/ras/BRAF/MAPK* signal transduction pathway in the pathogenesis of papillary carcinoma [3]. Generally, mechanisms governing the transformation of normal thyroid cells into carcinoma are not well understood. Thyroid epithelium is the second most common tissue type (after blood) where fusion gene products are critical for the early development of cancer [4]. The *ret* gene is frequently inverted or translocated to form the fusion genes *ret/PTCs* [5] but those genes alone are insufficient to cause cancer and require the simultaneous or accumulated activation of multiple gene products to progress from early differentiated stages to undifferentiated stages of malignancy.

The *FHIT* gene, located in 3p14.2 is very often inactivated in various types of cancer [6-8]. The mechanisms of *FHIT* inactivations are biallelic deletions, loss of heterozygosity, aberrant methylation, while point mutations are rare [9-11]. *FHIT* is encoded at FRA3B, the most frequent fragile site in human genome and *FHIT* loss is a frequent event in carcinogenesis [8].

Loss of *FHIT* protein expression and abnormal *FHIT* transcripts, including deletions of exons and insertions, are found in a high percent in lung and breast cancers [6,12-14] as well as in head and neck cancers [15]. *FHIT* is a putative tumor suppressor and belongs to the histidine triad superfamily of nucleotide-binding proteins. Re-expression of *FHIT* in cancer cell lines with *FHIT*-deletions suppressed their ability to form tumors in mice [16]. Analysis of preneoplastic and neoplastic lesions from the lungs of smokers has indicated that events that lead to lack of expression of *FHIT* are the earliest and the most frequent identified genetic changes in lung cancers [6].

Several studies indicate the aberration of *FHIT* gene in thyroid cancer. McIver et al. [17] found abnormal RNA processing as a common event in thyroid neoplasms. Zou et al. [2] described defective *FHIT* gene in both benign and malignant thyroid tumors, suggesting that the inactivation of this tumor suppressor gene is likely to be an early event in the pathogenesis of some forms of thyroid neoplasms.

Gene *p53* is another important gene in thyroid cancer progression. Some data suggest that *p53* mutations are involved in thyroid carcinogenesis and may play an important role in the malignant transformation of thyroid cells as well as thyroid tumor progression [18]. Alteration in *p53* contribute to development of metastatic forms of follicular thyroid carcinoma [19].

The aim of this study was to determine the prognostic significance of *FHIT* and *p53* genes alterations in thyroid lesions. To investigate whether the *FHIT* gene is important in thyroid tumor carcinogenesis, we screened the *FHIT* gene for alterations in different thyroid benign and malignant lesions. We also investigated mechanisms of *FHIT* gene inactivation and correlated our results with status of *p53*, and intensity of apoptosis.

Materials and methods

Patients and tissue specimens

Normal thyroid tissue, benign thyroid lesions (adenomatous goiter, follicular adenoma, thyroiditis, Graves disease and Hurtle adenoma) and malignant tumors (papillary, follicular, medullary and anaplastic carcinoma) were obtained from Department of Head and Neck Surgery, Hospital Ana Costa and Santa Casa da Misericordia and School of Medicine, Metropolitan University Santos, Brasil, from Clinical Hospital "Sestre milosrdnice", Zagreb, from General Hospital Slavonski Brod, from Clinical Hospital Center Zagreb, Department of Otorhinolaryngology and Head and Neck Surgery "Salata", Zagreb and from Croatian Tumor Bank [20]. All specimens were obtained during routine surgery. The tissue were snap frozen in liquid nitrogen shortly after surgical removal and stored at -80°C . A part of each frozen tumor sample was also embedded in paraffin. Sections of each paraffin block were stained with hematoxylin and eosin to confirm the exact tissue analyzed. The study included 62 men and 213 women with age range between 18 and 72 years (mean age, 48.8 years).

Immunohistochemical analysis

Immunohistochemical detection of FHIT was done using the anti-FHIT rabbit polyclonal antibody (1:80 dilution; Zymed, USA). The endogenous peroxidase activity was quenched by methanol containing 3% hydrogen peroxide (Sigma, Taufkirchen, Germany). Nonspecific binding was blocked by applying normal rabbit serum in a humidity chamber at a dilution of 1:10 for 30 min. Primary rabbit anti-FHIT antibody was applied overnight at 4°C . The secondary antibody (goat to mouse

immunoglobulins, DAKO, Denmark) was applied for 1 hour at room temperature. Peroxidase-antiperoxidase (PAP rabbit, DAKO) conjugate diluted 1:100 in phosphate-buffered saline (PBS) was applied for 45 min at room temperature. The slides were stained with diaminobenzidine tetrahydrochloride (DAB, Sigma) and then counterstained with hematoxylin.

Control staining was performed by omitting the primary antibody. As positive control in immunohistochemical studies, we used paraffin slides of the lung cancer positive for FHIT protein.

The localization and level of specific immunostaining for each slide was evaluated in the whole tumor area. The relative level of specific immunostaining and its localization were judged. The relative intensity of cell immunostaining was evaluated semiquantitatively, so that no staining was denoted (0), weak staining was denoted (1), moderate (2), and strong (3). Each sample was assessed independently by two observers. There was a 95 % initial agreement between them.

Loss of heterozygosity analysis

Tumor DNAs were extracted from frozen tumor tissue obtained during routine surgery of patients with thyroid gland lesions and stored at -80°C . All tumor specimens were examined by routine hematoxylin-eosin staining to determine the proportion of tumor cells in the sample (it had to be more than 80%). Control normal DNA was extracted from peripheral blood of patients. Frozen-tissue and blood DNA extraction was performed using proteinase K digestion and phenol chloroform extraction.

To analyze LOH at the *FHIT* gene locus, we used D3S1300 dinucleotide repeat and D3S4103 trinucleotide repeat and VNTR analysis as it was described

previously [15]. LOH at the *p53* gene locus was also analyzed by VNTR analysis and highly informative exogenic (CA)_n repeat as it was previously described [21].

LOH was defined by visible change in allele:allele ratio in tumors compared with matching normal tissue. Allelic deletion of FHIT was judged by a positive LOH at any of the two sites.

p53 mutations analysis

p53 gene mutations analysis was performed by SSCP analysis of all *p53* gene exons. Mutations were detected by direct sequencing of the relevant genomic DNA fragments with aberrant profile in SSCP analysis using CircumVent™ Thermal Cycle dideoxy DNA sequencing kit (New England Biolabs) according to the manufacturer's instructions. Mutations were additionally confirmed using fluorescence-based dideoxy sequencing on Applied Biosystems Model 373A automated sequencer.

RNA extraction and reverse transcription

Total RNA from tissues was extracted using RNeasy™ reagent (Qiagen, Crawley, UK) according to manufacturer's protocol. Recovered RNA was assayed by a 260/280 nm ratio.

The RT-PCR reaction was performed in a total volume of 40 µl. Total RNA (10 µg), 0.4 mM oligo (dT)₁₈ (New England Biolabs), and QH₂O up to 24 µl were prepared. After incubation for 10 min at 70°C the mixture was quickly cooled on ice and 16 µl of RT reaction mixture containing 8 µl of 5 x First strand buffer (Invitrogen)(250 mM Tris HCl pH 8.3, 375 mM KCl, 15 mM MgCl₂), 4 µl of 0.1M DTT (Invitrogen), 2 µl 10 mM deoxynucleotide mixture (dATP, dTTP, dCTP and

dGTP, 10 mM each)(Roche), 2 μ l of Rnase inhibitor (40 U/ μ l)(Roche) was added. The reaction proceeded in GeneAmp 2400 (Applied Biosystems) at 45°C for 2 min. Followed by the addition of 400 units of SuperScriptTMRnaseH- reverse transcriptase (200 U/ μ l)(Invitrogen), the reaction was incubated at 45°C for 60 min. The reaction was inactivated at 70°C for 15 min and at 94°C for 3 min. The cDNA was used as a template in the following PCR reactions.

***FHIT* gene expression analysis**

The *FHIT* gene expression analysis was performed by nested RT-PCR method as it was described previously [15]. Half of microliter of cDNA was used for PCR amplifications with primers 5U2 and 3D2 from *FHIT* exons 1 and 10, respectively. Amplification was carried out in 25 μ l volume. The PCR mixture consisted of 0.5 μ l of cDNA, 2.5 μ l of 10xPCR buffer II (Applied Biosystems), 1.5 mM of MgCl₂, 50 μ M of each dNTP, 5 pmol of each specific primer, and 1U of *Taq* DNA polymerase (Applied Biosystems). The PCR consisted of an initial denaturation step at 95°C for 5 min, followed by 45 cycles of 30 sec at 96°C, 30 sec at 56°C, and 45 sec at 72°C. Final extension lasted 10 min. Two microliters of first PCR products were used for nested PCR amplifications with primers 5U1 and 3D1 from *FHIT* exons 3 and 10, respectively. The PCR products were resolved by agarose gel electrophoresis (1.5% agarose stained with 0.5 μ g/ml ethidium bromide). RT-PCR products were directly sequenced after isolation of bands from low melting agarose and purification on columns. The sequencing of aberrant PCR products was performed as described previously [22].

Analysis of apoptosis

FACScan analysis of apoptosis was performed according to the procedure of Sard et al. [23]. Two million cells per sample were fixed with 2% paraformaldehyde in PBS, washed twice with TBS (50 mM Tris-HCl in saline solution), and permeabilized for 1 min with ice cold acetone. Staining was performed by incubating cells for 1 hr at 37⁰ C in 25 µl of TUNEL reaction mixture – *In Situ* Cell Death Detection Kit (Roche, Germany). Samples were analyzed by FACScan (Becton Dickinson, Erembodegem-Aalst, Belgium).

Cultivation of primary carcinoma cells

Surgical specimens were collected into sterile vessels containing RPMI 1640 medium with 10% heat inactivated fetal calf serum and 5% human serum. Informed consent was obtained from all patients from whom surgical specimens were obtained. Tumor tissue, without necrosis, was mechanically disrupted, placed into medium, cut into small pieces and pressed through a nylon sieve. Cells were introduced into T-75 flasks with RPMI 1640 medium supplemented with 9% fetal calf serum (FCS), 1% calf serum and 5% human serum, 2 mM L-glutamine and 20 mM HEPES. Tumor cell cultures were maintained as monolayers. The initial inoculum was about 1.8×10^5 cells per T-75 flask, and cells were cultivated in RPMI 1640 medium supplemented with transferrin (5 µg/ml), selenic acid (5 ng/ml) and HEPES (20 mM). Cells were store frozen (2×10^6 cells/ampule) in liquid nitrogen with 70% medium, 20% FCS and 10% DMSO. Two primary cultures of follicular carcinoma were established. One cell line was *p53⁻/FHIT⁻* and another was *p53⁺/FHIT⁺*. Both cell lines were inoculated into nude mice.

Tumorigenicity in nude mice

Follicular thyroid carcinoma cells from primary culture were inoculated s.c. into dorsal region of 4 seven week old nude mice. The tumor volume for each mouse was determined by measuring in two directions and calculated as tumor volume = length x (width)²/2.

Statistical analysis

Descriptive statistics are presented as mean \pm standard deviation. For ordinary data, descriptive statistics are presented with median and percentiles or as percentages. The table was analyzed with Fisher's exact test. Box-Whisker plots were generated in the basic module of the program Statistica. The correlation between apoptosis and *FHIT* gene status was analyzed with the Wilcoxon rank-sum test.

Results

FHIT protein expression in thyroid lesions

Three hundred and five samples of normal thyroid tissue (30 samples), benign (41 samples of adenomatous goiter, 28 of follicular adenoma, 30 of thyroiditis, 27 of Graves disease and 25 of Hürtle adenoma) and malignant (45 samples of papillary carcinoma, 40 of follicular carcinoma, 28 of medullar carcinoma and 11 of anaplastic carcinoma) thyroid lesions were examined for the presence of FHIT protein (Table 1). The observed staining pattern was essentially identical in all positive lesions and was represented by the weak to strong cytoplasmic staining of normal or tumor cells (Figure 1A, 1B, 1C and 1D).

Of 30 normal thyroid tissue that were examined 29 (96%) were positive for FHIT protein and the majority of samples 23 (76%) showed a moderate expression of FHIT protein. Only 6 (20%) samples of normal thyroid tissue showed a strong expression of FHIT protein (Figure 1A) and one sample was negative.

FHIT protein expression was more frequent in benignant than in malignant thyroid lesions. Of 151 benign thyroid lesions that were examined, 142 (94 %) were positive for FHIT protein and 66 (44 %) showed a moderate expression of FHIT protein (Figure 1B). The majority of adenomatous goiter (41%), follicular adenoma (53%), Graves disease (48%) and Hürtle adenoma (44%) samples showed a moderate FHIT protein expression. Only in thyroiditis majority of samples (64%) showed strong immunohistochemical staining of FHIT protein (Table 1).

On the contrary, the most malignant thyroid lesions were negative for FHIT protein, 59 (48 %) of 124 examined. The majority of follicular carcinoma (50%), medullary carcinoma (68%), anaplastic carcinoma (73%) samples showed a negative

FHIT protein expression. Only in papillary carcinoma majority of samples (44%) showed strong immunohistochemical staining of FHIT protein (Table 1)(Figure 1C and 1D).

Loss of heterozygosity

One hundred sixty and five samples of benign (30 samples of adenomatous goiter, 20 of follicular adenoma, 20 of thyroiditis, 22 of Graves disease and 19 of Hürtle adenoma) and malignant (11 samples of papillary carcinoma, 17 of follicular carcinoma, 15 of medullary carcinoma and 11 of anaplastic carcinoma) thyroid lesions were examined for the loss of heterozygosity (LOH) at the *FHIT* and *p53* genes loci (Table 2, 3 and 4).

To analyze LOH at the *FHIT* gene we used two microsatellite markers within the *FHIT* gene, D3S1300 dinucleotide repeat and D3S4103 trinucleotide repeat. Normal DNA showed one (homozygous, not informative patients) or two (heterozygous, informative patients) bands at both microsatellite markers. Allelic deletion of *FHIT* was judged by a positive LOH at any of the two sites. The LOH of *FHIT* gene was more frequent in malignant than in benignant thyroid lesions. Of 111 benignant thyroid lesions analyzed, 103 (92.8%) were heterozygous for analyzed loci and only 4 (3.9%) demonstrated LOH of the *FHIT* gene (2 adenomatous goiter, 1 follicular adenoma and 1 Hürtle adenoma) (Table 2). Of 54 malignant thyroid tumors analyzed, 50 (92.6%) were heterozygous and 28 (56%) demonstrated LOH of the *FHIT* gene (Table 3 and 4). Figure 2. represents the example of *FHIT* gene LOH at D3S4103 locus.

To analyze LOH at the *p53* gene we used highly informative exogenic (CA)_n repeat. The LOH of *p53* gene was also more frequent in malignant than in benign

thyroid lesions. Of 111 benign thyroid lesions examined, 90 (81.1%) were heterozygous and only 1 Hürtle adenoma (1.1%) demonstrated LOH of the *p53* gene (Table 2). Of 54 malignant thyroid tumors analyzed, 44 (81.5%) were heterozygous and 18 (40.9%) demonstrated LOH of the *p53* gene (Table 3 and 4).

LOH of the *FHIT* gene was more frequent event in malignant thyroid tumors than *p53* gene LOH.

***FHIT* gene expression**

FHIT gene status was examined by RT-PCR analysis for the presence of aberrant *FHIT* transcripts (Tables 2-4). According to the results, tumor samples were divided into two categories: *FHIT* normal and *FHIT* aberrant (exon missing). The size of normal PCR product (normal *FHIT* gene status) was 814 bp, and the sizes of aberrant products were from 350-690 bp (Figure 3).

Of 111 benign thyroid lesions analyzed, in 4 (3.6 %) aberrant *FHIT* gene transcripts were found (Table 2). Of 54 malignant thyroid tumors analyzed, in 19 (35.2 %) aberrant *FHIT* gene transcripts were found (3 papillary carcinoma, 1 follicular carcinoma, 7 medullary carcinomas and 8 anaplastic carcinomas) (Table 3 and 4). Anaplastic carcinomas displayed mutations in *FHIT* gene in almost all cases. Deletions were found in 5 cases and insertions in 3 cases of anaplastic carcinomas. In 5 malignant tumors *FHIT* gene status was not analyzed (Table 4).

***FHIT* gene expression and apoptosis**

Results of *FHIT* gene expression in malignant thyroid tumors were correlated with the rate of apoptosis in the same tumors. The rate of apoptosis in tumors with normal *FHIT* transcript was between 35% and 68% (mean value 57.4%) and in

tumors with aberrant transcripts was between 6% and 28% (mean value 16.7%). There was statistically significant lower rate of apoptosis in tumors with aberrant *FHIT* transcripts ($p < 0.01$) (Figure 4).

***p53* gene mutation analysis**

Results of *p53* gene mutation analysis in benign lesions are summarized in Table 2. The majority of benign thyroid lesions do not display mutation in *p53* gene. Only one follicular adenoma showed point mutation at codon 237 (ATG>ATT) resulting in Met>Ile amino acid change.

Results of *p53* gene mutations analysis in malignant thyroid tumors are summarized in Tables 3 and 4 and Figure 4. Gene *p53* was mutated in one papillary carcinoma, single point mutation at codon 237 was present resulting in Met>Ile amino acid change, while second tumor showed LOH at *p53* locus. Both tumors displayed concomitant mutation in *FHIT* gene and had distant metastases. Mutations in *p53* locus were much more frequent event in two malignant forms of thyroid neoplasms: medullary and anaplastic carcinomas. Eight out of 15 medullary carcinomas harbored single point mutation or LOH. In two tumors CGA>TGA point mutation at codon 213 (Arg>Termination) was found and in one TGT>TAT mutation at codon 238 (Cys>Tyr).

Anaplastic carcinomas displayed mutations in *p53* gene in almost all cases. *p53* gene was mutated in 7 tumors (LOH in 2 cases and point mutations in 5 cases) (Table 4). The point mutation GTA>GAA at *p53* gene codon 193 (His>Leu) was found in one anaplastic carcinoma, but in extranodular metastasis of the same tumor another mutation, GGC>GGT at the *p53* gene codon 248, was found (Figure 5).

Anaplastic tumors which harbored mutations in both genes displayed relative low percentage of apoptosis but not statistically significant (Figure 6).

Tumorigenicity in nude mice

Nude mice were inoculated with 2×10^7 cells of primary cultures of two follicular carcinoma. Morphological, genetical and immunohistochemical characteristics are shown in Table 5. The molecular genetic changes in *p53/FHIT* tumor were: LOH and point mutation of *p53* gene at codon 234 (TAC>TGC resulting with aminoacid mutation Tyr>Cys), exon 5-8 missing together with LOH of *FHIT* gene and low rate of apoptosis (5%). In *p53⁺/FHIT⁺* tumour *p53* and *FHIT* genes were not mutated and apoptosis rate was much higher (39%). *p53/FHIT* tumors growth was much faster than *p53⁺/FHIT⁺* tumors and this difference was statistically significant ($p < 0.01$) (Figure 7) and mice survival rate was shorter.

Discussion

Our results showed that *FHIT* gene is disrupted in thyroid lesions and hence, loss of FHIT protein function, together with aberration of *p53* gene, increased tumor cell proliferation and low rate of apoptosis may be important in the development and/or progression of thyroid cancer. Recently we obtained similar results on head and neck squamous cell carcinomas [15]. We also found higher incidence of *p53* mutation and aberrant processing of *FHIT* mRNA in more advanced undifferentiated tumors (in metastatic papillary and follicular, medullary and particularly in anaplastic carcinomas).

The pattern of abnormal *FHIT* transcript in our present study as well as in Zou et al study [2] is similar to those reported in lung, breast and head and neck cancers [6,10,15,24]. The majority of aberrant *FHIT* transcripts lack exons 4-5, 5-7, 5-8 or 4-8. In addition we as well as Zou et al. described deletions (between exons 4 and 5) and insertions (replacing exons 5-8) [2]. Given that defective *FHIT* genes were found in both benign and malignant thyroid tumors, the inactivation of *FHIT* gene is likely to be an early event in the pathogenesis of some forms of thyroid neoplasms.

Truncated *FHIT* transcripts were observed frequently alongside full length transcripts. Sequence analysis of the truncated gene transcripts revealed mainly exon skipping and alternate RNA processing events. Generalized defect in transcription control and fidelity could have a significant effect on tumor progression, subtly altering transcription patterns of many genes simultaneously and potentially creating changes in cellular growth [17]. Our results strongly indicate that aberrant mRNA processing is more common in more advanced tumors, particularly in anaplastic carcinomas.

Aberrant expression of *FHIT* gene is related to cell proliferation and apoptosis [15]. Overexpression of the *FHIT* gene induces cell apoptosis and alters cell-cycle processes. The apoptotic cell population markedly increased, and cells accumulated in S-phase after *FHIT* transduction. Ji et al. [25] suggested that the *FHIT* gene, when delivered at high efficiency into HI2 199 lung cancer cells by a recombinant adenoviral vector, functions as a tumor suppressor gene both *in vitro* and *in vivo*. Sard et al. [23] transferred *FHIT* gene into lung cancer cell line H460 lacking *FHIT* protein expression. Gene transfer resulted in reversion of tumorigenicity. A significant inhibition of cell growth was observed in transfected cells, and again a high rate of apoptosis induced DNA strand breaks in stable clones. FACScan analysis showed an apoptotic rate of 44-47% compared with a 15% level in the control H460 cells. Our results support clinical relevance of transfection experiments. Observed growth inhibitory effect of *FHIT* re-expressing cells could be related to apoptosis and cell-cycle arrest and link the tumor-suppressor activity of FHIT protein to its proapoptotic function. A role of FHIT protein as a proapoptotic factor is in agreement with the structural and biochemical studies indicating that FHIT-Ap3A complex is the native FHIT form involved in cellular signaling and apoptosis in human tumors to a decrease in Ap3A level [26,27].

In our study results of *FHIT* gene expression in malignant thyroid tumors were correlated with the rate of apoptosis in the same tumors. The rate of apoptosis in tumors with normal FHIT transcript was between 35% and 68% (mean value 57.4%) and in tumors with aberrant transcripts was between 6% and 28% (mean value 16.7%). There was statistically significant lower rate of apoptosis in tumors with aberrant *FHIT* transcripts ($p < 0.01$).

The inactivation of tumor suppressor genes is considered to be a critical event in the multi-step genetic process leading to the development of most cancers [28,29]. Loss of heterozygosity in *FHIT* locus is relatively frequent event in thyroid cancer as one of the mechanisms for inactivation in this gene. Several authors have investigated the incidence of LOH in thyroid neoplasms [30,31]. Zou found the highest incidence of LOH in follicular carcinomas, with chromosome 2p and 3p the most frequently affected sites. Fine mapping of 3p showed LOH clustered in the telomeric region (3p21-ter) as well as at D3S1300 (3p14.2) where *FHIT* was located [2,32]. LOH in 3p.14.2 region is highly localized to the microsatellite marker D3S1300, which displayed LOH in 73% of informative cases, while neighbouring microsatellite markers (D3S1234, D3S1481, D3S1480) had much lower rates of LOH (14-44%). This suggests selective allelic deletion in the D3S1300 region [17].

LOH of *FHIT* gene has been associated with both benign and malignant thyroid lesions suggesting that *FHIT* aberration may be an early event in development of thyroid cancer [2,33], although some data do not support an association between *FHIT* loss and the stage, histological grade or outcome in human thyroid cancer. Our data suggest strong difference in the *FHIT* aberration between benign and malignant thyroid lesions. Benign lesions have much less incidence of *FHIT* loss in comparison to malignant. Follicular carcinomas in our study show relatively high incidence of LOH at *FHIT* loci.

There is considerable controversy concerning when *p53* mutations arise during thyroid tumor development [34-36]. The *p53* gene has been implicated as a tumor suppressor gene whose inactivation by mutation has been noted in a variety of human malignancies. Cultured cells harboring *p53* mutations are unable to grow when transplanted *in vivo* [37] suggesting that the timing of *p53* mutation is a crucial step in

tumor progression. Some data have shown that p53 affects proliferative capabilities of thyroid cells *in vitro* [38]. Loss of p53 function could lead to genome destabilization promoting development of additional mutations [5]. Alternatively, *p53* gene loss may lead to deregulation in apoptotic pathways, shifting the balance between the anti-apoptotic and pro-apoptotic signals.

Most data suggest that *p53* mutations are involved in the transformation of thyroid cells and thyroid tumor progression [18,32,38-41]. Mutation of the *p53* gene are associated with the most aggressive histologic types of thyroid tumors, such as undifferentiated carcinoma, and that the alterations of this gene represent a late genetic event in human thyroid carcinogenesis [32]. Our results as well as those of other authors show that *p53* mutations are mainly present in poorly differentiated tumors and almost exclusively in those papillary and follicular carcinomas with distant metastases. Inactivation of p53 may confer these neoplasms with aggressive properties, and further loss of differentiated functions. Fagin et al. [41] confirmed that in both anaplastic tumors and cell lines, examples of heterozygous and homozygous *p53* mutations were identified. Transition observed in all positive anaplastic thyroid carcinoma samples involved CpG mutation. Because the cytosine in the CpG dinucleotide on codon 273 has been found to be methylated *in vivo*, the high mutation rate at this site in anaplastic carcinoma could be due to deamination of the methylated cytosine and replacement by a thymine. Mutations in different locations of *p53* gene may have different biological consequences. Several mutations including that of codon 273, showed loss of transcriptional activity due to impairment of p53 binding to specific DNA recognition sequences [41,42]. Therefore this mutation may confere growth advantage to cells harboring mutations of oncogenes.

Both *p53* and *FHIT* tumor suppressor gene mutations have been found frequently in undifferentiated thyroid carcinomas [2,43,44], but infrequently in differentiated thyroid cancers [45] and more commonly in anaplastic and poorly differentiated tumors [46]. Asakawa and Kobayashi [47] think that subsequent *p53* mutation may have caused the follicular neoplasm to transform to anaplastic carcinoma in some cases. Powell thinks that *FHIT* and *p53* gene loss may occur prior to loss of differentiated structures in advanced cancers. Thus as genes that control growth and apoptosis are mutated, the genotype of a given thyroid tumor may not reflect the observed phenotype, which may explain the misleading diagnosis associated with differentiated and poor thyroid outcome [48,49].

The mechanisms responsible for the transformation of normal thyroid cells into carcinoma are not well understood. To define the role of *RET*, *PTC3* and *p53* genes together with gene *FHIT* in thyroid cancerogenesis, Powell et al. [5] intercrossed *RET/PTC3* transgenics with *p53*^{-/-} mice. This new strain, *RET/PTC3*^{p53-/-} succumb to rapidly growing and large multilobed thyroid tumors containing mixtures of both well and poorly differentiated, highly proliferative follicular epithelial cells. Similarly, expression of *FHIT* protein was reduced in early tumors and undetected in older tumors irrespective of tumor histopathology [5]. The analysis of thyroid tumors that develop in *RET/PTC3*^{p53-/-} or *RET/PTC1+*^{p53-/-} mice [50] have revealed an important role of *p53* gene loss in the progression of differentiated thyroid cancer into an advanced poorly differentiated malignancy.

In our study, *p53*⁺/*FHIT*⁺ tumour *p53* and *FHIT* genes were not mutated and apoptosis rate was much higher (39%). *p53*⁻/*FHIT*⁻ tumors growth was much faster in nude mice than *p53*⁺/*FHIT*⁺ tumors and this difference was statistically significant ($p < 0.01$) and mice survival rate was shorter.

In conclusion, our results show a correlation between aberrant *FHIT* and *p53* expression, low rate of apoptosis, and malignancy. Our results support the hypothesis that *FHIT* gene alteration is involved in development of thyroid gland lesions and that aberrant *FHIT* and *p53* genes could be a prognostic marker in highly malignant thyroid lesions.

Acknowledgements

We thank following pathologists for help with the pathological classification of tumor samples: Angelo Sementilli and Fabio R. Lima from the Hospital Ana Costa, Santos, Leda V. Carvalho from the Hospital Santa Casa da Misericordia, Santos and Walter P.G. Decker from the Casa de Saude de Santos.

References

1. N.R. Farid, Y. Shi, M.J. Zou, Molecular basis of thyroid cancer, *Endocr Rev.* 15 (1994) 202-232.
2. M. Zou, Y. Shi, N.R. Farid, S.T. Al-Sedairy, M.C. Paterson, FHIT gene abnormalities in both benign and malignant thyroid tumours, *Eur J Cancer* 35 (1999) 467-472.
3. M. Sobrinho-Simoes, A. Preto, A.S. Rocha, P. Castro, V. Maximo, E. Fonseca, P. Soares, Molecular pathology of well-differentiated thyroid carcinomas, *Virchows Arch* September 28th 2005 1-7 *on line*
4. T. Mizuno, S. Kyoizumi, T. Suzuki, K.S. Iwamoto, T. Seyama, Continued expression of a tissue specific activated oncogene in the early steps of radiation-induced human thyroid carcinogenesis, *Oncogene* 15 (1997) 1455-1460.
5. D. Jr Powell, J.P. Russell, G. Li, B.A. Kuo, V. Fidanza, K. Huebner, J.L. Rothstein, Altered gene expression in immunogenic poorly differentiated thyroid carcinomas from RET/PTC3^{p53^{-/-}} mice, *Oncogene* 20 (2001) 3235-3246.
6. G. Sozzi, M.L. Veronese, M. Negrini, R. Baffa, M.G. Cotticelli, H. Inoue, S. Tornielli, S. Pilotti, L. DeGregorio, U. Pastorino, M.A. Pierotti, M. Ohta, The FHIT gene at 3p14.2 is abnormal in lung cancer, *Cell* 85 (1996) 17-26.
7. K. Kastury, R. Baffa, T. Druck, M. Ohta, M.G. Cotticelli, H. Inoue, M. Negrini, M. Ruge, D. Huang, C.M. Croce, J. Palazzo, K. Huebner, Potential gastrointestinal tumor suppressor locus at the 3p14.2 FRA3B site identified by homozygous deletions in tumor cell lines, *Cancer Res.* 56 (1996) 978-983.
8. M. Ohta, H. Inoue, M.G. Cotticelli, Y. Kastury, R. Baffa, J. Palazzo, Z. Siprasvili, M. Mori, P. McCue, T. Druck, The human FHIT gene, spanning the chromosome 3p14.2 fragile site and renal carcinoma-associated T(3;8) breakpoint, is abnormal in digestive tract cancers, *Cell* 84 (1996) 587-597.
9. S. Zöchbauer-Müller, K.M. Fong, A. Maitra, S. Lam, J. Geradts, R. Ashfaq, A.K. Virmani, S. Milchgrub, A.F. Gazdar, J.D. Minna. 5' CpG island methylation of the FHIT gene is correlated with loss gene expression in lung and breast cancer, *Cancer Res* 61 (2001) 3581-3585.

10. M. Negrini, C. Monaco, I. Vorechovsky, M. Ohta, T. Druck, R. Baffa, K. Huebner, C.M. Croce, The FHIT gene at 3p14.2 is abnormal in breast carcinomas, *Cancer Res.* 56 (1996) 3173-179.
11. K.M. Fong, E.J. Biesterveld, A. Virmani, I. Wistuba, Y. Sekido, S.A. Bader, M. Ahmadian, S.T. Ong, F.V. Rassool, P.V. Zimmerman, G. Giaccone, A.F. Gazdar, FHIT and FRA3B 3p14.2 allele loss are common in lung cancer and preneoplastic bronchial lesions and are associated with cancer-related FHIT cDNA splicing aberrations, *Cancer Res.* 57 (1997) 2256-2267.
12. I.I. Wistuba, C. Behrens, A.K. Virmani, G. Mele, S. Milchgrub, L. Girarg, J.W. Fondon, H. Garner, B. McKay, F. Latif, M.I. Lerman, S. Lam, High resolution chromosome 3p allelotyping of human lung cancer and preneoplastic/preinvasive bronchial epithelium reveals multiple, discontinuous sites of 3p allele loss and three regions of frequent breakpoints, *Cancer Res.* 60 (2000) 1949-1960.
13. G. Sozzi, L. Sard, L. De Gregorio, A. Marchetti, K. Musso, F. Buttitta, S. Tornielli, S. Pellegrini, M.L. Veronese, G. Manenti, M. Incarbone, A. Chella, Association between cigarette smoking and FHIT gene alterations in lung cancer, *Cancer Res.* 57 (1997) 2121-2123.
14. M. Campiglio, Y. Pekarsky, S. Menard, E. Tagliabue, S. Pilotti, C.M. Croce, FHIT loss of function in human primary breast cancer correlates with advanced stage of the disease, *Cancer Res.* 59 (1999) 3866-3869.
15. K. Pavelić, Š. Križanac, T. Čačev, M. Popović Hadžija, S. Radošević, I. Crnić, S. Levanat, S. Kapitanović, Aberration of FHIT gene is associated with increased tumor proliferation and decreased apoptosis - clinical evidence in lung and head and neck carcinomas, *Molecular Med.* 7(2001) 442-453.
16. Z. Siprashvili, G. Sozzi, L.D. Barnes, P. McCue, A.K. Robinson, V. Eryomin, L. Sard, E. Tagliabue, A. Greco, L. Fusetti, G. Schwartz, M.A. Pierotti, Replacement of FHIT in cancer cells suppresses tumorigenicity, *Proc Natl Acad Sci USA* 94 (1997) 13771-13776.
17. B. McIver, S.K. Grebe, L. Wang, I.D. Hay, A. Yokomizo, W. Liu, J.R. Goellner, C.S. Grant, D.I. Smith, N.L. Eberhardt, FHIT and TSG101 in thyroid tumours: aberrant transcripts reflect rare abnormal RNA processing events of uncertain pathogenetic or clinical significance, *Clin Endocrinology* 52 (2000) 749-757.

18. M. Zou, Y. Shi, N.R. Farid, p53 mutations in all stages of thyroid carcinomas, *J Clin Endocrinol Metab.* 77 (1993) 1054-1058.
19. Z Sapi, G Lukacs, M Sztan, J Papp, E Olah. Contribution of p53 gene alterations to development of metastatic forms of follicular thyroid carcinoma, *Diagn Mol Pathol.* 4 (1995) 256-260.
20. R. Spaventi, L. Pečur, K. Pavelić, Z.P. Pavelić, Š. Spaventi, P.J. Stambrook, Human tumor bank in Croatia: a possible model for a small bank as a part of the future European tumor bank network, *Eur J Cancer* 30A (1994) 419.
21. P. Berggren, G. Steineck, J. Adolfsson, J. Hansson, O. Jansson, P. Larsson, B. Sandstedt, H. Wijkstrom, K. Hemminki, P53 mutations in urinary bladder cancer, *Br J Cancer* 84 (2001) 1505-1511.
22. L. Virgilio, M. Shuster, S.M. Gollin, M.L. Veronese, M.Ohta, K. Huebner, C.M. Croce, FHIT gene alteration in head and neck squamous cell carcinomas, *Proc Natl Acad Sci USA* 93 (1996) 9770-9775.
23. L. Sard, P. Accornero, S. Torielli, D. Delia, G. Bunone, M. Campiglio, M.P. Colombo, M. Gramegna, C.M. Croce, M.A. Pierotti, G. Sozzi, The tumor-suppressor gene FHIT is involved in the regulation of apoptosis and in cell cycle control. *Proc Natl Acad Sci USA* 96(1996) 8489-8492.
24. R.H. Hruban, A.D.M. van Mansfeld, G.J.A. Offerhaus, D.M.J. van Weering, D.C. Allison, S.N. Goodman, T.W. Kensler, K.K. Bose, J.L. Cameron, J.L. Boss, K-ras oncogene activation in adenocarcinoma of the human pancreas. A study of 82 carcinomas using a combination of mutant enriched polymerase chain reaction analysis and allele-specific oligonucleotide hybridization, *Am J Pathol.* 143 (1993) 545-554.
25. L. Ji, B.L. Fang, N. Yen, K. Fong, J.D. Minna, J.A. Roth, Induction of apoptosis and inhibition of tumorigenicity and tumor growth by adenovirus vector-mediated fragile histidine triad (FHIT) gene overexpression, *Cancer Res.* 59 (1999) 3333-3339.
26. H.C. Pace, P.N. Garrison, A.K. Robinson, L.D. Barnes, A. Draganescu, A. Rosler, G.M. Blackburn, Z. Siprasvili, C.M. Croce, K. Huebner, C. Brenner, Genetic, biochemical, and crystallographic characterization of FHIT-substrate complexes as the active signalling from of FHIT, *Proc Natl Acad Sci USA* 95 (1998) 5484-5489.

27. L.L. Kisselev, J. Justesen, A.D. Wolfson, L.Y. Frolova, Diadenosine oligophosphates (AP(N)A), a novel class of signaling molecules? *FEBS Lett* 427(1998) 157-163.
28. A.G. Knudson, Antioncogenes and human cancer, *Proc Natl Acad Sci USA* 90 (1993)10914-10921.
29. R.A. Weinberg, Tumor suppressor genes, *Science* 254 (1991) 1138-1146.
30. K. Tanimoto, S. Hayashi, E. Tsuchiya, Y. Tokuchi, Y. Kobayashi, K. Yoshiga, T. Okui, M. Kobayshi, T. Ichikawa, Abnormalities of the FHIT gene in human oral carcinogenesis, *Br J Cancer* 82 (2000) 838-843.
31. M.F. Denissenko, A. Pao, M. Tang, G.P. Pfeifer, Preferential formation of benzo(α)pyrene adducts at lung cancer mutational hotspots in p53, *Science* 274 (1996) 430-432.
32. R Donghi, A. Longoni, S. Pilotti, P. Michieli, G. Della Porta, M.A. Pierotti, Gene p53 mutations are restricted to poorly differentiated and undifferentiated carcinomas of the thyroid gland, *J Clin Invest.* 91 (1993) 1753-1760.
33. H.W. Chang, M. Aoki, D. Fruman, K.R. Auger, A. Bellacosa, P.N. Tsichlis, L.C. Cantley, T.M. Roberts, P.K. Vogt, Transformation of chicken cells by the gene encoding the catalytic subunit of PI 3-kinase, *Science* 276 (1997) 1848-1850.
34. P. Komminoth, The RET proto-oncogene in medullary and papillary thyroid carcinoma. Molecular features, patophysiology and clinical implications, *Virchows Archiv* 431(1997) 1-9.
35. G.Z. Qin, J.Y. Park, S.Y. Chen, P. Lazarus, A high prevalence of p53 mutations in premalignant oral erythroplakia, *Int J Cancer* 80 (1999) 345-348.
36. C. Soravia, S.L. Sugg, T. Berk, A. Mitri, H. Cheng, S. Gallinger, Z .Cohen, S.L. Asa, B.V. Bapat. Familial adenomatous polyposis-associated thyroid cancer: a clinical, pathological, and molecular genetic study, *Am J Pathol.* 154 (1999) 127-135.
37. S. Battista, M.L. Martelli, M. Fedele, G. Chiappetta, F. Trapasso, G. De Vita., C. Battaglia, M. Santoro, G. Viglietto, J.A. Fagin, A. Fusco, A mutated p53 gene alters thyroid cell differentiation, *Oncogene* 11 (1995) 2029-2037.
38. F. Moretti, A. Farsetti, S. Soddu, S. Misiti, M. Crescenzi, S. Filetti, M. Androli, A. Sacchi., A. Pontecorvi, p53 re-expression inhibits proliferation

- and restores differentiation of human thyroid anaplastic carcinoma cells, *Oncogene* 14 (1997) 729-740.
39. X. Matias-Guiu, M. Cuatrecasas, E. Musulen, J. Prat, p53 expression in anaplastic carcinomas arising from thyroid papillary carcinomas, *J Clin Pathol.* 47(1994) 337-339.
 40. S. Kikuchi, H. Hiraide, S. Tamakuma, M. Yamamoto, Expression of wild-type p53 tumor suppressor gene and its possible involvement in the apoptosis of thyroid tumors, *Surg Today* 27(1997) 226-233.
 41. J.A. Fagin, K. Matsuo, A. Karmakar, D.L. Chen, S.H. Tang, H.P. Koeffler, High prevalence of mutations of the p53 gene in poorly differentiated human thyroid carcinomas, *J Clin Invest.* 91 (1993) 179-184.
 42. S.E. Kern, J.A. Pietenpol, S. Thiagalingam, A. Seymour, K.W. Kinzler, B. Vogelstein, Oncogenic forms of p53 inhibit p53-regulated gene expression, *Science* 256 (1992) 827-830.
 43. T.J. Chang, T.C. Tsai, Y.L. Wu, H.M. Yang, C.W. Chi, A.H. Yang, C.H. Lee, Abnormal transcripts of FHIT gene in thyroid cancer, *Oncol Rep.* 5 (1998) 245-247.
 44. Q.Y. Duh, R.F. Grossman. Thyroid growth factors, signal transduction pathways, and oncogenes, *Surg Clin N Am.* 75 (1995) 421-437.
 45. S.K. Grebe, B. McIver, I.D. Hay, P.S. Wu, L.M. Maciel, H.A. Drabkin, J.R. Goellner, C.S. Grant, R.B. Jenkins, N.L. Eberhardt, Frequent loss of heterozygosity on chromosomes 3p and 17p without VHL or p53 mutations suggests involvement of unidentified tumor suppressor genes in follicular thyroid carcinoma, *J Clin Endocrinol Metab.* 1997;82:3684-691
 46. T. Ito, T. Seyama, T. Mizuno, N. Tsuyama, T. Hayashi, Y. Hayashi, K. Dohi, N. Namamura, M. Akiyama, Unique association of p53 mutations with undifferentiated but not with differentiated carcinomas of the thyroid gland. *Cancer Res.* 52 (1992) 1369-1371.
 47. H. Asakawa, T. Kobayashi, Multistep carcinogenesis in anaplastic thyroid carcinoma: a report, *Pathology* 34 (2002) 94-97.
 48. A. Arezzo, R. Patetta, P. Ceppa, G. Borgonovo, G. Torre, F.P. Mattioli, Mucoepidermoid carcinoma of the thyroid gland arising from a papillary epithelial neoplasm, *Am Surg.* 64 (1998) 307-311.

49. M.L. Carcangiu, T. Steeper, G. Zampi, J. Rosai, Anaplastic thyroid carcinoma. A study of 70 cases. *J Am Clin Pathol.* 83 (1985) 135-158.
50. K.M. La Perle, S.M. Jhiang, C.C. Capen, Loss of p53 promotes anaplasia and local invasion in ret/PTC1-induced thyroid carcinomas, *Am J Pathol.* 157 (2000) 671-677.

FIGURE LEGENDS

FIGURE 1. Immunohistochemical analysis of FHIT protein. A. Normal thyroid tissue, strong immunostaining (3); B. Adenomatous goiter, moderate immunostaining (2); C. Papillary carcinoma, weak immunostaining (1); D. Anaplastic carcinoma, negative immunostaining (0). Immunohistochemistry was performed on formalin-fixed, paraffin-embedded tissue specimens (magnifications: A i B, 250X; C i D, 1000X).

FIGURE 2. Loss of heterozygosity (LOH) analysis of D3S4103 polymorphic marker in thyroid cancer. M, DNA marker pBR322/*Msp*I; N, Normal tissue; T, Tumor tissue. 1, heterozygous sample with LOH; 2, 3, heterozygous sample without LOH.

FIGURE 3. Expression of the FHIT gene by nested RT-PCR.

Normal FHIT products in three adenomatous goiters (lines A1, A2 and B2) and one follicular adenoma (line B1), 706 bp. Aberrant FHIT products in two papillary carcinomas (lines A3 and A4), 360 bp, and two anaplastic carcinomas (lines B3 and B4), 620 bp.

FIGURE 4. Correlation between FHIT gene status and percent of apoptosis in tumor cells. There was statistically significant lower rate of apoptosis in tumors with aberrant *FHIT* transcripts ($p < 0.01$).

FIGURE 5. Direct sequencing of PCR products containing a *p53* gene mutations. A. The point mutation GTA>GAA at *p53* gene codon 193 (His>Leu) was found in one

anaplastic carcinoma, but in B. extranodular metastasis of the same tumor another mutation, GGC>GGT at the p53 gene codon 248, was found.

FIGURE 6. Percent of apoptosis in tumor cells in two groups of anaplastic carcinomas, *p53* MUT / *FHIT* MUT and *p53* WT / *FHIT* MUT.

FIGURE 7. Tumorigenicity of follicular thyroid carcinoma cells from primary culture. The *p53*⁻/*FHIT*⁻ cells or *p53*⁺/*FHIT*⁺ cells were injected s.c. into nude mice and tumor sizes and survival were measured. *p53*⁻/*FHIT*⁻ tumors growth was much faster than *p53*⁺/*FHIT*⁺ tumors and this difference was statistically significant (p<0.01).

TABLE 1. Expression of FHIT protein in benign and malignant thyroid lesions

Thyroid lesion (No. analyzed)	FHIT protein status – expression (%)			
	0 (negative)	1 (weak)	2 (moderate)	3 (strong)
BENIGNANT THYROID LESIONS				
Adenomatous goiter (41)	3 (7)	8 (20)	17 (41)	13 (32)
Follicular adenoma (28)	3 (11)	3 (11)	15 (53)	7 (25)
Thyroiditis (30)	0 (0)	1 (3)	10 (33)	19 (64)
Graves disease (27)	1 (4)	3 (11)	13 (48)	10 (37)
Hürtle adenoma (25)	2 (8)	2 (8)	11 (44)	10 (40)
MALIGNANT THYROID TUMORS				
Papillary carcinoma (45)	12 (27)	3 (7)	10 (22)	20 (44)
Follicular carcinoma (40)	20 (50)	3 (8)	6 (15)	11 (27)
Medullary carcinoma (28)	19 (68)	2 (7)	1 (4)	6 (21)
Anaplastic carcinoma (11)	8 (73)	3 (27)	0 (0)	0 (0)

TABLE 2. Status of genes *FHIT* and *p53* in benignant thyroid lesions

BENIGNANT THYROID LESIONS	<i>FHIT</i> gene status	<i>p53</i> gene status
(No. analyzed)	N/EM/LOH	WT/Point mutation/LOH
Adenomatous goiter (30)		
27/30 (90%)	N	WT
1/30 (3%)	EM 8	WT
2/30 (7%)	LOH	WT
Follicular adenoma (20)		
18/20 (90%)	N	WT
1/20 (5%)	EM 5-7	ATG>ATT, Met> Ile (codon 237)
1/20 (5%)	LOH	WT
Thyroiditis (20)		
20/20 (100%)	N	WT
Graves disease (22)		
21/22 (95%)	N	WT
1/22 (5%)	EM 8	WT
Hürtle adenoma (19)		
17/19 (90%)	N	WT
1/19 (5%)	N	LOH
1/19 (5%)	EM 5-7 + LOH	WT

N – Normal transcript; EM – exon missing; LOH – loss of heterozygosity; WT – wild type

TABLE 3. Status of genes FHIT and p53 in malignant thyroid tumors

Thyroid tumor (No. analyzed)		<i>FHIT</i> gene status	<i>p53</i> gene status
Patient No.	TNM	N/EM/LOH	WT/Point mutation/LOH
Papillary carcinoma (11)			
1	T ₄ N _{1a} M ₀	LOH	ND
2	T ₂ N ₀ M ₀	LOH	ND
3	T ₁ N ₀ M ₀	N	WT
4	T ₄ N ₀ M ₁	EM 8	ATG>ATT, Met>Ile (codon 237)
5	T ₂ N ₀ M ₁	EM 5-7 + LOH	LOH
6	T ₁ N _{1a} M ₀	EM 8 + LOH	WT
7	T ₂ N ₀ M ₀	N	WT
8	T ₂ N ₀ M ₀	LOH	WT
9	T ₂ N ₀ M ₀	LOH	ND
10	T ₂ N ₀ M ₁	LOH	LOH
11	T ₄ N _{1a} M ₀	LOH	LOH
Follicular carcinoma (17)			
1	T ₃ N ₀ M ₁	LOH	ND
2	T ₂ N ₀ M ₀	LOH	ND
3	T ₂ N ₀ M ₀	EM 5-7 + LOH	ND
4	T ₃ N ₁ M ₀	N	WT
5	T ₂ N ₀ M ₁	N	LOH
6	T ₃ N ₀ M ₁	LOH	LOH
7	T ₂ N ₀ M ₀	LOH	WT
8	T ₂ N ₀ M ₀	N	WT
9	T ₃ N ₀ M ₁	LOH	LOH
10	T ₂ N ₀ M ₀	ND	LOH
11	T ₂ N ₀ M ₀	ND	WT
12	T ₂ N ₀ M ₀	LOH	ND
13	T ₂ N ₀ M ₁	N	LOH

14	T ₃ N ₀ M ₁	N	LOH
15	T ₂ N ₀ M ₁	N	LOH
16	T ₂ N ₀ M ₀	LOH	ND
17	T ₂ N ₀ M ₀	LOH	WT
Medullary carcinoma (15)			
1	T ₂ N _{1a} M ₀	LOH	ND
2	T ₂ N _{1a} M ₀	LOH	ND
3	T ₃ N _{1a} M ₁	N	TGT>TAT, Cys>Tyr (codon 238)
4	T ₂ N _{1a} M ₁	EM 8	LOH
5	T ₂ N ₀ M ₁	N	CGA>TGA, Arg>Term (codon 213)
6	T ₂ N _{1a} M ₁	EM 4-8	LOH
7	T ₃ N _{1a} M ₀	EM 4-8 + LOH	WT
8	T ₃ N _{1a} M ₀	72 bp insertion	WT
9	T ₂ N _{1a} M ₀	EM 5-7 + LOH	WT
10	T ₃ N _{1a} M ₁	N	CGA>TGA, Arg>Term (codon 213)
11	T ₂ N _{1a} M ₀	LOH	LOH
12	T ₃ N _{1a} M ₁	EM 8	LOH
13	T ₂ N ₀ M ₁	EM 4-8 + LOH	WT
14	T ₃ N _{1a} M ₀	N	WT
15	T ₂ N _{1a} M ₁	N	LOH

N – Normal transcript; EM – exon missing; LOH – loss of heterozygosity; WT – wild type; ND – not determined

Table 4. Status of genes *FHIT* and *p53*, FHIT protein expression, apoptosis and survival in anaplastic carcinomas

Patients	<i>FHIT</i> gene status	FHIT protein expression	<i>p53</i> gene status	Apoptosis	Survival
No.	N/EM/LOH	0 (neg), 1 (weak)	WT/Point mutation/LOH	%	months
1	29 bp deletion + LOH	0	LOH	10	< 10
2	839 bp deletion + LOH	0	LOH	16	< 10
3	85 bp deletion	0	¹ GTA>GAA, His>Leu (codon 193) ² GGC>GGT (codon 248)	7	6
4	ND	1	CGT>CAT, Arg>His (codon 273)	4	10
5	180 bp deletion	0	GGC>GGT (codon 248)	ND	7
6	ND	1	WT	28	12
7	72 bp insertion + LOH	0	CGC>CCC, Arg>Pro (codon 238)	35	10
8	180 bp deletion	0	WT	5	< 10
9	9 bp insertion + LOH	1	WT	31	18
10	839 bp insertion	0	CCT>TCT, Pro>Ger (codon 141)	22	12
11	ND	0	WT	18	10

N – Normal transcript; EM – exon missing; LOH – loss of heterozygosity; WT – wild type; ¹ primary anaplastic carcinoma; ² extranodular metastasis

Table 5. Properties of two established thyroid cancer primary cell cultures

Type of cell culture	Morphology	Doubling time (h)	Immunohistochemistry marker (positive)	Cytogenetics	p53	FHIT	Apoptosis (%)	Growth in nude mice
Follicular carcinoma	polygonal flat-to-spindle-like growing adherently as monolayer	24	cytokeratin neurofilament vimentin	complex chromosomal changes	Mutation at codon 234 (TAC→TGC), LOH	EM 5-8 LOH	5	+ fast
Follicular carcinoma	polygonal flat growing adherently as monolayer	36	cytokeratin vimentin desmin neurofilament	near diploid karyotype with hexaploid sideline	wilde type	wilde type	39	+ slow

Figure 1.

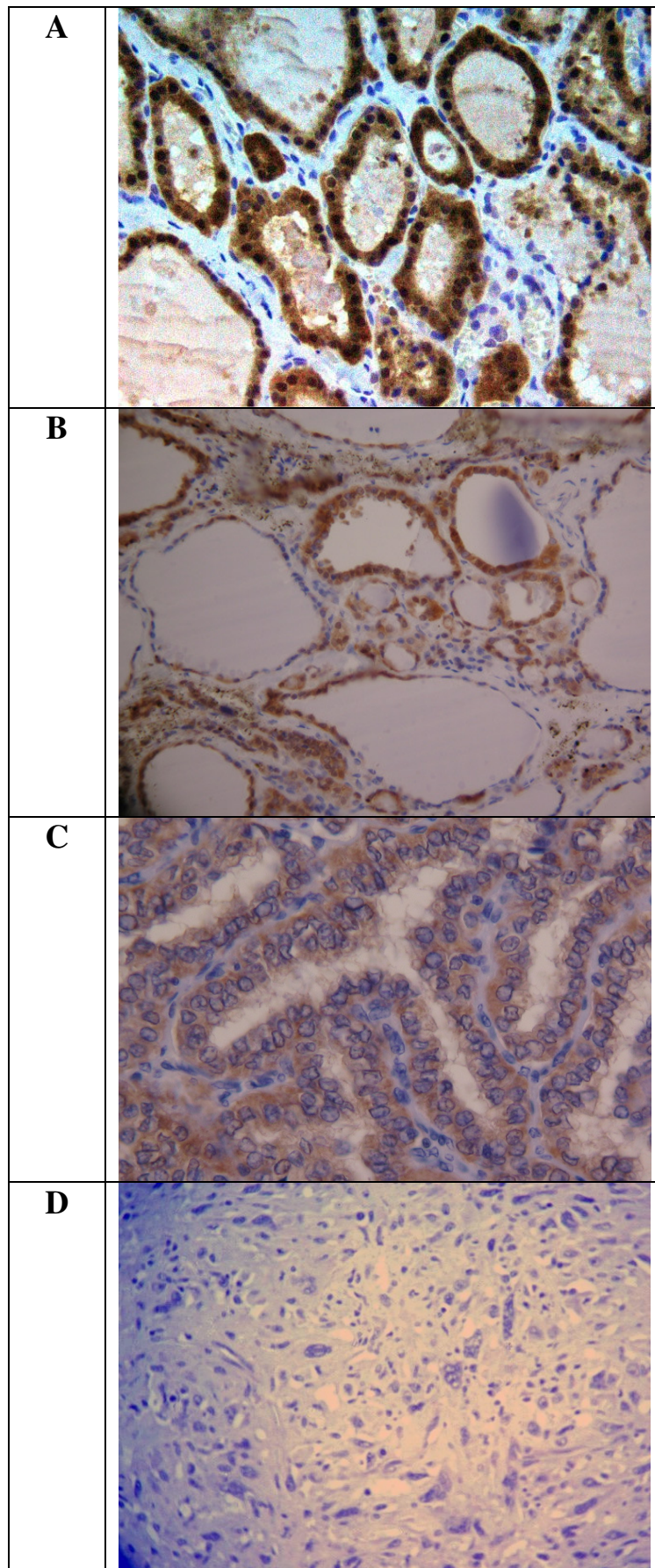


Figure 2.

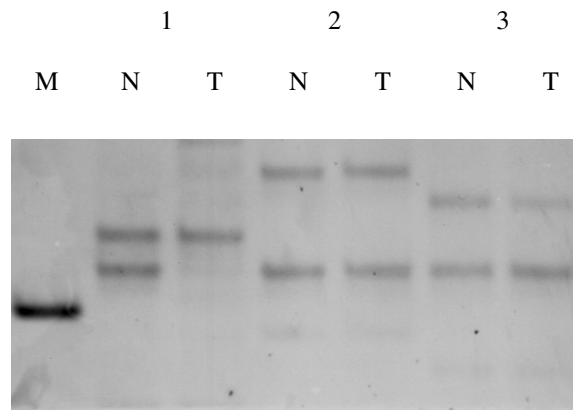


Figure 3. Expression of the FHIT gene by nested RT-PCR.

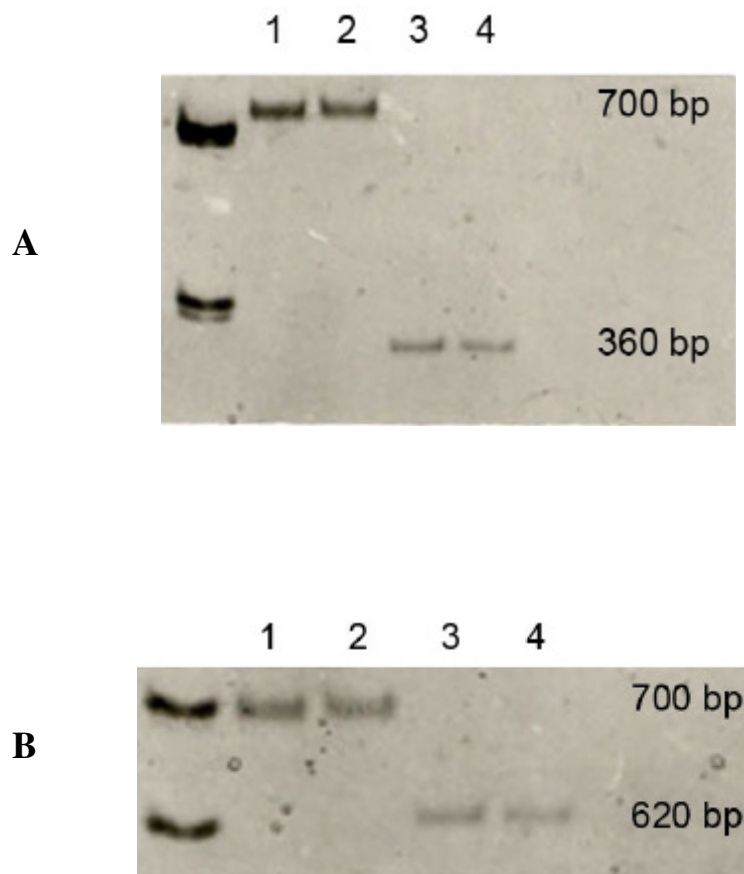


Figure 4.

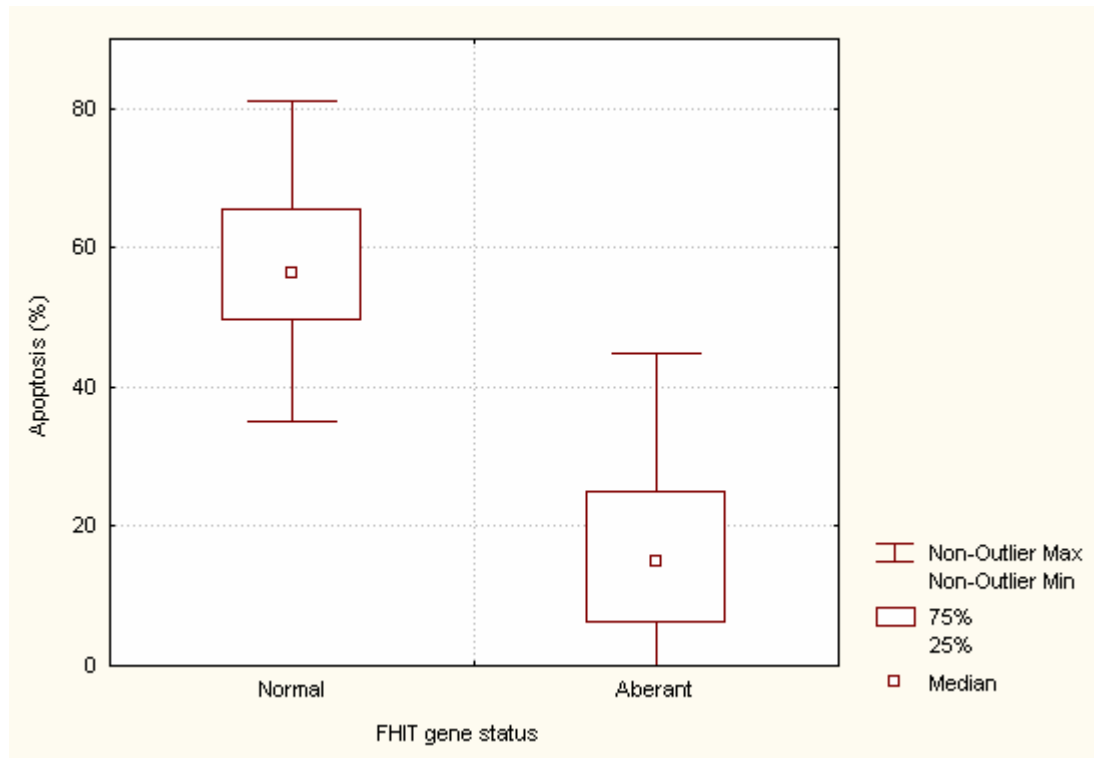
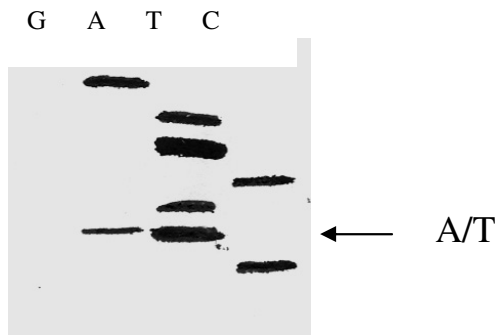


Figure 5.

A. Primary anaplastic carcinoma



B. Extranodular metastasis

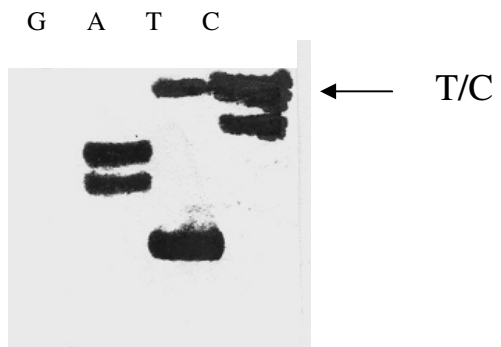


Figure 6.

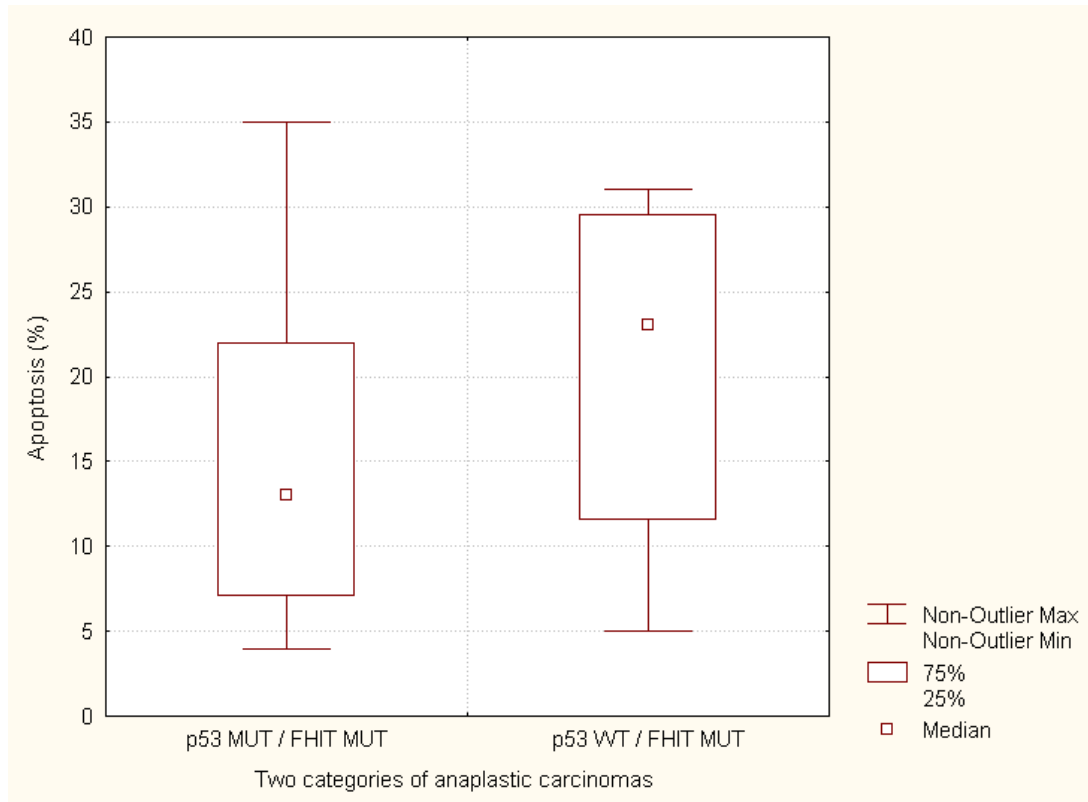


Figure 7.

