

Case Report

Usefulness of ultrasound in the diagnosis of peritoneal tuberculosis

Sebastiana Atzori, Gianpaolo Vidili, Giuseppe Delitala

Department of Clinical and Experimental Medicine, University of Sassari, Azienda Ospedaliero Universitaria, Sassari, Italy

Abstract

The peritoneum is one of the most common extrapulmonary sites of tuberculous infection. We report a case of peritoneal tuberculosis (TB) in a 25-year-old man. In this case, ultrasound of the abdomen played an important role in the diagnostic process. The diagnosis of this disease, however, remains a challenge because of its insidious nature, the variability of its presentation, and the limitations of available diagnostic tests. A high index of suspicion should be considered, particularly in high-risk patients with unexplained ascites. In our case ultrasound guided the diagnosis by rapidly identifying abnormal signs, which in high-prevalence settings are extremely suggestive of peritoneal tuberculosis.

Key words: abdominal tuberculosis; peritoneal tuberculosis; ultrasound in infectious diseases

J Infect Dev Ctries 2012; 6(12):886-890.

(Received 20 March 2012 – Accepted 30 July 2012)

Copyright © 2012 Atzori *et al.* This is an open-access article distributed under the Creative Commons Attribution License, which permits unrestricted use, distribution, and reproduction in any medium, provided the original work is properly cited.

Introduction

The peritoneum and its reflections are common sites of tuberculous involvement of the abdomen. Peritoneal tuberculosis (PTB) shows a bimodal distribution: it is most likely due to secondary hematogenous spread from latent tuberculous foci in middle-aged white patients, and shows a higher incidence in a young, non-white and immunocompetent population without any involvement of other tuberculous foci [1]. This case aims to illustrate the challenge of diagnosing peritoneal tuberculosis and the usefulness of ultrasonography (US) in visualizing signs of chronic peritonitis, orienting the diagnosis, and in the monitoring therapy.

Case report

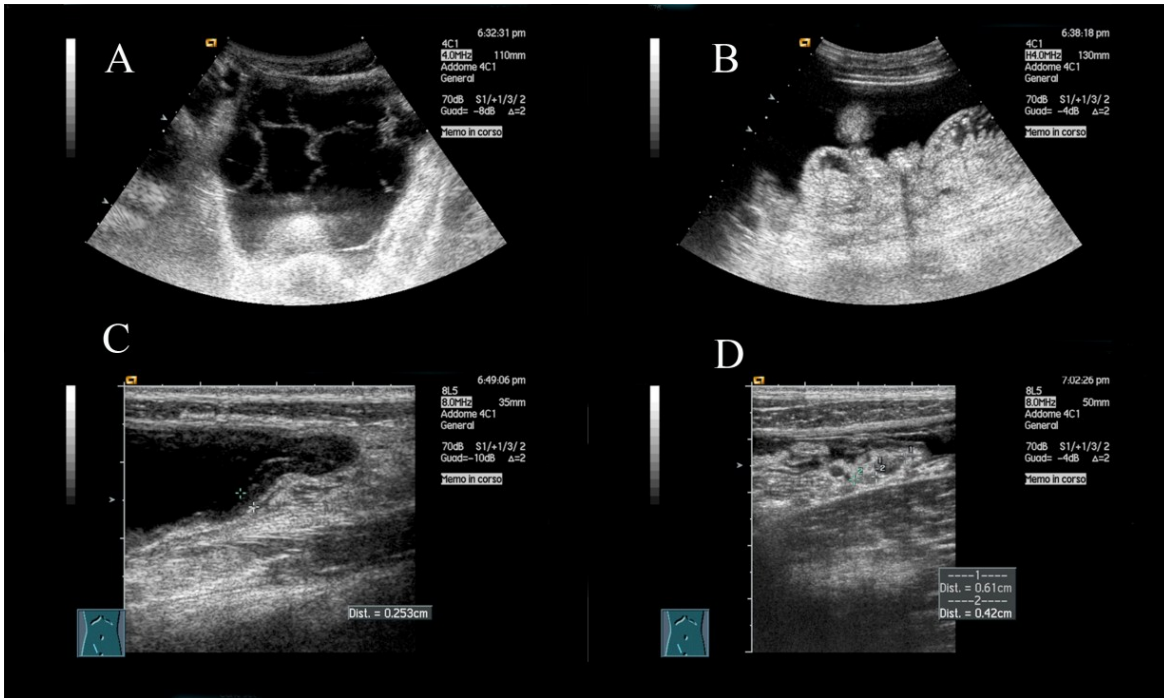
A 25-year-old man was admitted to our department with constant abdominal pain, fever up to 39°C, and nausea. The patient was born in Senegal but had come to Italy ten years before admission; thereafter he visited Dakar annually. He complained of a vague abdominal discomfort associated with nausea but not vomiting, non-productive cough, and decreased appetite since he had been to Dakar the month before admission. Two weeks before admission he had developed intermittent fever, with temperatures up to

37.7°C. One day before admission, pain in the lower quadrant developed and his temperature rose to 39.1°C.

The patient had no known co-morbidities, no history of hospitalization, and no alteration in bowel habit. Physical examination revealed tenderness in the lower quadrant of the abdomen. There was no sign of lymphadenopathies and the rest of the physical examination was unremarkable. Routine laboratory data showed hemoglobin at 10 g/dl and normal leucocyte count, platelets, electrolyte, renal and liver function tests. Urinalysis revealed leukocytes (100 white cells per high-power field), and a urine culture grew coagulase-negative *Staphylococcus*; blood cultures were sterile. Ciprofloxacin and pantoprazole were administered. Abdominal X ray showed a few dilated loops of bowel with some air fluid level. Chest X ray was normal.

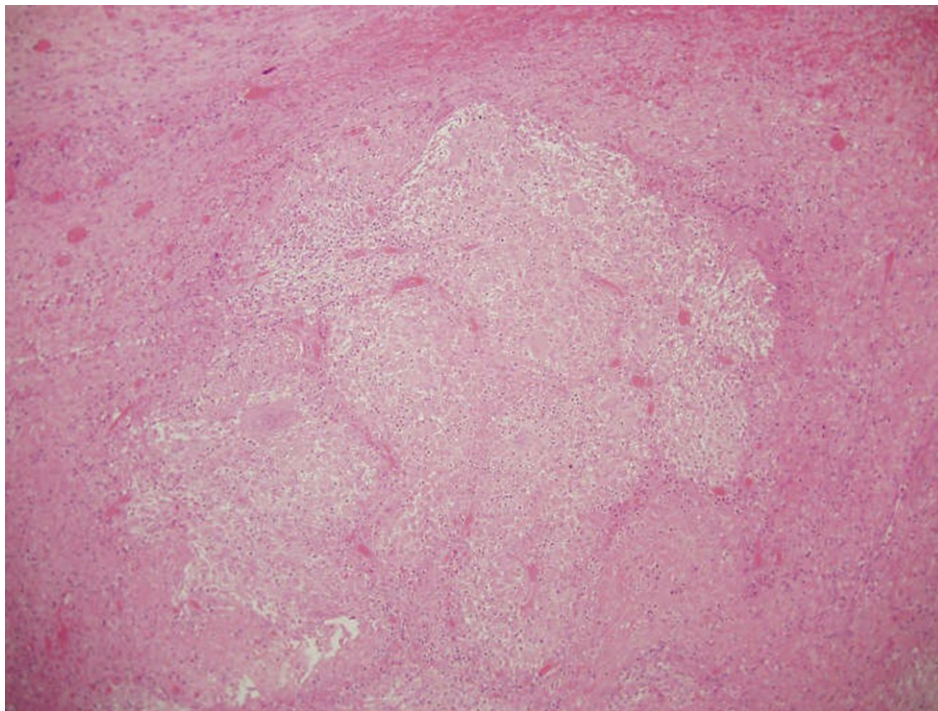
Ultrasound examination of the abdomen (Acuson Sequoia 512, 4C1 and 8L5 probes, Siemens, Mountain View, California, USA) showed the presence of interloop ascitic fluid with septations, thickening of the abdominal wall and the visceral peritoneum of the mesentery, increased echogenicity of mesenteric fat, conglomerated loops and enlarged lymph nodes in the small bowel mesentery (Figure 1).

Figure 1. Ultrasound scans of abdomen



Ultrasound examination of the abdomen showed the presence of interloop ascitic fluid with fibrotic branch (panel A). Mesenteric thickening (panel B). The use of linear probe (5-8 Mhz) showed thickening of the peritoneal wall (panel C) and enlarged lymph nodes with mesenteric thickening (panel D).

Figure 2. Histological section of peritoneum



Granulomatous inflammation with giant cells in histologic examination of the peritoneum

The ultrasound findings raised suspicion for inflammation of the peritoneal cavity and mesentery. An exploratory paracentesis revealed that the ascitic fluid was an exudate with a high proportion of lymphocytes. Differential diagnosis at this point included four groups of disorders: i) infectious disease; ii) also in relation to the history of immigration of the patient from a tropical area, inflammatory bowel disease; iii) autoimmune disease; and iv) lymphoma of the small intestine.

Test results for antinuclear antibodies, smooth muscle antibodies, double stranded DNA, SSA, SSB, Sm, RNP, Scl antigens, anti-cyclic citrullinated peptide IgG antibodies, anti-neutrophil cytoplasm antibodies were negative.

The patient's temperature fell into normal range when meropenem and amikacine were administered intravenously. The abdominal pain was improved although the patient continued to report diffuse discomfort associated with nausea.

Colonoscopy revealed no alteration. Test results were negative for hepatitis A, B and C, human immunodeficiency virus, syphilis, *Bartonella* species, *Legionella* *Borrelia*, toxoplasma, herpes simplex virus, parvovirus, cytomegalovirus, *Ehrlichia*, *Anaplasma*, *Rickettsia*, *Coxiella*, *Brucella*, *Leishmania*, Epstein Barr, *Salmonella*, and *Shigella*. We focused our diagnostic hypothesis on peritoneal tuberculosis. Skin test with PPD, Quantiferon test, urine, fecal, and ascitic fluid cultures were negative for *Mycobacterium tuberculosis* infection.

A contrast-enhanced tomography scan of the body was negative; in particular computed tomography (CT) of the abdomen did not confirm the ultrasound report except for the presence of ascitic fluid. Subsequently, an enteric CT was performed showing dilatation of mesenteric loops with hypotonia of the wall, conglomeration of jejuna and ileal loops and fluid among the loops as had been seen at ultrasound examination.

Since the patient continued to complain of symptoms an exploratory laparotomy was performed showing thickening and stiffness of the parietal peritoneum with increased vascularization that were referred to chronic inflammation, conglomeration of ileal loops, and thickening of the visceral peritoneum with the presence of several white-yellow nodules. Histologic examination showed the presence of granulomatous inflammation with giant cells (Figure 2) and standard chemotherapy treatment with rifampicin, isoniazid, pyrazinamide and ethambutol was started. Biopsy culture was positive for

Mycobacterium tuberculosis after two weeks. Lowenstein-Jensen media cultures were grown, and radiometric, fluorometric Automated Mycobacteria Growth Indicator Tube System (BACTEC 960/MGIT) and nucleic acid amplification assays (PCR for *Mycobacterium tuberculosis* complex) were performed.

After one month of treatment the clinical condition of the patient improved and he no longer complained of any kind of abdominal discomfort. The therapy was continued for twelve months without side effects; in particular, rifampicin, isoniazid, pyrazinamide and ethambutol were administered for two months and then only rifampicin and isoniazid for another six months. After three months the ascitic fluid and mesenteric thickening were no longer detectable on ultrasound examination.

Discussion

Abdominal tuberculosis is an infection involving different structures of the abdomen including the gastrointestinal tract, viscera and peritoneum. Although abdominal tuberculosis continues to be a significant health problem in the developing world, recently there has been an increase in the number of patients in developed countries. This is partly a result of increasing travel and migration and also of the rising number of patients susceptible to opportunistic infections [2-3].

In Africa the incidence of TB is about 3 million incident cases and extrapulmonary TB accounted for 19% of all TB cases reported [4]. The principal cause is *Mycobacterium tuberculosis*. Abdominal TB may be a primary infection, or secondary following reactivation, usually from a primary pulmonary focus. Routes of infection are ingestion, for example, of bacilli in sputum from an active focus in the lung, haematogenous spread from the lung, from infected lymph nodes, and direct spread from adjacent organs. Unpasteurized milk and milk products are the main routes of transmission of zoonotic TB caused by *Mycobacterium bovis* in countries where there are no eradication programmes [5].

Intestinal tuberculosis can affect the entire intestine, from the esophagus to the rectum, and can be confused with other pathologies. In particular, the clinical presentation can mimic both inflammatory diseases such as peptic ulcer, Crohn's disease, ulcerative colitis and neoplastic diseases such as cancer of the esophagus, stomach or colon [6,7]. Peritoneal TB (PTB) is the most frequent form of abdominal tuberculosis and involves—alone or in

combination—the peritoneal cavity, mesentery, and omentum [8].

The symptoms and signs of PTB are nonspecific and include abdominal pain and ascites and the diagnosis still requires a high suspicion index. Diagnosis of PTB remains a challenge also because of the lack in sensitivity of laboratory tests. Ascitic fluid analyses of patients with peritoneal TB reveal high protein levels and high leukocyte counts with a predominance of lymphocytes. Ziehl-Neelsen staining of ascitic fluid is untrustworthy and is positive in only 3% of PTB cases [9]. A mycobacterial culture requires prolonged incubation and is positive in only a third of patients. Tuberculin skin testing and interferon- γ assays (QuantiFERON-TB Gold In-Tube, Cellestis, Chadstone, Victoria, Australia) are mostly useful in the diagnosis of latent infections. Other tests such as ascitic fluid adenosine deaminase (ADA) and polymerase chain reaction (PCR) for *Mycobacterium* may help in the diagnosis but their result is low [9]. In our case we performed all the laboratory investigations except adenosine deaminase and all of them were negative. We did not test adenosine deaminase because of laboratory technical problems.

This case underscores the importance of ultrasound in guiding us to the clinical suspicion of PTB; indeed, ultrasound was crucially important in revealing all the elements necessary to suspect chronic peritonitis. In our experience, ultrasound oriented the diagnosis and should be the first diagnostic investigation in the suspicion of peritoneal tuberculosis, especially in a high-risk population. Ultrasound was able to identify the same alterations of an entero CT but with the advantage of being less expensive, widely available, and easy to perform. The common imaging features that may be seen with ultrasound in peritoneal TB are given by the possibility to detect the presence of ascites, the involvement of the peritoneal layers, mesentery and omentum. Ascites is easy to recognize and appears anechoic if it is a free fluid without debris. The presence of internal echoes is characteristic of exudative ascites. Ascites also could be focal if it is identified as an interloop fluid collection and loculated if the fluid is delimited by septa (Figure1, panel A). Peritoneal thickening appears as an irregular hypoechoic layer (Figure1, panel C). When peritoneal tuberculosis is suspected, ultrasound must be performed using both convex and linear probes. The use of linear transducers (5-8 Mhz) is very important because, using high frequencies, is easier to evaluate the presence of focal or diffuse thickening of the

peritoneum, ruling out in this way chronic inflammation from malignancies. Moreover, a colour Doppler should be performed to evaluate thickening of the peritoneum, to identify hyperaemia. Sonography is more sensitive than CT in the detection of diffuse peritoneal thickening, especially in the presence of ascities, characteristically found in chronic inflammation.

The involvement of the mesentery is common and can be found in an early stage and is characterized by a thickening of the wall, associated with an increase in the echogenicity and the presence of few lymph nodes within it (Figure1 panels C and D). In later stages of the disease, lymph nodes may be sonographically visualized as hypoechoic areas with irregular borders due to a conglomerate of caseating necrosis. In the case of peritoneal tuberculosis, the greater omentum is thickened with a heterogeneous echotexture, and sometimes contains hypoechoic nodules [10].

The combination of epidemiological data, clinical history of the patient, and the abdominal ultrasound results was useful in diagnosing PTB in our patient, and use of this method can avoid delays in initiating treatment and decrease diagnostic costs by avoiding more expensive exams [11]. The appropriate use of ultrasound should motivate clinicians to start a trial of medical therapy for TB rather than try to find a causative agent. According to the World Health Organization (WHO), in the case of high suspicion of TB, antibiotic therapy must be performed, and in this sense ultrasound could be very useful in monitoring the response to the therapy.

In developing countries, where the prevalence of TB is high, particularly in smear-negative TB in HIV-positive patients, ultrasound could have a potential public health benefit in terms of more rapid diagnosis, limitation of disease transmission, reduction of development of multidrug-resistant TB, and reduction of morbidity and mortality of PTB [12,13]. Despite these benefits, the use of ultrasound in rural, limited-resource settings has not reached its full potential because of the lack of equipment and trained personnel. The World Health Organization scientific Group on Clinical Diagnostic Imaging has noted that the need for trained personnel is greater than the need for equipment [14], and for that reason, short training courses on ultrasound for physicians or other health care workers, focused on limited key findings, may be an option to provide this technical knowledge in countries where diagnostic methods are limited [15].

References

1. Ramesh J, Banait GS, Ormero LP (2008) Abdominal tuberculosis in a district general hospital: a retrospective review of 86 cases. *Q J Med* 101: 189-195.
2. Raviglione MC, Snider DE Jr, Kochi A (1995) Global epidemiology of tuberculosis: morbidity and mortality of a worldwide epidemic. *JAMA* 273: 220-226.
3. Braun MM, Byers RH, Heyward WL (1990) Acquired immunodeficiency syndrome and extra-pulmonary tuberculosis in the United States. *Arch Intern Med* 150: 1913-1916.
4. World Health Organization (2012) Global Tuberculosis Report 2012. Available at www.who.int/tb/publications/global_report/en/. Last accessed 10 December 2012.
5. Thoeni RF, Margulis AR (1979) Gastrointestinal tuberculosis. *Semin Roentgenol* 14: 283-294.
6. Zhou ZY and Luo HS (2006) Differential diagnosis between Crohn's disease and intestinal tuberculosis in China. *Int J Clin Pract* 60: 212-214.
7. Donoghue HD and Holton J (2009) Intestinal tuberculosis. *Current Opinion in Infectious Disease* 22: 490-496.
8. Sanai FM and Bzeizi KI (2005) Systematic review: tuberculous peritonitis-presenting features, diagnostic strategies and treatment. *Aliment Pharmacol Ther* 22: 685-700.
9. Sandeep MP and Sweetser S (2011) The wet-ascitic form of tuberculous peritonitis. *Hepatology* 54: 364-365.
10. Batra A, Singh Gulati M, Sarma D, Shashi Bala P (2000) Sonographic appearances in abdominal tuberculosis. *Journal of Clinical Ultrasound* 28: 233-245.
11. Heller T, Goblirsch, Wallrauch C, Lessells R, Brunetti E (2010) Abdominal tuberculosis: sonographic diagnosis and treatment response in HIV-positive adults in rural South Africa. *Int J Infect Dis* 14 Suppl 3: 108-112.
12. Bussmann H, Koen E, Arhin-Tenkorang D, Munyadzwe G, Troeger J (2001) Feasibility of an ultrasound service on district health care level in Botswana. *Trop Med Int Health* 6: 1023-1031.
13. Shah SP, Epino H, Bukhman G, Umulisa I, Dushimiyimana J, Reichman A, Noble VE (2009) Impact of the introduction of ultrasound service in a limited resource setting: rural Rwanda 2008. *BMC Int Health Hum Rights* 9: 4.
14. World Health Organization (1998) Training in diagnostic ultrasound: essentials, principles and standards. Report of a WHO study group. <http://apps.who.int/bookorders/anglais/dartprt1.jsp?codlan=1&codcol=10&codcch=875>. Last accessed 10-December 12.
15. Heller T, Wallrauch C, Lessells R. J, Goblirsch S, Brunetti E (2010) Short report: Short course for focused assessment with sonography for human immunodeficiency virus/tuberculosis: preliminary results in a rural setting in South Africa with high prevalence of human immunodeficiency virus and tuberculosis. *Am J Trop Med Hyg* 82: 512-515.

Corresponding author

Gianpaolo Vidili, MD, PhD
 Dipartimento di medicina clinica e sperimentatale
 Clinica Medica
 Azienda Ospedaliero Universitaria
 Viale S. Pietro 8
 07100 Sassari, Italy
 Telephone: +39 079 228185
 Mobile phone number: +39 366 6873061
 Fax: +39 079 228387
 Email: gianpaolovidili@uniss.it

Conflict of interests: No conflict of interests is declared.