



Case Report

Open Access

Unusual Skin Metastasis due to Adenocarcinoma of the Stomach: A Case Report

Pruneddu S^{1*}, Piras D¹, Wijesuriya N² and Cerio R³¹Dermatology Department, University of Sassari, Italy²Department of Histopathology, The Royal London Hospital, London, UK³Department of Dermatology, Barts and the Royal London Hospitals NHS Trust, London, UK

Clinical Findings

A 68-year-old man presented with a skin thickening of the anterior neck started few months earlier. Upper respiratory and digestive tract had already been examined which proved normal. On clinical examination a hyper pigmented massively indurated leathery plaque was seen on the anterior and lateral aspect of the neck from the submandibular region down to the jugular fossae (Figure 1). The plaque was firm, well demarcated and measured 15 by 12 cm in diameter. It had a cobblestone like appearance with exaggerated folds, and was non painful. Patient complained of a mild discomfort while swallowing saliva of recent onset, but was otherwise asymptomatic. All his routine blood test was normal. The full skin examination was otherwise unremarkable. Our main differential diagnosis at that stage included a reactive process such as a sclerodermatous process, a neoplastic reaction or a lymph proliferative disease.

Histopathological findings and diagnosis

Deep skin biopsy from the neck area was obtained which showed on low power a normal epidermis and a diffuse dermal infiltrate, which was highly cellular (Figure 2a). On higher power those cells had a

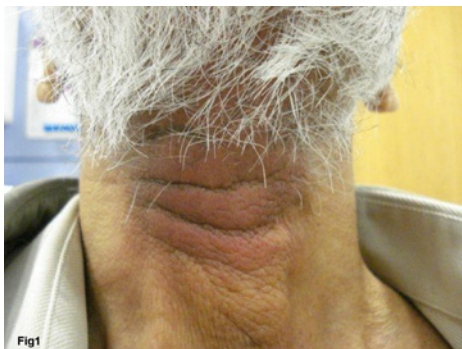


Figure 1: Well demarcated, hyper pigmented, firm, leathery plaque on lateral and anterior aspect of the neck.

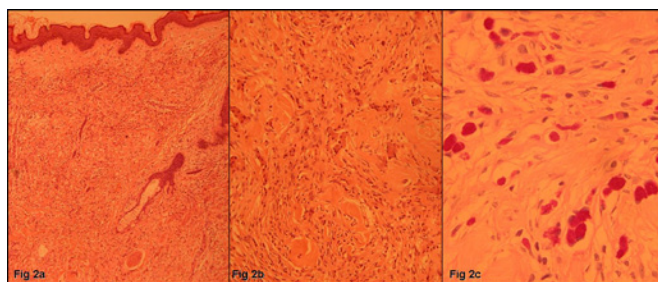


Figure 2: a diffuse highly cellular dermal infiltrate, b spindly shaped cells with abundant granular cytoplasm and an eccentric nuclei. Hypertrophic and prominent collagen boundless, c Positive violet staining for mucine.

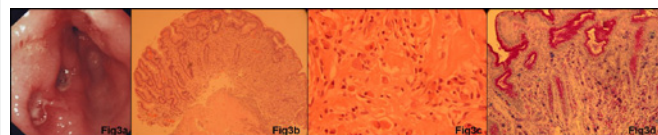


Figure 3: a gastric antrum: thickened and erithematous mucosa with 3 deep ulcers, b histology e&e low power: monomorphic cellular infiltrate in the lamina propria of the gastric mucosa, c higher power e&e: ring cell morphology of the cellular infiltrate with copious granular cytoplasm and eccentric nuclei, d PASD: presence of mucine in the cell cytoplasm, in dark violet filling the gastric mucosa.

spindly appearance, a copious amorphilic granular cytoplasm and an eccentric hyper chromatic and mildly pleomorphic nuclei. The dermis was filled with several hypertrophic and prominent collagen bundles between the cellular infiltrate (Figure 2b). Specific stains highlighted the presence of mucin in the cytoplasm of the cells (Figure 2c).

Immunohistochemical analysis showed a mild positivity for CK 7, strong positivity for CK 20 and carcinoma embryonic antigen and negativity for prostate specific antigen.

The patient was then urgently referred to a gastroenterologist and underwent an oesophagogastroduodenoscopy. Endoscopic examination showed a diffusely thickened and erithematous mucosa and 3 deep ulcers on the gastric antrum that looked malignant from their clinical appearance (Figure 3a).

Biopsy from one of those areas showed histologically a diffuse monomorphic cellular infiltrate in the lamina propria (Figure 3b). On higher magnification the cellular infiltrate had a ring cell morphology with copious granular cytoplasm and eccentric hyper chromatic and pleomorphic nuclei (Figure 3c), which was identical to the one observed in the skin specimen of the neck.

Specific stains highlighted the presence of mucin in the cell cytoplasm, filling diffusely the gastric mucosa (Figure 3d). A final diagnosis of carcinoma en cuirasse (CEC) of the neck region due to advanced adenocarcinoma of the stomach was made.

The patient was referred to the oncologist for further management,

*Corresponding author: Pruneddu S, Dermatology Department, University of Sassari, Italy, E-mail: sarapru@hotmail.it

Received October 07, 2011; Accepted November 02, 2011; Published November 06, 2011

Citation: Pruneddu S, Piras D, Wijesuriya N, Cerio R (2011) Crohn's Disease and Mucocutaneous Conditions. J Clin Exp Dermatol Res S3:001. doi:10.4172/2155-9554.S3-001

Copyright: © 2011 Pruneddu S, et al. This is an open-access article distributed under the terms of the Creative Commons Attribution License, which permits unrestricted use, distribution, and reproduction in any medium, provided the original author and source are credited.

where he underwent palliative chemotherapy with Irinotecan for the adenocarcinoma and radiotherapy on the plaque of the neck for symptomatic relief.

Discussion

Cutaneous metastases from carcinoma are relatively uncommon in clinical practice compared to metastasis in other organs of the body with ranges varying from 0.6 to 10% of all metastatic diseases. Cutaneous metastasis may herald the diagnosis of internal malignancy and for this reason they are very important to recognize. Actually, early recognition can lead to accurate and prompt diagnosis and timely treatment, but a high index of suspicion is required as clinical findings may be subtle. In most cases, cutaneous metastases develop after the initial diagnosis of the primary malignancy (metastases of breast carcinoma involving the chest wall several years after a mastectomy). In a very small percentage of patients, metastases may be discovered at the same time or prior to the diagnosis of a primary tumour.

In men most common sources of cutaneous metastasis belong from lungs and large intestine, but the stomach as well can be responsible even if with a low frequency [1]. In addition secondary deposits on skin of face and neck are mainly associated with squamous carcinoma of the oral cavity, while gastrointestinal tumours usually tend to involve the anterior abdominal wall. Intra-abdominal tumours sometimes metastasize to the skin of the umbilicus to form the so-called Sister Mary Joseph's nodule.

As for their variants, several clinical patterns of cutaneous metastasis can be observed. Most frequently a solitary nodule or groups of nodules are noticed, or in other cases the skin may presents with erythematous and inflammatory lesions. Less frequently or even rarely different manifestations from the previous mentioned can be seen, such as scarring or morphea-like lesions, modification of the scalp area, like alopecia neoplastica, which is a secondary deposit of malignant cells on the scalp in most cases due to breast carcinoma. Very rarely skin metastasis can present as indurated thick and fixed plaques as carcinoma en cuirasse.

(CEC) is the term generally applied to extensive infiltrating plaques resulting from cutaneous metastasis from cancer in other organs of the body. Taylor and Meltzer described this peculiar type of skin metastasis for the first time in 1938 [2]. Its name belongs from the Latin "coriaceous" that means made of leather, from corium, the original breastplate of ancient warriors.

These plaques are usually formed from the coalescence of hard carcinomatous nodules, but at other times pronounced inflammatory reaction is seen, so that many cases have been referred to as carcinoma erysipelotoides. Several cases of this inflammatory type of metastasis have been described in literature, all arising from the breast and involving the skin of the chest [3]. A case of this type of metastatic growth of the scrotal area was described from a primary lung carcinoma [4]. A report of a similar case involving the face and neck was reported, but with the primary growth in the rectum [5]. In all those cases the underlying neoplastic condition had been treated with appropriate chemotherapy or more rarely with adjuvant surgery.

A previous case of this type of metastasis arising from a stomach malignancy was described in 1950 [6], but our knowledge this is the first case reported of a (CEC) in a distant cutaneous site from the primary malignancy.

References

1. Krathen RA, Orengo IF, Rosen T (2003) Cutaneous metastasis: A meta-analysis of data. *South Med J* 96: 164–167.
2. Taylor, G, Meltzer A (1938) Inflammatory carcinoma of the breast. *Am J Cancer*: 33-49.
3. Carlesimo M, Rossi A, De Marco G, Narcisi A, Cacchi C, et al. (2009) Carcinoma en cuirasse of the breast. *Eur J Dermatol* 19: 289-290.
4. Ferguson MA, White BA, Johnson DE, Carrington PR, Schaefer RF (1998) Carcinoma en cuirasse of the scrotum: an unusual presentation of lung carcinoma metastatic to the scrotum. *J Urol* 160: 2154-2155.
5. Reuter M J, Nomland R (1941) inflammatory cutaneous meta- static carcinoma. *Wis Med* 40:196-201.
6. Harvey G, Cochrane T (1950) Carcinoma en cuirasse; primary lesion in stomach. *AMA Arch Derm Syphilol* 62: 651-654.

This article was originally published in a special issue, **Oncodermatology** handled by Editor(s). Dr. AE Reszko, Cornell University, USA

Submit your next manuscript and get advantages of OMICS Group submissions

Unique features:

- User friendly/feasible website-translation of your paper to 50 world's leading languages
- Audio Version of published paper
- Digital articles to share and explore

Special features:

- 200 Open Access Journals
- 15,000 editorial team
- 21 days rapid review process
- Quality and quick editorial, review and publication processing
- Indexing at PubMed (partial), Scopus, DOAJ, EBSCO, Index Copernicus and Google Scholar etc
- Sharing Option: Social Networking Enabled
- Authors, Reviewers and Editors rewarded with online Scientific Credits
- Better discount for your subsequent articles

Submit your manuscript at: www.editorialmanager.com/clinicalgroup