

Case Report

Abnormal Intraparotid Termination of Facial Vein and Its Clinical Importance

Satheesha Nayak B, Srinivasa Rao S (✉), Sapna M, Ashwini LS, Jyothsna P, Ashwini Aithal P, Swamy Ravindra S, Abhinitha P

Department of Anatomy, Melaka Manipal Medical College, Manipal Campus, Manipal University, Madhav Nagar, Manipal, Karnataka State, India. 576104.

Abstract

Facial vein is the main vein of the face. Though its origin is constant, it frequently shows variations in its termination. We report a rare type of variation of facial vein. The right facial vein coursed transversely across the masseter, superficial to the parotid duct and entered into the substance of the parotid gland, at its anterior border. Deep dissection of the gland revealed the abnormal termination of facial vein into the superficial temporal vein. The transverse facial vein drained into the facial vein. The superficial temporal vein after receiving the facial vein continued as retromandibular vein. Knowledge of this anomalous course and termination of facial vein may be important for the surgeons doing parotid, maxillofacial and plastic surgeries.

Keywords: Facial vein, parotid gland, superficial temporal vein, transverse facial vein

Correspondence:

Srinivasa Rao Sirasanagandla, Department of Anatomy, Melaka Manipal Medical College, Manipal Campus, International Centre for Health Sciences, Manipal University, Madhav Nagar, Manipal, Karnataka State, India. 576104. Tel no: +91-820-2922644 Fax: +91-820-2571905 Email: seenaih.anat@gmail.com

Date of submission: 30 Aug, 2012

Date of acceptance: 20 Sept, 2012

Introduction

Facial vein is the main vein of the face. It is the continuation of angular vein which is formed by the union of supratrochlear and supraorbital veins. Normally it runs on the side of the nose, passes deep to the zygomaticus major muscle, runs on the buccinator muscle along the anterior border of masseter and crosses the mandible and descends superficial to the submandibular salivary gland into the neck. It terminates by joining the anterior division of retromandibular vein to form the common facial vein which in turn terminates into the internal jugular vein. The facial vein is closely related to the facial artery in its course. It usually runs parallel to and behind the facial artery in the face (1). Knowledge of its variations is very useful for general surgeons, plastic surgeons and maxillofacial surgeons as a varied course of it might be the cause of bleeding during the surgeries.

Case Report

During routine dissection classes for medical undergraduates in Melaka Manipal Medical College, Manipal University, we observed a variant course and termination of the facial vein in the right side of the face of an adult male cadaver approximately aged 60 years. While dissecting the face, it was noted that the facial vein had a normal origin. It descended down along the side of the nose and reached the surface of buccinator muscle. It then coursed transversely on the masseter muscle with slight upward inclination. It crossed the parotid duct from below upwards, being superficial to the duct and then entered the substance of the parotid gland. Within the parotid gland, it received the transverse facial vein and finally terminated into the superficial temporal vein just above the termination of the maxillary vein (Fig. 1 and Fig. 2). The facial artery had a normal course and branching pattern.

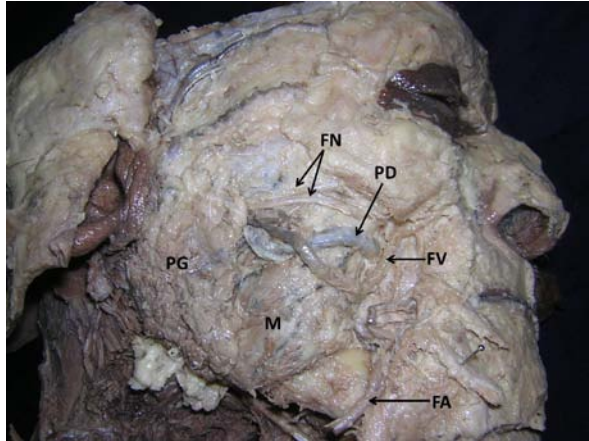


Figure 1: Photograph of the dissection of the right side of the face showing the unusual course of facial vein, and its entry into the parotid gland after crossing the parotid duct superficially. (PG; parotid gland, FN; facial nerve, PD; parotid duct, FV; facial vein, FA; facial artery, M; masseter muscle)

Discussion

The venous variations of the face are more common on the right side of the face (2). The facial vein normally joins with the anterior division of the retromandibular vein to form the common facial vein, which drains into the internal jugular vein. It shows frequent variations in its termination. It may terminate into the external jugular vein (3, 4) or into subclavian vein (5). Its high termination into the retromandibular vein within the parotid gland has also been reported (6). So far only one case has been reported where the facial vein terminated into the superficial temporal vein (7). There is no report on termination of the transverse facial vein into the facial vein. According to our knowledge for the first time in the literature, we report the abnormal intraparotid course of facial vein associated with the termination of transverse facial vein into it.

Knowledge of venous variations is important for the surgeons performing head and neck micro vascular surgeries to avoid unnecessary bleeding during intra operative trial and error procedures (8). Intraparotid course and termination of the facial vein may result in bleeding during parotid surgeries. The vein might get compressed by the parotid duct where it crosses the parotid duct or it might compress the parotid duct. If the vein compresses the parotid duct, this might result in improper drainage of saliva, resulting in enlargement of the gland, which might be mistaken for the presence of a sialolith. The varied course and termination may result in complications during removal of skin flaps for plastic surgery also.

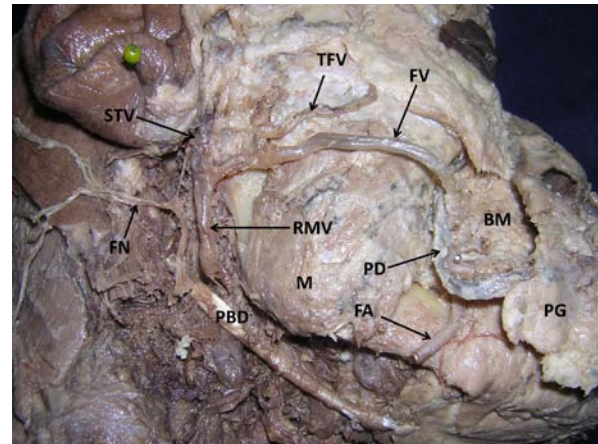


Figure 2: Photograph of the deep dissection of the right side of the face, where the parotid gland and duct have been dissected and reflected anteriorly to locate the termination of facial vein into the superficial temporal vein. Note the termination of transverse facial vein into the facial vein. (PG; parotid gland, PD; parotid duct, FV; facial vein, FA; facial artery, M; masseter muscle, BM; buccinator muscle, TFV; transverse facial vein, STV; superficial temporal vein, RMV; retromandibular vein, FN; facial nerve reflected back, PBD; posterior belly of digastric muscle)

Conclusion

The abnormal intraparotid course of the facial vein is clinically very important due to its rarity. It might bleed significantly in the transverse incisions while draining the parotid abscess. Knowledge of its close relationship with the parotid duct is also of importance for the surgeons removing the sialoliths.

References

1. Standring S, Borley NR, Collins P, Crossman AR, Gatzoulis MA, Healy JC, *et al.* Gray's Anatomy- The Anatomical Basis of Clinical Practice. London: Elsevier Churchill Livingstone, 2008, pp-492.
2. Mehra S, Kaul JM, Das S. Unusual venous drainage pattern of face: a case report. *J Anat Soc India* 2003; 52(1): 64-65.
3. Choudhry R, Tuli A, Choudhry S. Facial vein terminating in the external jugular vein: an embryologic interpretation. *Surg Radiol Anat* 1997; 19(2): 73-77.
4. Prakash R, Prabhu LV, Kumar J, Nayak V, Singh G. Variations of jugular veins: phylogenic correlation and clinical implications. *South Med J* 2006; 99(10): 1146-1147.

5. Prakash BB, Bhagath KP. A rare termination of left common facial vein into left subclavian vein: a case report. *Int J Morphol* 2007; 25(3): 555-556.
6. Kopuz C, Yavuz S, Cumhuri M, Tetik S, Ilgi S. An unusual coursing of the facial vein. *Kaibogaku Zasshi* 1995; 70(1): 20-22.
7. Peuker ET, Fischer G, Filler TJ. Correspondence-Facial vein terminating in the superficial temporal vein: a case report. *J Anat* 2001; 198(4): 509-510.
8. Nagase T, Kobayashi S, Sekiya S, Ohmori K. Anatomical evaluation of the facial artery and vein using color doppler ultrasonography. *Ann PlastSurg* 1997; 39(1): 64-67.