

Curcumin as an Anti-Arthritic Agent in Collagen-Induced Arthritic Sprague-Dawley Rats

(Kurkumin sebagai Suatu Agen Antiartritik untuk Tikus Sprague-Dawley yang Mengalami Artritis Aruhan Kolagen)

A.F. ZAHIDAH, O. FAIZAH, K. NUR AQILAH & K. TATY ANNA*

ABSTRACT

Curcuma longa or turmeric has long been used in traditional medicine by the local population in Malaysia as an antiinflammatory agent. It has been proven to contain natural antiarthritic compound called curcumin. Joints abnormality and destruction have been implicated in the pathogenesis of rheumatoid arthritis (RA) due to inflammatory reactions. In this study, collagen-induced arthritis (CIA) model was utilized to study the effects of curcumin on joint inflammation in Sprague-Dawley rats. Body weight measurement, arthritis score assessment and radiology score assessment were carried out at specific intervals throughout this study. The results showed that the mean arthritis and radiology scores for animal groups designated as CIA Curcumin^C and CIA Curcumin^T were significantly lower compared with the negative control (CIA OV) group respectively. The mean arthritis scores for CIA Curcumin^C group is significantly lower compared with CIA Curcumin^T group but there is no significant difference in the mean radiology scores between the CIA Curcumin^C and CIA Curcumin^T groups. In conclusion, the oral supplementation of curcumin at the dose of 110 mg/mL/kg/day has a potential to delay and improve joint abnormality and injury in Sprague-Dawley rats with CIA.

Keywords: Arthritis score; collagen-induced arthritis; curcumin; radiology score

ABSTRAK

Curkuma longa atau kunyit telah lama digunakan dalam perubatan tradisi oleh penduduk tempatan di Malaysia sebagai agen antiinflamasi. Ia terbukti mengandungi agen antiartritik semula jadi iaitu kurkumin. Ketaknormalan pada sendi terlibat dalam patogenesis artritis reumatoid (RA) disebabkan tindak balas inflamasi. Dalam kajian ini, model artritis aruhan kolagen (CIA) telah digunakan untuk mengkaji kesan kurkumin ke atas sendi tikus Sprague-Dawley. Sepanjang penyelidikan ini, pengukuran berat badan, penilaian skor artritis dan penilaian skor radiologi dilakukan pada selang masa tertentu. Hasil kajian menunjukkan bahawa purata skor artritis dan purata skor radiologi bagi kumpulan CIA kurkumin^C dan CIA kurkumin^T masing-masing adalah lebih rendah secara signifikan berbanding kumpulan kawalan negatif (CIA OV). Purata skor artritis bagi kumpulan CIA kurkumin^C adalah rendah secara signifikan berbanding kumpulan CIA kurkumin^T tetapi tiada perbezaan yang tekal pada purata skor radiologi antara kumpulan CIA kurkumin^C berbanding kumpulan CIA kurkumin^T. Kesimpulannya, suplemen oral kurkumin sebanyak 110 mg/mL/kg/hari berpotensi memperlakan dan memperbaiki ketaknormalan serta kecederaan pada sendi tikus Sprague-Dawley yang mengalami CIA.

Kata kunci: Artritis aruhan kolagen; kurkumin; skor artritis; skor radiologi

INTRODUCTION

Rheumatoid arthritis (RA) is a chronic autoimmune inflammatory disease that affects the joints and other tissues in the body (Brooks 2006). RA patients experience swelling in the joints, synovial tissue inflammation and subsequent damage to the cartilage. This will result in significant disability and decrease in the quality of life (Lindqvist et al. 2003).

RA affects about 1% of the population around the world (Brooks 2006). The epidemiology of RA in female to male is 3 to 1 and the peak age of RA among the patients is at the adult and the following stage (Borashan et al. 2009; Khurana & Berney 2005). Usually, RA is identified by their symmetrical pattern (Khurana & Berney 2005).

One of the most important features which distinguish RA from the other inflammatory arthritis is dependent on its ability to spread the disease to new joints (Emery & Symmons 1997). The aetiology of RA is multifactorial (Brooks 2006); the disease can arise as a result of complex interactions between genetic, hormonal, immunological, infective, environmental and physiological factors (MSR 2010).

Non-steroidal anti-inflammatory drugs (NSAIDs), steroidal agents and immunosuppressants are usually used as RA treatment. However, their side effects and toxicity call for alternative, safer and more effective natural product based drugs (Borashan et al. 2009). Consequently, there is dramatically growing attractions in herbal medicines among individuals who suffer from RA and in the RA

research community (Rao et al. 1999). Rhizomes of *Curcuma longa* has been used extensively as a spice in food and as treatment for many diseases in Ayurvedic and traditional Chinese medicine since ancient time (Ramadan et al. 2010). Curcumin (diferuloylmethane) is a major constituent found in the rhizomes of *Curcuma longa* which is a yellow-coloured powder (Borashan et al. 2009; Goel et al. 2008). It has the potential to treat RA (Aggarwal & Harikumar 2009).

Collagen-induced arthritis (CIA) is an experimental autoimmune disease that can be induced with type II collagen in the appropriate rodent strains and non-human primates (Brand et al. 2004). When compared with other experimental arthritis models, the characteristics of the CIA model resemble human RA more closely in its clinical, pathological, immunological and histological aspects (Brand et al. 2004; Kannan et al. 2005). In addition, CIA facilitates the understanding of RA pathogenesis in human and help to generate new therapeutic regimen for RA (Cho et al. 2007). Therefore, this research was designed to study the effects of curcumin on joint inflammation in male *Sprague-Dawley* rats with CIA.

MATERIALS & METHODS

ANIMALS

Male *Sprague-Dawley* rats weighing 150-200 g were supplied by the Laboratory Animal Research Unit of Universiti Kebangsaan Malaysia, Kuala Lumpur. The animals were housed each one per cage. All animals were maintained with a balanced diet and water *ad libitum*. The study was approved by the Universiti Kebangsaan Malaysia Animal Ethics Committee (UKMAEC) with the approval no; PP/ANAT/2011/TATY/22-MARCH/369-MARCH-2011-DECEMBER-2011-NAR-CAT2. The UKMAEC guidelines were followed, throughout the study.

EXPERIMENTAL SETUP

A total of 30 rats were divided equally into five groups. The grouping details are as follows:

CTRL: Normal control rats (untreated, given vehicle, 1.0 ml/kg/day/oral of olive oil starting from day 0 until day 42).

CIAOV: Negative control rats (CIA induction then given vehicle, 1.0 ml/kg/day/oral of olive oil starting from day 14 until day 42).

CIA BM: Positive control rats (CIA induction then given reference drug, 0.5 mg/ml/kg/day/oral of betamethasone starting from day 14 until day 42).

CIA Curcumin^T: Treatment rats (CIA induction then given 110 mg/ml/kg/day/oral of curcumin starting from day 14 until day 42).

CIA Curcumin^C: Concurrent treatment with arthritic induction rats (CIA induction then given 110 mg/ml/kg/day/oral of curcumin starting from day 0 until day 42).

INDUCTION OF CIA

CIA was induced in male *Sprague-Dawley* rats using the method described by Brand et al. (2007). Rats were intradermally injected at the base of the tail with 150 µg of bovine type II collagen (Chondrex, USA) emulsified with incomplete Freund's adjuvant (IFA, Chondrex, USA) on the day 0.

ARTHRITIS SCORE ASSESSMENT

The incidence and severity of arthritis were evaluated using a system of arthritic scoring every 2 days beginning on the day after collagen emulsion injection by two independent observers. Lesions of both hind paws of each rat were graded from 0 to 4 according to its clinical arthritic signs described by Brand et al. (2007). The total arthritis scores were calculated from the sum of both hind paws, with a maximum possible score of 8 for each rat.

RADIOLOGY SCORE ASSESSMENT

At the end of the experiment (day 42), rats were anaesthetised intramuscularly with 0.1 ml per 100 g of rat body weight of Ketamil and Ilium xylazin-20 mixture (Troy Laboratories Pty, Australia). Anaesthetised rats were placed on a radiographic box at a distance of 107 cm from the X-ray source. Radiographic analysis of normal and arthritic hind paws was performed by using X-ray machine (GE Model ML 02F, Germany), with a 48 kVp exposure for 0.5 mAs. A blind and independent assessment of the radiological score was performed by two observers. The following radiological criteria were considered: score 0, normal, no tissue swelling or bone damage; score 1, tissue swelling and edema; score 2, joint erosion; score 3, bone erosion and osteophyte formation (Cuzzocrea et al. 2001). The total radiology scores were calculated from the sum of both hind paws, with a maximum possible score of 6 for each rat (Cuzzocrea et al. 2001).

STATISTICAL ANALYSIS

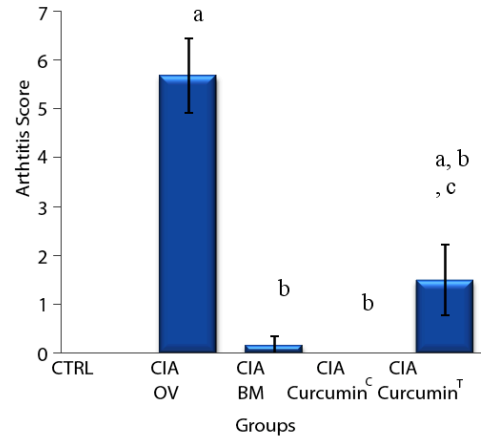
Statistical analysis was performed using SPSS statistical package version 19.0. All results were expressed as mean ± standard error of mean (SEM). Normality of distribution was verified by Shapiro-Wilk test. The parameters were analyzed by one-way ANOVA and followed by LSD and Tukey post hoc test to compare the difference among groups. The differences among groups were considered to be significant at $p < 0.05$.

RESULTS

Throughout the six weeks study, all arthritis rats showed persistent increase in both arthritis and radiology scores. Following the injections of collagen emulsion, rats developed arthritis beginning from day 8 onwards. Even before and after the onset of arthritis, curcumin at the dose of 110 mg/mL/kg/day for 28 days (CIA Curcumin^T) and

42 days (CIA Curcumin^c) markedly reduced the arthritis and radiology scores as compared with the vehicle-treated arthritic rats.

Figure 1 shows the arthritis scores in the control and experimental animal groups. As a result of inflammation induced by collagen emulsion, the arthritis scores was increased ($p < 0.05$) in olive oil-treated rats when compared with control rats. Treatment with betamethasone and curcumin beginning on day 14 showed significantly decreased ($p < 0.05$) arthritis scores. Treatment with curcumin beginning on the day of arthritis induction (day 0), has significantly ($p < 0.05$) inhibited the incidence of arthritis in comparison with olive oil-treated rats. However, treatment with curcumin beginning on day 14 showed markedly increased ($p < 0.05$) arthritis scores when compared with the treatment with curcumin starting on day 0.



Each bar represents the mean score \pm SEM, n=6
 a: $p < 0.05$ compared with CTRL group.
 b: $p < 0.05$ compared with CIA OV group
 c: $p < 0.05$ compared with CIA Curcumin^c group

FIGURE 1. Mean arthritis scores in different groups of rats

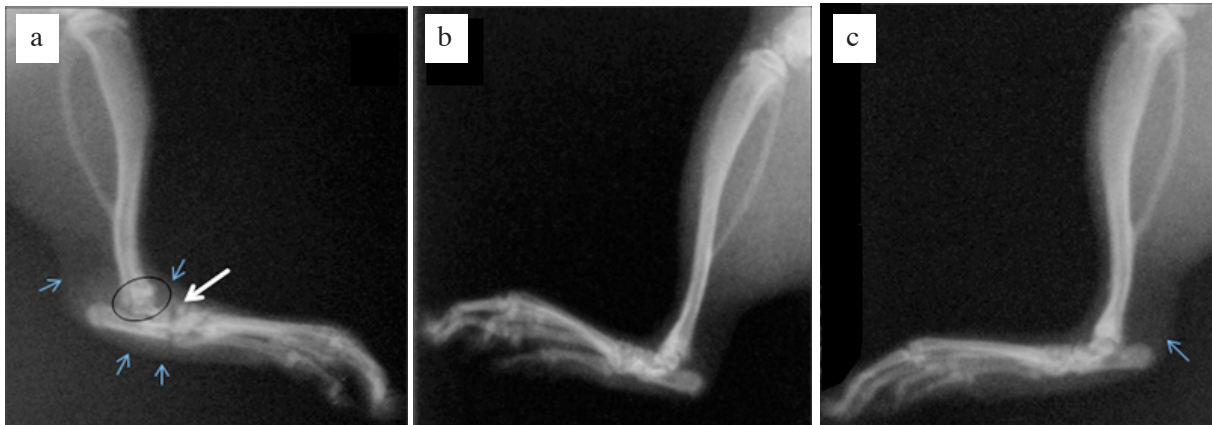
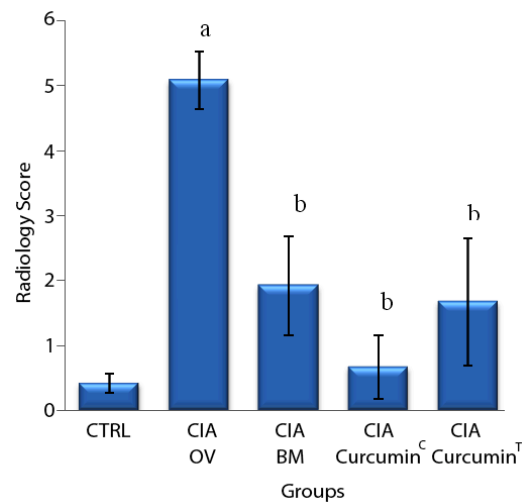


FIGURE 2. Radiographic images from CIA OV group (a) showing tissue swelling (small arrows), bone erosion (black circle) and osteophyte formation (thick white arrow), CTRL group, (b) showing a normal ankle joint, Curcumin^c group and (c) showing a mild tissue swelling (small arrow)

Radiographic images showed severe soft tissue swelling and edema, joint erosion, bone erosion and osteophyte formation in the joints of the olive oil-treated CIA rats in comparison with the joints of normal rats (Figure 2). In contrast, curcumin in both treatment protocols and betamethasone had significantly ($p < 0.05$) inhibit bone erosion and osteophyte formation of the arthritic joints in comparison with the olive oil-treated rats as revealed in the respective radiological scores (Figure 3).

DISCUSSION

RA is a disease that can affect the health and life of a person who is suffering from the chronic joints damage (AFM 2009). Macrophages are the initiators of the pathogenic cascade in RA pathology. When macrophages are activated in the synovial tissue, they are involved in the activation of inflammatory cells, cell contact, overexpression of



Each bar represents the mean score \pm SEM, n=6
 a: $p < 0.05$ compared with CTRL group
 b: $p < 0.05$ compared with CIA OV group

FIGURE 3. Mean radiological scores in different groups of rats

MHC class II molecules and cytokine production (Kinne et al. 2000).

Although natural plant based treatments are safe to use in various conditions, they are mostly ignored because their active components and molecular targets are not well defined (Aggarwal & Harikumar 2009). Curcumin has a high pleiotropic activity due to its complex chemical properties, ability to control various signaling pathways and capability of interacting with numerous molecular targets involved in inflammatory processes (Hatcher et al. 2008; Jurenka 2009).

Arthritis score is a clinical assessment of joint swelling (Funk et al. 2006). In this study, CIA rats showed a significant increase ($p < 0.05$) in arthritis scores compared with the control group. The alteration in plasma protein induces the synthesis of proinflammatory cytokines, prostaglandins, leukotrienes and matrix metalloproteinases that caused fluid accumulation in the synovium. This results in an increase in arthritis scores due to damage in joints and bones of the rat's paw (Cai et al. 2007; Joe et al. 1997).

This study demonstrated that CIA rats treated with betamethasone showed significantly lower ($p < 0.05$) arthritis scores compared with CIA rats treated with olive oil. Betamethasone is a quick acting drug that reduces the symptoms of CIA by inhibiting the production of pro-inflammatory cytokines which will in turn inhibit the inflammatory response and reduce the symptoms of arthritis (Makrygiannakis et al. 2006).

The curcumin which was given for 28 days and 42 days induced the reduction and inhibition of the joints inflammation, by reducing soft tissue swelling, erythema and ankylosis of joints. According to Moon et al. (2010), the reduction and inhibition of TNF- α and IL-1 β production cause disturbance to the cyclooxygenase-2 activity expression and reduction in the prostaglandins secretion. Hence, this suggests that curcumin has the capability in delaying the inflammatory response and reducing the occurrence of the joints inflammation symptoms. Thus, these changes will reduce arthritis scores.

Radiographs on the other hand provide a measure of damages that occur in patients with RA (Sokka 2008). Radiological studies showed that CIA rats treated with olive oil, experienced a significant progression ($p < 0.05$) in joint space narrowing, joint erosion, bone erosion and osteophyte formation. This caused a significant reduction in joints movement compared to the control group rats. Neutral matrix metalloproteinases are responsible for the pathological features of RA such as cartilage degradation (Liacini et al. 2002). The increase in the production of cytokines such as TNF- α and IL-1 β will help in the propagation of local or systemic inflammatory process in CIA (Nishikawa et al. 2003).

The radiological scores for the CIA rats treated with betamethasone was significantly lower ($p < 0.05$) compared to CIA rats treated with olive oil. Steroid drug caused a significant reduction in critical synovial mediator expression in the osteoclast differentiation process in RA

patients (Makrygiannakis et al. 2006). This results in a gradual decrease in joint erosion and joint space narrowing in RA disease.

Meanwhile, curcumin supplement for 28 days and 42 days were shown to be capable in arresting and reducing joint erosions and osteophyte formation. There is a significant decrease ($p < 0.05$) in the radiology scores when compared with CIA rats treated with olive oil. This radiological effect is in agreement with the findings in a study reported by Taty Anna et al. (2011). The mRNA upregulation of matrix metalloproteinases associated with arthritis was inhibited by curcumin, hence caused a reduction in the radiology scores (Onodera et al. 2000).

CONCLUSION

In this study, curcumin supplementation showed the capability to reduce arthritis and radiology scores. Therefore, this finding indicates that the oral supplementation of curcumin at the dose of 110 mg/mL/kg/day for 28 days (CIA Curcumin^T) and 42 days (CIA Curcumin^C) have a potential to delay and improve joint abnormality and injury in *Sprague-Dawley* rats with CIA.

ACKNOWLEDGEMENT

This research was supported by UKM GGPM grant, Grant No: UKM-GGPM-TKP-071-2010. We Dr. Suraya Aziz, Radiologist from Radiology Department, Universiti Kebangsaan Malaysia Medical Centre, Cheras, Kuala Lumpur, Malaysia and Nur Farhana Ab Kadir, X-ray technician from Diagnostic Imaging & Radiotherapy Department, Faculty of Allied Health Sciences, Universiti Kebangsaan Malaysia, Kuala Lumpur, Malaysia for their assistance.

REFERENCES

- AFM. 2009. *Pengenalan dan Perubatan Awal Penyakit Reumatoid arthritis*. Malaysia: Perbadanan Arthritis Malaysia.
- Aggarwal, B. & Harikumar, K. 2009. Potential therapeutic effects of curcumin, the anti-inflammatory agent, against neurodegenerative, cardiovascular, pulmonary, metabolic, autoimmune and neoplastic diseases. *The International Journal of Biochemistry & Cell Biology* 41(1): 40-59.
- Borashan, F.A., Ilkhanipoor, M., Hashemi, M. & Farah, F. 2009. Investigation the effects of curcumin on serum hepatic enzymes activity in a rheumatoid arthritis model. *Electronic Journal of Biology* 4(4): 129-133.
- Brand, D.D., Kang, A.H. & Rosloniec, E.F. 2004. The mouse model of collagen-induced arthritis. In *Autoimmunity: Methods and Protocols*, Perl, A. Totowa (ed.): Humana Press.
- Brand, D.D., Latham, K.A. & Rosloniec, E.F. 2007. Collagen-induced arthritis. *Nature Protocols* 2(5): 1269-1275.
- Brooks, P. 2006. Rheumatoid arthritis: aetiology and clinical features. *Medicine* 34(10): 379-382.
- Cai, X., Zhou, H., Wong, Y., Xie, Y., Liu, Z., Jiang, Z., Bian, Z., Xu, H. & Liu, L. 2007. Suppression of the onset and

- progression of collagen-induced arthritis in rats by QFGJS, a preparation from an anti-arthritic Chinese herbal formula. *Journal of Ethnopharmacology* 110(1): 39-48.
- Cho, Y., Cho, M., Min, S. & Kim, H. 2007. Type II collagen autoimmunity in a mouse model of human rheumatoid arthritis. *Autoimmunity Reviews* 7(1): 65-70.
- Cuzzocrea, S., Mazzon, E., Dugo, L., Serraino, I., Britti, D., Maio, M.D. & Caputi, A.P., 2001. Absence of endogenous interleukin-10 enhances the evolution of murine type II Collagen-Induced Arthritis. *European Cytokine Network* 12(4): 568-580.
- Emery, P. & Symmons, D.P.M. 1997. What is early rheumatoid arthritis?: definition and diagnosis. *Bailliere's Clinical Rheumatology* 11(1): 13-26.
- Funk, J.L., Oyarzo, J.N., Frye, J.B., Chen, G., Lantz, R.C., Jolad, S.D., Solyom, A.M. & Timmermann, B.N. 2006. Turmeric extracts containing curcuminoids prevent experimental rheumatoid arthritis. *Journal of Natural Products* 69(3): 351-355.
- Goel, A., Kunnumakkara, A. & Aggarwal, B. 2008. Curcumin as "Curecumin": From kitchen to clinic. *Biochemical Pharmacology* 75(4): 787-809.
- Hatcher, H., Planalp, R., Cho, J., Torti, F.M. & Torti, S.V. 2008. Curcumin: From ancient medicine to current clinical trials. *Cellular and Molecular Life Sciences* 65(11): 1631-1652.
- Joe, B., Rao, U.J. & Lokesh, B.R. 1997. Presence of an acidic glycoprotein in the serum of arthritic rats: modulation by capsaicin and curcumin. *Journal of Molecular Cell Biochemistry* 169: 125-134.
- Jurenka, J.S. 2009. Anti-inflammatory properties of curcumin, a major constituent of *Curcuma longa*: A review of preclinical and clinical research. *Alternative Medicine Review* 14(2): 141-153.
- Kannan, K., Ortmann, R. & Kimpel, D. 2005. Animal models of rheumatoid arthritis and their relevance to human disease. *Pathophysiology* 12(3): 167-181.
- Khurana, R. & Berney, S. 2005. Clinical aspects of rheumatoid arthritis. *Pathophysiology* 12(3): 153-165.
- Kinne, R.W., Brauer, R., Stuhlmuller, B., Palombo-Kinne, E. & Burmester, G.R. 2000. Macrophages in rheumatoid arthritis. *Arthritis Research* 2: 189-202.
- Liacini, A., Sylvester, J., Li, W.Q. & Zafarullah, M. 2002. Inhibition of interlenkin - 1 stimulated -1 (AP-1) and nuclear factor kappa B (NF-KB) transcription factors doewn-regulates matrix metalloproteinase gene expression in articular chondrocytes. *Matrix Biology* 21: 251-262.
- Lindqvist, E., Jonsson, K., Saxne, T. & Eberhardt, K. 2003. Course of radiographic damage over 10 years in a cohort with early rheumatoid arthritis. *Annals of the Rheumatic Diseases* 62: 611-616.
- Makrygiannakis, D., Af, Klint, E., Catrina, S.B., Botusan, I.R., Klareskog, E., Klareskog, L., Ulfgren, A.K. & Catrina, A. I. 2006. Intraarticular corticosteroids decrease synovial RANKL expression in inflammatory arthritis. *Arthritis Rheumatism* 54: 1463-1472.
- Moon, D.-O., Kim, M.-O., Choi, Y.H., Park, Y.-M. & Kim, G.-Y. 2010. Curcumin attenuates inflammatory response in IL-1 β -induced human synovial fibroblasts and collagen-induced arthritis in mouse model. *International Immunopharmacology* 10: 605-610.
- MSR. 2010. *What is Arthritis and Rheumatism?* Malaysia: Persatuan Reumatologi Malaysia.
- Nishikawa, M., Myoui, A., Tomita, T., Takahi, K., Nampei, A. & Yoshikawa, H. 2003. Prevention of the onset and progression of collagen-induced arthritis in rats by the potent p38 mitogen-activated protein kinase inhibitor FR167653. *Arthritis & Rheumatism* 48(9): 2670-2681.
- Onodera, S., Kaneda, K., Mizue, Y., Koyama, Y., Fujinaga, M. & Nishihira, J. 2000. Macrophage migration inhibitory factor up-regulates expression of matrix metalloproteinases in synovial fibroblasts of rheumatoid arthritis. *Journal of Biology Chemistry* 275:444-450.
- Ramadan, G., Al-Kahtani, M.A. & El-Sayed, W.M. 2011. Anti-inflammatory and anti-oxidant properties of *Curcuma longa* (Turmeric) versus *Zingiber officinale* (Ginger) rhizomes in rat adjuvant-induced arthritis. *Inflammation* 34(4) 291-301.
- Rao, J.K., Mihaliak, K., Kroenke, K., Bradley, J., Tierney, W.M. & Weinberger, M. 1999. Use of complementary therapies for arthritis among patients of rheumatologists. *Annals of International Medicine* 131: 409-416.
- Sokka, T. 2008. Radiographic scoring in rheumatoid arthritis. *Buletin of the NYU Hospital for Joint Diseases* 66: 166-168.
- Taty Anna, K., Elvy Suhana, M.R., Das, S., Faizah, O. & Hamzaini, A.H. 2011. Anti-inflammatory effect of *Curcuma longa* (turmeric) on collagen-induced arthritis: an anatomico-radiological study. *Clinica Terapeutica* 162(3): 201-207.

A.F. Zahidah
 Department of Biomedicine Science
 Faculty of Allied Health Sciences
 Universiti Kebangsaan Malaysia
 Jalan Raja Muda Abdul Aziz
 50300, Kuala Lumpur, Malaysia

O. Faizah, K. Nur Aqilah & K. Taty Anna*
 Department of Anatomy
 Faculty of Medicine
 Universiti Kebangsaan Malaysia
 Jalan Raja Muda Abdul Aziz
 50300, Kuala Lumpur, Malaysia

* Corresponding author; email: tatykamarudin@gmail.com

Received: 16 May 2011

Accepted: 2 November 2011