

CASE REPORT

Primary Thyroid Lymphoma: Two Different Presentations of a Rare Disease

Azlin I¹, Leong CF¹, NH Hamidah¹, Sharifah NA¹, Isa MR¹, Rohaizak M²

Departments of ¹Pathology and ²Surgery, Faculty of Medicine, Universiti Kebangsaan Malaysia, Jalan Yaacob Latiff, Bandar Tun Razak, 56000 Cheras, Kuala Lumpur.

ABSTRAK

Limfoma tiroid primer merupakan penyakit kanser yang jarang berlaku. Ia merangkumi 2% daripada keseluruhan limfoma malignan dan kurang daripada 5% daripada limfoma tiroid. Ia adalah penyakit yang sangat agresif dan merbahaya. Kebanyakan limfoma tiroid terdiri daripada limfoma 'non-Hodgkin' yang berasal dari sel limfoid B. Majoriti kes-kes berlaku dikalangan wanita enam puluhan. Kami melaporkan dua kes limfoma tiroid primer dengan memberi penekanan terhadap isu-isu klinikal dan kesulitan menangani penyakit ini. Kedua-dua pesakit datang ke hospital dengan kesukaran pernafasan yang memerlukan pembedahan. Keberkesanan radioterapi, kemoterapi, pembedahan dan penggunaan antibodi monoklonal masih lagi didebatkan. Peranan pembedahan di dalam menangani kes limfoma tiroid primer sudah banyak berubah namun peranannya yang penting di dalam kes-kes kecemasan tidak boleh diketepikan. Kedua-dua pesakit yang dilaporkan perlu menjalani pembedahan kecemasan tetapi hanya seorang sahaja yang telah menerima rawatan tambahan kemoterapi dan radioterapi. Kedua-dua kes ini memaparkan kesukaran di dalam pengurusan kes limfoma tiroid primer.

Kata kunci: limfoma tiroid primer, kanser tiroid, limfoma malignan

ABSTRACT

Primary thyroid lymphoma is a rare disorder accounting for about 2% of all malignant lymphomas and less than 5% of thyroid malignancies. It is an aggressive disease with poor outcome. The majority of thyroid lymphomas are non-Hodgkin lymphomas of B-cell origin. Majority of cases occur in women in the sixth decade. We report two cases of primary thyroid lymphoma and highlight the clinical issues and challenges posed by this rare disease. Both cases presented with respiratory obstructive symptoms that required surgical intervention. The optimal management for a primary thyroid lymphoma be it chemotherapy, radiotherapy, surgery or monoclonal antibodies is still debatable. The role for surgery has evolved through the years but its importance in emergency situations should not be overlooked. Both our patients had to undergo surgery but only one patient received additional chemotherapy and radiotherapy. These two case reports illustrated the difficulties in managing this rare disorder.

Key words: primary thyroid lymphoma, thyroid malignancies, malignant lymphoma

Address for correspondence and reprint requests: Dr Azlin Ithnin, Department of Pathology, Faculty of Medicine, Universiti Kebangsaan Malaysia, Jalan Yaacob Latiff, Bandar Tun Razak, 56000 Cheras, Kuala Lumpur. Tel: 603-9145 5837. Fax: 603-9173 6676. Email: nazlin@ppukm.ukm.my

INTRODUCTION

Primary thyroid lymphoma is a rare disorder accounting for about 2% of all malignant lymphomas in general and less than 5% of thyroid malignancies (Sippel et al. 2002). Approximately 50-80% of primary thyroid lymphomas is of B-cell origin; which is the diffuse large cell type. The mucosa-associated lymphoid tissue (MALT) lymphomas, the more indolent lymphomas, account for 6 - 27% of thyroid lymphomas (Widder & Pasiëka 2004). The most common clinical presentation of thyroid lymphoma is a rapidly enlarging thyroid mass associated with compressive symptoms (Sippel et al. 2002, Abdel et al. 2001) namely dyspnea, dysphagia and pain. Patients are usually elderly with a peak incidence in the sixth decade (Ha et al. 2001) and have a female preponderance (Sippel et al. 2002, Tupchong et al. 1986, Charles et al. 2002). These tumours are noted to be almost always arising in the background of Hashimoto's thyroiditis (Sippel et al. 2002).

Management of thyroid lymphomas has evolved over the last 20 years from having the surgeons as major players for removal of obstructive symptoms to the more current approach of non-invasive chemotherapy and external beam radiation. Nevertheless, surgery still plays an important role as demonstrated by several studies (Sippel et al. 2002, Widder & Pasiëka 2004). Optimal treatment for primary thyroid lymphoma continues to be a colourful debate amongst clinicians.

CASE REPORT

Patient 1

A 65-year-old Chinese man was referred for a progressively enlarging thyroid mass of 4 months' duration, associated with hoarseness of voice and respiratory obstructive symptoms. He had no history

of fever, night sweats, loss of weight or loss of appetite.

On physical examination, he was a well built gentleman with a large neck swelling. His blood pressure was 130/80 mmHg and pulse rate was 90 per minute. There were multiple enlarged cervical lymph nodes but no other abnormalities were found. His full blood count and serum biochemistry was normal except for a mild elevation of lactate dehydrogenase (LDH) levels (644 U/L).

Assessment by the otolaryngologist revealed a large multinodular goiter with retrosternal extension and bilateral vocal cord involvement. Fine needle aspiration cytology of the anterior thyroid swelling showed features consistent with poorly differentiated malignant tumour with possibilities that include malignant lymphoma and anaplastic carcinoma.

Following the biopsy, he developed sudden onset of acute obstructive respiratory symptoms which led to an emergency debulking of his thyroid mass and tracheostomy. The histopathological examination of the thyroid tissue showed diffuse infiltration by large malignant cells arranged in sheets. The malignant cells exhibit pleomorphic vesicular nuclei and occasional prominent nucleoli. Immunohistochemically, the malignant cells expressed B cell markers (CD20 and CD79 α) and were negative for creatinine kinase and T cell markers (CD3 and CD45Ro) and this confirmed the diagnosis of diffuse large B-cell lymphoma with extra thyroidal extension.

Staging bone marrow aspiration and trephine biopsy showed no marrow infiltration by lymphoma cells. Computed tomography (CT) scan of the neck and thorax showed a large thyroid mass with retrosternal extension, multiple cervical lymphadenopathy, narrowing of the vocal cord and thickening of the larynx due to lymphomatous infiltration of the larynx.

The patient was started on chemotherapy consisting of rituximab, cyclophosphamide, doxorubicin, vincristine and prednisolone (R-CHOP) two weeks after debulking of his tumour. During the post chemotherapy period, he developed upper gastro-intestinal bleeding, left temporo-parietal infarct, and nosocomial pneumonia with Methicillin Resistant *Staphylococcus aureus*. However, he recovered from the complications after a prolonged stay in the hospital. After completing his sixth R-CHOP, a gallium scan was performed which showed an increased uptake in the right side of the superior mediastinum and hilar region. He was given another two cycles of R-CHOP, but a repeat gallium scan showed persistent uptake with similar pattern and intensity and then radiotherapy was planned as the next choice of treatment for this patient.

Patient 2

A 68-year-old Malay lady who initially presented with a sudden increase in thyroid gland size, associated with pain and acute upper airway obstruction. An urgent CT scan showed a thyroid mass with retrosternal extension and left internal jugular vein invasion with thrombosis. There was no mediastinal lymph node enlargement. She did not present with any B symptoms such as fever, night sweats or loss of significant body weight. An emergency modified radical neck dissection was performed and the left internal jugular vein was ligated. The histopathological examination revealed diffuse large B-cell lymphoma of the thyroid gland (Figure 1).

One week later, she developed left arm swelling and pain. An ultrasound Doppler showed evidence of left subclavian and axillary vein thrombosis. She was started on warfarin tablets 2 mg daily and was referred to our centre for chemotherapy. However, she only turned up at our hos-

pital two weeks later with dysphagia to solid food, neck swelling and left neck pain. Physical examination showed a large left neck swelling which was firm and tender. There was also a thyroidectomy scar present. Her blood pressure was 160/90 mmHg and her pulse rate was 95 beats per minute. Examination of other systems was normal. Her full blood count and serum biochemistry were normal except for a highly elevated lactate dehydrogenase level ($> 12,000$ U/L) and a slightly increased serum uric acid (577 $\mu\text{mol/L}$). Her thyroid function test showed hypothyroidism (free T4: <5.15 pmol/L, thyroid stimulating hormone: 69.41 $\mu\text{IU/ml}$). No bone marrow assessment was done previously.

A direct laryngoscopy showed a swollen epiglottis and left vocal cord palsy. The patient was planned for a tracheostomy prior to chemotherapy. Unfortunately, she collapsed in the ward a day after admission, was resuscitated, and required intensive care unit nursing. A CT angiography showed pulmonary embolism involving the right main, ascending and descending pulmonary arteries. Her stay in the intensive care unit was complicated by bleeding following anticoagulant therapy, a deteriorating renal function, septicaemia with *Staphylococcus aureus* and hypothyroidism. Her renal function deteriorated further and she continued to bleed despite continuous support with blood products. Her coagulation profile was persistently prolonged (PT: 22.4 seconds, INR: 1.85, APTT: >180 seconds). CT scan of the brain showed gross oedema secondary to hypoxic brain injury. She finally succumbed to her illness one week post admission.

DISCUSSION

Malignant tumours of the thyroid in general are not very common. The incidence accounts for 1-2 cases per 100,000 people (Sippel et al. 2002). Of these,

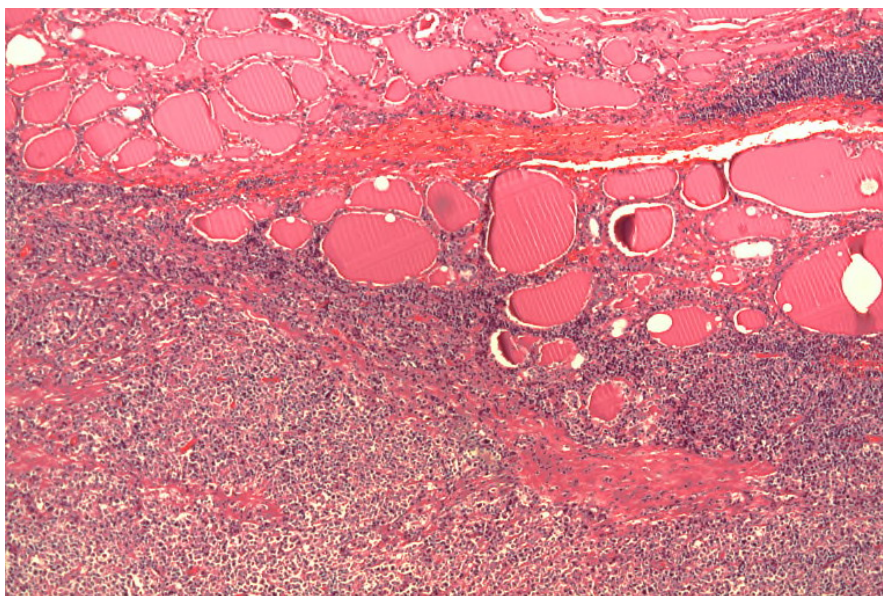


Figure 1: Diffuse infiltration of thyroid tissue with lymphoid cells. H&E (x40)

thyroid lymphomas only account for less than 5% of thyroid malignancies and 2% of all malignant lymphomas (Sippel et al. 2002). They commonly present with a rapidly enlarging neck mass, often causing obstructive symptoms as in both of the cases presented. It occurs more frequently in women than men (Sippel et al. 2002; Tupchong et al. 1986; Charles et al. 2002), in keeping with the predilection of thyroid disease for women in general.

Thyroid lymphoma is frequently associated with Hashimoto's thyroiditis (Abdel et al. 2001) which is not evident in both cases mentioned. There are however, case series which report the association of thyroiditis to be between 25-75% (Abdel et al. 2001). It is hypothesized that chronic antigenic stimulation secondary to autoimmune disorders leads to chronic proliferation of lymphoid cells, which eventually undergo mutation resulting in clonal proliferation and development of lymphoma (Moshynska & Saxena 2008). However, not all patients with Hashimoto's thyroiditis develop lymphoma of the thyroid gland.

The International Prognostic Index (IPI) is used to predict the risk of disease recurrence and overall survival by taking into account factors such as age, stage of disease, performance status, number of extranodal sites, and the presence or absence of an elevated serum lactate dehydrogenase (LDH) (The International Non-Hodgkin's Lymphoma Prognostic Factors Project 1993). This is used generally to predict survival in patients with non-Hodgkin's lymphoma. Based on this system, both patients described above have an IPI score of 2 (age and elevated LDH) which places them in the low/intermediate risk. A study done by Ha et al. (2001) tested the usefulness of the IPI in predicting the prognosis of patients with thyroid lymphoma. The 5-year survival rate for patients with an IPI of 0 was 86% versus 50% for patients with an IPI of greater than 0. The data included patients treated with radiation alone, chemotherapy alone, or combined-modality therapy. A different study (Abdel et al. 2001) of 60 patients with thyroid lymphoma showed that mediastinal involvement and performance

status was the most important independent prognostic factors influencing relapse-free survival and overall survival.

Primary thyroid lymphoma is uncommon and its optimum management has always been a controversial issue. As the number of cases is small, mainly in the form of case reports, there is lack of randomized prospective studies and thus different treatment protocols are being practised. In the past, surgery played a major role in the diagnosis and treatment of thyroid lymphoma (Abdel et al. 2001). This still hold true for cases of localized mucosa-associated thyroid (MALT) lymphoma where there is a complete response rate of more than 90% (Widder & Pasiaka 2004). Surgery also plays an important role in the early control of symptoms especially in patients with severe airway obstruction or those with severe pain (Sippel et al. 2002). A retrospective study of 46 cases by Tupchong et al. (1986) showed that patients with total macroscopic removal of the tumour had the highest rate of local control and has a long survival rate when compared to those receiving radiotherapy alone. However, in these cases the disease was limited to the thyroid and cervical lymph nodes.

The more common type of thyroid lymphoma is diffuse large B-cell lymphoma (DLBCL) which is aggressive and usually presents with disseminated disease as shown in the present cases. The surgical risks for these patients are considerable which includes operative mortality, nerve injuries (recurrent laryngeal), hypoparathyroidism and possible damage to the trachea, esophagus and large vessels. With the advent of fine needle aspiration cytology, flow cytometry and immunohistochemical analysis; it is possible to avoid unnecessary surgical intervention for tissue diagnosis (Charles et al. 2002). Furthermore, combination therapy of radiation and chemotherapy without extensive surgery is associated with an

equal or a superior 5 year survival rate without the additional risks of surgery (Abdel et al. 2001).

In the present cases, both patients underwent emergency thyroidectomy to relieve the obstructive symptoms. In the first case, the patient received a combination of rituximab and CHOP. Rituximab is a chimeric monoclonal antibody that targets CD20 antigen expressed on B-cells. The use of rituximab in combination with the standard chemotherapy protocol has been shown to have significant survival benefit and improvement of patient outcome in DLBCL (Feugier et al. 2005). In this randomized study, rituximab combined with CHOP was compared to CHOP alone in patients aged more than 60 years with diffuse large B-cell lymphoma and CD20-positivity. The combination of rituximab and CHOP improved rates of complete response, failure-free survival, and survival. Although this study does not look at primary thyroid lymphoma per se, it may be assumed that rituximab will benefit any lymphomas with CD20 positivity as it specifically targets these antigens that are present on B-cells. Our patient received 8 cycles of the combination chemotherapy and survived for 12 months from the time of presentation.

The second case was more complicated since the patient had concomitant thrombosis, initially involving the left internal jugular vein which developed into a left subclavian and axillary thrombosis post-operatively. Following that, she developed pulmonary embolism in the ward. The acute coronary syndrome that she had prior to collapse may have been due to another thrombosis within the coronary vessels itself. This added to the difficulty in her management. Anticoagulant was needed to prevent further thromboembolism but she developed bleeding complications. If chemotherapy was started earlier, she might have benefited from the reduced tumour burden.

The bulk of her tumour may have contributed to the stasis of blood within her vessels and caused the repeated episodes of thrombosis. A second surgery was not an option at this time as she was haemodynamically unstable. Her prognosis may have been better if chemotherapy was started immediately after debulking of her tumour initially.

We describe two cases of primary thyroid lymphoma that presented with an enlarging thyroid mass and had to undergo emergency thyroidectomy. Both had similar presentations but with different outcomes. Treatment options for primary thyroid lymphoma include combined therapy with surgery playing a minimal role for diagnosis but a crucial role for compromised airway secondary to an enlarging thyroid mass. Addition of a monoclonal antibody may increase survival risk for patients who are rapidly diagnosed and commenced early treatment.

REFERENCES

- Abdel, A., Ayman, A., Alaa, K., Gamal, E.H., Yasser, K., Nasser, A.R., Gamal G., Dahish A., Alan A., Henrik S. & Adnan E. 2001. Primary thyroid lymphoma. A retrospective analysis of prognostic factors and treatment outcome for localized intermediate and high grade lymphoma. *Am J Clin Oncol* **24**(3): 299-305.
- Charles, C., Herbert, C., William, H. & Robert, U. 2002. Primary thyroid lymphoma: Can the diagnosis be made solely by fine-needle aspiration? *Ann of Surg Oncol* **9**(3): 298-302.
- Feugier, P., Van Hoof, A., Sebban, C., Solal-Celigny, P., Bouabdallah, R., Fermé, C., Christian, B., Lepage, E., Tilly, H., Morschhauser, F., Gaulard, P., Salles, G., Bosly, A., Gisselbrecht, C., Reyes, F., Coiffier, B. 2005. Long-term results of the R-CHOP study in the treatment of elderly patients with diffuse large B-cell lymphoma: a study by the Groupe d'Etude des Lymphomes de l'Adulte. *J Clin Oncol* **23**(18): 4117-4126.
- Ha, C.S., Shadle, K.M., Medeiros, L.J., Wilder, R.B., Hess, M.A., Cabanillas, F. & Cox, J.D. 2001. Localized non-Hodgkin lymphoma involving the thyroid gland. *Cancer* **91**(4): 629-635.
- Moshynska, O.V. & Saxena, A. 2008. Clonal relationship between Hashimoto thyroiditis and thyroid lymphoma. *J Clin Pathol* **61**(4): 438-444.
- Sippel, R.S., Gauger, P.G., Angelos, P., Thompson, N.W., Mack, E. & Chen, H. 2002. Palliative thyroidectomy for malignant lymphoma of the thyroid. *Ann Surg Oncol* **9**: 907-911.
- Tupchong, L., Hughes, F. & Harmer, C.L. 1986. Primary lymphoma of the thyroid: clinical features, prognostic factors, and results of treatment. *Int J Radiat Oncol Biol Phys* **12**(10): 1813-1821.
- Widder, S. & Pasiaka, J.L. 2004. Primary thyroid lymphomas. *Curr Treat Options Oncol* **5**(4): 307-313.