

CASE REPORT

Oncocytic Schneiderian Papilloma: A Rare Sinonasal Papilloma Removed via Endoscopic Medial Maxillectomy

Faizah AR¹, Mazita A¹, Marina MB¹, Jeevanan J¹, Isa MR²

Department of ¹Otorhinolaryngology and ²Pathology, Faculty of Medicine, Universiti Kebangsaan Malaysia, Kuala Lumpur

ABSTRAK

Papiloma sinonasal terdiri daripada tiga jenis iaitu 'inverted', 'fungiform' dan onkositik. Papiloma onkositik merupakan jenis yang jarang berlaku dan ianya lebih kerap terjadi kepada mereka yang telah lanjut usia. Secara klinikal, kelakuannya menyerupai jenis papiloma 'inverted' kerana mempunyai risiko tinggi mengalami rekuren serta mengandungi komponen malignan. Kami melaporkan seorang pesakit yang mempunyai ketumbuhan papiloma onkositik yang berasal dari sinus maksila sehingga ke kaviti hidung dan nasofarink. Walaupun ketumbuhan ini telah wujud dalam jangkawaktu yang lama tetapi tiada komponen malignan yang ditemui. Pembedahan endoskopi maksilektomi medial telah dilakukan untuk membuang ketumbuhan tersebut dengan jayanya. Secara kesimpulannya, diagnosa papiloma onkositik perlu dipertimbangkan pada pesakit lanjut usia yang mempunyai polip hidung sebelah. Tambahan pula, pembedahan endoskopi maksilektomi medial merupakan kaedah pembedahan yang dapat memberikan keputusan yang memuaskan.

Kata kunci: papiloma onkositik, endoskopi maksilektomi medial

ABSTRACT

There are three types of papilloma which arises from the Schneiderian membrane namely inverted, fungiform and oncocytic. Oncocytic papilloma is the rarest type and occurs predominantly in the older age group. Clinically, its behaviour is similar to inverted papilloma in having both local recurrence and associated malignancy. We report a rare case of oncocytic papilloma arising from the maxillary sinus, extending into the nasal cavity and nasopharynx, in a 78-year-old lady. Despite the longstanding history there was no evidence of associated malignancy in this lesion. An endoscopic medial maxillectomy was successfully utilized for approach and complete tumour excision. In conclusion, oncocytic papilloma should be considered as a differential diagnosis in patients presenting with unilateral polypoid nasal lesions especially in the elderly. In addition, endoscopic medial maxillectomy can provide an adequate approach for complete tumour removal.

Key words: oncocytic papilloma, endoscopic medial maxillectomy

Address for correspondence and reprint requests: Dr Mazita Ami, Department of Otorhinolaryngology, Faculty of Medicine, Universiti Kebangsaan Malaysia, Jalan Yaacob Latif, Bandar Tun Razak, 56000 Cheras, Kuala Lumpur. Tel: 603-91456045. Fax: 603-91737840. Email: mazitaami@yahoo.com

INTRODUCTION

Fungiform papilloma, inverted papilloma and oncocytic Schneiderian papilloma are three morphologically separate lesions arising from the Schneiderian membrane (Hyams 1971). Oncocytic type is the rarest which comprises about 3-5% and occurs mostly in patients over 50 years of age (Cunningham et al. 1987). Characteristic histological appearance of multilayered eosinophilic epithelium with mixed exophytic and inverted growth pattern differentiates this tumour from the other type of papillomas. The clinical behavior is similar to inverted papilloma but has a higher rate of local recurrence and malignant transformation (Kaufman et al. 2002).

CASE REPORT

A 78 year old lady presented with recurrent unilateral epistaxis associated with progressive nasal blockage for six years. She denied facial numbness or visual symptoms. Clinically there was no ophthalmoplegia. Nasal endoscopy showed a friable mass arising from the left middle meatus filling the nasal cavity and nasopharynx (Figure 1). Otherwise, ear, throat, head and neck examination was unremarkable.

An intranasal biopsy was taken which showed histological features of oncocytic papilloma. Computed tomography of the paranasal sinuses showed a soft tissue mass filling the left maxillary antrum, extending into the nasal cavity and nasopharynx with widening of the maxillary ostium. There was no bony erosion noted which would suggest malignancy.

The patient underwent an endoscopic medial maxillectomy for tumour excision. Intraoperative findings revealed that the tumour mass was occupying the left nasal cavity with its attachment within the maxillary sinus. The surgery started with debulking of the tumour with a powered

microdebrider until visualization of the tumour protruding through the maxillary ostium. The procedure then entailed a radical inferior turbinectomy following which an L-shaped osteotomy was performed. The vertical limb corresponded to the anterior wall of the maxilla and the horizontal limb corresponded to the floor of the maxillary sinus. The tumour was then removed using a microdebrider and its origin traced to the posteromedial wall of the maxillary sinus. Complete tumour excision was achieved with preservation of healthy surrounding mucosa.

Histopathological examination of the specimen revealed multiple polypoidal tissue with a central core of connective tissue composed of proliferating columnar epithelial cells with admixture of mucin containing cells and numerous microcysts (Figure 2) which was consistent with the diagnosis of oncocytic papilloma. There was no evidence of malignancy in the multiple samples of the surgical specimen.

The patient had an uneventful postoperative recovery. She was last seen at six months post operatively and there was no recurrence noted.

DISCUSSION

Oncocytic papilloma (OCP) is derived from the Schneiderian membrane and is also called cylindrical cell papilloma or columnar cell papilloma (Hyams 1971). The etiology for OCP is unknown. There is no sex predilection, unlike in inverted and fungiform types which occur predominantly in males.

The most common presenting features are unilateral nose block and intermittent epistaxis. OCP always occurs unilaterally, usually arising from or involving the maxillary sinus (Barnes & Bedetti 1984; Hyams 1971) in contrast to inverted papilloma which often arises from the lateral nasal wall (Lawson et al. 1995).

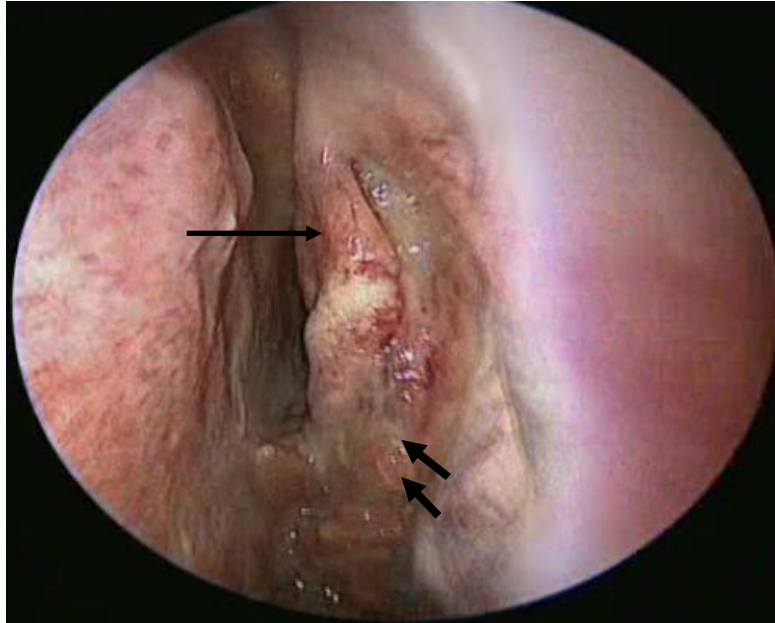


Figure 1: Endoscopic picture of the left nasal cavity which shows a polypoidal fleshy mass (double arrows) arising from the middle meatus and extending into the nasopharynx (single arrow pointing to the middle turbinate).

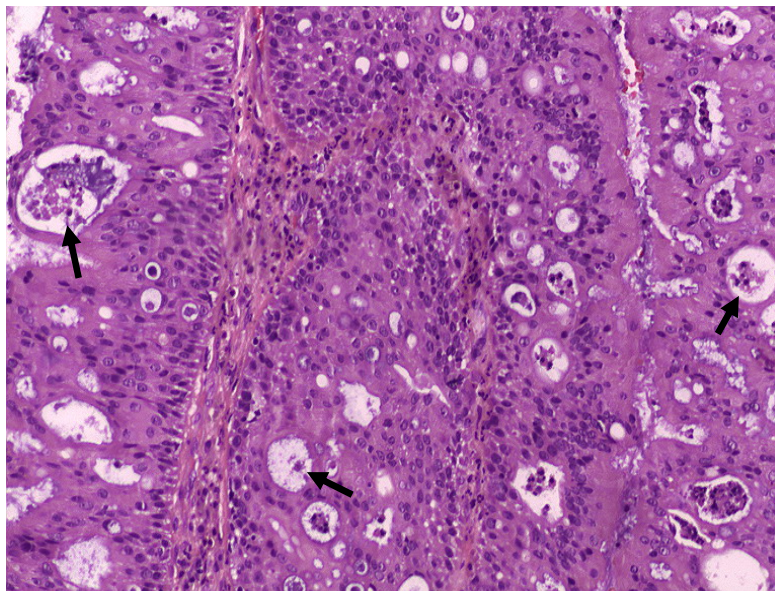


Figure 2: Histological section of the tumour shows multilayers of proliferating columnar epithelium with presence of microcysts (arrows).

Grossly, OCP appears as a fleshy pink papilloma or grey polypoidal growth. The classic histologic description of OCP is the presence of both exophytic and inverted growth patterns, composed of multilayers of columnar cells with eosinophilic cytoplasm and small uniform dark nuclei. The epithelial cells of OCP are true oncocytes from the sinonasal respiratory epithelium - hence the term oncocytic Schneiderian papilloma was used. The epithelium characteristically contains small cysts filled with mucin or neutrophils (microabscess) (Barnes & Bedetti 1984; Hyams 1971).

OCP has similar clinical behaviour with the inverted type which includes a propensity for local invasiveness, recurrence and malignant transformation. Although OCP is relatively uncommon, they have a higher rate of recurrence and malignant transformation. The recurrence rate is 33% versus 15% and malignant change is 17% versus 9% in OCP compared to inverted papilloma (Kaufman et al. 2002). The most frequent type of malignancy is invasive squamous cell carcinoma. As in inverted papilloma, the carcinoma may arise within the papilloma as evidenced by a degradation of histologic changes ranging from dysplasia to carcinoma in situ to invasive carcinoma or simply a coexistence of carcinoma with papilloma at the same anatomical site.

Complete resection of this tumour is advocated in view of the high recurrence rate and possibility of missing an associated carcinoma. Much has been written on the advantages of endoscopic medial maxillectomy over the external approach. Endoscopic approach has superior magnification and angled view for better visualization and delineation of tumour margins. Endoscopic sinus surgery including endoscopic medial maxillectomy is a viable primary treatment alternative for sinonasal inverted papilloma with comparable recurrence rates to external approaches (Wormald et al. 2003; Nicolai et

al. 2006). Tumours arising from anteromedial and anterior wall of the maxillary sinus can be addressed by an endoscopic medial maxillectomy in which removal of the medial wall of the maxilla (including the inferior turbinate) up to its anterior wall is performed. It can be combined with a canine fossa puncture to resect disease arising from the lateral wall and floor of the maxillary sinus (Wormald et al. 2003). It can also provide excellent and complete exposure of the maxillary sinus and ethmoids without removing the lamina papyracea, the medial floor of the orbit, the anterior maxillary wall, and the frontal process of maxilla with preservation of the medial palpebral ligament, unlike open medial maxillectomy (Sadeghi et al. 2003). Lack of an external scar, shorter operative time and reduced bleeding reduces morbidity and hospital stay. However, an open approach is advocated in tumours extending into the orbit, frontal sinus and intracranium as well as those with wide attachment within the sinonasal complex (Tufano & Thaler 1999).

In our patient the endoscopic approach was opted in view of the limited tumour extension which was viable for complete excision via the endoscopic technique. Preoperative imaging was also not suggestive of any associated malignancy where an open approach would be advocated. Endoscopic tumour excision also affords shorter hospital stay with no associated morbidity which was ideal in our elderly patient.

Post operative routine endoscopic surveillance is important regardless of the surgical approach to detect early recurrence of tumours that may be harbouring a malignancy.

CONCLUSION

Oncocytic papilloma is uncommon and has a higher rate of recurrence and malignant transformation compared to in-

verted papilloma. It should be considered in the differential diagnosis of unilateral polypoid nasal lesions especially in elderly patients. Endoscopic medial maxillectomy can be the procedure of choice as it is minimally invasive and provides good tumour clearance in selected cases.

REFERENCES

- Barnes, L. & Bedetti, C. 1984. Oncocytic Schneiderian papilloma: a reappraisal of cylindrical cell papilloma of the sinonasal tract. *Hum Pathol* **15**: 344-351.
- Cunningham, M.J., Brantley, S., Barnes, L. & Schramm, V.L.Jr. 1987. Oncocytic Schneiderian papilloma in a young adult: A rare diagnosis. *Otolaryngol Head Neck Surg* **97**: 47-51.
- Hyams, V.J. 1971. Papillomas of the nasal cavity and paranasal sinuses: A clinicopathologic study of 315 cases. *Ann Otol Rhinol Laryngol* **80**: 192-206.
- Kaufman, M.R., Brandwein, M.S. & Lawson, W. 2002. Sinonasal Papillomas: Clinicopathologic Review of 40 Patients with Inverted and Oncocytic Schneiderian Papillomas. *Laryngoscope* **112**: 1372-1377.
- Lawson, W., Ho, B.T., Shaari, C.M. & Biller, H.F. 1995. Inverted papilloma: A report of 112 cases. *Laryngoscope* **105**: 282-288.
- Nicolai, P., Tomenzoli, D., Lombardi, D. & Maroldi, R. 2006. Different endoscopic options in the treatment of inverted papilloma. *Operative techniques in Otolaryngology* **17**: 80-86.
- Sadeghi, N., Al-Dhahri, S. & Manoukian, J.J. 2003. Transnasal Endoscopic Medial Maxillectomy for Inverting Papilloma. *Laryngoscope* **113**: 749-753.
- Tufano, R.P. & Thaler, E.R. 1999. Endoscopic management of sinonasal inverted papilloma. *Am J Rhino* **13**: 423-426.
- Wormald, P.J., Ooi, E., van Hasselt, C.A. & Nair, S. 2003. Endoscopic Removal of Sinonasal Inverted Papilloma Including Endoscopic Medial Maxillectomy. *Laryngoscope* **113**: 867-873.