

CASE REPORT**Concomitant t(8;21) and Trisomy 4 in a Patient with Acute Myeloid Leukemia (AML)**Phan CL¹, Ong TC¹, Chang KM¹, Zubaidah Z², Puteri Jamilatul NMB²¹ *Clinical Hematology Laboratory, Department of Hematology, Hospital Ampang, Jalan Mewah Utara, Pandan Mewah, 68000 Ampang, Selangor, Malaysia*² *Hematology Unit, Cancer Research Center (CaRC), Institute for Medical Research (IMR), Jalan Pahang 50588 Kuala Lumpur, Wilayah Persekutuan, Malaysia***ABSTRAK**

Aberasi t(8;21)(q22;q22) kerap berlaku pada leukemia myeloid akut (18-20%) dan selalunya dikaitkan dengan sub-jenis 'French-America-British (FAB) M2'. Aberasi trisomi 4 jarang berlaku dan ia adalah keabnormalan spesifik yang berlaku pada AML M2 atau M4. Kami melaporkan satu kajian kes daripada seorang wanita berumur 33 tahun di mana diagnosa klinikal dan laporan hematologi menunjukkan leukemia promyelosit akut (APL). Ujian sitogenetik pesakit menunjukkan keabnormalan kromosom melibatkan aberasi t(8;21) dan trisomi kromosom 4. Kehadiran trisomi 4 dengan t(8;21) dalam kes AML jarang berlaku. Kehadiran trisomi 4 dengan t(8;21) tidak mempunyai signifikansi yang jelas tetapi ia berkait dengan prognosis yang kurang baik.

Kata kunci: AML-FAB M2, t(8;21), trisomi 4

ABSTRACT

The t(8;21)(q22;q22) is a frequently occurring aberration in acute myeloid leukemia (AML) (18-20%) and usually correlate with French-America-British (FAB) M2 subtype. Several studies showed that patients carrying this abnormality demonstrated good response to standard chemotherapy but also have a high incidence of disease relapse. Trisomy 4 is a rare and specific chromosomal abnormality occurring in AML M2 or M4 of the FAB subtypes. We report a case of a 33-year-old female with an apparently clinical and hematologic diagnosis of acute promyelocytic leukemia (APL) in whom cytogenetic analysis revealed an abnormal karyotype with trisomy 4, in addition to t(8;21). Trisomy 4 and t(8;21) in a patient with AML is rare. The significance of t(8;21) with trisomy 4 in AML are unclear but patients bearing this abnormality are associated with a poor prognosis.

Key words: AML-FAB M2, t(8;21), trisomy 4

Address for correspondence and reprint requests: Phan Chin Lee, Clinical Hematology Laboratory, Department of Hematology, Hospital Ampang, Jalan Mewah Utara, Pandan Mewah, 68000 Ampang, Selangor. Tel: 603-4289 6532 / 6226 / 6219. Fax: 603-4295 4666. Email: cuapcl@hotmail.com

INTRODUCTION

The t(8;21)(q22;q22) is a frequently occurring aberration in acute myeloid leukemia (AML) (18-20%), and usually correlates with the French-America-British (FAB) M2 subtype (Shinagawa et al. 1999). The translocation involves the *RUNX1* gene on chromosome 21q22 and the *RUNX1T1* gene on chromosome 8q22. The translocation resulted in fusion of transcripts *RUNX1/RUNX1T1* on the derivative of chromosome 8. It is reported that patients with AML carrying the t(8;21)(q22;q22) exhibit good response to chemotherapy with a high remission rate and long-term disease-free survival. However, it may be associated with a high incidence of early relapse in some cases (Shinagawa et al. 1999). Trisomy 4 is a recurrent but rare chromosome abnormality which appears to occur in a broad range of hematologic malignancies, mainly cases of AML with FAB M2 and M4 subtypes, and some cases with M1 and M5 subtypes (Kwong et al. 1993; Shinagawa et al. 1999; Beghini et al. 2000). Trisomy 4 could also be secondary to an environmental mutagen or drug exposure (Shinagawa et al. 1999; Nishii et al. 2003). It may also present with a sole cytogenetic abnormality or concomitantly with other aberrations. The significance of its occurrence is still undefined.

CASE REPORT

We report a case of a 33-year-old female presenting with fever and anemia. Her full blood picture (FBP) showed pancytopenia. The morphology of the circulating blasts showed presence of Auer rods with hypergranulation. Full blood count showed a white blood cell (WBC) count of 2.3×10^9 /L, with a hemoglobin (Hb) concentration of 6.4 g/L and a platelet count of 37×10^9 /L. There was no history of long term medication and toxic

chemical exposure. She was suspected as having AML, FAB M3 (APL). However, the bone marrow aspirate (BMA) was reported as only AML. BMA was sent for cytogenetic analysis to confirm the diagnosis. A trans-retinoic acid (ATRA) regimen was given to her as the initial treatment. She died soon after the diagnosis.

CYTOGENETICS ANALYSIS

Chromosome analysis of bone marrow aspirate was performed using the standard cytogenetic protocol. The karyotype was described according to the International System for Human Cytogenetic Nomenclature (Shaffer & Tommerup 2005). Thirteen metaphases were analysed. Cytogenetic analysis demonstrated 46,XX,+4, t(8;21)(q22;q22) (Figure 1). This finding excluded the diagnosis of AML M3, but indicated that the patient is having AML with trisomy 4 in addition to t(8;21).

DISCUSSION

The t(8;21)(q22;q22) AML present at diagnosis is associated with a better prognosis and generally demonstrated prolonged disease-free survival (Nishii et al. 2003). AML with the t(8;21) is frequently associated with a loss of sex chromosome Y in males and an inactive X in females, and 3.4% of the cases are variant translocations (Shinagawa et al. 1999; Nishii et al. 2003). A case of FAB M2 subtype with anomalies, complex translocation of t(6;21;8) and trisomy 4 have been reported. However, the presence of trisomy 4 has not demonstrated any influence in clinical prognosis (Shinagawa et al. 1999).

Aberrations in chromosome 7 and chromosome 8 are reported to be associated with secondary AML or during clonal progression of AML (Beghini et al. 2000; Trivedi et al. 2008). Trisomy 4 is

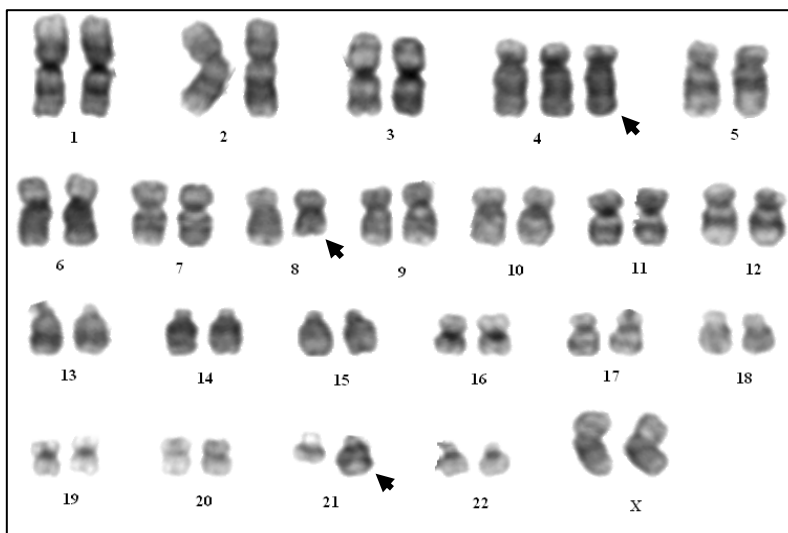


Figure 1: Chromosome rearrangements of t(8;21)(q22;q22) and trisomy 4 (arrows)

rarely reported as the abnormality in AML (<1%) (Trivedi et al. 2008). Nishii et al. (2003) showed that t(8;21) AML with trisomy 4 is very rare. Out of 94 cases, only three were found to have concomitant aberrations of t(8;21) with trisomy 4 (3.2%) (Nishii et al. 2003). t(8;21) AML with trisomy 4 has a poor prognosis and was speculated that the presence of *KIT* mutation may be responsible for the adverse effect of the disease (Langabeer et al. 2003; Trivedi et al. 2008). Few studies have demonstrated that patients with the t(8;21) and a trisomy 4 showed a significantly high frequency of *KIT* mutation (10%) than patients with normal and complex aberrant karyotype (Shimada et al. 2006). Patients with activation of *KIT* gene have been shown to confer drug resistance, which could explain the relatively poor prognosis (Beghini et al. 2000; Langabeer et al. 2003; Shimada et al. 2006). *KIT* is localized at chromosome 4q12, thus trisomy 4 leads to an increased gene dosage of *KIT*. It is believed that the occurrence of t(8;21) represents the initial step to initiate the disease, followed by activation of *KIT* pathway that promotes disease progression (Beghini et al. 2000; Shimada et al. 2006).

In our case, the patient apparently had clinical and hematological features suggestive of acute promyelocytic leukemia (APML) in whom the cytogenetic analysis revealed the presence of trisomy 4 with an additional t(8;21) hence, excluding the diagnosis of APML. Inclusion of cytogenetic analysis in addition to clinical and morphological criteria will produce a reliable clinical diagnosis of the disease. This is because of variable morphology due to the presence of complex or additional chromosomal alteration, also the multiple genetic events which may affect the various maturation stages of cells. Thus, cytogenetic analysis is one of the useful tools to confirm the clinical diagnosis. Detection of the t(8;21) can be further investigated with fluorescence in situ hybridization (FISH) analysis to determine the *AML1* gene rearrangement. Other diagnostic tests include immunophenotyping which may help to identify the subtype of t(8;21) AML.

A study by Nishii et al. (2003) reported that most of the cells carrying trisomy 4 showed low expressions of CD19 and IL-17 receptor, and high expressions of CD33, CD18, and CD 56 when compared to t(8;21) AML without other additional chromosomal abnormality (Nishii et

al. 2003). CD56 expression in AML is reported in multidrug resistance (Trivedi et al. 2008). There was no flow cytometric analysis done in our case. Therefore, we cannot explain the relation between CD56 expression and trisomy 4 in t(8;21) AML.

In conclusion, the present case of AML FAB M2 is a rare case in terms of cytogenetic findings. Concomitant t(8;21) with trisomy 4 may constitute a distinctive subtype of t(8;21) AML (Nishii et al. 2003). Hence the acquisition of trisomy 4 in AML with *AML1* rearrangement might promote disease progression and an unfavourable prognosis. This case illustrated the essential roles of cytogenetics studies in confirming the diagnosis. Cytogenetics analysis provides simultaneous analysis of genetic rearrangements within leukemic cell. Meanwhile FISH analysis approached is a complementary test for conventional cytogenetics that helps to determine the chromosomal rearrangements such as t(8;21), t(15;17) and inv(16) in AML cases.

ACKNOWLEDGMENTS

We would like to thank the Director General of Health Malaysia for permission to publish this paper. We would like to acknowledge the Director of Ampang Hospital, Datin Dr Aishah bt Ahmad Mukinuddin, members of IMR's genetic laboratory for their technical assistance and staff of the Haematology Department, Hospital Ampang for their support.

REFERENCES

- Beghini, A., Ripamonti, C.B., Castorina, P., Pezzetti, L., Doneda, L., Cairoli, R., Morra, E. & Larizza, L. 2000. Trisomy 4 leading to duplication of a mutated KIT allele in acute myeloid leukemia with mast cell involvement. *Cancer Genet Cytogenet* **119**: 26-31.
- Kwong, Y.L., Ha, S.Y., Liu, H.W. & Chan, L.C. 1993. Trisomy 4 may occur in a broad range of hematologic malignancies. *Cancer Genet Cytogenet* **69**: 139-140.
- Langabeer, S.E., Beghini, A. & Lariza, L. 2003. AML with t(8;21) and trisomy 4: Possible involvement of c-kit? *Leukemia* **17**: 1915.
- Nishii, K., Usui, E., Katayama, N., Lorenzo, V.F., Nakase, K., Kobayashi, T., Miwa, H., Mizutani, M., Tanaka, I., Nasu, K., Dohy, H., Kyo, T., Taniwaki, M., Ueda, T., Kita, K. & Shiku, H. 2003. Characteristics of t(8;21) acute myeloid leukemia (AML) with additional chromosomal abnormality: Concomitant trisomy 4 may constitute a distinctive subtype of t(8;21) AML. *Leukemia* **17**: 731-737.
- Shaffer, L.G. & Tommerup, N. 2005. An International System for Human Cytogenetic Nomenclature (2005). Basel: S. Karger.
- Shimada, A., Taki, T., Tabuchi, K., Tawa, A., Horibe, K., Tsuchida, M., Hanada, R., Tsukimoto, I. & Hayashi, Y. 2006. KIT mutations, and not FLT3 internal tandem duplication, are strongly associated with a poor prognosis in pediatric acute myeloid leukemia with t(8;21): A study of the Japanese Childhood AML Cooperative Study Group. *Blood* **107**: 1806-1808.
- Shinagawa, A., Komatsu, T. & Ninomiya, H. 1999. Complex translocation (6;21;8), a variant of t(8;21), with trisomy 4 in a patient with acute myelogenous leukemia (M2). *Cancer Genet Cytogenet* **109**: 72-75.
- Trivedi, P.J., Patel, P.S., Brahmabhatt, M.M., Patel, S.B., Gajjar, S.B., Iyer, R.R., Parikh, E.H., Shukia, S.N., Shah, P.M. & Bakshi, S.R. 2008. A case of acute myeloid leukemia-M2 with trisomy 4 in addition to t(8;21). *India Journal of Human Genet* **14**:20-22.