

ORIGINAL ARTICLE

Otogenic Brain Abscess: A Retrospective Study of 10 Patients and Review of The Literature

Asma A¹, Hazim MYS¹, Marina MB¹, Azizi AB², Suraya A³, Norlaili MT⁴, Mazita A¹, Zahiruddin¹, L Saim¹

Department of ¹Otorhinolaryngology, ²Surgery, ³Radiology and ⁴Family Medicine, Faculty of Medicine, Universiti Kebangsaan Malaysia, Jalan Yaacob Latif, 56000 Cheras, Kuala Lumpur, Malaysia.

ABSTRAK

Rawatan otitis media kronik yang betul boleh mengurangkan insiden abses otogenik otak. Objektif kajian ini adalah untuk menilai profil klinikal, rawatan dan kesan pesakit yang didiagnos dengan abses otogenik otak. Rekod perubatan pesakit di Pusat Perubatan Universiti Kebangsaan Malaysia (PPUKM) yang dirawat sebagai abses otogenik otak dari Januari 1997 sehingga Januari 2006 dianalisa secara retrospektif. Dalam tempoh tersebut seramai lebih kurang 10,800 pesakit mengalami jangkitan telinga tengah kronik mendapat rawatan susulan di Klinik Telinga Hidung dan Tekak, PPUKM. Sepuluh pesakit (2 perempuan, 8 lelaki) dengan purata umur 47 tahun (umur di antara 11 sehingga 69 tahun). Min bagi jangka masa rawatan susulan adalah 14 bulan. Semua pesakit menghadapi kolesteatoma. Kesemua pesakit mempunyai sejarah discaj telinga yang kronik, sakit kepala, sakit telinga dan demam. Enam dari 10 pesakit mempunyai abses serebelar dan 4 mempunyai abses lobus temporal. Kesemua pesakit dirawat dengan antibiotik spektrum luas. Lima pesakit menjalani pembedahan mastoidektomi sebagai rawatan utama manakala abses otak dirawat secara konservatif. Manakala lima pesakit lagi menjalani pembedahan kraniotomi dan pengaliran nanah diikuti dengan pembedahan mastoid apabila fungsi neurologi sudah stabil. Tiada pesakit yang mempunyai tanda serebelar yang kekal ketika rawatan susulan dan tiada kes kematian. Di sini kami menunjukkan bahawa rawatan awal dan tepat bagi pesakit abses otogenik otak memberikan hasil pemulihan neurologi yang baik.

Kata kunci: abses otak otogenik, abses lobus temporal, abses serebelum

ABSTRACT

Proper management of chronic otitis media may reduce the incidence of otogenic brain abscess. The aim of this study was to describe the clinical profile, treatment and surgical outcome of patients presenting with otogenic brain abscess. The medical record of patients in Universiti Kebangsaan Malaysia Medical Centre (UKMMC) with otogenic brain abscess were retrospectively analyzed from January 1997-January 2006. Within this period we had approximately 10,800 of follow up cases of chronic otitis media (COM) in our clinic. Ten patients (2 females, 8 males) with an average age of 42 (age range 11 to

Address for correspondence and reprint requests: Associate Prof Dr Asma bt Abdullah, Department of Otorhinolaryngology, Faculty of Medicine, University Kebangsaan Malaysia, Jalan Yaacob Latif, 56000 Cheras, Kuala Lumpur.

69 years) were identified with otogenic brain abscess and included in this study. The mean follow-up period was 14 months. All patients had cholesteatoma. All patients had a history of chronic ear discharge, headache, otalgia and fever. Six of the 10 patients had cerebellar abscess and 4 had temporal lobe abscess. Cerebellar signs were present in 3 patients. All the patients were treated with broad-spectrum antibiotics. In 5 patients, mastoid exploration was the primary surgical treatment and the brain abscesses were treated conservatively. In the other 5 patients, craniotomy and drainage were performed followed by mastoid exploration when their neurological conditions had stabilized. All our patients had uneventful recovery. There were no permanent cerebellar signs during the follow up and no mortality reported in our series. In this series we demonstrated that early diagnosis and proper treatment of otogenic abscess leads to good neurological outcome.

Key words: otogenic brain abscess, temporal lobe abscess, and cerebellar abscess

INTRODUCTION

The incidence of intracranial complications of chronic otitis media (COM) is estimated to be between 0.02% and 1.97% (Osama et al 2000). The extracranial and intracranial complications occur when chronic infection within the middle ear and mastoid spaces extends to the region beyond the bony confines. Osama et al (2000) reviewed 2890 cases of chronic otitis media from 1990-1999 and found that 57 (1.92%) cases had intracranial complications (IC) and 39 (1.35%) cases had extracranial complications (EC). They observed that meningitis and brain abscess were common amongst the intracranial complications group, whereas subperi-osteal abscesses (mastoid and Bezolt's abscess) were common complications in the extracranial complications group. Despite advances in the development of antibiotics, we still have otogenic brain abscess in our country. Therefore, the aim of this study was to describe the clinical profile, treatment and surgical outcome of patients presenting with otogenic brain abscess.

MATERIALS AND METHODS

Between January 1997 and January 2006, a total of 10,800 cases of chronic otitis media (COM) were followed-up in our clinic. Clinical records of patients in

UKMMC with otogenic brain abscess were reviewed. The data analyzed included age, sex, clinical symptoms, site of abscess, treatment options and complications.

RESULTS

There were 10 patients (2 females, 8 males) with a mean age of 42 (range 11 to 69) years. The mean follow-up period was 14 months. All patients had cholesteatoma. At the first presentation to the ENT Clinic, the patients were treated with a high index of suspicion and an urgent Computerized Tomography (CT) scan was performed. All patients had a history of chronic ear discharge, headache, otalgia and fever (Table I). Six of the 10 patients had cerebellar abscesses (Figure 1) and 4 had temporal lobe abscesses (Figure 2). Cerebellar signs were present in 6 patients. All the patients were admitted and treated with broad-spectrum antibiotics. In 5 patients, mastoid exploration was the primary surgical treatment and the brain abscesses were treated non-surgically. In the other 5 patients, craniotomy and drainage was performed followed by mastoid exploration when their neurological conditions had stabilized. One patient was admitted for 3 weeks for intravenous antibiotics as the brain abscess did not completely resolve after the repeat CT brain. There was no permanent neurological deficit in our pa-

tients during follow up. There was also no mortality in this study. We advocate urgent CT scan of temporal bone and brain to be done and is mandatory in any patients presenting with ear discharge, moderate to severe headache, otalgia and fever.

DISCUSSION

In this study we found cholesteatoma in all our patients with otogenic brain abscesses. They presented with a history of chronic ear discharge, headache, otalgia and fever.

Table 1: Clinical summary of our patients with otogenic brain abscess

Patient	Age (years)	Gender	Duration of ear discharge	Location of abscess	Treatment modality
1	11	Female	15 years	Temporal	M and A
2	45	Male	10 years	Temporal	C,M and A
3	23	Male	11 years	Temporal	C,M and A
4	55	Female	9 years	Cerebellum	C,M and A
5	69	Male	24 years	Cerebellum	M and A
6	45	Male	5 years	Cerebellum	C, M and A
7	31	Male	4 years	Cerebellum	M,C and A
8	43	Male	9 years	Cerebellum	M and A
9	56	Male	10 years	Cerebellum	M and A
10	60	Male	12 years	Temporal	M and A

M:Mastoid exploration
 C:Craniotomy
 A:Antibiotics

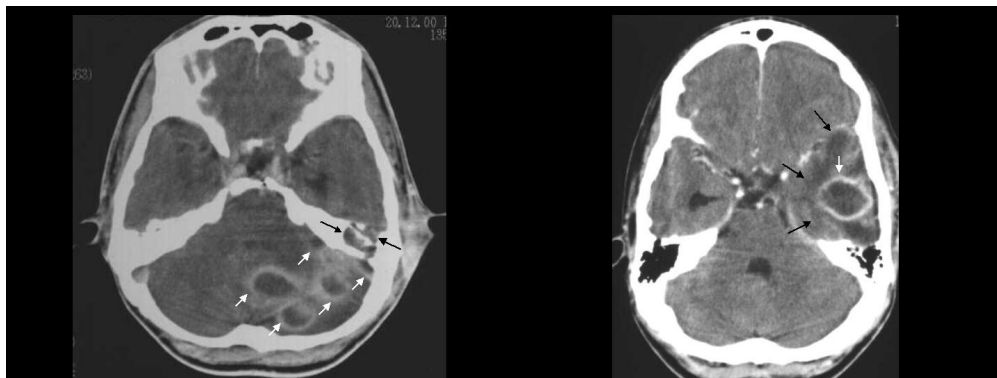


Figure 1

Figure 2

Figure 1: Contrast CT of the brain shows multiple abscesses (white arrows) in the left cerebellum seen as hypodense areas with peripheral ring enhancement. There are areas of bony destruction (black arrows) in the left petrous bone.

Figure 2: Contrast CT of the brain shows an abscess (white arrow) in the left temporal lobe seen as a hypodense area with peripheral ring enhancement. The surrounding hypodensity (black arrows) is due to cerebral edema.

The underlying pathology for cerebellar abscess was cholesteatoma. Cholesteatoma produces enzymes that cause demineralization of bone. The infection can spread through this bony erosion into the posterior cranial fossa (PCF) and cause cerebellar abscess (Nadol and Schuknecht 1993).

The infection also can spread to the PCF through the internal auditory canal (IAC), which opens into it. Another possible route of spread is through inflammation of small veins (thrombophlebitis). Thrombophlebitis can spread in any direction and can cause temporal lobe abscess and other extracranial complications (i.e. mastoid abscess, perisinus abscess, subperiosteal abscess). According to Nadol and Schuknecht (1993) direct extension is the route commonly implicated in complications due to COM. Thrombophlebitis spread is more common in acute infections and in acute exacerbations of chronic infection (Nadol and Schuknecht 1993).

Cerebellar signs were present in all our patients with cerebellar abscess. Gait ataxia and nystagmus were the commonest complaints in this group. However, there were no other cerebellar signs such as dysarthria, dysdiadochokinesia, past-pointing and rebound phenomenon. We advocate that any COM patients with symptoms and signs of impending complications of otitis media should be admitted urgently for parenteral antibiotic and further radiological investigations.

Clinical neurological examination is helpful in the localization of the abscess. Nominal aphasia may be associated with abscesses if located in the dominant temporal lobe. Other signs include quadrantic homonymous hemianopias (involving upper quadrants is more frequent than the lower quadrants) and contralateral limb weakness (Nadol and Schuknecht 1993).

All our patients had a history of fever. Glasscock and Shambaugh (1990) reported that fever in brain abscess, is usually low grade and some patients may have a subnormal temperature. Less than

50% of patients with brain abscess present with the classical triad of fever, headache and neurological deficit (Nadol and Schuknecht 1993). Youngs (1998) and Neely (1986) described signs and symptoms of brain abscess according to the stages of its development. The first stage corresponds to the encephalitis stage that results from the invasion of brain tissue. The symptoms are general malaise, headache, fevers, chills, nausea and vomiting. They are usually quite mild and often mimic an exacerbation of chronic otitis media.

During the second stage or "latent stage" the abscess localizes and the symptoms disappear. The third stage is characterized by signs and symptoms associated with both increased intracranial pressure and compression of specific structures in the brain. Severe headache is present in 50% to 60% of patients (Haines et al 1990). Nausea and vomiting (often projectile) occur in 25% to 50% of cases. About 20% to 30% of patients may present with seizures (Haines et al 1990). Sodden and Koch (2000) reported a child with an otogenic brain abscess presenting with febrile seizures. The third stage of brain abscess progression is when the abscess ruptures into the ventricle or the subarachnoid space. This will result in rapid clinical decline and ultimately death due to severe ventriculitis.

The factors that contribute to the spread of infection beyond the middle ear space depend on the species and virulence of the organism. Other factors are host immune system and prior therapy. Levent and Bulent (2000) reviewed 41 patients with otogenic brain abscess and reported localization in the temporal lobe in 54%, the cerebellum in 44% and in both locations in 2%. None of our patients had abscesses in both locations. They also found that all patients had COM and 95% had cholesteatoma. Jaran et al (1995) from Chiang Mai, Thailand reported 29 patients with otogenic brain abscess secondary to COM of whom 89.7% had cholesteatoma.

Temporal lobe abscesses were seen in 20 (68.9%) and cerebellar abscesses in 9 patients (31.1%). Kurien et al (1998) reported that all their patients had cholesteatoma as in our group.

Laboratory investigations add little to the diagnosis of brain abscess. Britt (1985) reported that total white blood cell (TWBC) might be elevated or normal. CT with intravenous contrast is the imaging modality of choice in screening for complications of COM. It can demonstrate the site of complications, the extent of the abscess, and any bone involvement (Fitzpatrick and Gan 1999). Magnetic resonance imaging (MRI) with contrast and magnetic resonance angiography are useful in the definitive diagnosis of certain intracranial complications such as lateral sinus thrombosis. Both contrast enhanced CT or MRI will demonstrate ring enhancement for brain abscesses (Soden and Koch 2000, Marquadt et al 2000). The abscess is usually encircled by an area of low density representing oedema in the surrounding brain tissue (Fitzpatrick and Gan 1999).

Early treatment of brain abscess is mandatory. Management can be medical alone (intravenous antibiotics). This is usually reserved for patients with small abscesses (< 3 cm in diameter), multiple lesions or those who are at high risk for surgery (Fitzpatrick and Gan 1999). Intravenous antibiotic therapy should be started as early as possible. Polymicrobial infection is common in COM and its complications (Nadol and Schucknecht 1993). Therefore broad-spectrum antibiotic coverage for aerobic and anaerobic organisms is recommended. Combination drug therapy may be necessary to accomplish this goal.

Surgical treatment may involve aspiration or excision of the abscess (Britt 1985). The treatment of the condition is tailored to the clinical presentation of each patient and neurological considerations. The importance of early and appropriate treatment of the abscess cannot be over-emphasized.

In general, however it is desirable to delay surgical treatment of the infected ear until the patient is neurologically and systemically stable. Clinical deterioration and progression of infection despite appropriate medical therapy are indications for earlier surgical intervention (Nadol and Schucknecht 1993). All our patients were treated with broad-spectrum antibiotics (3rd generation cephalosporins). In 50% of our patients mastoid exploration was the primary surgical treatment and the brain abscesses were treated conservatively. In the other 5 patients, craniotomy and drainage was performed followed by mastoid exploration when their neurological condition had stabilized. There was no mortality in this study. All our patients had an uneventful recovery. The mortality rates in other studies were 31% and 10% reported by Jaran et al (1995) and Levent and Bulent (2000) respectively.

CONCLUSION

The primary goal of management of otogenic brain abscess is to overcome the danger of brain abscess either by conservative treatment with antibiotics or surgical drainage. Mastoid explorations are performed only when their neurological condition is stable. A high index of suspicion aided by contrast enhanced CT is important for early diagnosis and treatment.

ACKNOWLEDGEMENTS

The authors wish to express their appreciation to Mr. Kamaruzzaman for his assistance in photography.

REFERENCES

- Britt, R. H. 1985. *Brain abscess*. In Wilkins RH, Rengachary SS, editors *Neurosurgery*., 1928-1956. New York: Mc Graw Hill.
- Fitzpatrick, M. O., Gan, P. 1999. Contrast enhanced computed tomography in the early diagnosis of cerebral abscess. *Br J Med*. **319**: 239-241.

- Glasscock, M. E., Shambaugh, J. R. 1990. *Intra-cranial complication of otitis media*. Surgery of the ear, 4 th edition., 249-275. Philadelphia: WB Saunders.
- Haines, S. J., Mampalam T, Rosenblum M. I., Naqib M. G. 1990 *Cranial and intra-cranial bacterial infection*. *Neurological Surgery.*, 3707-3735. Philadelphia: WB Saunders
- Jaran, K., Niramom, N., Suprannee, F. et al. 1995. Intracranial complications of suppurative otitis media: 13 year's experience. *Am J Otolaryngol* **16**: 104-109.
- Kurien, M., Job, A., Mathew, J., Chandy, M. 1998. Otogenic intracranial abscess: concurrent craniotomy and mastoidectomy-changing trends in developing country. *Arch Otolaryngol Head Neck Surg.* **1249**: 1353-1357.
- Levent, S. and Bulent, S. 2000. Otogenic brain abscess. *Otolaryngol Head & Neck Surg.* **123**: 751-755.
- Marquardt, G., Schick U., Muller, W. 2000. Brain abscess decades after a penetrating shrapnel injury. *Br J Neurosurg.* **14**: 246-248.
- Nadol, J. B., Suhuknecht, H. F. 1993. *Complication of chronic otitis media*. Surgery of the ear and temporal bone., 171-191. Raven press Ltd. New York.
- Neely, J.G. 1986. *Complication of temporal bone infection*. Otolaryngol Head Neck Surg 4 th edition ed. St Louis's., 2988-29915. Mosby.
- Osama, U., Cureoglu, S., Hosoglu, S. 2000. The complications of chronic otitis media: report of 93 cases. *J Laryngol Otol.* **114**: 97-100
- Soden, J., Koch, T. K. 2000. Brain abscess presenting with febrile seizure. *Clin Pediatr.* **39**: 395-408.
- Youngs, R. 1998 *Complications of suppurative otitis media*. Diseases of the ear. Sixth edition., 398-415. Arnold: Hodder headline Group London.