

CASE REPORT

Squamous Cell Carcinoma of the Tongue in A Patient with Rothmund-Thomson Syndrome (Recq4 Mutation)-Intolerance to Radiotherapy

Hamidah A¹, Mazlina M¹, Zarina AL¹, Muhaizan WM², Fuad I³, Jamal R¹

Department of ¹Pediatrics, ²Pathology and ³Radiotherapy, Faculty of Medicine, Universiti Kebangsaan Malaysia, Kuala Lumpur

ABSTRAK

Seorang pesakit sindrom Rothmund-Thomson (RTS) yang berusia 27 tahun telah di diagnosis dengan kanser sel skuamus dasar lidah. Keabnormalan mekanisma pemulihan DNA pada sebahagian pesakit RTS mendorong mereka untuk mendapat kanser dan keadaan ini juga mempengaruhi toleren kepada rawatan radioterapi yang diberikan.

Kata kunci: sindrom Rothmund-Thomson (RTS), kanser sel skuamus dasar lidah, toksisiti radioterapi

ABSTRACT

We report a case of squamous cell carcinoma of the base of the tongue in a 27 years old patient with Rothmund-Thomson syndrome (RTS). An abnormal DNA repair mechanism in some RTS patients predispose them to malignancy and influence the tolerance to radiotherapy.

Key words: Rothmund-Thomson syndrome, squamous cell carcinoma tongue, radiation toxicity

INTRODUCTION

Rothmund-Thomson syndrome (RTS [MIM #268400]) is a rare and severe autosomal recessive genodermatosis. It was first reported in 1868 in a patient with cataract and progressive poikiloderma by the German ophthalmologist Rothmund and subsequently by the British dermatologist, Thomson with the

current eponym introduced in 1957 (Taylor 1957). RTS is diagnosed clinically and the main features include proportionate dwarfism, premature ageing, skin hyperpigmentation appearing within the first semester of life and longlife persisting, poikiloderma, telangiectasia, brittle hair sometimes progressing to total alo-

Address for correspondence and reprint requests: Assoc Prof Dr Hamidah Alias, Department of Pediatrics, Faculty of Medicine, Universiti Kebangsaan Malaysia, Jalan Yaacob Latif, Bandar Tun Razak, 56000 Cheras, Kuala Lumpur. Tel: 603-91455396. Fax: 603-91737827. Email: midalias@ppukm.ukm.my

pecia, dystrophic nails, juvenile cataract, photosensitivity and congenital skeletal defects as hypoplasia or absence of the radii and thumbs. There is a higher than expected incidence of cutaneous and non-cutaneous malignancies particularly osteosarcoma (Vennos et al. 1992, Wang et al. 2001). Several RTS patients have been described to have two malignancies including osteosarcoma and lymphoma (Wang et al. 2001).

Mutations in helicase RECQ4 gene are responsible for a subset of cases of RTS. The RECQ4 gene structure is unusual because it contains many small introns <100bp. Wang et al. (2002) described a proband with RTS who had a novel 11-bp intronic deletion and showed that this mutation results in a 66-bp intron too small for proper slicing. Constraint on intron size may represent a general mutational mechanism in RTS (Wang et al. 2002). This patient and his non-identical twin sister both had a homozygous mutation of the RECQ4 gene which is responsible for the severe phenotype associated with RTS (Balraj et al. 2002). The twin sister developed osteosarcoma of the left humerus at the age of 15. She received chemotherapy and underwent limb salvage surgery. However, she developed metastases in her lungs and succumbed to the disease.

Response to radiotherapy in RTS patients has been variable. An abnormal DNA repair mechanism in some RTS patients predisposes them to malignancy and influence the tolerance of radiotherapy. We are aware of three previous reports of patients with RTS developing squamous cell carcinoma (SCC) of the tongue (Borg et al. 1998, Martin-Bertolin et al. 1998, Dahele et al. 2004). A patient was reported to develop increased radiosensitivity and tissue intolerance to chemotherapy (Borg et al. 1998) while another patient was reported to tolerate radiotherapy without evidence of increased morbidity (Dahele et al. 2004). In

this report, we describe a patient with a history of osteosarcoma who developed SCC of the base of the tongue. He underwent a course of radiotherapy for the SCC of the tongue.

CASE REPORT

The patient is a 27 year-old male, the first twin of a set of non-identical twins. The twins first presented with clinical features of RTS at the age of 10 months. Four generation pedigree showed a high degree of consanguinity, and the parents are first cousins. Molecular analysis showed a homozygous mutation in RECQ4 helicase: 2746-2756-delTGGGCTGAGGC in IVS8 which is responsible for the severe phenotype associated with RTS in both twins, while both parents and the grandmothers were heterozygous. These findings were reported previously by Balraj et al. (2002).

The patient developed multicentric osteosarcoma of the left humerus and right upper tibia at the age of 14 years. The tumor in the right upper tibia was resected and allogenic bone grafting was performed. Subsequently, he received chemotherapy and later limb salvage surgery was performed for the tumor in the left humerus. However, he had to undergo an above knee amputation of the right leg as the site of the bone graft was infected with avascular necrosis and detachment of the proximal part of the bone graft. He did not receive radiotherapy during the treatment for osteosarcoma. He was disease-free for 10 years following therapy.

On follow-up he was noted to have right submandibular lymphadenopathy of 2.5cm x 2.0cm but defaulted referral for a biopsy. Three months later he was admitted for enlarging right neck swelling associated with right tongue pain and difficulty in eating. There was a history of intermittent fever, lethargy, and loss of weight (height 141.5cm, weight dropped

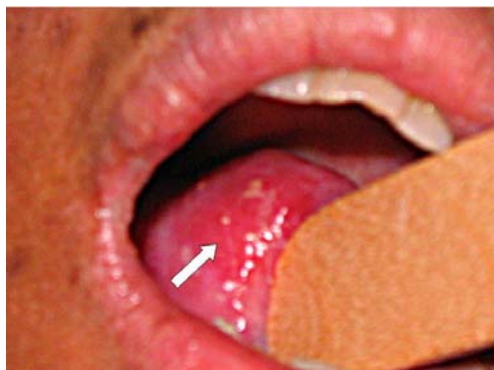


Figure 1: There is an ulcer at the right side of the posterior base of the tongue.

from 26.3kg to 25.1kg, BMI dropped from 13.2 to 12.6). Physical examination revealed a 3.0cm x 3.5cm ulcer at the right side of the posterior base of his tongue (Figure 1). Biopsy of the ulcer confirmed the presence of a well-differentiated SCC (Figure 2). It was staged as T2N2CM0 according to the 1998 American Joint Committee on Cancer (AJCC) staging system (American Joint Committee on Cancer, 1998).

Tumor excision was not performed in view of the extension of the tumor and

his poor clinical condition. The patient was then advised for radiotherapy. In the first phase of radiotherapy the primary tumor and neck was treated to a total dose of 40 Gy in 20 fractions at 2.0 Gy per fraction. The patient developed severe mucositis requiring regular intravenous morphine, oral toilet and liquid nutritional supplement and the treatment schedule was interrupted. After introduction of spinal cord shielding in the second phase of treatment, the primary tumor and neck was boosted with a further 26 Gy in 13 fractions. Subsequently the right neck was treated with a boost of 10 Gy in 5 fractions. The overall treatment time was extended to 63 days from a planned 42 days because of toxicity-related breaks and patient non-compliance. The tumor size reduced to approximately 0.5cm x 0.5cm at completion of radiotherapy. The patient developed severe mucositis with skin desquamation in the treated area (Figure 3) following treatment. Local site infection was successfully treated with antibiotics. The toxicity symptoms subsided two months after completion of radiotherapy. Unfortunately,

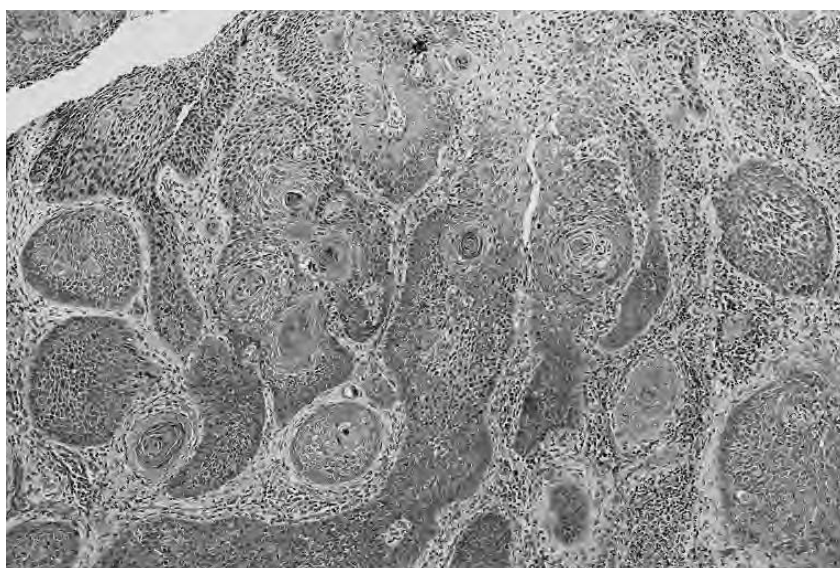


Figure 2: The section shows islands of well-differentiated squamous cell carcinoma (Hematoxylin and eosin stain, x40).

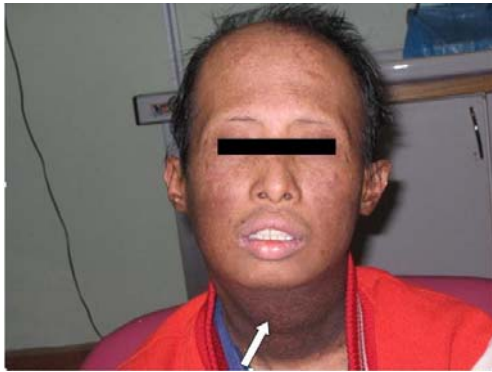

Figure 3: Radiation-induced cutaneous reaction with inflamed skin, hyperpigmentation and areas of skin breaks in the neck after completion of treatment.

the tumor recurred and the patient died 16 months after diagnosis of SCC.

DISCUSSION

We believe that in our patient, the severe phenotype was responsible for the multiple malignancies. In addition, being a chronic cigarette smoker increased his relative risk of SCC in the tongue. Cancers of the head and neck show a strong association with alcohol consumption and smoking, particularly cigarettes. This patient however did not have a history of alcoholism. The severe phenotype, chronic cigarette smoking, and previous chemotherapy for treatment of osteosarcoma had most likely played a role in the pathogenesis of the tongue cancer in this patient.

In addition, we found that our patient had a severe toxicity from radiotherapy. A similar finding was reported by Borg et al. (1998) in a patient with an advanced tumor who had greater than expected postoperative radiotherapy toxicity, and the dose per fraction as well as the total dose was reduced (from 1.8 to 1.65 Gy per fraction and total dose from 66.6 Gy to 58.55 Gy). The treatment time in this report was also extended from 45 to 71 days as a result of the toxicity. In contrast, Dahele et al. (2004) described a

patient with SCC of the tongue who tolerated postoperative radiotherapy well, without evidence of increased early or late radiation morbidity. The patient received radiotherapy at a total dose of 50 Gy in 25 fractions over 5 weeks without undue toxicity. Given the heterogeneity in the syndrome, it is possible that patients' susceptibility to radiation toxicity also varies. Reports on abnormal DNA repair after irradiation in RTS could explain for excess treatment toxicity in some patients.

Recently, Hicks et al. (2007) reported that the clinical behaviour of patients with RTS and osteosarcoma is similar to patients with sporadic osteosarcoma, and suggested that these patients should initially be treated with conventional doses of chemotherapy as prescribed by current protocols. However, five patients were reported to require chemotherapy dose modifications, most commonly due to mucositis from doxorubicin (Hicks et al. 2007). Therefore, careful clinical observation is needed to monitor for enhanced doxorubicin sensitivity in RTS patients. It is apparent that some RTS patients have abnormal DNA repair mechanisms that could lead to increased toxicity to radiotherapy and chemotherapy. Therefore a complete screening for malignancies of RTS patients are important to identify those patients who are prone to develop cancer and are therefore likely to experience increase treatment morbidities. The present case illustrates the importance of regular follow-up of all RTS patients and screening those who are prone to develop cancer.

REFERENCES

- American Joint Committee on Cancer: AJCC Cancer Staging Handbook (ed 5). 1998. Philadelphia, PA, Lippincott-Raven; 38-39.
- Balraj, P., Concannon, P., Jamal, R., Beghini, A. Hoe, T.S., Khoo, A.S. & Volpi, L. 2002. An unusual mutation in RECQ4 gene leading to

- Rothmund-Thomson syndrome. *Mutation Research* **508**:99-105.
- Borg, M.F., Olver, I.N. & Hill, M.P. 1998. RTS and tolerance of chemoradiotherapy. *Australas Radiol* **42**:216-218.
- Dahele, M.R., Benton, E.C., Hennessy, A., MacDougall, R.H., Price, A., Mitchell, R. & Watson, J. 2004. A patient with Rothmund-Thomson syndrome and tongue cancer – experience of radiation toxicity. *Clinical Oncology* **16**:371-372.
- Hicks, M.J., Roth, J.R., Kozinetz, C.A. & Wang, L.L. 2007. Clinicopathological features of osteosarcoma in patients with Rothmund-Thomson syndrome. *J Clin Oncol* **25**:370-375.
- Martin-Bertolin, S., Amorrortu-Velayos, J. & Aliaga Boniche, A. 1998. Squamous cell carcinoma of the tongue in a patient with Rothmund-Thomson syndrome. *Br J Plast Surg* **51**:646-648.
- Taylor, W.B. 1957. Rothmund's syndrome; Thomson's syndrome; congenital poikiloderma with or without juvenile cataracts. *AMA Arch Dermatol* **75**:236-244.
- Vennos, E.M., Collins, M. & James, W.D. 1992. Rothmund-Thomson syndrome: review of the world literature. *J Am Acad Dermatol* **27**:750-762.
- Wang, L.L., Levy, M.L., Lewis, R.A., Chintagumpala, M.M., Lev, D., Rogers, M. & Plon, S.E. 2001. Clinical manifestations in a cohort of 41 Rothmund-Thomson syndrome patients. *Am J Med Genet* **102**:11-17.
- Wang, L.L., Worley, K., Gannavarapu, A., Chintagumpala, M.M., Levy, M.L. & Plon, S.E. 2002. Intron-size constraint as a mutational mechanism in Rothmund-Thomson syndrome. *Am J Hum Genet* **71**:165-167.