

Detection of Human Papillomavirus, p53 and c-erbB-2 Protein Expression in Juvenile Laryngeal Papillomatosis: A Report of 2 Cases

¹Siti Aishah Md Ali, ²Ilina Isahak, ²Dahlan Sabil, ¹Fatimah Sahlan, ³Lokman Saim, ³Abdullah Sani Mohamed

Departments of ¹Pathology, ²Medical Microbiology & Immunology, and ³Otorhinolaryngology, Faculty of Medicine, Universiti Kebangsaan Malaysia, Kuala Lumpur.

ABSTRAK

Perkaitan antara papilomavirus manusia (HPV) dengan papilomatosis larinks telah lama didokumentasi. Kami melaporkan dua kes papilomatosis larinks dan mengkorelasi kes-kes ini dengan kehadiran HPV, protein-protein p53 dan c-erbB-2. Kes yang pertama ialah seorang pesakit lelaki berumur satu tahun dan kes yang kedua, seorang pesakit perempuan berumur enam tahun. Spesimen biopsi yang berfiksasi formalin dan terbenam-parafin telah diuji secara teknik in situ hibridisasi untuk kehadiran genom HPV. Teknik ini menggunakan prob-prob berbiotin yang spektrumnya luas dan jenis spesifik. Manakala ekspresi imunohistokimia pada protein-protein p53 (DO7, 1:50) dan c-erbB-2 (DAKO A0485, 1:300) dievaluasi dengan antibodi yang terdapat secara komersial. Secara histologi, tumor pada kedua-dua kes ini menunjukkan bentuk papilari pada papiloma skuamus. Kes pertama mengesan HPV jenis 6, HPV jenis 11 dan ekspresi protein p53 manakala kes kedua hanya mempunyai HPV jenis 6. Kedua-dua kes HPV menunjukkan tanda positif terhad di nukleus pada epitelium skuamus superfisial. Kes yang pertama menunjukkan kepositifan p53 yang kelihatan di bahagian basal hingga satu per tiga epitelium papiloma larinks dan biopsi susulan yang terkini menunjukkan kepositifan p53 telah melanjut ke lapisan atasan epitelium. Ekspresi protein c-erbB-2 tidak dikesan pada kedua-dua kes ini. Penemuan ini adalah sama dengan kajian lain di mana pemantauan susulan klinikal pada kes-kes ini disyorkan kerana ia kecenderungan berulang.

Kata kunci: papilomatosis larinks juvenil, papilomavirus manusia, protein p53, protein c-erbB-2

ABSTRACT

The association of human papillomavirus (HPV) with juvenile laryngeal papillomatosis has been well documented. We report two cases of juvenile laryngeal papillomatosis and correlated these cases with presence of HPV, p53 and c-erbB-2 proteins. The first case was a one-year-old male patient and the second a six-year-old female patient. Formalin-fixed paraffin-embedded biopsy specimens were tested for the presence of HPV genome by the technique of in situ hybridisation using wide spectrum and type specific biotinylated probes while the immunohistochemical expression of p53 (D07, 1:50) and c-erbB-2 (DAKO A0485, 1:300) proteins were evaluated with commercially available antibodies. Histologically the tumours in both cases showed papillary configuration of squamous

Address for correspondence and reprint requests: *Profesor Madya Dr Siti Aishah Md Ali, Jabatan Patologi, Fakulti Perubatan, Universiti Kebangsaan Malaysia, Jalan Yaakob Latif, Bandar Tun Razak, 56000 Cheras, Kuala Lumpur. E-mel: saishah@mail.hukm.ukm.my*

papilloma. The first case detected HPV type 6, HPV type 11 and p53 protein expression while the second case showed only HPV type 6. Both cases of HPV showed positive signals confined to the nuclei in the superficial squamous epithelium. The first case showed p53 positivity seen from the basal region up to one third of the epithelium of laryngeal papillomas and the subsequent recent repeat biopsy showed the positivity of p53 had extended throughout the upper layers of the epithelium. Expression of c-erbB-2 protein was not detected in both cases. These findings were similar as in other studies where follow-up of the cases was recommended since they tend to recur.

Key words: juvenile laryngeal papillomatosis, human papillomavirus, p53 protein, c-erbB-2 protein

INTRODUCTION

Juvenile laryngeal papillomatosis are benign epithelial neoplasms of the laryngeal mucosa, often multiple and recurrent with a tendency to spread throughout the respiratory tract (Moore & Lattes, 1959). The most common age of onset is during the first 5 years of life. The lesions may regress spontaneously at puberty but occasionally the patients will have recurrences throughout life. Juvenile multiple laryngeal papillomas are known to be caused by human papillomavirus (HPV) infection especially HPV-6 and HPV-11 (Corbitt et al, 1988).

P53 is the protein product of a tumour suppressor gene on the short arm of chromosome 17 (Isobe et al, 1986). It is involved in the regulation of the cell cycle and the triggering of apoptosis. Mutations of this tumour suppressor gene are amongst the commonest detected in human malignancies (Lane, 1994). While the wild-type (normal) p53 is not usually detected by immunohistochemistry as it has a short half-life (6-20 min), most genetic alterations result in the accumulation of a stabilised protein in the nucleus which is readily detectable by immunohistochemistry in paraffin-embedded tissue (Levine, 1992; Wynford-Thomas, 1992). Positivity indicates that the normal function of p53 in directing apoptosis of genetically abnormal cells is no longer operating in the cell.

Oncoprotein c-erbB-2 (also known as *neu*/HER2) belongs to the family of the epidermal growth factor receptors, together with the Epidermal Growth Factor receptor (*c-erb* B1), Her3 (*c-erb* B3) and Her4 (*c-erb* B4), possesses tyrosine kinase activity, and is able to confer growth advantages to tumour cells overexpressing the protein and/or manifesting amplification of the cognate gene (Kurebayashi, 2001). *c-erb* B2 is a 185-kDa glycoprotein, which has been mapped to on chromosome 17q21 (Akiyama et al, 1986). Amplification of the gene has been demonstrated in adenocarcinomas arising at a number of different sites as breast, ovary and gastrointestinal tract (Tal et al, 1988).

Here we report two cases of laryngeal papillomas containing viral genomes of HPV by in situ hybridisation and p53 with c-erbB-2 protein expressions by immunohistochemical method.

CASE REPORTS

CASE 1

In 1986, a one-year-old Chinese male baby lost his voice for three months duration, but he responded to call. There was no productive cough, fever or congenital abnormality. Before this episode he was crying and there was no significant illness of note. He was a full-term baby and he was delivered by spontaneous vaginal delivery.

Examination under general anaesthesia showed laryngeal papillomatosis. Since then he had more than 40 direct laryngoscopes and tracheoscopy in an attempt to eradicate the papillomas. In 1987, a tracheostomy was performed.

Interferon therapy for a duration of one month was started in 1988 but this failed to eradicate the disease. In 1991, the papilloma had spread to the stoma, subglottic area and the upper part of the trachea.

Presently he is undergoing repeated direct laryngoscopy, tracheoscopy and plucking of the papillomas monthly. This is because the papillomas reappear after each surgical procedure. The latest biopsy was done in year 2001, and in 2002, he died of widespread involvement of the papillomas in the lungs.

CASE 2

A six years old Chinese girl from Johore presented to the Ear, Nose and Throat (ENT) clinic of Universiti Kebangsaan Malaysia (UKM) in 1993 complaining of hoarseness of the voice for the past one year. The hoarseness was gradual in onset but progressively increased in intensity. It was accompanied by productive cough with greenish sputum. There was no stridor, dyspnea or choking.

Initially, she sought treatment at another hospital and a direct laryngoscopy was done. A diagnosis of left vocal cord papilloma was confirmed histologically. She was referred for further management in UKM.

Examination under anesthesia, multiple laryngeal papillomatosis were detected arising from the left vocal cord, posterior half of left false cord and anterior commissure.

Further biopsies and laser vaporization were done. Later, she was subjected to another laser vaporization. The papillomatosis had recurred in the same area and extended to one-third of the right vocal cord. There was no subglottic extension.

Due to the persistent nature of this condition, she underwent further examination under anesthesia and repeated treatment. She was however lost to follow-up.

MATERIALS AND METHODS

Both specimens consisted of multiple small fragmented laryngeal tissues, each measuring 4 x 3 cm and 1.5 x 1.5 x 1.5 cm in aggregate.

The specimens were fixed in 10% buffered formalin and sampled in accordance with the departmental manual. Light microscopic slides were prepared from these tissues fixed in formalin, embedded in paraffin, cut at 4µm in thickness and stained with haematoxylin and eosin according to standard procedure.

Laryngeal papillomatosis biopsy specimens at the time of diagnosis (the above specimens) and from the last subsequent procedure (done in 2001) were used for detection of both p53 and c-erbB-2 proteins.

Detection of p53 and c-erbB-2 proteins by immunohistochemical staining

Immunohistochemistry was performed on paraffin-embedded tissue using the labelled streptavidin biotin method (LSAB+kit, DAKO K 0690, Dako-Cytomation, Glostrup, Denmark). The mouse monoclonal antibody against p53 (DO-7, Dakopatts, at a dilution of 1:50) was used while polyclonal antibody against c-erbB-2 (DAKO A 0485, 1:300) was employed.

Briefly, 3 µm sections were cut from the formalin-fixed, paraffin-embedded tissue blocks and mounted on silanized glass slides, deparaffinised, and placed in target retrieval solution (DAKO S1699, Dako-Cytomation, Glostrup, Denmark) and in a microwave 600W for 10 minutes. The slides were left to cool in room temperature for 20 minutes and then washed again.

Subsequently, the slides were placed in 3% hydrogen peroxide for 5 minutes at room temperature. The tissue sections were then incubated with anti-Human p53 mouse monoclonal antibody (DO-7, 1:50) at room temperature for 30 minutes.

After several washes with Tris buffered saline (TBS), sufficient amount of biotinylated linking antibody was applied and the sections were incubated at room temperature for 15 minutes followed by washing in three changes of TBS. Labelled Streptavidin Biotin (LSAB, Dako-Cytomation, Glostrup, Denmark) was then applied and the slides were again incubated at room temperature for 15 minutes and subsequently washed with three changes of TBS.

Localisation of p53 was visualised by incubating the tissue sections for 10 minutes in substrate-chromogen solution (Dako Corp, Carpinteria, California). The slides were finally washed under running tap water, counterstained with haematoxylin, dehydrated, cleared and mounted. The positive control was from a known p53 positive tissue section of an infiltrating ductal carcinoma, and the negative control was from the tissue section of the same case but without primary antibody.

The reactivity for p53 protein was regarded as positive if distinct nuclear staining was present. Staining pattern was scored semi-quantitatively as follows: 0, no staining; 1, staining of the basal cells and suprabasal region up to one third of the epithelial thickness; 2, staining of two thirds of the epithelial thickness; and 3, staining throughout the epithelial thickness.

Staining for c-erbB-2 was performed as described for p53 with minor modifications. Heating in the microwave (600W) for 20 minutes was carried out followed by incubation with a 1:300 dilution of polyclonal rabbit anti-Human c-erbB-2 (DAKO A 0485, DakoCytomation, Glostrup, Denmark) at room temperature for 30 minutes.

The positive control was taken from a known c-erbB-2 positive section of an

infiltrating ductal carcinoma and the negative control was obtained from the tissue section of the same case as above but without primary antibody.

c-erbB-2 positivity is scored according to: 0 = no membranous staining; 1+ = incomplete membranous staining; 2+ = membranous staining of moderate intensity in more than 10% neoplastic cells; 3+ = strong and complete membranous staining in more than 10% neoplastic cells.

In situ hybridisation

In situ hybridisation was performed using human papillomavirus DNA probes commercially obtained from Dako (Carpenteria, CA, USA) and In situ Hybridisation detection System (DAKO® in situ hybridisation detection system, Dako, Carpenteria, CA, USA), as described previously (12). The Wide Spectrum and the type specific HPV biotinylated DNA probes were prepared from HPV DNAs which were cloned into plasmid vectors. The targets for Wide Spectrum probe were the genomic DNAs of HPV types 6, 11, 16, 18, 30, 31, 33, 35, 45, 51 and 52. The specific HPV probes used were types 6, 11, 16, 18, 31 and 33. The positive control probe was prepared from total human DNA. The target was total genomic human DNA. The negative control was a plasmid DNA.

Positive reactions for hybridisation were shown as blackish purple stain mainly in the nuclei of infected cells containing target DNA and negative reactions of the epithelial cells were stained as light pink. Typing with Type-Specific HPV probes was done on specimens showing positive signals with Wide Spectrum HPV probe.

RESULTS

Pathology findings

The histological appearances of both tissues were typical of laryngeal papillomatosis. Microscopically, the papillomata appeared as projections of kerati-

nised stratified squamous epithelium overlying a fibrovascular core (Fig.1a). Parakeratosis and koilocytes were present and the latter appeared as vacuolated cells with clear cytoplasm. There was no atypia seen in these tissues.

In situ hybridisation

In situ hybridisation study detected specific signals of HPV-6 DNA in both cases and HPV-11 DNA in only the first case. The other viral types were not identified. The specific signal was observed as dense and homogenous, blackish purple nuclear stain, located in the superficial squamous epithelial cells (Fig. 1b&c).

p53 and c-erbB-2 protein expressions

For the first case, tissue blocks from biopsy taken at onset and the latest biopsy in 2001 were selected after examination of the haematoxylin and eosin stained tissue sections. By immunohistochemistry, the first section showed positive staining for p53 protein, most pronounced in the lower third of the epithelium with focal intermediate staining, while section from the latest biopsy showed the staining had extended to the intermediate layer in a diffuse pattern (Fig. 2 & 3).

For the second case, tissue blocks available from the biopsy taken at presentation showed patchy staining of p53 protein in the basal layer.

For both cases, immunohistochemical staining for c-erbB-2 were negative.

DISCUSSION

Juvenile laryngeal papillomas (LP) present in children or adolescents with multiple papillary tumours on the true cords, from which they spread to the false cords, epiglottis and subglottic area, and in rare cases even to the trachea and bronchi (Moore, 1959). The long period of papilloma infection of the larynx is reflected by the fact that our first patient required a tracheostomy at some stage of the

disease. The more aggressive behaviour of the papilloma has also resulted in this patient requiring laser treatment.

Two types of HPV have been specifically associated with laryngeal papillomas. These are HPV-11, which was originally detected and cloned from a benign laryngeal papilloma and HPV-6 where it was isolated from a condyloma acuminatum (genital wart) and subsequently shown to be associated with condyloma acuminata and laryngeal papillomas (LPs) in adults and children (Gissman & zur Hansen, 1980; Mounts et al, 1982). Both our cases were associated with HPV-6 and the first case had an additional HPV-11 which has been proved to be the most refractory to treatment (Hartley et al, 1994).

A variety of human tumours exhibit mutations in the p53 gene that can lead to increased stability of its protein, resulting in increased immunostaining (Lane, 1994). Overexpression of p53 protein is commonly demonstrable in benign epithelial lesions of the upper respiratory tract. A study showed that in LPs, overexpression of p53 protein increased with the grade of epithelial abnormalities. The distribution of positive cells changed from scattered and focal, in simple and abnormal hyperplasia, to diffuse in atypical hyperplasia (Luzar et al, 1997).

The HPVs produce two separate viral proteins, one of them an E6 viral protein, is not interactive with HPV-6 and HPV-11, and both are most frequently found in LPs (Knudson, 1993). Thus, in the presence of HPV-6 and HPV-11, p53 protein can still preserve its tumor-suppressor activity in LP and this may account for the significant lower rate of malignant transformation of LP (Luzar et al, 1997).

Another study identified 12 patients with recurrent laryngeal papillomatosis for a minimum of five years and each patient had at least three biopsies done; one biopsy was at the time of diagnosis, one at an intermediate time during treatment and the third from the last procedure (Rabah et al, 2000). They concluded that HPV typing,

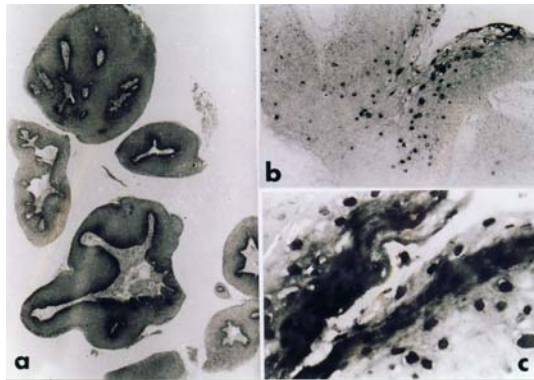


FIGURE 1: Histological section of laryngeal papillomatosis (Case 1) (Haematoxylin & eosin, a, x20). Cells containing HPV 6 DNA by in situ hybridisation, indicated by the dark-stained nuclei of the superficial cells (b, x40 & c, x400)

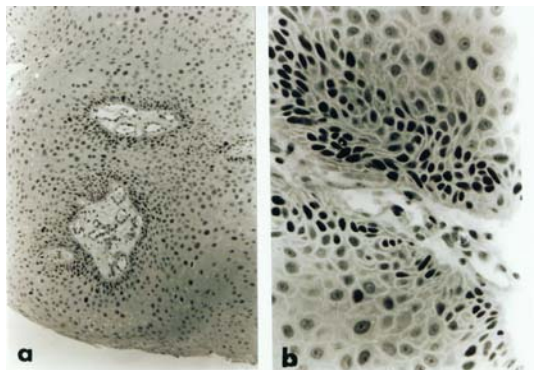


FIGURE 2: Laryngeal papillomatosis. Histological section from Case 1 showing nuclear staining for p53 protein in the cells within the basal layer, and a few positive cells in the upper epithelial cells. (Immunoperoxidase, a, x 40; b, x400)

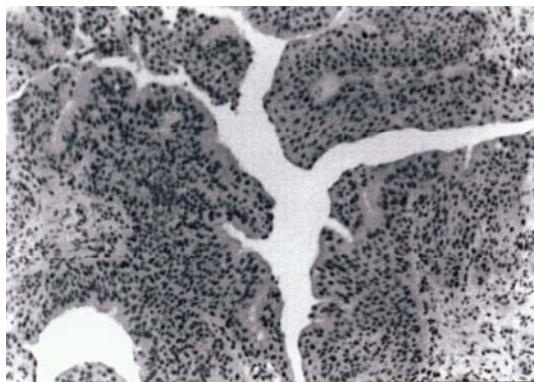


FIGURE 3: Laryngeal papillomatosis. Histological section from Case 1 showing nearly diffuse nuclear staining of p53 protein throughout the epithelial thickness (Immunoperoxidase stain, x20)

especially HPV-11 may be helpful in identifying patients with aggressive recurrent laryngeal papillomatosis and the weak association between p53 indexes and procedures per year and virus type may have some predictive value in identifying the aggressive type. Our first patient had HPV-11 and was followed-up for nearly 15 years and histologically, so far, no atypical changes were seen in the epithelium.

Luzar et al showed c-erbB-2 protein was observed in the hyperplastic epithelium covering LPs, and staining increased with increasing grades of epithelial thickness (Luzar et al, 1997). Membranous staining is considered to indicate c-erbB-2 over-expression, which is characteristically associated with c-erbB-2 amplification in breast carcinomas. With the increasing grade of epithelial abnormalities, cytoplasmic staining became predominant compared to membranous staining, and c-erbB-2 positivity sometimes occupied the whole thickness. Both our cases showed no membranous staining.

CONCLUSION

One of the above cases followed-up had frequent recurrences and was shown to have HPV type 11 and p53 positive cells. These p53 positive cells were shown in the earlier specimen to be scattered and focally distributed, and follow-up biopsy after many years showed nearly diffuse distribution. These findings were similar as in other studies, where follow-up of the cases was recommended since they tend to recur (Luzar et al, 1997; Rabah et al, 2000).

ACKNOWLEDGEMENTS

The authors would like to thank Encik Rosli Nasir of Hospital Universiti Kebangsaan Malaysia for preparing the photographs.

The study was supported by the Ministry of Science, Technology and environment (Grant IRPA No.03-037-03-075) and

Universiti Kebangsaan Malaysia (F 4/99 & FF/15/2001)

REFERENCES

- Akiyama T, Sudo C, Ogawara H et al. The product of the human c-erbB-2 gene: a 185-kilodalton glycoprotein with tyrosine kinase activity. *Science*. 1986; 232; 1644-1646.
- Corbitt G., Zarod A.P., Arrand J.R., Longson M., Farrington W.T. Human papillomavirus genotypes associated with laryngeal papilloma. *J Clin Pathol*. 1988; 41:284-285.
- Gissman L., zur Hansen H. Partial characterization of viral DNA from human genital warts (condyloma acuminata). *Int J Cancer*. 1980; 25:605-609.
- Hartley C., Hamilton J, Birzgalis AR, Farrington WT. Recurrent respiratory papillomatosis – the Manchester experience, 1974-1992. *J Laryngol Otol*. 1994; 108:226-229.
- Isobe M., Emanuel BS., Givol D., Oren M., Croce CM. Localisation of gene for human p53 tumour antigen to band 17p13. *Nature* 1986; 320:84-85.
- Knudson A. Genetics of the tumors of the head and neck. *Arch Otolaryngol Head Neck Surg*. 1993; 119:735-737.
- Kurebayashi J J. Biological and clinical significance of her2 overexpression in breast cancer. *Breast cancer* 2001; 8:45-51.
- Lane DP. P53 and human cancers. *Br Med Bulletin*. 1994; 50:582-599
- Levine AJ. The p53 tumour-suppressor gene. *N Engl J Med*. 1992; 326:1350-1352.
- Luzar B, Gale N, Kambic V, Poljak M, Zidar N and Vodovnik A. Human papillomavirus infection and expression of p53 and c-erbB-2 protein in laryngeal papillomas. *Acta Otolaryngol (Stockh)*. 1997; 527(Suppl):120-124.
- M A. Siti-Aishah, I. Isahak, D Sabil, F Sahlan, H Md Tahir A A Yahya. Detection of human papillomavirus using in situ hybridisation technique in vulvo-vaginal warts. *Malaysian Journal of Medical Sciences*. 2000;7(2):27-31.
- Moore R.L., Lattes R. Papillomatosis of the larynx and bronchi. *Cancer*. 1959; 12:117-126.
- Mounts P., Shah K.V., Kashima H. Viral aetiology of juvenile- and adult-onset squamous papilloma of the larynx. *Proc Natl Acad Sci USA*. 1982; 79:5425-5429.
- Pauletti G, Dandekar S, Rong H et al. Assessment of methods for tissue-based detection of the HER-2/neu alteration in human breast cancer: a direct comparison of fluorescence in situ hybridisation and immunohistochemistry. *J Clin Oncol*. 2000; 18:3651-64.
- Rabah R., Sakr W., Thomas R., Lancaster WD., Gregoire L. Human Papillomavirus type, proliferative activity and p53, potential markers of

- aggressive papillomatosis. *Arch Pathol Lab Med.* 2000; 124:721-724.
- Tal M, Wetzler M, Josefberg Z et al. Sporadic amplification of the HER2/neu proto-oncogene in adenocarcinomas of various tissues. *Cancer Res.* 1988; 48:1517-1520.
- Wynford-Thomas D. p53 in tumour pathology: Can we trust immunocytochemistry? *J Pathol.* 1992; 166:329-330.