

# Cochlear Implantation in Children with Labyrinthitis Ossificans.

<sup>1</sup>Abdullah A, <sup>1</sup>Shaharudin MH, <sup>1</sup>Ami M, <sup>2</sup>Marhaban JA, <sup>2</sup>Awang MA, <sup>3</sup>Zulfiqar MA, <sup>4</sup>Othman BF, <sup>1</sup>Saim L

<sup>1</sup>Department of Otorhinolaryngology Head and Neck Surgery, <sup>2</sup>Department of Medical Rehabilitation Services and <sup>3</sup>Department of Radiology, Faculty of Medicine, Universiti Kebangsaan Malaysia.

<sup>4</sup>Department of Audiology and Speech Sciences, Faculty of Allied Health Sciences, Universiti Kebangsaan Malaysia.

## ABSTRAK

Pengerasan pada koklea sebelum ini adalah kontra indikasi relatif bagi pembedahan implan koklea. Ini disebabkan oleh kesulitan untuk memasukkan elektrod dengan selamat ke dalam koklea. Akibatnya elektrod atau bahagian telinga dalam berkemungkinan akan rosak. Tambahan pula osifikasi pada skala timpani akan menghadkan bilangan elektrod yang masuk ke dalam koklea. Keberkesanan implan koklea dipertikaikan disebabkan kemungkinan jumlah aliran elektrik yang tinggi diperlukan di dalam koklea yang telah mengalami pengerasan. Di dalam kes ini juga jumlah sel neuron tidak diketahui. Ini semua mungkin akan menyebabkan kesulitan pada prosedur pembedahan dan memberi kesan pada hasil jangka masa panjang. Walaubagimanapun sekarang ini pembedahan implan koklea dapat dilakukan pada koklea yang telah mengalami osifikasi bergantung kepada pengalaman doktor pakar bedah. Disini kami melapurkan bahawa pembedahan implan koklea adalah selamat dijalankan pada koklea yang telah mengalami pengerasan.

*Kata kunci: pembedahan implan koklea, labrintitis osifikan, kepekakan sensorineural*

## ABSTRACT

Evidence of ossification was previously considered a relative contraindication to cochlear implantation. It was considered difficult or impossible to achieve safe electrode insertion because of bony obstruction. Either the electrodes or the inner ear structures could be damaged. Moreover, obstructed scala tympani could limit the number of electrodes that can be inserted. The efficacy of the electrical stimulation was also questioned, as a higher current would be needed on an ossified cochlea. Finally, the neural survival in ossified cochlea is unknown. This may complicate the surgical procedure and affect the long-term outcome. However, depending on the experience of the surgeon, cochlear implantation has been attempted even in grossly ossified cochlea. Here we illustrate that cochlear implantation is safe in labyrinthitis ossificans.

*Keywords: cochlear implant, labyrinthitis ossificans, sensorineural hearing loss*

---

**Address for correspondence and reprint requests:** Dr Asma Abdullah, Department of Otorhinolaryngology, Medical Faculty, University Kebangsaan Malaysia, Jalan Yaakub Latif, 56000 Cheras, Kuala Lumpur, Malaysia.  
E-mail: [asmaent@yahoo.com](mailto:asmaent@yahoo.com)

## INTRODUCTION

Labyrinthitis ossificans is a pathologic ossification in the cochlea and labyrinth (Aferzon M. & Reams C.L. 2001). It is usually caused by an infection that reaches the inner ear via either the tympanogenic (most common), meningogenic or hematogenic route. Bacterial meningitis is the most common cause of meningogenic labyrinthitis. The infection spreads to the inner ear via subarachnoid spaces such as the cochlear aqueduct and the internal auditory canal. Infection in the subarachnoid spaces (meningitis) also can reach the cochlea via hematogenous spread. Ossification secondary to meningitis is typically bilateral. In the early years of cochlear implant surgery, ossification of the cochlea was a contraindication for cochlear implant surgery. As surgeons gained more experience with implantation, they found that some degree of ossification could be dealt with through modifications of the surgical technique.

## CASE REPORTS

### CASE 1

MF, a 14-year-old Malay boy was diagnosed to have postlingual sensorineural hearing loss secondary to head injury. He was involved in a motor vehicle accident (MVA) at the age of 11 years. The high resolution computed tomography (HRCT) and magnetic resonance imaging (MRI) of the temporal bone showed labyrinthitis ossificans. He underwent uneventful surgery without any complications one and half years after the MVA. Intraoperatively there was moderate ossification in the scala tympani. An extended cochleostomy was performed until an opening was found deep at the basal turn of the cochlea. A straight electrode was inserted. However, only partial insertion was achieved up to 11 electrodes.

### CASE 2

DLKM, a 4-year-old Chinese boy had normal hearing in both ear before he had Haemophilus influenzae meningitis at the age of three years 4 months. He was treated with intravenous antibiotics in Malacca General Hospital for about 3 weeks. He developed epilepsy for which he was treated with Syrup Sodium Valpoorate 375mg bd. Clinical examination was unremarkable and his high resolution computed tomography (Fig.1) and magnetic resonance imaging of the temporal bone showed features of labyrinthitis ossificans (Fig. 2, 3). An extended cochleostomy was initially performed but there was no opening found. A 2 mm tunnel was drilled at the basal turn anteriorly. A straight electrode was partially inserted. Seven months after the operation, he could respond to loud sounds and was able to say simple words such as "papa" and "mama".

### CASE 3

LWT, a 6-year-old Chinese boy with profound sensory neural hearing loss (SNHL) secondary to meningococcal meningitis at the age of 5 years, was diagnosed to have profound SNHL. About 5 days after being discharged from the hospital, the mother noticed that he did not respond to sound. A hearing aid was tried for 6 months but with no benefit. His HRCT of the temporal bone was normal. MRI was not performed. However, intraoperatively there was fibrous tissue in the scala tympani noted during cochleostomy. No ossification was found. A straight electrode was inserted through the cochleostomy. Only partial insertion was achieved (Fig. 4). There was no postoperative complications.

## DISCUSSION

Hearing loss following an episode of bacterial meningitis is a well-documented

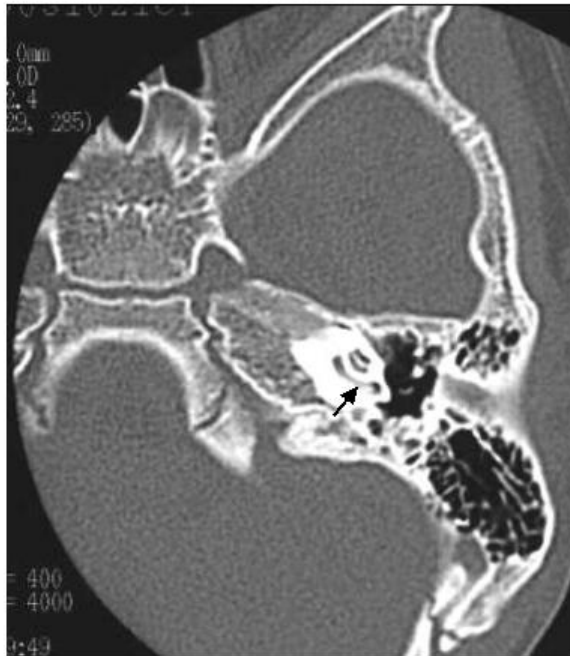

FIGURE 1: An axial HRCT from case 2 shows opacity of the lumen of the left cochlea.

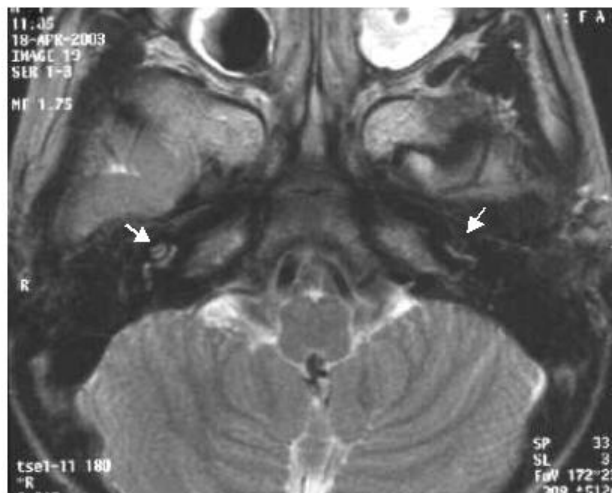


FIGURE 2: An axial T2-weighted MRI (case 2) shows hypointensity of the lumen of the cochlea bilaterally, compared to cerebrospinal fluid (CSF), which is hyperintense.

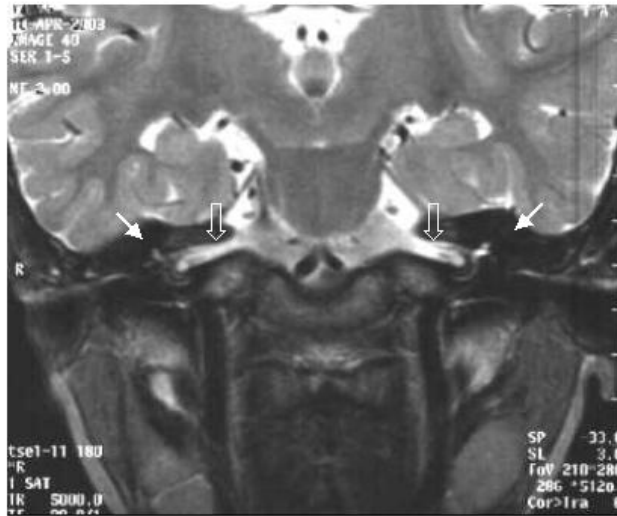

FIGURE 3: A coronal T2-weighted MRI (case 2) shows hypointensity of the labyrinthine structures bilaterally.

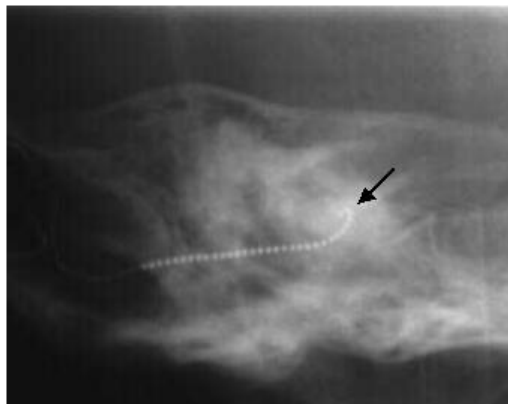


FIGURE 4: A modified Stenver's (cochlear) view shows partial insertion of electrodes in case 3.

phenomenon with incidence ranging from 5% to 35% (Kim HY et. al. 2001). Fortnum and Davis (1993) reported that up to 10% of children who suffer acute bacterial meningitis would sustain some degree of permanent unilateral or bilateral deafness.

Weissman and Kameron (1993) reported that approximately 2 to 5% of children and adults who survive a bacterial meningitis develop profound bilateral SNHL. The site is almost always at the cochlea where there is loss of the organs of Corti and not

at the auditory nerve as was previously reported (Dodds A et. al. 1997). The infective process in the cochlea and labyrinth may produce a reaction in the endosteum resulting in new bone formation (Novak MA et. al. 1990). Post-meningitis SNHL can occur as early as 48 hours post infection.

As early as two weeks after the onset of meningitis, fibrosis is present followed by new bone formation within two months (Niparko JK & Mabrie DC. 1999). Ossification initially develops in the basal turn of the cochlea at the region of the scala tympani near the round window (Desouza C et. al 1991, Dodds A et. al. 1997). Radiographic evidence of ossification can be found as early as two months after the acute infection indicating that the intra cochlear process probably begins much earlier (Novak MA et. al. 1990).

Green et al (1991) reported that a partially obliterated lumen can appear to be patent in the temporal bone scan as seen in case 3. A labyrinth that has undergone fibrous obliteration may appear normal on CT but will lack the high signal on T<sub>2</sub> weighted MRI (Harnsberger HR et. al. 1987, Weissman JL & Kamerer DB. 1993). Therefore, it is advocated that MRI of the temporal bone is required in all post meningitis cases for cochlear implantation although they have normal HRCT.

Balkany et al (1988) reported 15 patients with partially ossified cochlea where the results of cochlear implant were similar to those achieved in patients who had normal cochlea. Electrodes were completely inserted in 14 patients and partially in one patient (Balkany T et. al. 1988). Becker et al (1984) reported that mild labyrinthitis ossification is not a contraindication to cochlear implantation.

Novak et al (1990) found that timing of implantation may be critical. A delay of even a few months probably would have allowed ossification to proceed to a degree that standard implantation procedures would have been impossible. Therefore the potential benefit of cochlear implantation

may be reduced (Dodds A et. al. 1997, Novak MA et. al. 1990). In case 2 the operation was performed about 8 months post meningitis after discussing with the parents regarding the benefit of cochlear implantation. In case 3, the patient underwent cochlear implantation 11 months post meningitis.

#### *Surgical technique in ossified cochlear*

Various surgical techniques have been proposed to minimize complications of electrode insertion in the ossified cochlea. Radical cochleostomy has been performed when extensive ossified cochlear is encountered. Gantz et al (1998) described a method of drilling out the entire basal turn of the cochlea to facilitate cochlear implantation in a completely ossified cochlea. Several authors have since reported satisfactory results in patients using the Gantz (1998) procedure (Weissman JL & Kamerer DB. 1993, Rauch SD et. al. 1997, Lambert PR et. al. 1991). Limited tunnel techniques are more frequently used. These techniques are simpler, less time consuming and involve less potential for complication than extensive cochleostomy (Trinh BA et. al. 2000). However, these techniques can impose serious limitations to multichannel stimulation because of the high chance of partial insertion. Scala vestibuli insertions have also been used in the presence of a complete obstruction of the scala tympani.

Steenerson and Garry (1999) described three patients with scala tympani ossification with open scala vestibuli and successful implantation in the scala vestibuli. Steenerson and Garry (1994) reported that scala vestibuli implantation is an alternative when ossification is found in scala tympani. They reported that scala vestibuli cross section area may be greater than scala tympani resulting in easier cochlear implant electrode insertion.

#### **CONCLUSION**

It is advocated that all patients with meningitis undergo a detailed assessment

of the cochlea with MRI despite a normal looking HRCT. Cochlear implantation in labyrinthitis ossificans is still feasible. However it should be performed by an experienced otologist who would be able to vary the surgical technique for electrode insertion according to severity of the ossification of the cochlea.

## ACKNOWLEDGEMENTS

We would like to thank our audiologists, radiographer, speech therapists and Mr Kamarulzaman Othman for their contributions.

## REFERENCES

- Aferzon M. & Reams C.L. Labyrinthitis ossificans. *Ear Nose & Throat Journal*. 2001; 80:700-2.
- Balkany T, Gartz B & Nadol J. Multi channel cochlear implants in partially ossified cochlea. *Ann Otol Rhinol Laryngol*. 1988; 97:3-7.
- Becker TS, Eisenberg LS, Luxford WM & House WF. Labyrinthine ossification secondary to childhood bacterial meningitis: Implications for cochlear implant surgery. *Am J Neuro Radiol*. 1984; 5:731-41.
- Desouza C, Paparella MM & Yoon TH. Pathology of labyrinthitis ossification. *Journal of Laryngol Otol*. 1991; 105:621-4.
- Dodds A, Tuskiewicz E & Ramsen E. Cochlear implantation after bacterial meningitis: the danger of delay. *Arch Dis Child*. 1997; 72(2):139-0.
- Fortnum H & Davis A. Hearing impairment in children after meningitis: incidence and resource implications. *Br J Audiol*. 1993; 22:43-52.
- Gantz BJ, McCabe BF & Tyler RS. Use of multichannel cochlear implant in obstructed and obliterated cochlea. *Otolaryngol Head Neck Surg*. 1998; 98:72-81.
- Green JD, Marion MS & Hinjasa R. Labyrinthitis ossificans. Histopathologic consideration for cochlear implantation. *Otolaryngol Head Neck Surg*. 1991; 104:320-6.
- Harnsberger HR, Dart DJ, Parkin JL, Wendy R & Osborn AG. Cochlear implant candidates: assessment with CT and MR Imaging. *Radiology*. 1987; 144:53-7.
- Kim HY, Chute PM & Hartrick CJ. Presenting labyrinthitis ossificans. *Arch Otolaryngol Head Neck Surg*. 2001; 127:180-5.
- Lambert PR, Ruth RA & Hodges AV. Multichannel cochlear implant and electrically evoked auditory brainstem response in a child with labyrinthitis ossificans. *Laryngoscope* 1991; 101:14-9.
- Niparko JK & Mabrie DC. Radiology forum. *Arch Otolaryngol Head Neck Surg*. 1999; 125:912-5.
- Novak MA, Fifer RC, Barkmeier JC & Firszt JB. Labyrinthine ossification after meningitis: Its implications for cochlear implantation. *Otolaryngol Head Neck Surg*. 1990; 103:351-5.
- Rauch SD, Hermann BS, Davis LA & Nadol Jr JB. Nucleus 22 cochlear implantation results in post meningitis deafness. *Laryngoscope*. 1997; 107:1606-9.
- Steenerson RF & Gar LB. Multichannel cochlear implantation in Children with Cochlear ossification. *Am J Otol*. 1999; 20:442-4.
- Steenerson RL & Gary LB. Multichannel cochlear implantation in obliterated cochlear using the Gantz procedure. *Laryngoscope*. 1994; 104:1071-3.
- Trinh BA, Bergeron F & Ferron P. Long-term follow-up of cochlear implant users with ossified cochlea. *J of Otol*. 2000; 29:278-85.
- Weissman JL & Kamerer DB. Labyrinthitis ossificans. *Am J Otolaryngol*. 1993; 14:363-5.