

Kajian Kes/Case Study

Kimura's Disease in Malaysian Patients : Three Case Reports

ROSLAN ABDUL RAHMAN, FADZILAH ISMAIL, ROSZALINA RAMLI, GHAZALI MAT NOR, SHA PRIMUHARSA PUTRA

ABSTRAK

Penyakit Kimura adalah sejenis penyakit inflamatori kronik yang melibatkan tisu subkutaneus kawasan kepala dan leher, aksila dan anggota atas serta kawasan pinggul. Di kawasan kepala dan leher, kelenjar air liur major dan nodus limfa adalah kawasan yang sering kali terlibat dan ianya dikaitkan dengan eosinophilia dan peningkatan serum IgE. Tiga kes penyakit Kimura yang melibatkan kelenjar parotid, kelenjar nodus limfa dan pipi dilaporkan bersama dengan ringkasan ulasan kes-kes yang telah dilaporkan sebelumnya.

Kata kunci: Penyakit Kimura, penyakit inflamatori kronik, lesi kawasan kepala dan leher

ABSTRACT

Kimura's disease is a chronic inflammatory disorder which affects the subcutaneous tissues of the head and neck, axilla and upper limb as well as the groin region. In the head and neck region, major salivary glands and regional lymph nodes are mainly involved with associated eosinophilia and an elevated IgE concentration. Three cases of Kimura's disease involving the parotid glands, lymph nodes and cheek are presented with a brief review of the literature.

Key words: Kimura's disease, ,chronic inflammatory disorder, head and neck lesions

INTRODUCTION

Kimura's Disease (KD) is a non-neoplastic chronic inflammatory condition that usually appears as nodules in the subcutaneous tissue of the head and neck. It was first described in 1937 by Kimm and Szeto in China; who reported seven cases of benign lymph node enlargement with eosinophilic infiltrate, which they termed as eosinophilic hyperplastic lymphogranuloma (Kimm & Szeto 1937). Kimura et al. (1948) from Japan reported a similar finding and described it as an "unusual granulation and hyperplastic changes of lymphatic tissue", and this condition has since become widely known as Kimura's disease (Kimura et al. 1948). Most cases of KD occur in the Oriental population, especially in males of Chinese and Japanese origin. It may also occur sporadically in Caucasians, and rarely in the African population. Although the disease can become apparent at any age, most of the cases described have occurred in the second and third decades of life, with 80 -

87% of the affected patients being males (Sawada & Nomura 1984; Peters et al. 1986; Kuo et al. 1988)

CASE REPORTS

CASE 1

A 37 year old Malay man presented with a bilateral, painless swellings at the pre-auricular region for nearly ten years, and over the past year, noticed a progressive increase in the size of the swellings. There was no discharge, skin changes nor excessive salivation noted, and facial nerve function was intact. The patient's medical history was otherwise unremarkable. The significant clinical findings was bilateral parotid swellings measuring about 6x5cm, causing facial asymmetry, but no palpable cervical lymphadenopathy. The blood investigations were unremarkable except for an increase in the differential eosinophilic count (54.9%) although the white cell count was normal ($11 \times 10^9/l$ cell) and a markedly increased IgE concentration of more than 1,450 iu/ml. The MRI scan demonstrated a diffuse enlargement of the left parotid gland compared to the right parotid gland. Fine needle aspiration biopsy was performed and showed numerous eosinophils and lymphocytes suggestive of Kimura's disease. The patient was advised surgery but he declined, however, remains on follow-up.

Insert Figure 1a,1b,1c,1d

CASE 2

A 56 year old Malay man presented with a painless swelling of the right cheek for more than eight months, which was slowly increasing in size. There was no history of trauma, trimus or discharge from the swelling. The patient's medical history was unremarkable. On examination he was a fit healthy middle aged man. There was a diffuse swelling of the right cheek, with no change in skin colour and no discharging sinus. Intra-orally, there was a firm, well-circumscribed swelling with a smooth surface, measuring about 2x2 cm in the right buccal mucosa area. The swelling was mobile and slightly tender on palpation. Routine blood investigations and chest radiograph were normal. An incisional biopsy was performed, and this was reported as Kimura's disease. Subsequent excision of the lesion was performed, and histological examination showed fibro-fatty tissue exhibiting lymphoid proliferation with germinal centers, an angiomatoid component, and an abundance of stromal eosinophils strongly suggestive of Kimura's disease. The patient remains well on follow-up.

CASE 3

A 15 year old Malay girl presented with progressive swelling but painless on the right post-auricular and right upper cervical areas. The slow growing condition was noticed for over a period of one and a half years. There was no history of infection or trauma. The patient's medical history was otherwise unremarkable. On examination, she was fit and healthy. There was a swelling measuring 3x4 cm located at the right post auricular area. The swelling was firm, lobulated, non-tender, and displaced the pinna anteriorly. The overlying

skin was normal with no discharging sinus. Also present was a palpable 1 x 1 cm mobile, right upper cervical lymph node. Full blood investigations were unremarkable except for a rise in the white cell count i.e $19.1 \times 10^9/l$ with an increased differential count of 53% of eosinophils. The IgE concentration was markedly increased at more than 1,000 iu/ml. Rapid mononucleosis assay was negative, and titres for toxoplasma gondii, rubella, cytomegalovirus and filariasis were non-reactive. The CT scan demonstrated a right post-auricular swelling which was confined to the region, with multiple, bilateral small neck-nodes. Fine needle aspiration biopsy showed multiple fragments of lymph node tissue with abundant infiltration of eosinophils but no evidence of any malignant change. Based on the peripheral eosinophilia, increased IgE concentration and cytological appearance, a diagnosis of Kimura's disease was made. An excisional biopsy was performed, with the histology being similar to previous report. The patient remained well until a year post-operatively, when she complained of a right pre-auricular swelling, measuring about 2x3 cm, which was painless. A fine needle aspiration biopsy was performed and showed similar findings as Kimura's disease. She was advised surgery, but refused and remains on follow-up.

DISCUSSION

Kimura's disease (KD) often involves young oriental males and commonly presents with a solitary or multiple, painless, slow growing subcutaneous nodules. It usually involves the head and neck region, particularly the parotid gland and submandibular areas, and rarely the scalp and orbital region. Common associated findings include cervical lymphadenopathy, eosinophilia (reaching 10-57%) and elevated serum IgE levels. Other less common sites include the extracranial soft tissues such as the oral cavity, axilla, groin, upper limb and spermatic cord. KD has also been reported to affect skeletal muscle and prostate. Juvenile temporal arteritis has also been coupled as an accessory sign of KD (Li et al. 1996; Tham et al. 1981; Kennedy et al. 1992).

Generally KD is a localized condition with a benign clinical course but recurrence is not uncommon. In approximately 12% of patients, there is a related renal disease, usually presenting as nephrotic syndrome. A array of changes in which evidence of IgE deposits are present on the glomerular basement membrane can be seen on renal biopsy (Qunibi et al. 1988; Matsuda et al. 1992).

The aetiology and pathogenesis of KD is unknown and it may be related to a disturbance in the immune regulation of eosinophil and IgE production. This current hypothesis believes that as a result of interaction between types 1 and 2 T-helper cells (Th 1 and Th 2) leads to an excess production of eosinophilotropic cytokines such as interleukin-4 (IL-4). Patients with an active stage of KD have a higher than normal levels of the cytotoxic proteins, eosinophilic cationic protein (ECP) and major basic protein (MBP), all found within the granules of the eosinophils. The pathogenesis of KD may also be related to an aberrant clonal T-cell proliferation, possibly restricted only to the lymph nodes, and the production of interleukin-5 (IL-5) which may lead to eosinophilia. Allergic, bacterial, viral (e.g. Epstein-Barr virus), fungal (e.g. candida albican) and parasitic aetiologies have been linked to KD but they have not been constantly recognized (Takenaka et al. 1976; Tabata et al. 1992; Wierenga et al. 1993).

The differential diagnosis for KD are many and they include angiolymphoid hyperplasia with eosinophilia (ALHE), lymphoma, Hodgkin's disease, lymphocytoma, Kaposi's sarcoma, tuberculosis, eosinophilic granuloma, epitheloid haemangioma, angiofollicular hyperplasia, low grade angiosarcoma, hamartoma, Mikulicz disease and nodal metastasis. Except for ALHE, the clinical and histological features of these diseases are easily distinguishable from KD (Kung et al. 1984; Urabe et al. 1987).

The diagnosis of KD is clear-cut and must be based on clinical examination and histopathological findings. Histological section shows an intense, chronic inflammatory infiltrate mainly composed of lymphocytes that form lymphoid follicles with occasional germinal centres and numerous eosinophils that may form eosinophilic microabscesses. Lesser numbers of plasma cells and mast cells are found. There is also evidence of increased angiogenesis and fibrosis found within the lesion. Immunofluorescence studies show germinal centres containing significant IgE deposits and variable amounts of IgG, IgM and fibrinogen. These features are attuned with the three cases presented.

Imaging is often unhelpful as they may give a variable appearance and are non-specific especially with the use of plain radiograph. Ultrasound may demonstrate masses that are solid, round or oval, or hypoechoic but they do not really show the nature of the lesion and are not helpful in treatment planning. On a computerised tomogram, contrast enhancement may indicate the vascular nature of the lesion, but this does not appear to be a consistent finding. Involved tissues may demonstrate high T1 and T2-weighted signal intensities on Magnetic Resonance Imaging, with the use of contrast enhancement such as gadolinium-DTPA. Although not diagnostic of KD, CT and MRI findings may help to delineate the extent of the disease in more than one plane (Nagamachi et al. 1996; Goldenberg et al. 1997).

Kimura's disease is a benign but disfiguring disease, and often follows a protracted course with no evidence of malignant transformation. Various treatment modalities for KD have been suggested. Surgical excision may be indicated for cosmetic reasons, or when lesions invade vital head and neck structures. Recurrence is common, occurring in up to 25% of cases treated with surgical excision alone (Day et al. 1997). Recurrent lesions may be treated with systemic steroid therapy, but seldom result in a cure. Radiotherapy may be indicated for patients with tumour relapse after steroid withdrawal or for recurrent disease. Hareyama et al, using radiotherapy at dosages of 26-30 Gy, achieved local control in 90% of cases, and they strongly recommend that no surgical procedure other than a biopsy should be carried out. The radiation field should be limited to the lesion and adjacent lymph nodes, with an optimum dosage of 26-30 Gy regardless of tumour size (Hareyama et al. 1998).

The advantage of radiotherapy for KD is that it offsets the need for long-term corticosteroids, but considering the benign nature of KD and the concern regarding malignant transformation of the condition, radiotherapy should be reserved as second line treatment. Cyclosporin A and other therapeutic interventions such as argon and CO₂ laser vapourization, retinoic acid, cytotoxic agents, electrodesiccation and curettage have also been used though with variable success rates (Senel et al. 1996). Therapy for KD will remain directed at the symptoms of the disease rather than at the causative agents as the aetiology of the disease is still unknown. At the moment, surgery is still the treatment of choice as it can be both diagnostic and therapeutic.

ACKNOWLEDGEMENT

The authors would like to thank Kelvin Lim Lye Hock of the Department of Oral and Maxillofacial Surgery, Faculty of Dentistry, Universiti Kebangsaan Malaysia, for his contribution to the article.

REFERENCES

- Day TA, Abreo F, Hoajsoe DK, Aarstad RF, Stucker FJ. 1995. Treatment of Kimura's disease: a therapeutic enigma. *Otolaryngol. Head Neck Surg.* 112:333-337.
- Goldenberg D, Gatot A, Barki Y, Leiberman A, Fliss DM. 1997. Computerized tomographic and ultrasonographic features of Kimura's disease. *J. Laryngol. Otol.* 3:389-391.
- Hareyama M, Oouchi A, Nagakura H, Asakura K, Saito A, Satoh M, Tamakawa M, Akiba H, Sakata K, Yoshida S, Koito K, Imai K, Kataura A, Morita K. 1998. Radiotherapy for Kimura's disease: the optimum dosage. *Int. J. Radiat. Oncol. Biol. Phys.* 40(3):647-651.
- Kennedy SM, Pitts JF, Lee WR, Gibbons DC. 1992. Bilateral Kimura's disease of the eyelids. *Br. J. Ophthalmol.* 76:755-757.
- Kimm HT, Szeto C. 1937 Eosinophilic hyperplastic lymphogranuloma, comparison with Mickulicz's disease. *Proc. Chin. Med. Soc.* 23:699-700.
- Kimura T, Yoshimura S, Ishikawa E. 1948. Unusual granulation combined with hyperplastic change of lymphatic tissue. *Trans. Soc. Pathol. Jpn.* 37:170-180.
- Kung ITM, Gibson JB, Bannatyne PM. 1984. Kimura's disease: a clinicopathological study of 21 cases and its distinction from angiolymphoid hyperplasia with eosinophilia. *Pathol.* 16:39-44.
- Kuo TT, Shih LY, Chan HL. 1988. Kimura's disease. Involvement of regional lymph nodes and distinction from angiolymphoid hyperplasia with eosinophilia. *Am. J. Surg. Pathol.* 12:843-854.
- Li TJ, Chen XM, Wang SZ, Fan MW, Semba I, Kitano M. 1996. Kimura's disease: a clinicopathologic study of 54 Chinese patients. *Oral Surg. Oral Med. Oral Pathol. Oral Radiol. Endod.* 82(5):549-555.
- Matsuda O, Makiguchi K, Ishibashi K, Chida Y, Ida T, Matsuda K, Tomita K, Marumo F, Hiruma M. 1992. Long-term effects of steroid treatment on nephrotic syndrome associated with Kimura's disease and review of the literature. *Clin. Nephrol.* 37:119-123.
- Nagamachi S, Hoshi H, Ohnishi T, Jinnouchi S, Flores LG, Futami S, Watanabe K, Tsuboi Y, Miyanaga S, Morimitsu T. 1996. TI-201 SPECT in Kimura's disease involving the parotid glands and cervical nodes. *Clin. Nucl. Med.* 21:125-128.
- Peters E, Altini M, Kola AH. 1986. Oral angiolymphoid hyperplasia with eosinophilia. *Oral Surg. Oral Med. Oral Pathol.* 61:73-79.
- Qunibi WY, Al-Sibai MB, Akhtar M. 1988. Mesangio-proliferative glomerulonephritis associated with Kimura's disease. *Clin. Nephrol.* 30:111-114.

- Sawada Y, Nomura K. 1984. Kimura's disease: a case report. *J. Dermatol.*11:487-492.
- Senel MF, Van Buren CT, Etheridge WB, Barcenas C, Jammal C, Kahan BD. 1996. Effects of cyclosporine, azathioprine and prednisone on Kimura's disease and focal segmental glomerulosclerosis in renal transplant patients. *Clin. Nephrol.*45(1):18-21.
- Tabata H, Ishikawa O, Ohnishi K, Ishikawa H. 1992. Kimura's disease with marked proliferation of HLA-DR+ CD4+ T cells in the skin, lymph node and peripheral blood. *Dermatol.*184:145-148
- Takenaka T, Okuda M, Usami A, Kawabori S, Ogami Y. 1976. Histologic and immunologic studies on eosinophilic granulation of soft tissue, so called Kimura's disease. *Clin. Allergy.*6:27-39
- Tham KT, Leung PC, Saw D, Gwi E. 1981. Kimura's disease with salivary gland involvement. *Br. J. Surg.*68:495-497
- Urabe A, Tsuneyoshi M, Enjoji M. 1987. Epitheloid haemangioma versus Kimura's disease. *Am. J. Surg. Pathol.*11:758-766
- Wierenga EA, Backx B, Snoek M, Kapsenberg ML.1993. Relative contributions of human types 1 and 2 T-helper cell-derived eosinophilic cytokines to development of eosinophilia. *Blood.* 82:1471-1479

Roslan Abdul Rahman
Roszalina Ramli
Ghazali Mat Nor
Department of Oral and Maxillofacial Surgery
Faculty of Dentistry
Universiti Kebangsaan Malaysia

Fadzilah Ismail
SHA Primuharsa Putra
Department of Otorhinolaryngology
Faculty of Medicine
Universiti Kebangsaan Malaysia

FIGURE 1 (Case 1)

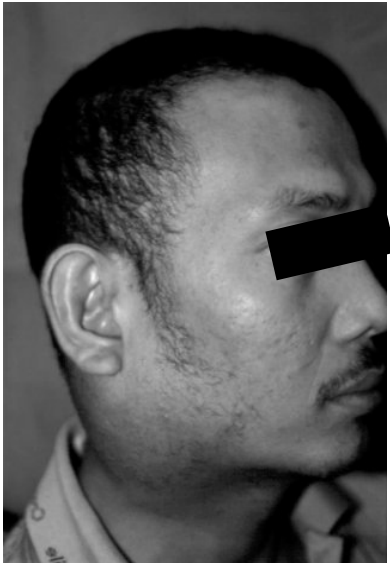

Figure 1 a

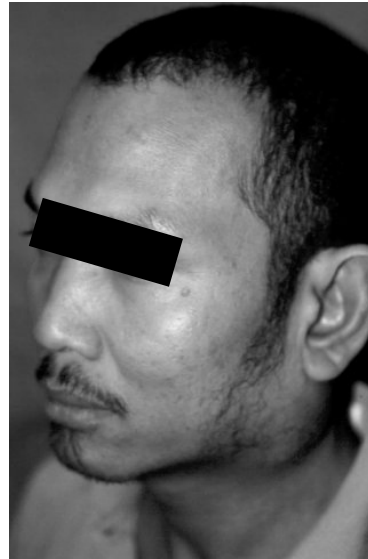

Figure 1 b

Figure 1 a and b show swelling involving bilateral parotid glands

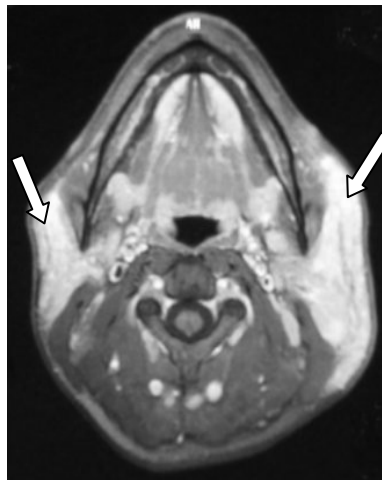


Figure 1 c
Axial MRI with IV contrast (Gd-DTPA)
showing the lesions bilaterally (arrows)

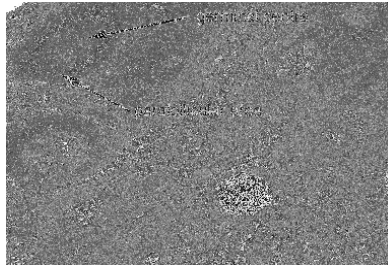


Figure 1 d
Histopathology showing lymph node tissue
composed of hyperplastic follicles with prominent
germinal centers (H & E, x10)