

Case report

Clinical Submission of Supernumerary Head of Adductor Brevis Muscle

Vandana M(✉), Suri R, Ravi S, Vandana D, Gayatri R.

Department of Anatomy, Vardhman Medical College & Safdarjung Hospital, New Delhi-4, India

Abstract

Adductor brevis is an important member of the adductor family occupying the medial compartment of the thigh executing the function of adduction and medial rotation. Deviations from normal anatomy are unusual and rarely reported. A survey of anatomical archives revealed occasional mention of additional bellies of adductor brevis muscle. The present study reports a double belly of adductor brevis muscle (AB) found during a cadaveric dissection class for medical students. The left sided AB displayed two bellies disposed in the same plane. This case report attempts to present the clinical applications of supernumerary bellies of this important adductor muscle of the thigh. It is feasible to categorize these muscular variations upon specialized radiological procedures such as CT and MRI scans only if the radiologist possesses satisfactory understanding of variant anatomy of this region. It is thereafter inferred that upon recognition these muscles present a fair chance of being utilised in reconstructions. A biomechanical overview of the present anomaly is also attempted.

Keywords: Adductor brevis, reconstructions, supernumerary, variations

Correspondence:

Dr. Vandana Mehta, Associate Professor, Department of Anatomy, Vardhman Medical College & Safdarjung Hospital, New Delhi, New Delhi-100004, India.

Tel no: 0091-9910061399 Email: drvandanamehta@gmail.com

Date of submission: 23rd Dec 2010

Date of acceptance: 16th Feb 2011

Date of publication: 6th Apr 2011

Introduction

The triangular adductor brevis (AB) arises by a narrow origin from the outer surfaces of the inferior pubic ramus between the gracilis and obturator externus. The fibres pass backward, laterally and downward displaying a linear aponeurotic insertion from the lesser trochanter to the linea aspera and into the upper part of the linea aspera, immediately behind the pectineus and upper part of the adductor longus (1).

AB is frequently divided into two or three parts. It derives its innervation from the anterior and posterior branches of obturator nerve (2). The primary actions of AB are flexion, adduction and medial rotation of the thigh. There is a surfeit of clinical settings in which a scrupulous acquaintance with anatomical variants of AB is compulsory for apt implementation of perineal reconstructions. (3)

We presume that from the biomechanical point of view, if the accessory belly of AB is sacrificed for reconstructive reasons, there would be negligible functional loss as the main AB will take over the adduction function.

Case report

The left adductor region of an adult male cadaver of Indian origin revealed an unusual supernumerary muscle during an undergraduate practical class. As the adductor longus was reflected to study the AB and pectineus, we encountered an atypical supernumerary muscle in relation to the AB muscle. This muscle was lying in the same plane as the pectineus. (Fig 1) The origin of the muscle was from the inferior pubic ramus close to the origin of AB.

The main belly of left sided AB measured 12 cm and 5 cm in width. The accessory belly being smaller measured 7 cm in length and 2 cm in width. The insertion of the accessory belly was adjacent to the main belly. The dimensions of the right sided AB

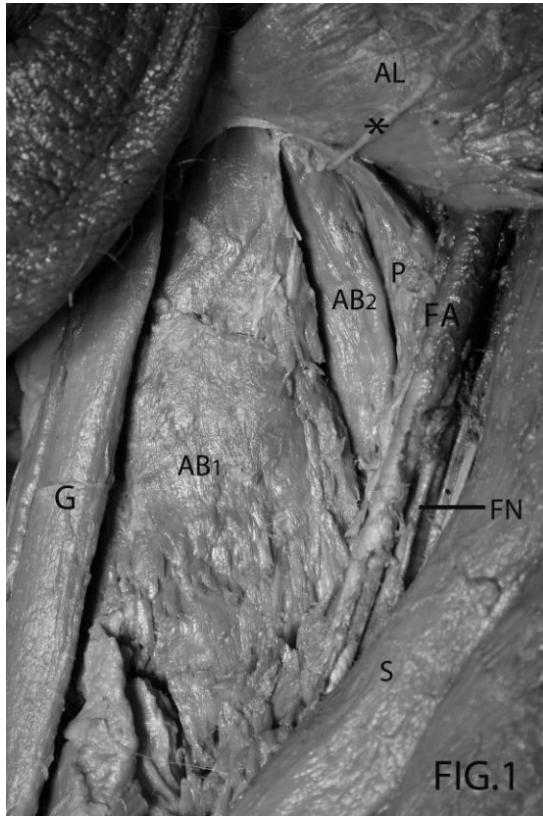


Fig 1: Photograph of adductor region of the left side showing the following:

G-Gracilis muscle; S- Sartorius muscle; P- Pectineus muscle; AL- Adductor Longus muscle; AB₁- Adductor brevis; AB₂- Accessory belly of adductor brevis; FN- Femoral nerve; FA- Femoral artery; *- Branch of femoral nerve to the accessory belly.

were 9 cm in length and 2.5 cm in width. The neural innervation of the accessory muscle was derived from the obturator nerve. Other muscles in the vicinity exhibited normal morphology. No neurovascular incongruity was observed.

Discussion

An earlier study clarified the true nature of AB, determining its dual innervations from the anterior and posterior branches of obturator nerve. The specific AB was found to occur in 23% of cases and the anterior and posterior branches of obturator nerve supplied the respective surfaces of the muscle. The authors arrived at the conclusion that at some stage in

the ontogenic process, the specific AB was formed by means of a fasciculus which had separated from the obturator externus and fused secondarily to the posterior surface of regular AB (4).

A supernumerary muscle present between the AB and adductor minimus was described in a previous report. An incidence of 33% was recorded by the authors. It stemmed from the inferior pubic ramus and inserted into the aponeurosis of adductor minimus muscle, pectineal line or the posterior aspect of lesser trochanter's base. It derived its innervation from its posterior aspect, by a filament from the twig originating from the posterior branch of the obturator nerve. It was deduced further that the additional muscle may have formed as a result of detachment from the superficial layer of the obturator externus during the process of ontogeny (5).

A similar case report described an anomalous muscle between AB (50.7%) as well as an abnormal fasciculus fused to the posterior surface of the adductor minimus (24.7%). These authors came to the conclusion that the original obturator externus muscle (OE) readily underwent variation in the process of ontogeny due to the influence of the obturator nerve. Although the anomalous muscle found in the present study appeared to be independent of the OE, we are sure of the role of ontogeny in the embryogenesis of the muscle (6).

Reconstructive surgery was attempted in myelomeningocele patients with subluxating or dislocated hips, where posterolateral iliopsoas were treated by transfers. Surgery was performed at 1 year of age with bilateral adductor transfer to the ischium, followed in 2 weeks by the posterolateral transfer of the iliopsoas muscle. The transferred iliopsoas muscle has a better mechanical advantage in its new function as an abductor and extensor, and the hips were better centered radiographically than the cases with iliopsoas transfer alone (7).

Additionally, myelodysplastic patients with subluxation or dislocation of the hip were treated surgically by transferring the origins of AB along with the other adductors to the ischial tuberosity. The presence of an additional belly of AB could possibly be utilized for the same purpose, thereby sparing the other adductors for the adduction function which otherwise weakens as a result of the transfer. In fact, an improved muscle balance with fewer flexion-adduction contractures and a higher incidence of stable hips at follow-up (8).

Adductor muscle strain may prove to be incapacitating for the athlete especially if improperly treated. Sports surgeons resort to adductor release and tenotomy only if other rehabilitative procedures fail to cure the patient of pain and debility (9).

An uncommon simultaneous occurrence of acute abscess of iliopsoas and AB leading to proximal leg muscle weakness was explained in a prior study. This case was confirmed by CT and MRI scans. Often, a CT guided percutaneous drainage of the abscess is sought by the surgeons. Lack of knowledge of this additional belly of AB could lead to erroneous diagnosis and consequent delay in treatment which might prove catastrophic for the life of the patient (10).

The trans obturator tape procedure (TOT) procedure has been noted the safest and most minimally invasive treatment of stress urinary incontinence in women. A rare complication of post operative AB myositis in an otherwise safe technical procedure was described in a prior case report. The presence of two bellies of AB muscle could burden the surgeons further by probably aggravating the problem and jeopardizing the treatment outcome of the patient (11). Another cadaveric study incorporated the usage of trans vaginal tape in female cadavers to explore efficacy of a trans obturator approach. The adductors were separated from their attachments. In order to pass from the superficial subcutaneous fat to the obturator muscles the tape was inserted into three adductor muscles -gracilis, AB and magnus. However, it was submitted that the tape traversed the AB muscle in 7 of 10 TVT-O passages (group 1 cadavers). We strongly believe that anatomical variation pertaining to AB muscle will have a direct bearing on the safe implementation of this reparative procedure. Furthermore, these authors favored the trans obturator approach as it offered negligible bladder, urethral, vascular, digestive and neurological complications (3).

Ultrasound imaging has been successful in localizing the medial femoral region with 100% clarity. Additionally, this region is frequently used as a landmark for localization of the common obturator nerve with a success rate of 80%. There is considerable inconsistency in the obturator nerve's divisions and subdivisions and this is reflected in the form of tribulations frequently encountered in the application of regional anesthetic techniques (12).

Conclusion

We summarise that adequate anatomical erudition of the medial femoral region with the possible muscular variations is indispensable for proper performance of surgeries and reconstructions.

References

1. Sinnatamby CS. Lower limb. In: Last's Anatomy. 10th Ed. Edinburgh: Churchill Livingstone; Churchill Livingstone 1998. p. 327.
2. Bergmann RA, Afifi AK, Miyauchi R. Adductor brevis. Illustrated encyclopedia of human anatomic variation: Opus I: Muscular System: Alphabetical listing of muscles: <http://www.anatomyatlases.org/AnatomicVariations/MuscularSystem>
3. Bonnet P, Waltregny D, Reul O, de Leval J. Transobturator vaginal tape inside out for the surgical treatment of female stress urinary incontinence: anatomical considerations. *J Urol* 2005 Apr; 173(4):1223-8.
4. Miura M, Nakamura E, Kato S, Usui T, Miyauchi R. The true nature of the adductor brevis dually innervated by the anterior and posterior branches of the obturator nerve in humans. *Okajimas Folia Anat Jpn* 1994 Aug;71(2-3):67-82.
5. Nakamura E, Masumi S, Miura M, Kato S, Miyauchi R. A supernumerary muscle between the adductors brevis and minimus in humans. *Okajimas Folia Anat Jpn* 1992 Aug;69(2-3):89-98.
6. Yatsunami M, Tai T, Irie Y, Ogawa K, Miyauchi R. A morphological study on the human obturator externus muscle with reference to anomalous muscle and anomalous fasciculus originating from the obturator externus muscle. *Okajimas Folia Anat Jpn* 2004 Mar;80(5-6):103-14.
7. Benton LJ, Salvati EA, Root L. Reconstructive surgery in the myelomeningocele hip. *Clin Orthop Relat Res* 1975 Jul-Aug;(110): 261-8.
8. London JT, Nichols O. Paralytic dislocation of the hip in myelodysplasia. The role of the adductor transfer. *J Bone Joint Surg Am* 1975 Jun;57(4): 501-6.

9. Nichols SJ, Tyler TF. Adductor muscle strains in sport. *Sports Med* 2002;32(5): 339-44.
10. Chalaupka FD. Acute iliopsoas and adductor brevis abscesses presenting with proximal leg muscle weakness. *Neurol Sci* 2006 Jun; 27(2): 125-28.
11. DeSouza R, Shapiro A, Westney OL. Adductor brevis myositis following transobturator tape procedure: a case report and review of the literature. *Int Urogynecol J Pelvic Floor Dysfunct* 2007 Jul;18(7):817-20.
12. Anagnostopoulou S, Kostopanagiotou G, Paraskeuppoulos T, Chantzi C, Lolis E, Saranteas T. Anatomic variations of the obturator nerve in the inguinal region: implications in conventional and ultrasound regional anesthesia techniques. *Reg Anesth Pain Med* 2009 Jan-Feb;34(1):33-9.