

A Novel Approach to CT Scans' Interpretation via Incorporation into a VR Human Model

Sophia Sakellariou¹, Vassilis Charissis², Ben M. Ward³,
David Chanock⁴, and Paul Anderson²

¹ Aberdeen Royal Infirmary, Acute Medicine, Aberdeen, UK

² University of Glasgow/ Glasgow School of Art, Digital Design Studio,
10 Dumbreck Road, G41 5BW, Glasgow, UK

³ University of Edinburgh, UK

⁴ Ayr Hospital, Department of Radiology, Ayr, UK
v.charissis@gsa.ac.uk

Abstract. This paper presents a novel approach for interpretation of Computerised-Tomography (CT) scans. The proposed system entails an automated transfer of selected CT scans onto a default Virtual Reality human model. Contemporary training requirements often are proven to be time-consuming for the clinical facilities which have to split unevenly their operational time between radiological examinations and the Radiologists' training. Adhering to the contemporary training requirements we employed a plethora of VR and Human-Computer Interaction techniques in order to enable the trainees to familiarise themselves with the interpretation of such data and their actual, spatial correlation inside the human body. Overall the paper presents the challenges involved in the development of this method and examines the potential as well the drawbacks for deployment of such system in large scale teaching audience. Finally the paper discusses the results of an initial user-trial, which involved twelve trainee doctors, and offers a tentative plan of future work which aspires to customise the software for different learning levels.

Keywords: HCI, CT scans, VR Human Model, Medical Training.

1 Introduction

Contemporary technological advancements have enabled the health-related sciences to enter a new era, commonly described as the era of computer-aided medicine. In particular, the use of Computer Tomography (CT) plays a significant role in the understanding of human anatomy and pathology as the scrutinizing visual and volumetric analysis of the scanned data can offer a clear view of a patient's condition. In the early stages of medical training however, analysis of CT imaging can be convoluted, as correct interpretation of the radiological images mainly relies upon a three dimensional (3D) internal understanding of anatomy that each user acquires through training.

A plethora of randomized controlled studies have shown positive learning outcomes in basic undergraduate anatomy teaching with the use of 3D visualizations and novel user-interfaces in conjunction with existing radiological and diagnostic imaging [1]. Early samples of such combinatory approach can be found in the user interface

designed for the Visible Human Explorer which allows navigation between coronal section overviews and axial image previews with the use of sliders that animate the cross-sections through the body [2].

Subsequent studies that additionally involved Virtual Reality (VR) and direct manipulation interfaces have demonstrated a positive impact in shortening the learning curve in medical training [3, 4, 5, 6]. A fusion of CT and VR has also been used in clinical applications where interventional radiologists utilised this combinatory approach for performing percutaneous controlled radiofrequency trigeminal rhizotomy (RFTR) assisted by a VR imaging technique for idiopathic Trigeminal Neuralgia [7]. Similarly Virtual Reality and Augmented Reality have been employed to enhance the CT understanding and support in real-time surgical operations and in surgical rehearsal and simulation [5, 8, 9]. Yet the potential role of enhanced visualization in radiological training is still a largely uncharted area.

This paper presents the development process of a hybrid method which merges Virtual-Reality with contemporary CT scan planes. In turn the system under investigation has been evaluated through a comparative study in-between contemporary teaching methods and the proposed VR-CT. The paper will describe analytically the users' reactions and performance results, offer a discussion of the preferences and feedback and conclude with future aspirations and plans for the continuation of this research to a level that would have a direct, positive impact on medical training.

2 CT Transfer Process into VR Environment

Adhering to the above observation with regard to the contemporary CT interpretation teaching we endeavoured into the development of a methodology which would enable the direct transfer of CT scans to a VR environment. To this end an initial assertion of the data transfer and different process had to be planned in order to provide the project with a course of action map which is described in turn.

The original CTs had to pass through a format alteration in order to minimise their size without though compromising their clarity. The reason of this action reflects the necessity of small files which could be easily transferred as texture maps onto transparent 3D planes.

In the second step the projected images were forming a block of 3D planes which corresponded to the actual CT slices. This equally segmented block was then incorporated onto the VR human model corresponding to the depicted area (i.e. chest CT intersecting the chest area of the model). The accuracy of intersection is acceptable, if we consider the projection issues into a VR environment and the data manipulation with haptic devices. Although still under-development, the software follows precisely the borders of the major organs (i.e. lungs) by tracking the borders of the 3D lungs' model with the employment a borders' pattern analysis algorithm.

It has to be noted that due the large number of CTs that typically depict a specific section of the human body, we opted for a selection of scans (i.e. one every ten images) which will still track the shape of the organ structures without though delaying the uploading process. Furthermore during the development period we received feedback from mini-trials which led us to the conclusion that the interface should facilitate a "hide" option which will make fully transparent the majority of CT scans and retain only a small number which might be more challenging to interpret or they have some specific/rare pathology illustrated.

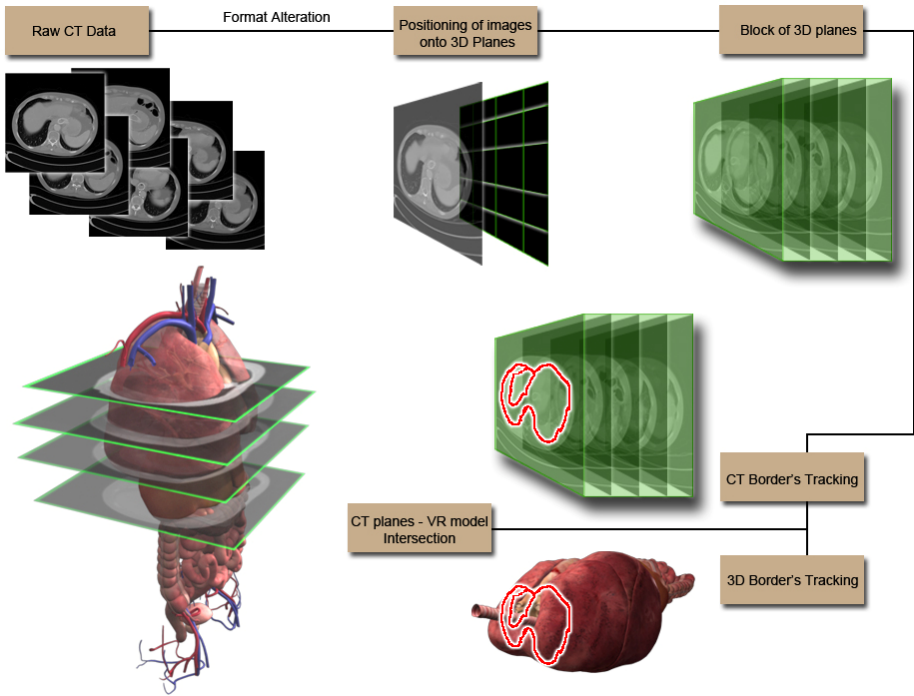


Fig. 1. Workflow for the incorporation of CT scans into the VR human model

3 Interface Development for VR-CT

By the completion of the workflow and the successful encounter of implementation issues we proceeded in the development of a Human-Computer Interface which would empower the user to navigate in real-time through the VR human model and investigate the spatial relations and the actual depicted CT data.

In particular, we have developed a prototype HCI system in which it is possible to incorporate selectively individual CT scans which correlate perfectly with a “default” 3D human body. This enables the users to explore in the virtual environment the positioning of particular human body elements and improve their interpretation abilities by investigating the sectioning CT images. The interface development aimed to depict meaningful information that could enhance the learning process of the trainee doctors in a synthetic environment. Our focusing point was on the interface functionalities, which will enable trainees to mentally perceive the three-dimensional structure of the human body and navigate through, discovering and perfecting information acquisition and interpretation. These interface components present fresh opportunities for the portrayal of scanned data featuring an infinite selection of viewing positions.

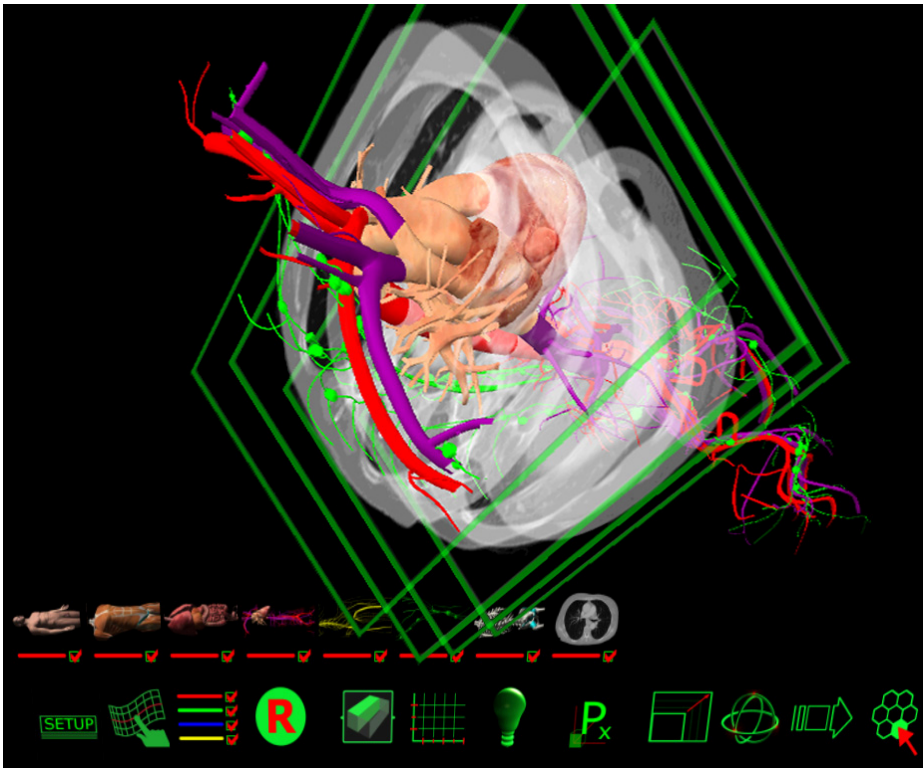


Fig. 2. (a) Screenshot of user during manipulation of the incorporated CTs into the VR human model; (b) Interface bars: human layers (top), default actions (bottom)

Such functionality offers the ability to the users to mentally triangulate the position of the anatomical structures and correlate them instantly to the CT depictions. Our attempt to directly apply publicly accepted interface components to the medical training environment was a challenging process as the icons had to be designed in accordance to the requirements of each section. To this end the icons were showing miniature representations of the layers as illustrated in the upper toolbar of Figure 3. In this particular case study the virtual interface was enriched with a CT icon which revealed four distinctive CT images in the thoracic area.

4 Experiment Rationale

A comparative study was deemed essential in order to identify and evaluate the potential benefits and pitfalls of the VR-CT teaching versus traditional methods of teaching the interpretation of CTs. The VR environment utilized for this experiment was equipped with haptic-glove for “hands-on” interaction with the 3D human model as illustrated in figure 3.

A sample of twelve foundation year doctors (FYs) were randomly selected and divided in two groups which were lectured with a VR method and the traditional routine

respectively. Their performance was measured through a series of pre and post teaching as presented below. A usability questionnaire was employed to capture their thoughts and feedback with regards to these two diverse teaching techniques.

1. Pre assess Likert (demographics etc)
2. The pre-assessment quiz (10mins)
3. 5 minutes with the CT activator sheet
4. Intervention (15mins tutorial - focus on the structures on the CT)
5. Post assessment (CT spot test)
6. Usability questionnaire (no limit)

In this paper we are focusing our analysis on the pre and post-assessment results derived by Likert-scale questionnaires which can be indicative of the proposed systems positive aspects as well as of potential issues arising.

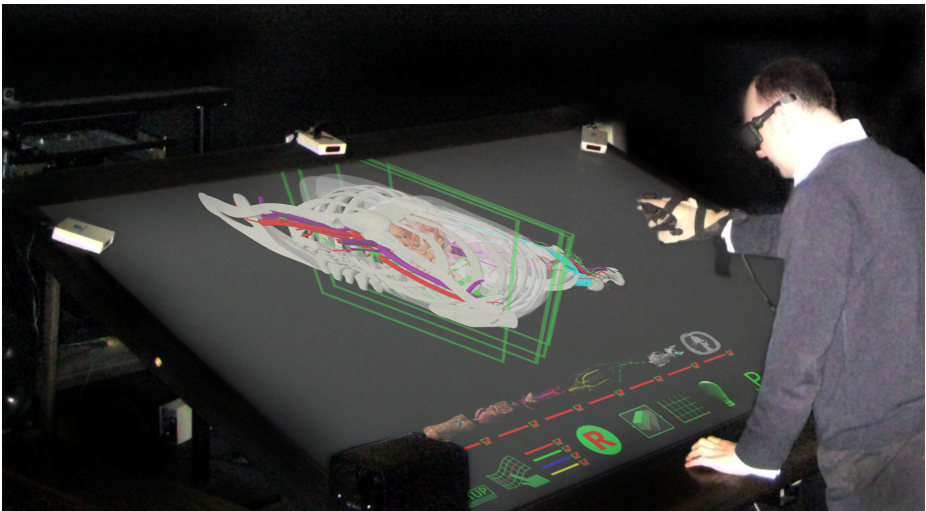


Fig. 3. Investigation of CT data through VR during the user-trials

5 Results

The pre-assess Likert questionnaire aimed to establish that there were no significant differences between the two subgroups of users in relation to their familiarity with system technology, anatomy knowledge, training experience, exposure to pro-section and dissection teaching methods and previous focused CT interpretation practice. All twelve users had comparable experience of anatomy training, had graduated from UK medical schools, and had on average between 8 and 12 months exposure to surgical hands on training at “house officer” level.

All users graded themselves moderately computer literate; none had previous experience in VR environments, and all only had minimal CT interpretation teaching.

Furthermore, the pre-assess Likert study explored the users’ views on current anatomy teaching and their learning behaviours on interpreting 3D data for clinical use. Their responses were very similar, with no significant differences in p-values in any

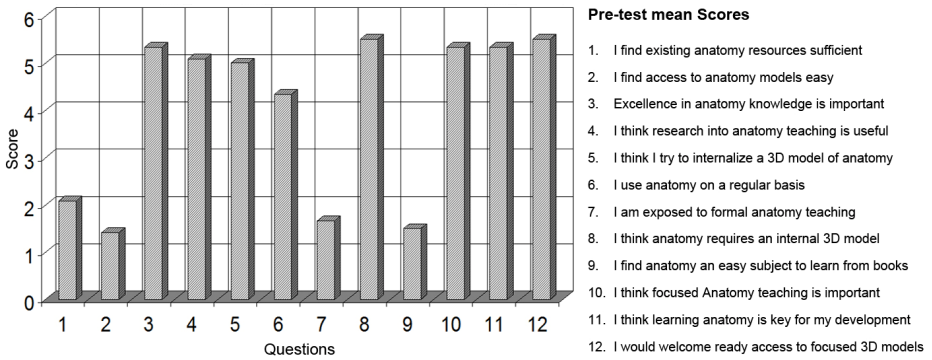


Fig. 4. Pre-test mean scores in all 12 pre-assess Likert questions

of the attitude determining questions ($p>0.05$). Notably, the trainees uniformly expressed the view that current anatomy teaching in undergraduate level and during clinical years is fragmented, limited and lacking in depth, whilst the teaching methods were described as time consuming and non-engaging.

A confounding 80% of users found it difficult to construct a mental 3D map of the human anatomy from studying 2D models and thus application of their anatomy knowledge in a clinical interpretation scenario was graded as inadequate for their clinical needs.

In similar numbers, 75% of users strongly agreed that further enhancement of their anatomy training will aid their clinical practice with the remaining 25% agreeing with the aforementioned, but not as strongly. The pre-test mean scores for all questions are presented diagrammatically in Figure 4.

The pre-assessment quiz consisted of open questions relating to the anatomy involved in the study, namely the thorax as depicted on CT scans. It established the baseline knowledge of the users prior to any intervention and was compared with the post intervention assessment quiz. The aims of the exercise were two-fold: Identify the user's prior pure anatomy knowledge and familiarity with CT scans and furthermore elucidate their ability to comprehend how anatomical structures relate to each other in a 3D environment..

The latter was assessed by questions referring to space relations of superimposed structures in 2D images (i.e. posterior/anterior). It is of interest to note that although the distribution of answers in regards to pure anatomy knowledge followed the normal distribution curve, with most users scoring adequately in those questions, the distribution was negatively skewed on questions relating to 3D relationships.

Both groups improved on their scores after the teaching intervention, as expected, the traditional method group with a mean improvement in scores of 18%, whilst the VR method group with a mean percentage improvement of 22%. Scores were not significantly different between the two groups either pre-intervention ($p=0.36$) or post intervention ($p=0.50$).

Despite both methods of training producing statistically comparable results overall, on single factor ANOVA, on analysing particular questions relating to the spatial relationship of structures, the VR group had a distinct advantage with 50% more correctly answered questions ($p=0.007$).

On concluding the experiment all users completed the usability questionnaire, where they were asked to grade their views about the educational approach. In total 25 statements were graded on a 6 point Likert scale. The views of the two groups were markedly different on almost all points with p values less than 0.001 on two sample t-testing. Positively phrased statements regarding the educational approach scored very highly in the VR group whilst scoring low in the traditional method group and vice versa for negatively phrased statements. The only points that did not exhibit such a highly significant difference related to the ease of use of the system and the familiarity with the interfaces. Notably even in these questions the response in the VR group was positive, with the majority of users finding the VR system more engaging, interesting and easy to use and more efficient in elucidating spatial inter-relationships of structures. Users preferred the VR system over traditional teaching methods and they were more inclined to recommend it to their peers ($p < 0.001$ compared to the traditional method group responses).

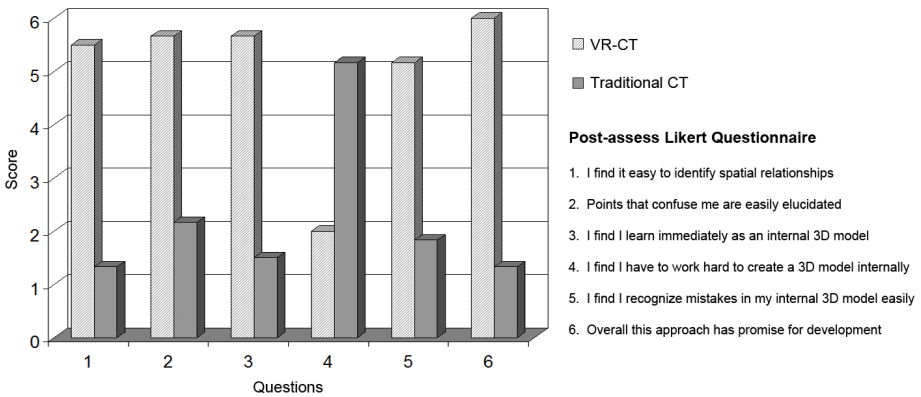


Fig. 5. Post-assess Likert scores in 6 selected questions relevant to the 3D anatomical awareness and the CT interpretation

It is quite interesting to note the feedback provided by the users in six particular questions that were aiming to identify the potential impact of the VR explanatory method and interpretation of CT images against the traditional process. Evidently the VR method was highlighted as the favourite as Figure 5 illustrates. The results of these specific questions are further discussed in the following section.

6 Discussion

The ongoing analysis of the derived evaluation data suggested that the incorporation of selective CT scans in a VR environment offers great flexibility on the reviewing process of the scans against the 3D volumes of the anatomical structures. However the existing interface did not offer a clear view of the sections that the scans slice. Such issues could be resolved however, in future developments of the system.

Interestingly the presentation of the same 3D human model and the dissecting CT images were deemed considerably more helpful in the 3D environment of the development software presented in a PC monitor.

Despite the positive conclusions drawn from the experimental analysis of the data there are a few confounders introducing bias that need to be considered given the small numbers involved in the study. As most users involved in the trial were volunteers a more positive response was expected with the VR educational approach as this is the most innovative and a novelty for trainees. The pre-Linkert questionnaire had already established their dislike of current educational methods and as such a more technologically advanced approach might have been positively received despite of its merits. In analysing the pre and post quizzes however, the VR approach proved significantly better in elucidating 3D structures, a fact unrelated to the trainees' behaviour towards this approach.

6.1 VR Group

In particular the VR group spent more time to investigate the structural data of the model and how these could be depicted in each section presented in a CT scan. This elaborate investigation offered a better understanding of the spatial correlation of the organs, muscular and skeletal structures illustrated in each CT.

- The favourite interaction tool was the layer remover (as in every other case study that we evaluated). In this case-study it enabled the doctors to remove even the scans from their original positions, investigate them and reposition them back to the 3D human body.
- The transparency tool offered an additional way to interact with the data and "clear-partially" whole sections which were obstructing the doctors from viewing the scans inside the human body.
- Finally the slicing tool presented an alternative to both aforementioned tools in order to virtually slice the model in any possible angle or in alignment with the CT scans.

6.2 Contemporary Group

The response of the contemporary-learning method group appeared on the antipode of the VR group, as the following selection of common reactions suggest.

- The black and white "dry" representation of scans was again quite confusing for the FYs that went through the traditional teaching process.
- The 2D depictions and illustrations offered a better solution as they presented specific parts of the anatomy. However due to the complexity of this particular structure a number of different in-depth layers could not be revealed simultaneously, resulting to a tortuous process of providing a plethora of different drawings presenting different angles of different sections.

Notably the investigation of the whole lot of the CT scans (250 sections involved in this part of the body) could be significantly easier and more meaningful through the CT viewing program installed in hospital facilities. However it could still be a challenging process to interpret specific pathologies appearing in a CT, if a trainee does not have a considerable amount of familiarization time with the CT viewers. As such

stripping the CT scans from their original functionalities we were able to identify the ability of each user to illustrate in a 3D mental map the CT depictions, with and without the support of a VR training session.

7 Conclusions

The initial analysis of the data suggests that the VR-CT representation could potentially clarify the spatial correlation between different structures that might be difficult to interpret directly in a CT scan. However it was obvious that the incorporation of the CT scan in a synthetic environment has to be enhanced with a number of other interactivity tools. Additionally the ultra-sensitive tracking devices of the VR space should be toned down in order to allow the users to investigate the CTs and the 3D model without the artefacts produced by the “trembling” of the physical movements of the user’s head and hand.

Our tentative future plan of work aims to improve the performance of the system and potentially create an automated transfer of CT scans in a VR body in order to enable the medical trainees and practitioners to explore different pathological issues coming from a variety of patients. Such functionality might be extended in order to enhance also the surgical rehearsal process.

Concluding, we aspire to incorporate additional scan data from different sources, demonstrate in the virtual environment the different types of information that could be derived and trial them out in all medical schools across Scotland incorporating in our study a much greater number of trainees and thus reducing any potential bias.

Acknowledgements

The authors would like to express their gratitude to the staff of the Radiology Department of Ayr hospital in Scotland for the provision of CT images and their enthusiastic collaboration.

References

1. Nicolson, T., Chalk, C.: Can virtual reality improve anatomy education? A randomised controlled study of a computer-generated three-dimensional anatomical ear model, *Medical Education* 40, 1081–1087 (2006)
2. North, C., Shneiderman, B., Plaisant, C.: User Controlled Overviews of an Image Library: A Case Study of the Visible Human. In: *Proceedings 1st ACM International Conference on Digital Libraries*, pp. 74–82 (1996)
3. Sang-Hack, J., Bajcsy, R.: Learning Physical Activities in Immersive Virtual Environments. In: *IEEE Proceedings of the International Conference on Computer Vision Systems, ICVS 2006*, St. Johns University, Manhattan, New York City, USA (2006)
4. Pandey, P., Zimitat, C.: Medical Students’ Learning of Anatomy: Memorisation, Understanding and Visualization. In: *Medical Education*, vol. 41(1). Blackwell Science, Malden (2007)

5. Ward, B.M., Charissis, V., Rowley, D., Anderson, P., Brady, L.: An Evaluation of Prototype VR Medical Training Environment: Applied Surgical Anatomy Training for Malignant Breast Disease. In: Proceedings of the 16th International Conference of Medicine Meets Virtual Reality, Long Beach, California, USA (2008)
6. Satava, R.M.: Medical Applications of Virtual Reality. *The Journal of Medical Systems* 19 (1995)
7. Meng, F.-G., Wu, C.-Y., Liu, Y.-G., Liu, L.: Virtual Reality Imaging Technique in Percutaneous Radiofrequency Rhizotomy for Intractable Trigeminal Neuralgia, Technical Report appears in Elsevier (2008)
8. Soler, L., Nicolau, S., Schmid, J., Koehl, C., Marescaux, J., Pennec, X., Ayache, N.: Virtual reality and Augmented Reality in Digestive Surgery. In: Proceedings of the 3rd IEEE and ACM International Symposium on Mixed and Augmented Reality, ISMAR 2004, pp. 278–279 (2004); ISBN: 0-7695-2191-6
9. Eriksson, M., Dixon, M., Wikander, J.: A Haptic VR Milling Surgery Simulator-Using High-Resolution CT-Data. In: Proceedings of the 14th International Conference of Medicine Meets Virtual Reality, Long Beach, California, USA (2006)
10. Reitinger, B., Bornik, A., Beichel, R., Schmalstieg, D.: Liver Surgery Planning Using Virtual Reality, Virtual and Augmented Reality supported simulators. *IEEE Computer Graphics and Applications* (2006)