



Murdoch
UNIVERSITY

MURDOCH RESEARCH REPOSITORY

This is the author's final version of the work, as accepted for publication following peer review but without the publisher's layout or pagination.

The definitive version is available at

<http://dx.doi.org/10.1016/j.toxicon.2011.07.008>

Jacoby-Alner, T.E., Stephens, N., Davern, K.M., Balmer, L., Brown, S.G.A. and Swindells, K. (2011) *Histopathological analysis and in situ localisation of Australian tiger snake venom in two clinically envenomed domestic animals*. *Toxicon*, 58 (4). pp. 304-314.

<http://researchrepository.murdoch.edu.au/5338/>


Copyright: © 2011 Elsevier Ltd.

It is posted here for your personal use. No further distribution is permitted.

Accepted Manuscript

Title: Histopathological analysis and in situ localisation of Australian tiger snake venom in two clinically envenomed domestic animals

Authors: T.E. Jacoby-Alner, N. Stephens, K.M. Davern, L. Balmer, S.G.A. Brown, K. Swindells



PII: S0041-0101(11)00226-1

DOI: [10.1016/j.toxicon.2011.07.008](https://doi.org/10.1016/j.toxicon.2011.07.008)

Reference: TOXCON 4145

To appear in: *Toxicon*

Received Date: 23 March 2011

Revised Date: 8 July 2011

Accepted Date: 12 July 2011

Please cite this article as: Jacoby-Alner, T.E., Stephens, N., Davern, K.M., Balmer, L., Brown, S.G.A., Swindells, K. Histopathological analysis and in situ localisation of Australian tiger snake venom in two clinically envenomed domestic animals, *Toxicon* (2011), doi: 10.1016/j.toxicon.2011.07.008

This is a PDF file of an unedited manuscript that has been accepted for publication. As a service to our customers we are providing this early version of the manuscript. The manuscript will undergo copyediting, typesetting, and review of the resulting proof before it is published in its final form. Please note that during the production process errors may be discovered which could affect the content, and all legal disclaimers that apply to the journal pertain.

**Histopathological analysis and *in situ* localisation of Australian tiger snake venom
in two clinically envenomed domestic animals**

Jacoby-Alner, T.E.^{1,2}, Stephens, N.³, Davern, K.M.², Balmer, L.⁴, Brown, S.G.A.⁵ and Swindells, K.⁶

Highlights

- Venom-induced pathological changes were observed in the lungs, kidneys and muscle tissue of both patients
- Evidence, not previously noted, of procoagulant venom effects were apparent, with formed thrombi in the heart, lungs (small fibrillar aggregates and larger, discrete thrombi) and kidneys
- Work has shown pathological evidence of procoagulant venom activity supporting previous suggestions that an initial thrombotic state occurs in envenomed patients
- Illustrates venom localisation in the lung, kidney and muscle tissues of clinically envenomed animals

Histopathological analysis and *in situ* localisation of Australian tiger snake venom**in two clinically envenomed domestic animals**

Jacoby-Alner, T.E.^{1,2}, Stephens, N.³, Davern, K.M.², Balmer, L.⁴, Brown, S.G.A.⁵ and Swindells, K.⁶

¹ Centre for Forensic Science, University of Western Australia

² Monoclonal Antibody Facility, Western Australian Institute for Medical Research

³ School of Veterinary and Biomedical Science, Murdoch University

⁴ Centre for Diabetes Research, Western Australian Institute for Medical Research, and Centre for Medical Research, The University of Western Australia, Perth.

⁵ Centre for Clinical Research in Emergency Medicine, Western Australian Institute for Medical Research and University of Western Australia, Centre for Medical Research

⁶ Murdoch Pet Emergency Centre, School of Veterinary and Biomedical Sciences, Murdoch University

Conflicts of Interest: Nil

Corresponding Author: Tamara Jacoby-Alner, c/o Edith Cowan University, 270 Joondalup Drive, Joondalup, WA, 6027; Tel: +618 6304 2118; Fax: +618 6304 5717; Email: t.jacoby@ecu.edu.au

Abstract

Objective: To assess histopathological changes in clinically envenomed tiger snake patients and identify tissue specific localisation of venom toxins using immunohistochemistry.

Samples: One feline and one canine patient admitted to the Murdoch Pet Emergency Centre (MPEC), Murdoch University with tiger snake (*Notechis* sp.) envenoming. Both patients died as a result of envenomation. Non-envenomed tissue was also collected and used for comparison.

Methodology: Biopsy samples (heart, lung, kidney and skeletal muscle tissue) were retrieved 1-2 hours post death and processed for histopathological examination using Haemotoxylin and Eosin, Martius Scarlet Blue and Periodic Acid Schiff staining. Tissues were examined by light microscopy and tissue sections subjected to immunohistochemical staining using in-house generated monoclonal and polyclonal antibodies against *Notechis* venoms.

Results: Venom-induced pathological changes were observed in the lungs, kidneys and muscle tissue of both patients. Evidence, not previously noted, of procoagulant venom effects were apparent, with formed thrombi in the heart, lungs (small fibrillar aggregates and larger, discrete thrombi) and kidneys. Immunohistochemical assays revealed venom present in the pulmonary tissue, in and around the glomerular capsule and surrounding tubules in renal tissue and scattered throughout the Gastrocnemius muscle tissue.

Conclusion: This work has shown pathological evidence of procoagulant venom activity supporting previous suggestions that an initial thrombotic state occurs in envenomed patients. We have shown that venom toxins are able to be localised to specific tissues, in this case, venom was detected in the lung, kidney and muscle tissues of clinically envenomed animals. Future work will examine specific toxin localisation using monoclonal antibodies and identify if antivenom molecules are able to reach their target tissues.

Keywords: Tiger snake, *Notechis scutatus*, snake bite, envenoming, immunohistochemistry, histopathology.

Abbreviations: VICC: Venom-induced consumptive coagulopathy, Nsv: *Notechis scutatus* venom, PBS: Phosphate buffered saline, FBS: Fetal bovine serum, IHC: Immunohistochemistry, CK: Creatine kinase, MPEC: Murdoch Pet Emergency Centre, VDK: Venom detection kit, GM: Gastrocnemius muscle, H&E: Haemotoxylin and Eosin, MSB: Martius Scarlet Blue, PAS:

Periodic Acid Schiff, AV: antivenom, OCT: Optimal cutting temperature, APTT: Activated partial thromboplastin time.

ACCEPTED MANUSCRIPT

1
2
3
4
5
6
7
8
9
10
11
12
13
14
15
16
17
18
19
20
21
22
23
24
25
26
27
28
29
30
31
32
33
34
35
36
37
38
39
40
41
42
43
44
45
46
47
48
49
50
51
52
53
54
55
56
57
58
59
60
61
62
63
64
65

1. Introduction

1
2 There are up to 3,000 reported snakebites in humans (Sutherland and Leonard 1995; White 2000)
3 and an estimated 6,000 snakebites in domestic animals each year in Australia (Mirtschin et al.
4 1998), many requiring antivenom (AV) treatment. The most common, potentially lethal clinical
5 feature seen in envenomed humans is venom-induced consumptive coagulopathy (VICC); a result
6 of procoagulant toxins in the venom. The severity and occurrence of major clinical effects seen in
7 human and animal victims appears to differ. As shown by Isbister *et al.*, (2008) (Isbister et al.
8 2008), 90% of human tiger snake bite patients display VICC, with few presenting with neurotoxic
9 and myotoxic effects. In contrast, canine victims present more often with paralysis, though may
10 also present with clinical signs referable to coagulopathy (Holloway and Parry 1989). This may
11 be a reflection of differences in time since bite to discovery and treatment in the two groups and
12 that VICC may go unnoticed in animals. It is not uncommon for domestic animal envenomings to
13 be discovered hours, sometimes days after the bite or when symptoms are observed, whereas
14 envenomed humans are almost always noticed at the time of first aid investigation, with treatment
15 following shortly thereafter. Cats rarely have clinical signs of coagulopathy but show severe
16 paralysis and myotoxicity. Notably, cats have been reported to be about three times less sensitive
17 (on a weight basis) to both brown and tiger snake venoms than dogs (Moisidis et al. 1996).

18
19
20
21
22
23
24
25
26
27
28
29
30
31
32
33 Early studies by Kellaway, (Kellaway 1929, 1932, 1934) and more recently work by Harris *et al.*,
34 (Harris et al. 1975, 1981, 2000; Preston et al. 1990) and others, have examined the
35 histopathological effects of *Notechis* sp. in envenomed animal tissue. In most of these studies the
36 focus has been on the neurotoxic and myotoxic effects of this family of venoms and most involved
37 the examination of experimentally envenomed animal muscle tissue. Similarly, Lewis, (1994)
38 (Lewis 1994), examined skeletal muscle tissue of experimentally envenomed dogs, but also
39 extended his histopathological analysis to the kidney looking at direct nephrotoxic effects of
40 *N.scutatus* venom. Although these studies have aided our understanding of the mechanisms of
41 actions of some of these neuro- and myotoxins, more specifically, notexin, none have defined their
42 specific tissue localisation. Moreover, none thus far have investigated the *in vivo* procoagulant
43 effects of or described the histopathological changes in the heart and lung after *Notechis* species
44 clinical envenomings.

45
46
47
48
49
50
51
52
53
54
55
56
57
58
59
60
61
62
63
64
65
66
67
68
69
70
71
72
73
74
75
76
77
78
79
80
81
82
83
84
85
86
87
88
89
90
91
92
93
94
95
96
97
98
99
100
101
102
103
104
105
106
107
108
109
110
111
112
113
114
115
116
117
118
119
120
121
122
123
124
125
126
127
128
129
130
131
132
133
134
135
136
137
138
139
140
141
142
143
144
145
146
147
148
149
150
151
152
153
154
155
156
157
158
159
160
161
162
163
164
165
166
167
168
169
170
171
172
173
174
175
176
177
178
179
180
181
182
183
184
185
186
187
188
189
190
191
192
193
194
195
196
197
198
199
200
201
202
203
204
205
206
207
208
209
210
211
212
213
214
215
216
217
218
219
220
221
222
223
224
225
226
227
228
229
230
231
232
233
234
235
236
237
238
239
240
241
242
243
244
245
246
247
248
249
250
251
252
253
254
255
256
257
258
259
260
261
262
263
264
265
266
267
268
269
270
271
272
273
274
275
276
277
278
279
280
281
282
283
284
285
286
287
288
289
290
291
292
293
294
295
296
297
298
299
300
301
302
303
304
305
306
307
308
309
310
311
312
313
314
315
316
317
318
319
320
321
322
323
324
325
326
327
328
329
330
331
332
333
334
335
336
337
338
339
340
341
342
343
344
345
346
347
348
349
350
351
352
353
354
355
356
357
358
359
360
361
362
363
364
365
366
367
368
369
370
371
372
373
374
375
376
377
378
379
380
381
382
383
384
385
386
387
388
389
390
391
392
393
394
395
396
397
398
399
400
401
402
403
404
405
406
407
408
409
410
411
412
413
414
415
416
417
418
419
420
421
422
423
424
425
426
427
428
429
430
431
432
433
434
435
436
437
438
439
440
441
442
443
444
445
446
447
448
449
450
451
452
453
454
455
456
457
458
459
460
461
462
463
464
465
466
467
468
469
470
471
472
473
474
475
476
477
478
479
480
481
482
483
484
485
486
487
488
489
490
491
492
493
494
495
496
497
498
499
500
501
502
503
504
505
506
507
508
509
510
511
512
513
514
515
516
517
518
519
520
521
522
523
524
525
526
527
528
529
530
531
532
533
534
535
536
537
538
539
540
541
542
543
544
545
546
547
548
549
550
551
552
553
554
555
556
557
558
559
560
561
562
563
564
565
566
567
568
569
570
571
572
573
574
575
576
577
578
579
580
581
582
583
584
585
586
587
588
589
590
591
592
593
594
595
596
597
598
599
600
601
602
603
604
605
606
607
608
609
610
611
612
613
614
615
616
617
618
619
620
621
622
623
624
625
626
627
628
629
630
631
632
633
634
635
636
637
638
639
640
641
642
643
644
645
646
647
648
649
650
651
652
653
654
655
656
657
658
659
660
661
662
663
664
665
666
667
668
669
670
671
672
673
674
675
676
677
678
679
680
681
682
683
684
685
686
687
688
689
690
691
692
693
694
695
696
697
698
699
700
701
702
703
704
705
706
707
708
709
710
711
712
713
714
715
716
717
718
719
720
721
722
723
724
725
726
727
728
729
730
731
732
733
734
735
736
737
738
739
740
741
742
743
744
745
746
747
748
749
750
751
752
753
754
755
756
757
758
759
760
761
762
763
764
765
766
767
768
769
770
771
772
773
774
775
776
777
778
779
780
781
782
783
784
785
786
787
788
789
790
791
792
793
794
795
796
797
798
799
800
801
802
803
804
805
806
807
808
809
810
811
812
813
814
815
816
817
818
819
820
821
822
823
824
825
826
827
828
829
830
831
832
833
834
835
836
837
838
839
840
841
842
843
844
845
846
847
848
849
850
851
852
853
854
855
856
857
858
859
860
861
862
863
864
865
866
867
868
869
870
871
872
873
874
875
876
877
878
879
880
881
882
883
884
885
886
887
888
889
890
891
892
893
894
895
896
897
898
899
900
901
902
903
904
905
906
907
908
909
910
911
912
913
914
915
916
917
918
919
920
921
922
923
924
925
926
927
928
929
930
931
932
933
934
935
936
937
938
939
940
941
942
943
944
945
946
947
948
949
950
951
952
953
954
955
956
957
958
959
960
961
962
963
964
965
966
967
968
969
970
971
972
973
974
975
976
977
978
979
980
981
982
983
984
985
986
987
988
989
990
991
992
993
994
995
996
997
998
999
1000

1 measurement of various clinical indications, such as serum creatine kinase (CK), creatinine levels
2 for myotoxic effects (Ponraj and Gopalakrishnakone 1997, 1996) and International Normalisation
3 Ratio/ Prothrombin Time (INR/PT), Activated Partial Thromboplastin Time (APTT), D-Dimer
4 levels and whole blood clotting time for coagulopathic envenomings (Ferguson et al. 2002;
5 Isbister et al. 2002, 2006). Testing of venoms *in vitro* on various animal derived primary and
6 cultured cells (Hodgson and Wickramaratna 2002; Kubo et al. 2002; Kuruppu et al. 2006;
7 Marshall and Herrmann 1989; Rigoni et al. 2004) and on animal nerve-muscle preparations
8 (Ramasamy et al. 2004; Zamuner et al. 2004) have aided our understanding of mechanisms of
9 action and toxicities, while others observed histopathological changes in animal tissues after
10 injection of venom or purified venom toxins (Mandal and Bhattacharyya 2007; Ponraj, 1997) to
11 define sites and mechanisms of action. The majority of these studies have focused on snakes found
12 outside Australia. Where these studies focused on the clinical outcomes and *in vitro* functions of
13 various snake venoms and their toxins, others have measured crude venom levels in tissues and
14 organs of experimental animals and human autopsy specimens (Brunda et al. 2006; Selvanayagam
15 et al. 1999). No studies to date have detected or identified the specific tissue (cellular) localisation
16 of Australian venom toxins in the tissues or organs of clinically envenomed patients.
17
18
19
20
21
22
23
24
25
26
27
28
29
30

31 Venom toxins thought to be responsible for the most severe clinical effects seen in humans and
32 domestic animals are: (i) prothrombin activating enzymes acting on coagulation factors leading to
33 venom induced consumptive coagulopathy, (ii) pre and post-synaptic neurotoxins that result in
34 paralysis and (iii) myotoxic components that promote muscle cell destruction (or myonecrosis).
35 Therefore we might expect to find venom toxins localised on the endothelium of the vasculature,
36 on neuronal cells and throughout muscle tissue respectively in envenomed patients. In the case of
37 prothrombin activators, demonstration of a substantial amount of the toxin bound to endothelial
38 surfaces would cause us to question the relevance of serum concentrations of this toxin as most of
39 the active toxin may be on the endothelial surface rather than in the blood. The aims of this study
40 were to examine clinically envenomed animal tissue for evidence of procoagulant, neurotoxic and
41 myotoxic venom activity and to use a panel of developed antibodies to identify tissue specific
42 toxin localisation.
43
44
45
46
47
48
49
50
51
52
53
54
55
56
57
58
59
60
61
62
63
64
65

2. Materials and Methods

2.1 Materials

Antibodies: mouse anti-CD146 was purchased from Abcam, anti-mouse FITC and anti-rabbit AF488 from Millipore, Streptavidin-Cy3, Hoescht 3342 stain and Protein-G-Sepahrose were obtained from Amersham Biosciences. SuperFrost slides (Ecco) and OCT embedding medium were purchased from ProSciTech, Perth. The SOLV solution (Xylene substitute) was purchased from Scot Scientific, Perth and foetal bovine serum (FBS) was purchased from Gibco.

2.2 Samples

Feline and Canine samples were obtained from two patients with Tiger snake envenoming whom presented to Murdoch Pet Emergency Centre (MPEC), Murdoch University between October 2008 and March 2009. Ethics approval was obtained from Murdoch University (Ref: R2202/08) and The University of Western Australia (UWA) (Ref: F15811). Samples were collected with the owner's consent. The species of snake responsible was, in both cases, determined by a venom detection kit (VDK), CSL Ltd from patient serum. Control canine and feline tissue was obtained from non-envenomed MPEC patients with ethical approval. Mice were maintained at the Biomedical Research Facility, UWA (Ref: RA/100/593).

2.3 Tissue collection and processing

Within one hour of death, multiple biopsy samples were collected from the envenomed canine and feline patients. Tissues collected were lung, heart, kidney and Gastrocnemius muscle. One sample of each tissue was immediately frozen in OCT medium stepwise on liquid nitrogen and stored at -80°C. The second biopsy sample of each tissue was placed in 10% formalin and maintained at room temperature. Post mortem urine and serum samples were collected from the canine and feline patients as part of their routine treatment.

Frozen canine tissue was trimmed and sectioned (10µm) on a Leica Microtome (Model CM30505) and sections fixed to slides for 5 minutes in ice cold acetone. Fixed slides were then stored at -80°C. Segments of formalin fixed tissue (canine and feline) were oriented to obtain transverse sections and immersed in 50% alcohol. Tissues were processed and stained by the Histology Department (Technologists Michael Slaven and Gerard Spoelstra), School of Veterinary and Biomedical Science, Faculty of Health Science, Murdoch University. In brief, tissues were

1 processed on a Tissue Tek VIP tissue processor and dehydrated with changes in various
2 concentrations of alcohol. Tissues were then embedded in paraffin using a Leica EG 1150C and
3 4µm sections cut on a Leica microtome. All paraffin embedded tissue slides were stained with
4 Haematoxylin and Eosin (H&E), Martius Scarlet Blue (MSB) and Periodic Acid Schiff (PAS). All
5 tissue sections were examined by light microscopy.
6
7
8
9

10 **2.4 Immunohistochemistry**

11 Monoclonal and polyclonal (pAb) antibodies raised to detect *Notechis scutatus* venom (Nsv) and
12 Notexin, both unconjugated and biotinylated, were optimised for use in Immunohistochemistry
13 (IHC) using normal and frozen envenomed mouse tissue sections.. Each of the antibodies was
14 tested at varying concentrations (1:50, 1:100 and 1:200). Similarly, secondary antibodies (anti-
15 mouse FITC, anti-rabbit AF488 and Streptavidin-Cy3) were titrated to determine optimal working
16 dilutions. Prior to staining with antibodies, paraffin embedded tissue sections were deparaffinised
17 and subjected to an antigen retrieval. This was accomplished by an initial immersion of the tissue
18 sections in three changes of SOLV (Xylene substitute) solution for 10 minutes. Slides were
19 subsequently transferred into 100% alcohol (3 changes of 3 mins each) followed by 95%, 70% and
20 50% ethanol respectively for 3 minutes each. Sections were rinsed twice with PBS (5 mins) and
21 processed for antigen retrieval. Tissue sections were immersed in citrate buffer (10mM, pH 6.0)
22 and incubated at 95°C, 10 mins and allowed to cool for 20 minutes. Sections were washed in PBS
23 and blocked with 10% FBS in PBS. Primary antibodies were then added and incubated overnight
24 at 4°C in a humidified chamber. Relevant antibody controls were prepared for each tissue type.
25 Tissue sections were washed with 2 changes of PBS (5 mins) followed by the application of
26 secondary antibodies; anti-mouse FITC and Streptavidin-Cy3 required a further 1 hour incubation
27 and two additional washes with PBS. The final wash contained a 1:5,000 dilution of Hoescht stain
28 (Amersham) to enable the visualisation of the cell's DNA. Slides were viewed on an inverted
29 fluorescent microscope (Olympus, IX71) and images captured with an Olympus (DP70) camera.
30
31
32
33
34
35
36
37
38
39
40
41
42
43
44
45
46
47
48
49
50
51
52
53
54
55
56
57
58
59
60
61
62
63
64
65

3. Results

3.1 Case Histories

3.1.1 Case 1

Collie cross Kelpie canine, 2 years old, Female; presented to MPEC in cardiac and respiratory arrest within 2 hours of suspected envenoming. Upon presentation, the patient was intubated, ventilated, followed by CPR. Despite drug administration (adrenaline, atropine and IV Hartman's at shock rates) and 4 attempts at defibrillation, there was no response. The owners decided to halt CPR given the poor prognosis. A venom detection kit (VDK) was performed on post mortem serum which was strongly and immediately positive for Tiger snake venom. The circulating serum crude venom (Nsv) concentration (post mortem) was determined to be 22.5ng/ml and notexin level 11.1ng/ml by immunoassay.

3.1.2 Case 2

Domestic Shorthair feline, 1 year old, Male; presented to MPEC early in the morning after having appeared normal the night before. On initial physical examination, the patient was in lateral recumbency with flaccid paralysis of all four limbs. There was generalised Lower Motor Neuron (LMN) paralysis, weak palpebral reflexes (eyelid/eyebrow), dilated pupils and absent pupillary light response (PLR). VDK on urine was strongly positive to Tiger snake venom. APPT was 75 seconds (normal range of 60 to 115) and serum Creatine kinase (CK) was 93,800 U/L (normal range of 50 to 100). Symptoms progressed to severe LMN paralysis and the feline became hypotensive, hypothermic and hypoxic. Urine showed signs of haemoglobinuria and/or myoglobinuria. Treatment included Chlorpheniramine (1mg/kg) IM and 7 vials of antivenom (AV) which included 2 vials of Summerland Serums Tiger/Multibrown AV administered within 15 minutes of the initial exam, a third vial 3 hours later, another vial 3 hours later and a further 3 vials 7 hours after the first dose administered. Each Summerland Serums Tiger/Multibrown AV contains 3000 units Tiger snake AV plus 1500 units of Brown snake AV. At this stage the feline was hypoventilating ($PvCO_2 = 73\text{mmHg}$, and $ETCO_2 = 60\text{mmHg}$) with decreased respiratory effort and rate, consistent with severe flaccid paralysis progressing to respiratory paralysis. At this point ventilation commenced.

Flaccid paralysis remained through the evening and the patient was maintained under light anaesthesia with alfaxalone by continuous rate infusion (CRI). Mild improvement was seen the following day, with the feline able to move and objecting to the endotracheal (ET) tube but displayed ongoing hypoventilation when attempting to wean from the ventilator. On day 3, CK

1 levels of 805,100 U/L, AST = 6,440 (normal range 26 to 43), ALT = 1,520 (normal range 0 to 83)
2 with urea and creatine normal. Complete blood count (CBC) showed mild anaemia and a mild
3 thrombocytosis/thrombocythaemia. Mild improvement in neurological status was observed and
4 although the patient could maintain ET_{CO}₂ levels within normal ranges for up to 30 minutes, the
5 patient quickly developed respiratory fatigue without ventilator support. On day 4, CK serum
6 concentrations had decreased to 226,720 U/L, AST = 1,520 and ALT = 1,360. The feline went
7 into cardiac arrest during an ET tube change, failed to respond to CPR/adrenaline and
8 subsequently passed away. Serum crude venom (Nsv) concentration (pre treatment) was found to
9 be 28.7ng/ml.
10
11
12
13
14
15
16

17 18 **3.2 Histopathological Changes**

19 A summary of the tissue specific histopathological findings are presented in Table 1. Evidence of
20 procoagulant venom effects were observed in the epicardium of the feline heart (Figure 1A and B)
21 and throughout the feline pulmonary tissue (Figure 1C and E) as well as in the vasculature of the
22 renal cortex in the canine patient (Figure 1F), apparent by visibly formed thrombi. The presence of
23 fibrin was confirmed by MSB staining. The lungs of both animals showed multifocal to coalescing
24 alveolar collapse, (Figure 2A and C), hence the lungs were unable to fully inflate, some of which
25 may have been in part due to post-mortem changes. The presence of eosinophilic (proteinaceous)
26 material within the alveoli is consistent with the presence of oedema and small aggregate of
27 fibrillar deposits possibly suggestive of further procoagulant venom activity, indicated by arrows
28 in Figure 2C.
29
30
31
32
33
34
35
36
37
38
39

40 Hydropic changes were observed in kidney tissue of both patients', a degenerative change where
41 cells swell with fluid was observed, indicative of cells becoming vacuolated. No signs of
42 proteinuria or necrosis were observed in the canine tissue; however, distinct changes indicating
43 increased glomerular permeability were noted in the feline kidney. In the feline occasional fibrillar
44 deposits were seen in the glomeruli; glomerular capillary thrombus formation may be indicative of
45 procoagulant toxin activity. Expanded Bowman's spaces containing an amorphous pale
46 eosinophilic material, confirmed by PAS staining, was suggestive of proteinuria (Figure 3B and
47 C) in the feline tissue. The appearance of hypereosinophilic epithelial cells without the presence of
48 an accompanying inflammatory response was indicative of mild post-mortem autolysis. No
49 pathological changes were observed in the canine GM tissue, which was not surprising as the time
50 since envenoming to presentation and death was within 3 hours, thereby not allowing the toxins
51 sufficient time to reach the muscle fibres and cause myonecrosis. In contrast, significant changes
52
53
54
55
56
57
58
59
60
61
62
63
64
65

1 were observed in the feline tissue including selective degeneration of myofibres with an
2 accompanying inflammatory response (Figure 4A and B); and as indicated by arrows in Figures
3 4C and D, macrophages are seen actively phagocytosing individual necrotic myofibres. Non-
4 envenomed feline muscle tissue is presented for comparison (Figure 4E and F)
5
6
7

9 **3.3 Tissue localisation of venom toxins**

10
11 Although minor histopathological observations were made in both cardiac tissues, modest
12 fluorescence was apparent when staining the tissue with an anti-Nsv IgG pAb. Limited staining of
13 frozen sections of the entire canine myocardium along with a speckled staining throughout the
14 cardiac muscle tissue was seen when compared to the secondary alone control (not shown) and the
15 non-envenomed tissue control. However, when probing the canine pulmonary tissue with the same
16 pAb, multifocal to coalescing intense staining was observed, indicating the presence of a
17 significant amount of venom in this tissue (Figure 5A and B). A commercially available anti-
18 CD146 antibody, reactive with endothelial cells and smooth muscle, also showed limited staining
19 on paraffin embedded tissue and so it was difficult to determine exactly where the venom
20 localised. As illustrated in Figure 5A and B, it appeared as though the toxins were not confined to
21 one specific location (i.e. blood vessels, bronchi or bronchioles), but scattered throughout the
22 tissue. This is consistent with the appearance of nerve fibres, to be confirmed with further
23 investigation. All fluorescence observed was absent in secondary alone controls and non-
24 envenomed tissue sections (Figure 5C and D).
25
26
27
28
29
30
31
32
33
34
35
36
37

38 Correlating to histopathological changes observed in the feline kidney, IHC experiments carried
39 out on frozen canine kidney tissue resulted in anti-Nsv staining in and around the glomerular
40 capsule in the renal cortex, as well as in surrounding tubules (Figure 6A). No distinct staining
41 above background fluorescence was observed in the feline kidney, which may be the result of a
42 combination of the administration of antivenom, the time since envenoming and collection of the
43 tissue (>4 days), as opposed to the canine tissue, which was collected within 3 hours post
44 envenomation. Although it may have been too early following envenomation to observe
45 histopathological changes in the canine GM tissue, IHC assays revealed that venom was present.
46 Illustrated in Figure 6D and E, using a biotinylated anti-Nsv (then Strep-Cy3), punctate staining
47 pattern was observed in both patients through the Gastrocnemius muscle tissue itself as well as a
48 staining of toxins within the vasculature (centre bottom bundle). All staining observed was greater
49 than the fluorescence intensity of the secondary alone and non-envenomed control tissue (Figure
50 6C and F) controls at the same exposure.
51
52
53
54
55
56
57
58
59
60
61
62
63
64
65

4. Discussion

The purpose of this work was to initially assess the histopathological changes in several organs of clinically envenomed tiger snake patients, confirmed by VDK, and relevant controls and secondly to conduct preliminary experiments to localise venom toxins *in vivo*. What became very clear through this work is that histopathological change in tissues in response to Australian elapid envenoming is an area poorly represented in the literature.

This work was conducted in consultation with an experienced Veterinary Specialist in Emergency Medicine and Critical Care plus a Pathologist which has ensured that no signs commonly presenting in normal domestic animals have been misinterpreted as venom induced effects.

4.1 Heart

In the canine tissue, mild, peracute, multifocal haemorrhage was observed (not shown) which is consistent with findings reported by Tibballs *et al.* (Tibballs et al. 2002). The canine heart tissue showed changes within a short time period (2 hours), therefore suggestive that the coagulopathic venom toxins are fast acting toxins, exerting their effects soon after envenoming. Although there were no signs of cardiac myocyte degeneration (indicative of myotoxic venom activity) in either patient's heart tissue, a small epicardial thrombus was detected in the feline heart sections, indicative of procoagulant toxin action.

4.2 Lung

The histopathological changes in the lungs of both pulmonary tissues are consistent with the clinical outcomes seen in both patients. Several thrombi were observed within the feline vasculature (Figure 1C-E) which would more than likely manifest clinically as dyspnoea. The feline had been ventilated for several days post envenoming and went into cardiac arrest when being weaned off the ventilator. It is likely that the venous thrombosis was directly caused by the original snake envenoming, but time spent on the ventilator may have contributed to the fibrinous alveolar exudates observed. The pulmonary thrombosis evident was sufficiently significant to be functionally catastrophic. Direct pathological thrombosis, more specifically pulmonary embolism as a result of snake envenoming has only previously been described in cases involving the Martinique vipers and related species from the West Indies (Dong-Zong et al. 2002; Thomas et al. 1995).

1 It has been suggested that in true coagulopathy a brief window of thrombus formation as the toxin
2 enters the circulation is expected (White 2005), which prior to the activation of fibrinolysis gives
3 rise to the consumption of coagulation factors, seen clinically in patients. Thrombus formation has
4 previously been documented in experimental dogs in response to brown snake envenoming
5 (Tibballs et al. 1991, 1992). This work has also shown pulmonary thrombus formation as well as
6 emboli observed in heart and kidney tissues. It has been suggested that even a few minutes of such
7 thrombotic complications can be devastating for the victim, as the occlusion of critical vessels by
8 thrombi can result in cardiac arrest and death (White 2005).

14 4.3 Kidney

15 Although Tiger snake envenoming has been widely reported to cause kidney damage in clinically
16 envenomed patients (Cheng and Currie 2004; Currie 2000; Hood 1975; Jolles et al. 1998; White
17 1995), it is unclear whether renal failure is a direct result of the venom's nephrotoxicity or a
18 secondary effect of myoglobinuria. Different types of kidney damage induced by snake venoms
19 and purified venom toxins (from snakes found outside Australia) has been thoroughly reviewed by
20 Sitprija *et al.*, (1982) (Sitprija et al. 1982), allowing us to utilise this work when examining kidney
21 damage caused by Australian snakes.

22 Interestingly, within the vasculature of the canine renal cortex, a small thrombus/embolus was
23 observed (Figure 1F). Usually, thrombi are attached to the vascular endothelium, however, in this
24 case it is possible that the thrombus detached from the endothelium as an embolus and was freely
25 circulating through the patient's vasculature. One particular study of the renal effects of tiger
26 snake envenoming in experimental dogs showed the presence of lesions, indicating acute tubular
27 necrosis (Lewis 1994). The author also noted the presence of variable amounts of proteinaceous
28 material within the renal tubules. Our work is consistent with these findings where mild
29 proteinuria was observed within the proximal loops of Henle and the Bowmans's space of the
30 feline kidney. This is indicative of increased glomerular permeability and is suggestive of direct
31 toxin activity. In the canine kidney, anti-Nsv staining showed a punctuate fluorescence pattern in
32 and around the glomerulus and surrounding tubules suggesting large amounts of venom are being
33 filtered through the kidneys most likely leading to the renal damage identified.

4.4 Muscle

1
2
3 The effects of tiger snake phospholipase A₂ myotoxins on muscle fibres have been well
4 documented and shown to produce skeletal muscle paralysis by inhibiting synaptosomal
5 membrane choline transport from nerve endings (Mollier et al. 1990). Harris *et al.* (Harris et al.
6 1975, 2003; Harris and MacDonell 1981; White 1987) showed that the purified notexin caused
7 destruction of the myofibres in a mosaic pattern and Preston *et al.*, (1990) (Preston et al. 1990)
8 found a dose-dependent relationship between the extent of muscle loss and the amount of venom
9 injected in experimental animals. The feline muscle tissue in this study also clearly showed
10 myotoxicity with an inflammatory response as defined by Mebs and Ownby, (1990) (Mebs and
11 Ownby 1990) and Harris and Maltin (Harris and Maltin 1982), respectively.
12
13
14
15
16
17
18
19

20 No signs of necrosis were observed in the canine muscle which may be due to the short time frame
21 between envenoming and presentation, as opposed to the feline. Lewis, (1994) (Lewis, 1994)
22 found that after the injection of *N.scutatus* venom into the muscle tissue of dogs, segmental
23 necrosis of the underlying tissue within 1 hr of envenomation was present and the degeneration of
24 myofibres at 3 hrs post bite. A major difference here is that the toxin was delivered locally and
25 directly to the musculature rather than through the circulation as in the clinical patients described
26 here.
27
28
29
30
31
32

33 In the canine GM muscle, although no histopathological changes were observed, a clear staining
34 pattern was observed. This staining was consistent with the histopathological changes observed in
35 the feline muscle. Venom staining in the canine appeared the brightest in several locations
36 throughout the connective tissue between muscle epimysium with many less bright areas
37 appearing in the endomysium (shown to contain capillaries) and within the muscle fibres
38 themselves. Although not as prominent as in the canine, a mild scattered staining pattern was
39 observed in the feline muscle (not shown). Considering the myonecrosis observed in the feline
40 muscle by standard histopathological examination, it is not surprising that venom was detected
41 within the tissue.
42
43
44
45
46
47
48
49
50
51
52
53
54
55
56
57
58
59
60
61
62
63
64
65

Concluding remarks

1
2
3 In this work it was not anticipated that venom would be detected in the feline tissues as this patient
4 had been treated with 7 vials of antivenom and therefore venom toxins would more than likely
5 already be bound by antibody molecules. In the canine patient however, envenoming and
6 presentation was within 2 hours, with no antivenom treatment and we therefore anticipated venom
7 toxins to be abundant in the canine tissue, which coincides with our results. .
8
9

10
11
12 This work has described the examination of post mortem heart, lung, kidney and Gastrocnemius
13 muscle tissue from two tiger snake envenomed animal patients admitted to MPEC. For the first
14 time, pathological evidence of procoagulant venom activity has been presented, with numerous
15 thrombi observed in the lungs, heart and kidney of the clinically envenomed patients. This
16 supports the proposal that an initial thrombotic state occurs in snakebite patients that leads to the
17 depletion of vital clotting factors, manifesting in VICC, clinically seen in human and domestic
18 animal victims. A panel of antibodies has been developed against various Australian snake
19 venoms and individual toxins for use in localising venom toxins *in vivo* in envenomed patient
20 tissue. Results presented here suggest the presence of venom toxins in each of the tissues
21 examined and offer a valuable tool in further clarifying toxin localisation.
22
23
24
25
26
27
28
29
30
31

32
33
34 **Funding Information:** The study was completed in partial fulfilment of a PhD through the Centre
35 for Forensic Science, University of Western Australia and funded by the Monoclonal Antibody
36 Facility, Western Australian Institute for Medical Research
37
38
39

Acknowledgements

40
41
42
43 We thank Pauline van Eeden for her technical assistance and advice as well as the Murdoch
44 University Veterinary Pathology team for processing the tissue.
45
46
47
48
49
50
51
52
53
54
55
56
57
58
59
60
61
62
63
64
65

References

- 1
2
3 Brunda, G., Rao, B.S., Sarin, R.K., 2006, Quantitation of indian krait (*Bungarus caeruleus*) venom in
4 human specimens of forensic origin by indirect competitive inhibition enzyme-linked
5 immunosorbent assay. *Journal of AOAC International* 89, 1360-1366.
6
7 Cheng, A.C., Currie, B.J., 2004, Venomous Snakebites Worldwide with a Focus on the Australia-Pacific
8 Region: Current Management and Controversies. *Journal of Intensive Care Medicine* 19, 259-269.
9
10 Currie, B.J., 2000, Snakebite in tropical Australia, Papua New Guinea and Irian Jaya. *Emergency Medicine*
11 12, 285-294.
12
13 Dong-Zong, H., Ming-Ling, W., Jou-Fang, D., Dar-Yu, Y., Shoen-Yn, L.-S., 2002, Multiple Thrombotic
14 Occlusions of Vessels after Russell's Viper Envenoming. *Pharmacology & Toxicology* 91, 106-
15 110.
16
17 Ferguson, L.A., Morling, A., Moraes, C., Baker, R., 2002, Investigation of coagulopathy in three cases of
18 tiger snake (*Notechis ater occidentalis*) envenomation. *Pathology* 34, 157-161.
19
20 Harris, J.B., Johnson, M.A., Karlsson, E., 1975, Pathological responses of rat skeletal muscle to a single
21 subcutaneous injection of a toxin isolated from the venom of the Australian tiger snake, *Notechis*
22 *scutatus scutatus*. *Clinical and Experimental Pharmacology and Physiology* 2, 383-404.
23
24 Harris, J.B., MacDonell, C. A., 1981, Phospholipase A2 activity of notexin and its role in muscle damage.
25 *Toxicon* 19, 419-430.
26
27 Harris, J.B., Maltin, C. A., 1982, Myotoxic activity of the crude venom and the principal neurotoxin,
28 taipoxin, of the Australian taipan, *Oxyuranus scutellatus*. *British Journal of Pharmacology* 76, 61-
29 75.
30
31 Harris, J.B., Grubb, B.D., Maltin, C.A., Dixon, R., 2000, The Neurotoxicity of the Venom Phospholipases
32 A2, Notexin and Taipoxin. *Experimental Neurology* 161, 517-526.
33
34 Harris, J.B., Vater, R., Wilson, M., Collen, M.J., 2003, Muscle fibre breakdown in venom-induced muscle
35 degeneration. *Journal of Anatomy* 202, 363-372.
36
37 Hodgson, W.C., Wickramaratna, J.C., 2002, *In Vitro* neuromuscular activity of snake venoms. *Clinical and*
38 *Experimental Pharmacology and Physiology* 29, 807-814.
39
40 Holloway, S.A., Parry, B.W 1989, Observations on blood coagulation after snakebite in dogs and cats.
41 *Australian Veterinary Journal* 66, 364-366.
42
43 Hood, V.L., 1975, Acute renal failure with myoglobinuria after tiger snake bite. *Medical Journal of*
44 *Australia* 2, 638-641.
45
46 Isbister, G.K., Currie, B.J., Little, M., Daly, F.F.S., Isbister, J.P., 2002, Coagulopathy from tiger snake
47 envenoming and its treatment. *Pathology* 34, 588-590.
48
49 Isbister, G., K., Williams, V., Brown, S.G.A., White, J., Currie, B.J., 2006, Clinically applicable laboratory
50 end-points for treating snakebite coagulopathy. *Pathology* 38, 568-572.
51
52 Isbister, G.K., Brown, S.G. MacDonald, E. White, J., Currie, B.J., 2008, Current use of Australian snake
53 antivenoms and frequency of immediate-type hypersensitivity reactions and anaphylaxis. *Medical*
54 *Journal of Australia* 188, 473-476.
55
56 Jolles, S., Lawrence, S., Gallagher, J., Fulcher, D., 1998, Severe rhabdomyolysis after Tiger snake bite.
57 *Journal of the Royal Society of Medicine* 91, 267-269.
58
59 Kellaway, C.H., 1929, The venom of *Notechis scutatus*. *Medical Journal of Australia* 1, 348-358.
60
61 Kellaway, C.H., 1932, The Peripheral Action of the Australian Snake Venoms 3. The reversibility of the
62 Curari-like action. *The Australian Journal of Experimental Biology and Medical Science* 10, 195-
63 202.
64
65

- 1 Kellaway, C.H., 1934, The Peripheral Action of Australian Snake Venoms 4. Action on sensory nerve
2 endings in Frogs. The Australian Journal of Experimental Biology and Medical Science 12, 177-
3 186.
- 4 Kubo, A., Iwano, M., Kobayashi, Y., Kyoda, Y., 2002, *In vitro* effects of habu snake venom on cultured
5 mesangial cells. Nephron 92.
- 6 Kuruppu, S., Fry, B.G., Hodgson, W.C., 2006, *In vitro* neurotoxic and Myotoxic effects of the venom from
7 the black Whip Snake (*Demansia Papensis*). Clinical and Experimental Pharmacology and
8 Physiology 33, 264-368.
- 9 Lewis, P.F., 1994, Myotoxicity and nephrotoxicity of common tiger snake (*Notechis scutatus*) venom in the
10 dog. Australian Veterinary Journal 71, 136-139.
- 11 Mandal, S., Bhattacharyya, D., 2007, Ability of a small, basic protein isolated from Russell's viper venom
12 (*Daboia russelli russelli*) to induce renal tubular necrosis in mice. Toxicon 50, 236-250.
- 13 Marshall, L.R., Herrmann, R. P., 1989, Australian snake venoms and their *in vitro* effect on human
14 platelets. Thrombosis Research 54, 269-275.
- 15 Mebs, D., Ownby, C.L., 1990, Myotoxic components of snake venoms: Their biochemical and biological
16 activities. Pharmacology & Therapeutics 48, 223-236.
- 17 Mirtschin, P.J., Masci, P., Paton, D.C., Kuchel T., 1998, Snake bites recorded by veterinary practices in
18 Australia. Australian Veterinary Journal 76, 195-198.
- 19 Moisisidis, A.V., James, T., Smith, H.V., Cox, J.C., 1996, Snake envenomation in cats and its detection by
20 rapid immunoassay. Australian Veterinary Journal 74, 143-147.
- 21 Mollier, P., Chwetzoff, S., Menez, A., 1990, A monoclonal antibody recognizing a conserved epitope in a
22 group of phospholipases A2. Molecular Immunology 27, 7-15.
- 23 Ponraj, D., Gopalakrishnakone, P., 1996, An animal model for myoglobinuria using a myotoxin from
24 *Pseudechis australis* (king brown snake) venom in mice. Toxicon 34, 623-623.
- 25 Ponraj, D., Gopalakrishnakone, P., 1997, Renal lesions in rhabdomyolysis caused by *Pseudechis australis*
26 snake myotoxin. Kidney International 51, 1956-1969.
- 27 Preston, S.A., Davis, C.E., Harris, J.B., 1990, The assessment of muscle fibre loss after the injection of the
28 venom of *Notechis scutatus* (Australian tiger snake). Toxicon 28, 201-214.
- 29 Ramasamy, S., Isbister, G. K., Hodgson, W. C., 2004, The efficacy of two antivenoms against the *in vitro*
30 myotoxic effects of black snake (*Pseudechis*) venoms in the chick biventer cervicis nerve-muscle
31 preparation. Toxicon 44, 837-845.
- 32 Rigoni, M., Schiavo, G., Weston, A. E., Caccin, P., Allegrini, F., Pennuto, M., Valtorta, F., Montecucco,
33 C., Rossetto, O., 2004, Snake presynaptic neurotoxins with phospholipase A2 activity induce
34 punctate swellings of neurites and exocytosis of synaptic vesicles. Journal of Cell Science 117,
35 3561-3570.
- 36 Selvanayagam, Z.E., Gnanavendhan, S. G., Ganesh, K. A., Rajagopal, D., Subba Rao, P. V., 1999, ELISA
37 for the detection of venoms from four medically important snakes of India. Toxicon 37, 757-770.
- 38 Sitprija, V., Suvanpha, R., Pochanugool, C., Chusil, S., 1982, Acute Interstitial Nephritis in Snake Bite.
39 Am J Trop Med Hyg 31, 408-410.
- 40 Sutherland, S.K., Leonard, R.L., 1995, Snakebite deaths in Australia 1992-94 and a management update.
41 Medical Journal of Australia 163, 616-618.
- 42 Thomas, L., Tyburn, B., Bucher, B., Pecout, E., Ketterie, J., Tieux, D., Smadja, D., Garnier, D. & Plumelle,
43 Y., 1995, Prevention of thrombosis in human patients with *Bothrops Lanceolatus* envenoming in
44 Martinique: failure of anticoagulants and efficacy of a monospecific antivenom. American Journal
45 of Tropical Medicine and Hygiene 52, 419-426.
- 46 Tibballs, J., Sutherland, S.K., Kerr, S., 1991, Studies on Australian snake venoms, part II: the
47 haematological effects of brown snake (*Pseudonaja*) species in the dog. Anaesth. Intensive Care
48 19, 338-342.
- 49
50
51
52
53
54
55
56
57
58
59
60
61
62
63
64
65

- 1 Tibballs, J., Sutherland, S.K., 1992, The efficacy of heparin in the treatment of common brown snake
2 (*Pseudonaja textilis*) envenomation. *Anaesthesia and Intensive Care* 20, 33-37.
- 3 Tibballs, J., Monagle, P., Parkin, D., Ibrahim, K., Dauer, R., Braitberg, G., 2002, Tiger snake
4 envenomation and disseminated intravascular coagulation (DIC). *Pathology* 34, 481-483.
- 5 White, J., 1987, Elapid snakes; aspects of envenomation. In: Covacevich, J., Davie, P. & Pearn, J. (Eds),
6 *Toxic Plants and Animals: a guide for Australia.*, 504 p.
- 7 White, J., 1995, Clinical Toxicology of snakebite in Australia and new Guinea. In: Meier, J., White, J.
8 (Eds) *Handbook of Clinical Toxicology of Animal toxins and poisons*. CRC Press, Boca Raton,
9 FL., 595-618 pp.
- 10 White, J., 2000, Why do people still die from brown-snake bites? *Emergency Medicine* 12, 204-206.
- 11 White, J., 2005, Snake venoms and coagulopathy. *Toxicon* 45, 951-967.
- 12 Zamuner, S.R., da Cruz-Hofling, M. A., Corrado, A. P., Hyslop, S., Rodrigues-Simioni, L., 2004,
13 Comparison of the neurotoxic and myotoxic effects of Brazilian *Bothrops* venoms and their
14 neutralization by commercial antivenom. *Toxicon* 44, 259-271.
- 15
16
17
18
19
20
21
22
23
24
25
26
27
28
29
30
31
32
33
34
35
36
37
38
39
40
41
42
43
44
45
46
47
48
49
50
51
52
53
54
55
56
57
58
59
60
61
62
63
64
65

1
2
3
4
5
6
7
8
9
10
11
12
13
14
15
16
17
18
19
20
21
22
23
24
25
26
27
28
29
30
31
32
33
34
35
36
37
38
39
40
41
42
43
44
45
46
47
48
49

Table 1: Histopathological findings of analysed tiger snake envenomed domestic animal tissue

ACCEPTED MANUSCRIPT

1
2
3
4
5
6
7
8
9
10
11
12
13
14
15
16
17
18
19
20
21
22
23
24
25
26
27
28
29
30
31
32
33
34
35
36
37
38
39
40
41
42
43
44
45
46
47
48
49

Figure 1 Histopathological evidence of procoagulant venom activity in clinically envenomed animal tissue. **A.** Feline cardiac tissue, x200, MSB stained. Myocardium (Myo) on the left and Subepicardial adipose tissue (Ep) to the right containing coronary arteries (CA) and vein (CV) surrounded by muscular connective tissue (collagen stains blue). The vein (top right) contains an early thrombus, **B.** Feline cardiac tissue, x 400, MSB stained. A higher magnification of the thrombus inside the vascular lumen (VL), **C.** Feline pulmonary tissue, x100, H&E stained. Notice the thickening of the alveolar septa (a) and the thrombi (Thr) in the smaller blood vessels (BV), **D.** Feline pulmonary tissue, x 200, MSB stained. Large bronchus (Br) filled with eosinophilic material surrounded by Hyaline cartilage (Hc). Above bronchus is a large blood vessel lumen (BVL) containing a large early thrombus, **E.** x400, MSB stained. Large thrombus in large muscular artery magnified further and composed of erythrocytes (yellow), leukocytes (nuclei brown/black) and fibrin (red/pink) and clusters of platelets appearing amphophilic (pink/purple), **F.** Canine kidney, x100, MSB stained. Observe the renal cortex blood vessel containing a small thrombus formation (red).

1
2
3
4
5
6
7
8
9
10
11
12
13
14
15
16
17
18
19
20
21
22
23
24
25
26
27
28
29
30 **Figure 2 Histopathological changes in envenomed and non-envenomed pulmonary tissue. A.** Canine tissue, x100, MSB stained. Notice
31 the general congestion and a blood vessel (BV) filled with erythrocytes (yellow) and two bronchi (BR) filled with eosinophilic
32 (proteinaceous) material and the presence of extravascular erythrocytes, indicative of haemorrhage, **B.** Canine tissue, x200, MSB stained.
33 Notice hyperaemia (pooling of erythrocytes within the vasculature) within the alveolar septa and alveolar atelectasis (collapse). Also apparent
34 is the proteinaceous, lacy material present in the bronchioles (Br), **C.** Feline tissue, x 200, MSB stained. Observe multifocal small aggregates
35 of red fibrillar deposits throughout the alveolar septa and occasionally in the alveolar lumen, indicated by arrows, **D.** x100 and **E.** x200 Non-
36 envenomed Canine tissue, MSB stained and **F.** x100, Non-envenomed Feline tissue, MSB stained.
37
38
39
40
41
42
43
44
45
46
47
48
49

1
2
3
4
5
6
7
8
9
10
11
12
13
14
15
16
17
18
19
20
21
22
23
24
25
26
27
28
29
30
31
32
33
34
35
36
37
38
39
40
41
42
43
44
45
46
47
48
49
50
51
52
53
54
55
56
57
58
59
60
61
62
63
64
65

Figure 3 Histopathological observations of tiger snake envenomed feline kidney tissue. A. x400, MSB stained. Notice the irregularly shaped glomeruli (GL) with expanded Bowman's space (Bs) filled with eosinophilic (proteinaceous) material. Arrows indicate fibrillar deposits (bright red). Proximal convoluted tubules (PT), distal convoluted tubules (DT) and collecting tubules (CT) indicated, **B.** x200, PAS stained and **C.** x400, PAS stained. Notice occasional minor proteinuria indicated by lacy material in the proximal loops of Henle (PL) and Bowman's space (arrows), **D.** Non-envenomed feline glomerulus, MSB stained, x 200.

1
2
3
4
5
6
7
8
9
10
11
12
13
14
15
16
17
18
19
20
21
22
23
24
25
26
27
28
29
30
31
32
33
34
35
36
37
38
39
40
41
42
43
44

Figure 4 Histopathological observations of tiger snake envenomed Feline

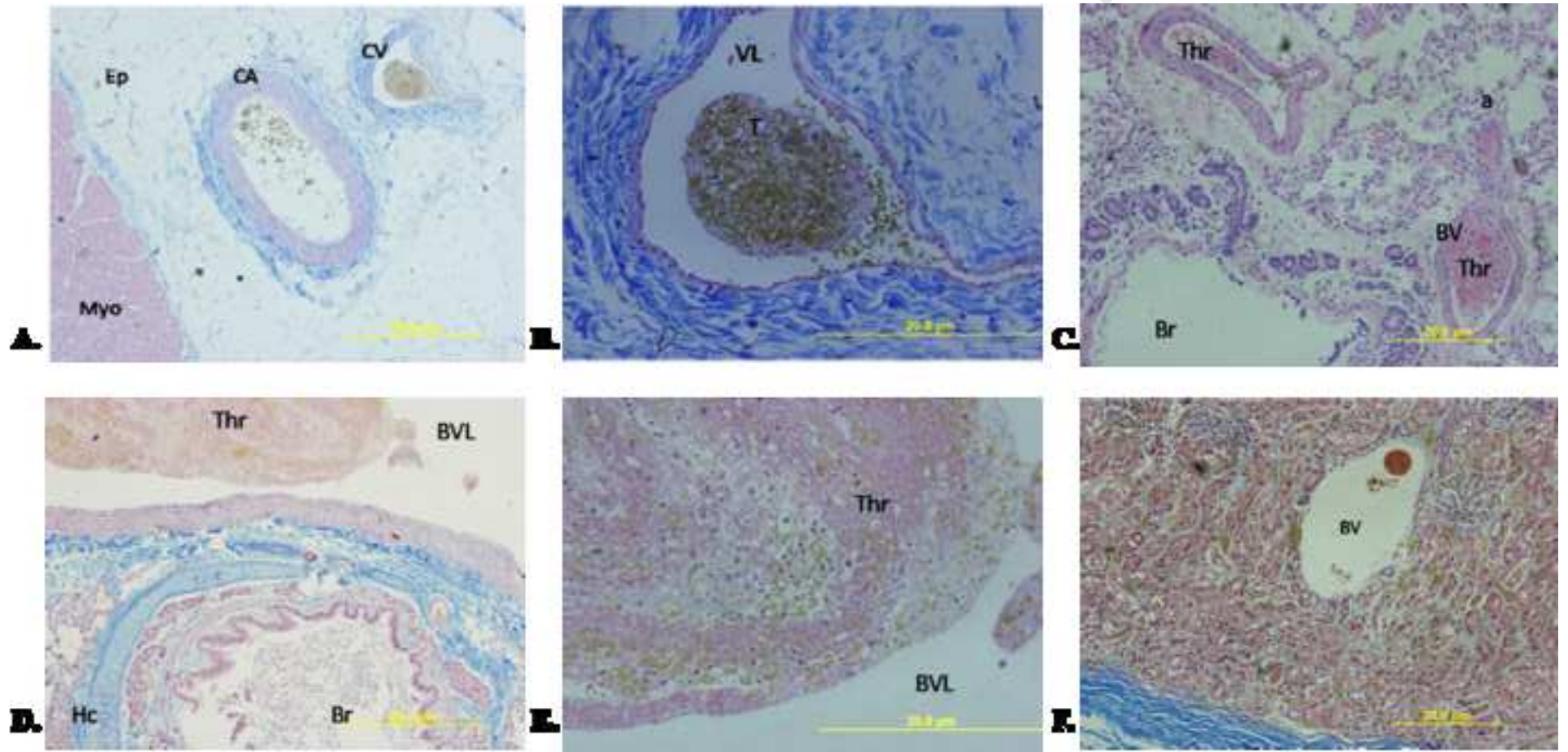
45 **Gastrocnemius muscle tissue.** **A.** x100, MSB stained. Notice the scattering of necrotic
46 muscle fibres highlighted in blue/purple, **B.** x200, H&E stained. Muscle fibres with
47 moderate inflammatory infiltrate, **C.** x200 and **D.** x400, MSB stained, both showing
48 individual and grouped necrotic fibres and inflammatory infiltrate. All arrows indicate
49 the presence of individual macrophages phagocytosing necrotic muscle fibres. **E.** x 200,
50 H&E stained, non-envenomed feline muscle and **F.** x 200, MSB stained non-
51 envenomed feline muscle.
52
53
54
55
56
57
58
59
60
61
62
63
64
65

1
2
3
4
5
6
7
8
9
10
11
12
13
14
15
16
17
18
19
20
21
22
23
24
25
26
27
28
29
30
31
32
33
34
35
36
37
38
39
40
41
42
43
44
45
46
47
48
49

Figure 5 Anti-Nsv staining of tiger snake envenomed and non-envenomed canine lung tissue. Formalin fixed post-mortem pulmonary tissue was processed and embedded in paraffin. Sections were stained with an anti-*Notechis scutatus* pAb (left) and Hoechst stain, a merged image is presented (centre). **A.** and **B.** offer two distinct fields of view at x 400 magnification. Notice the antibody staining (red) and cell nuclei (blue). **C.** Non-envenomed canine lung, x 200, stained with anti-NsPA/Strep-Cy3 and D. Hoescht stained non-envenomed canine lung, x 200.

1
2
3
4
5
6
7
8
9
10
11
12
13
14
15
16
17
18
19
20
21
22
23
24
25
26
27
28
29
30
31
32
33
34
35
36
37
38
39
40
41
42
43
44
45
46
47
48
49

Figure 6 Anti-Nsv staining of tiger snake envenomed canine kidney and muscle tissue. x400. **A.** Renal tissue stained with anti-Nsv pAb followed by anti-rabbit AF488. Notice areas of bright staining in and around the glomerulus (GL) and surrounding tubules. Bowman's space (Bs) is also indicated. **B.** Hoechst stain and **C.** anti-rabbit AF488 secondary alone control. **D.** GM tissue, x200, stained with anti-Nsv pAb Biotin followed by Streptavidin-Cy3. Notice the bundle of cellular material within the vascular endothelium as well as punctate staining throughout the muscle tissue. **E.** Hoechst stain and **F.** x100, Non-envenomed canine muscle tissue stained with anti-Nsv pAb Biotin followed by Streptavidin-Cy3.



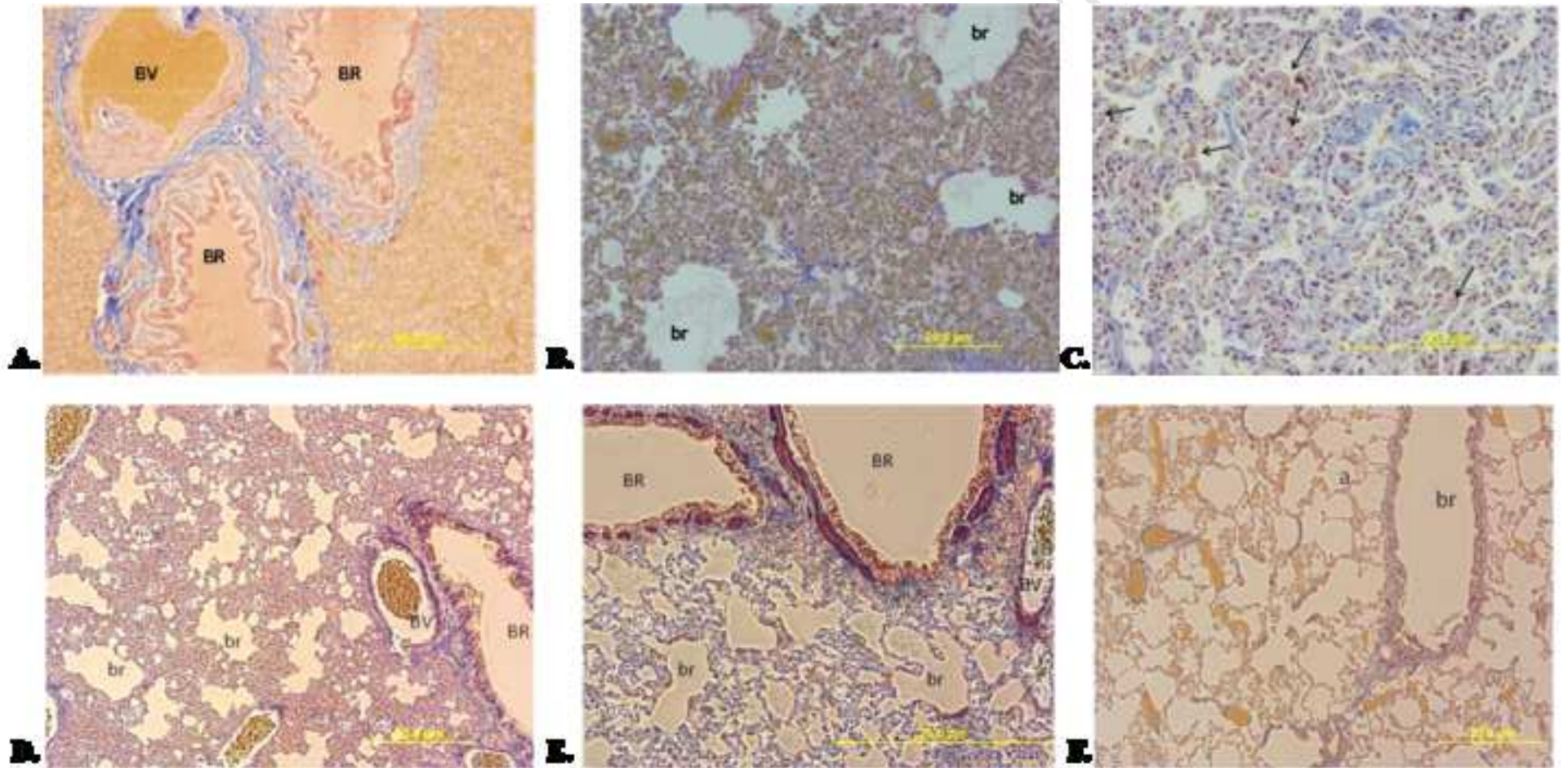


Figure 3
[Click here to download high resolution image](#)

