
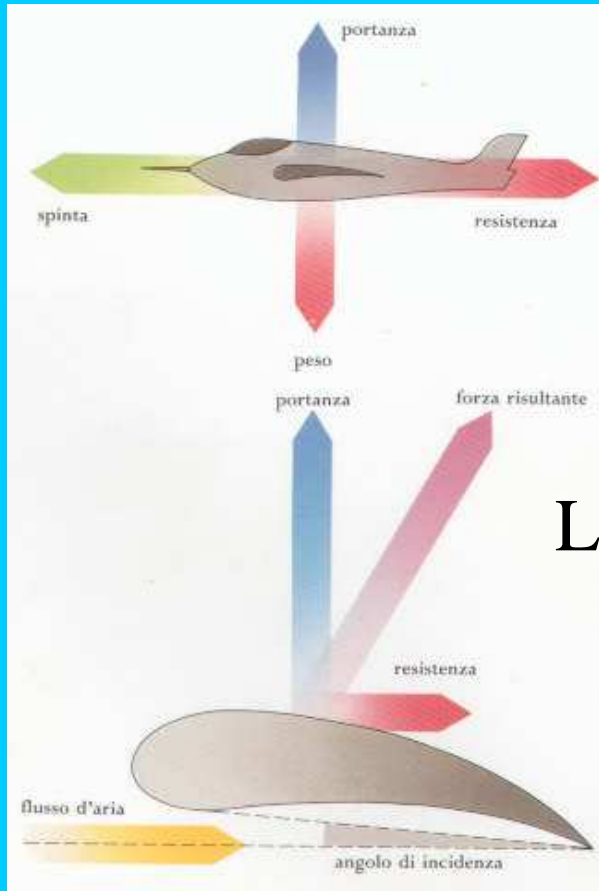


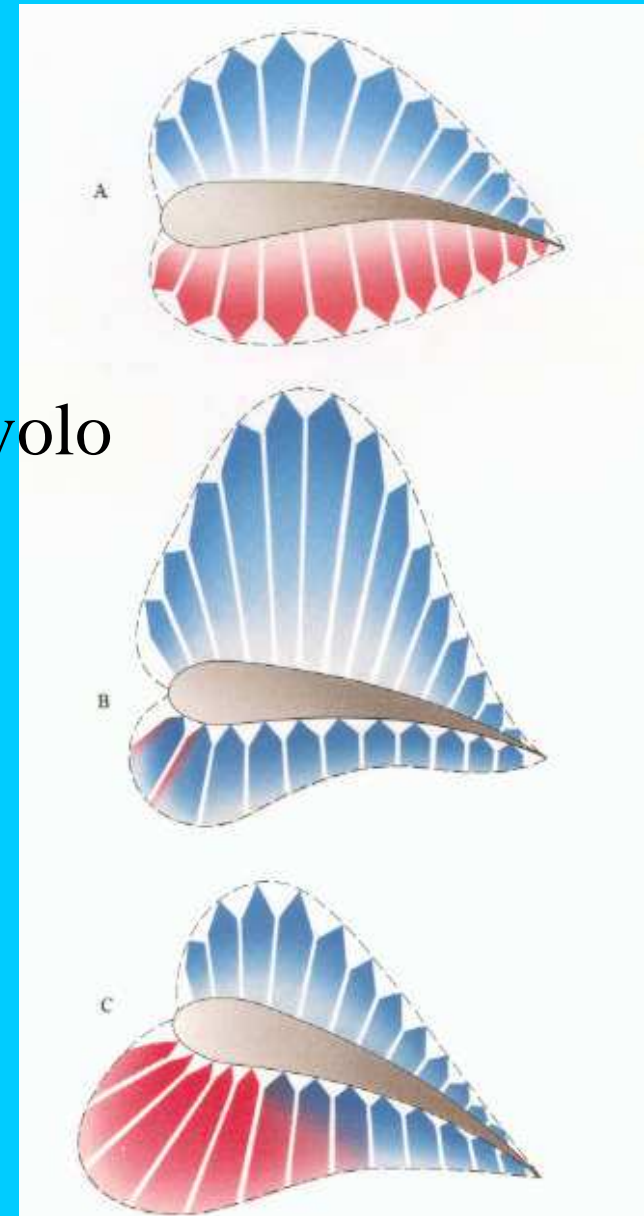
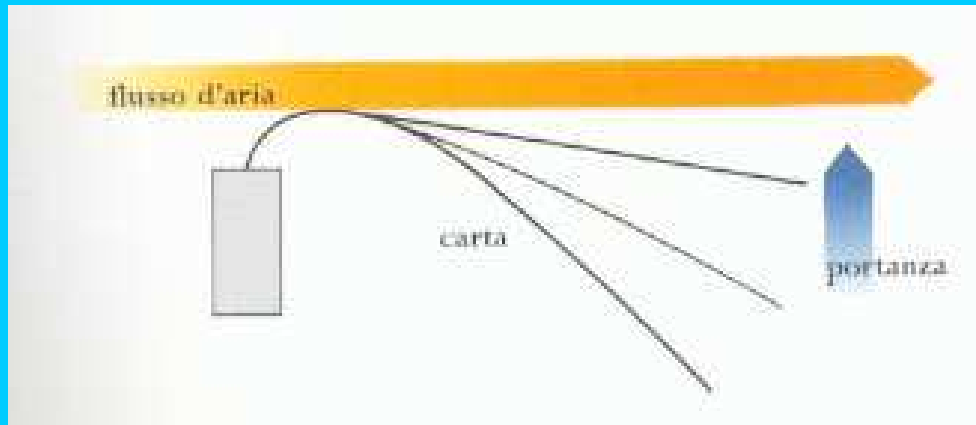
# Chirurgia funzionale dell'ala negli uccelli

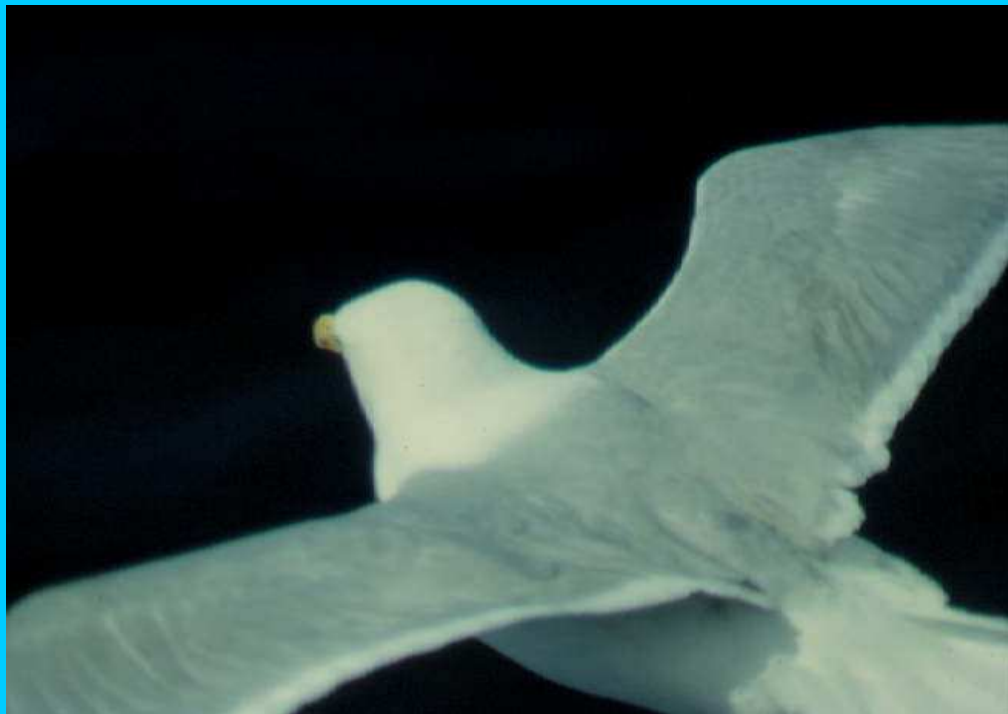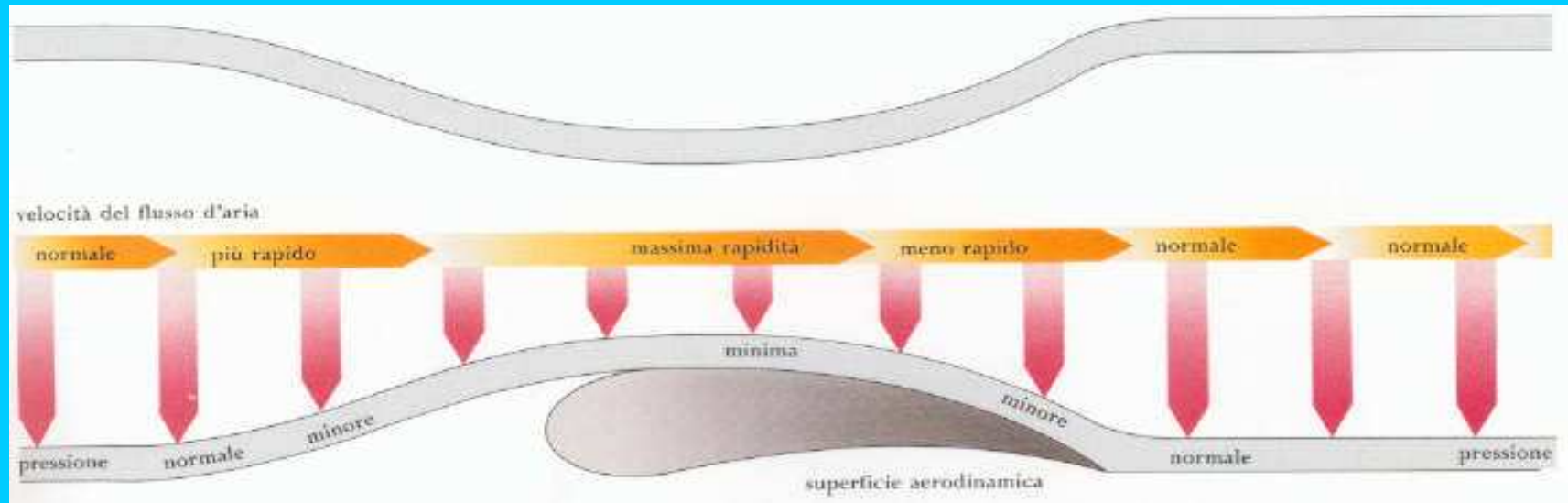


DELOGU MAURO  
Facoltà di Medicina Veterinaria  
Università di Bologna



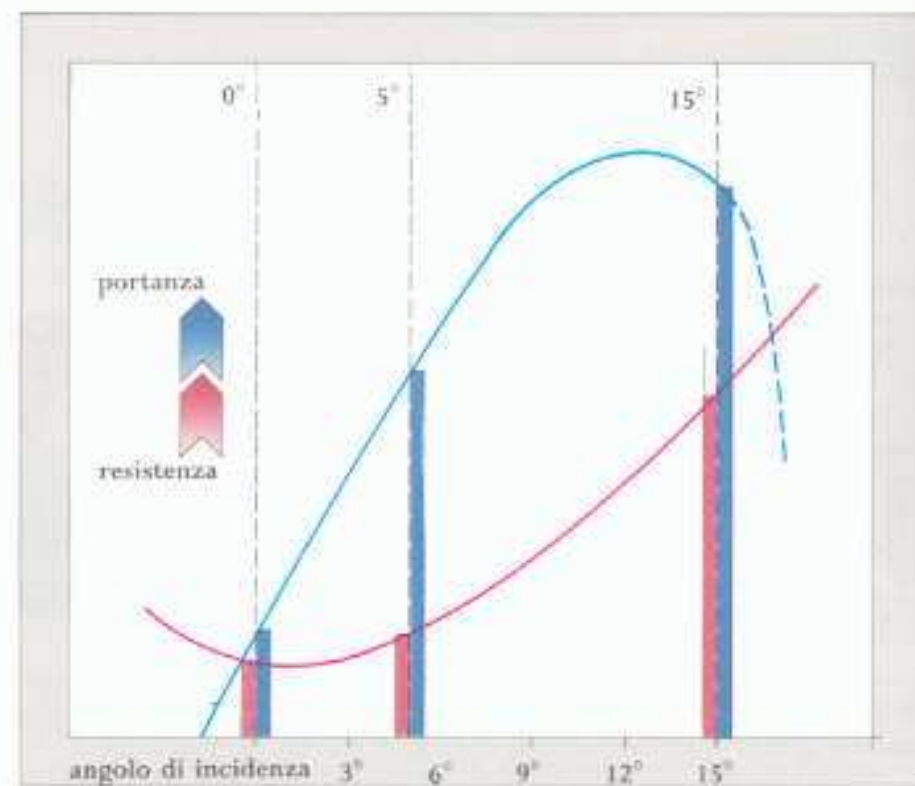
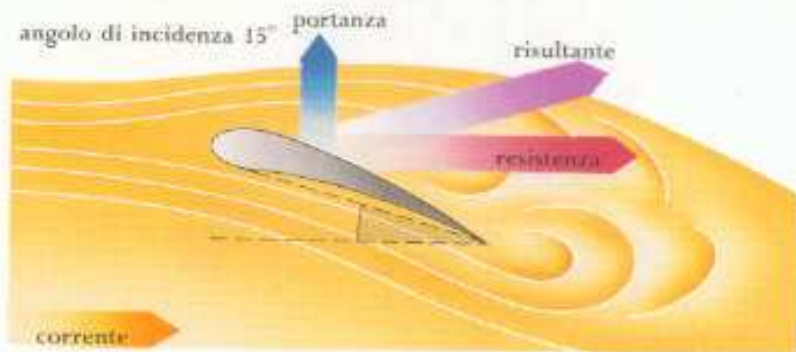
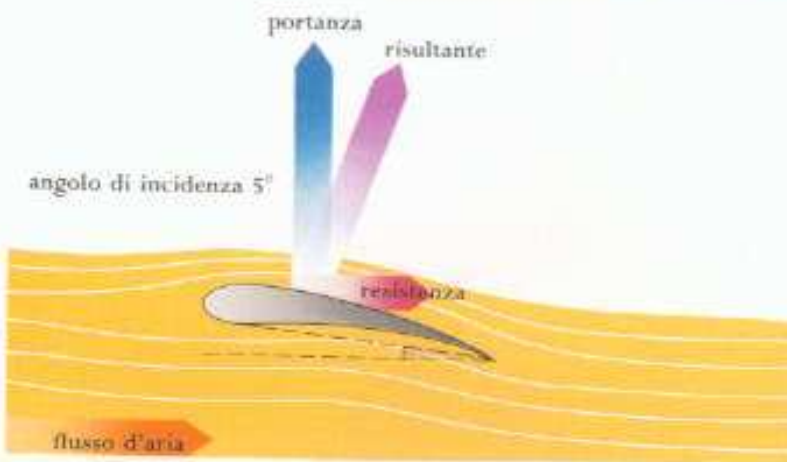
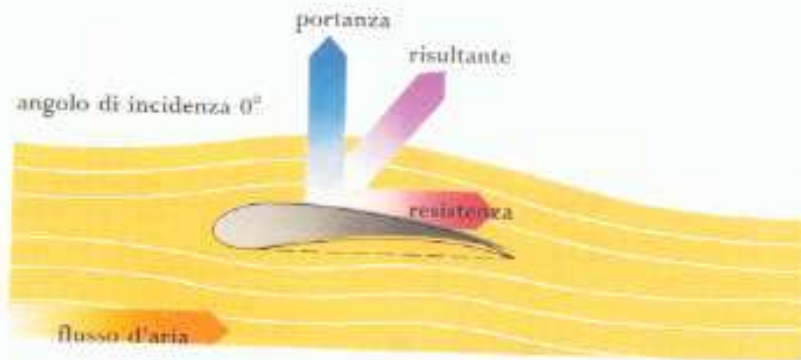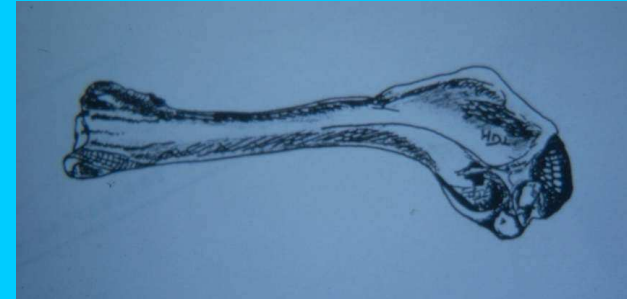## La portanza e il volo



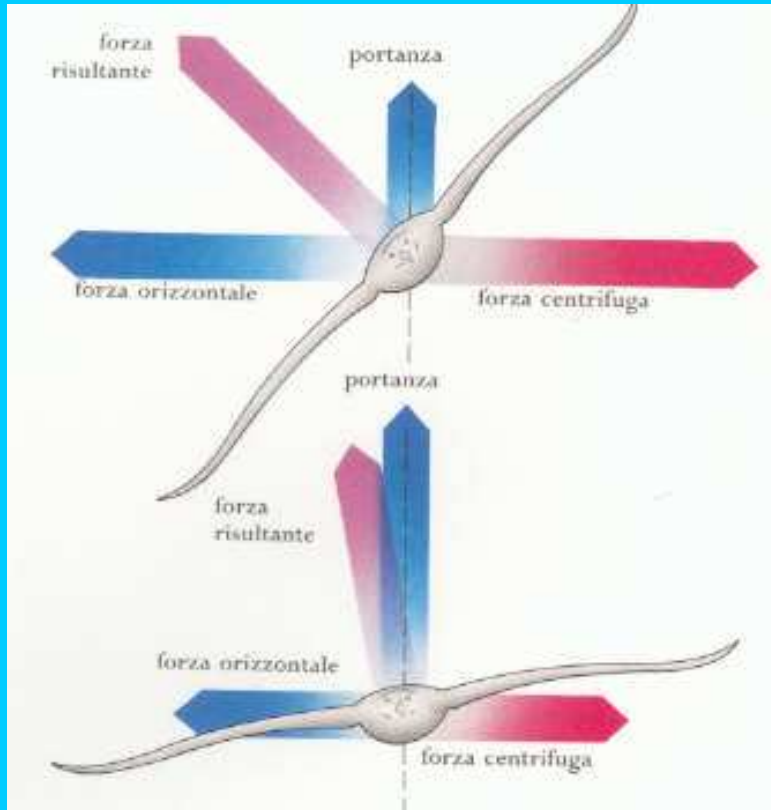


Portanza e teorema di Bernoulli

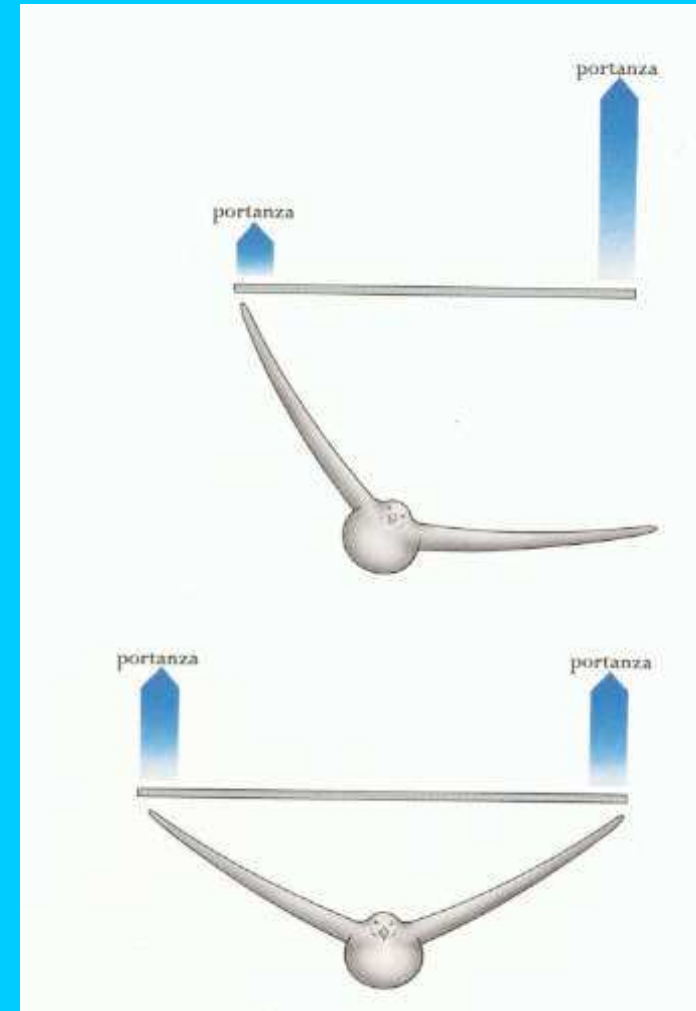
# Angolo di incidenza: il ruolo dell'omero



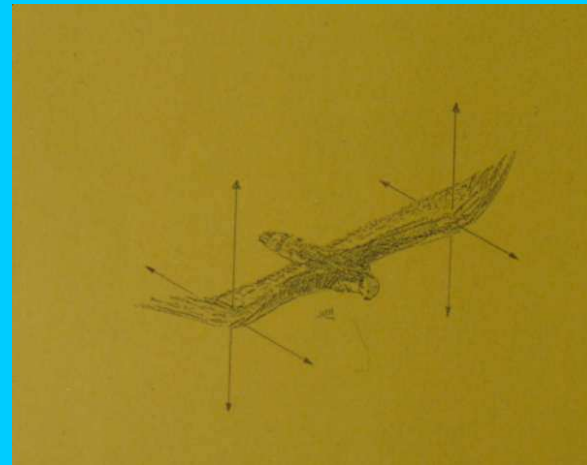

## Il volo inclinato



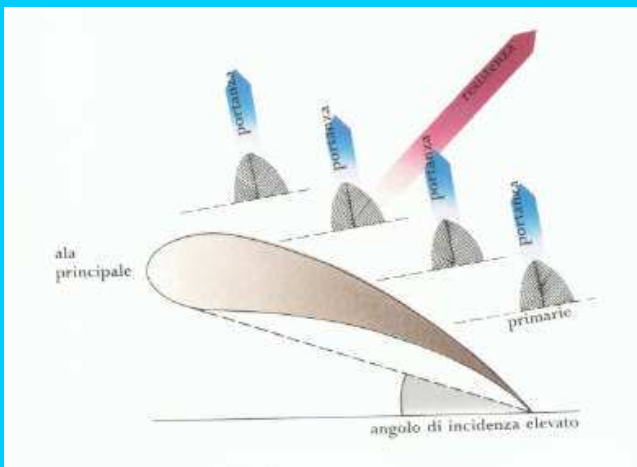
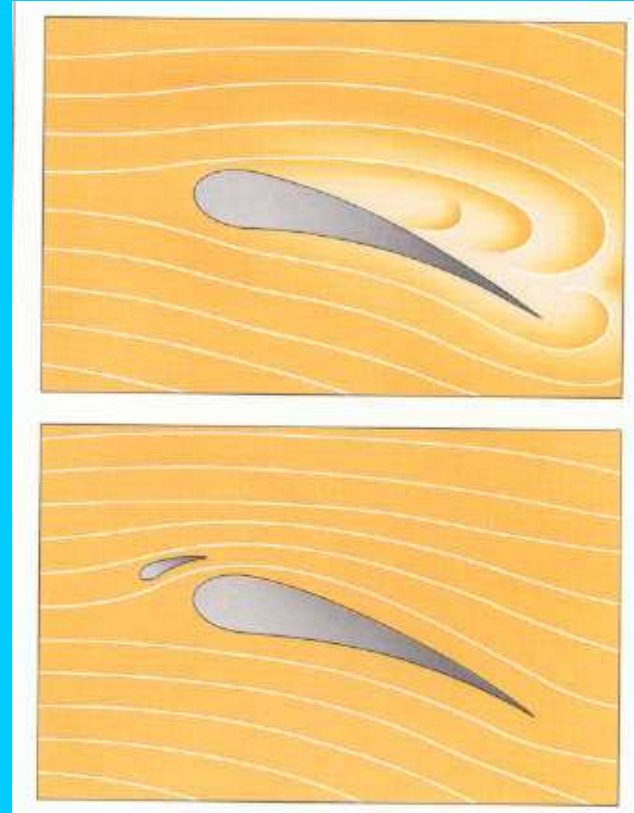
Diagnostica clinica e portanza



## Coefficiente di allungamento alare e punti di pressione

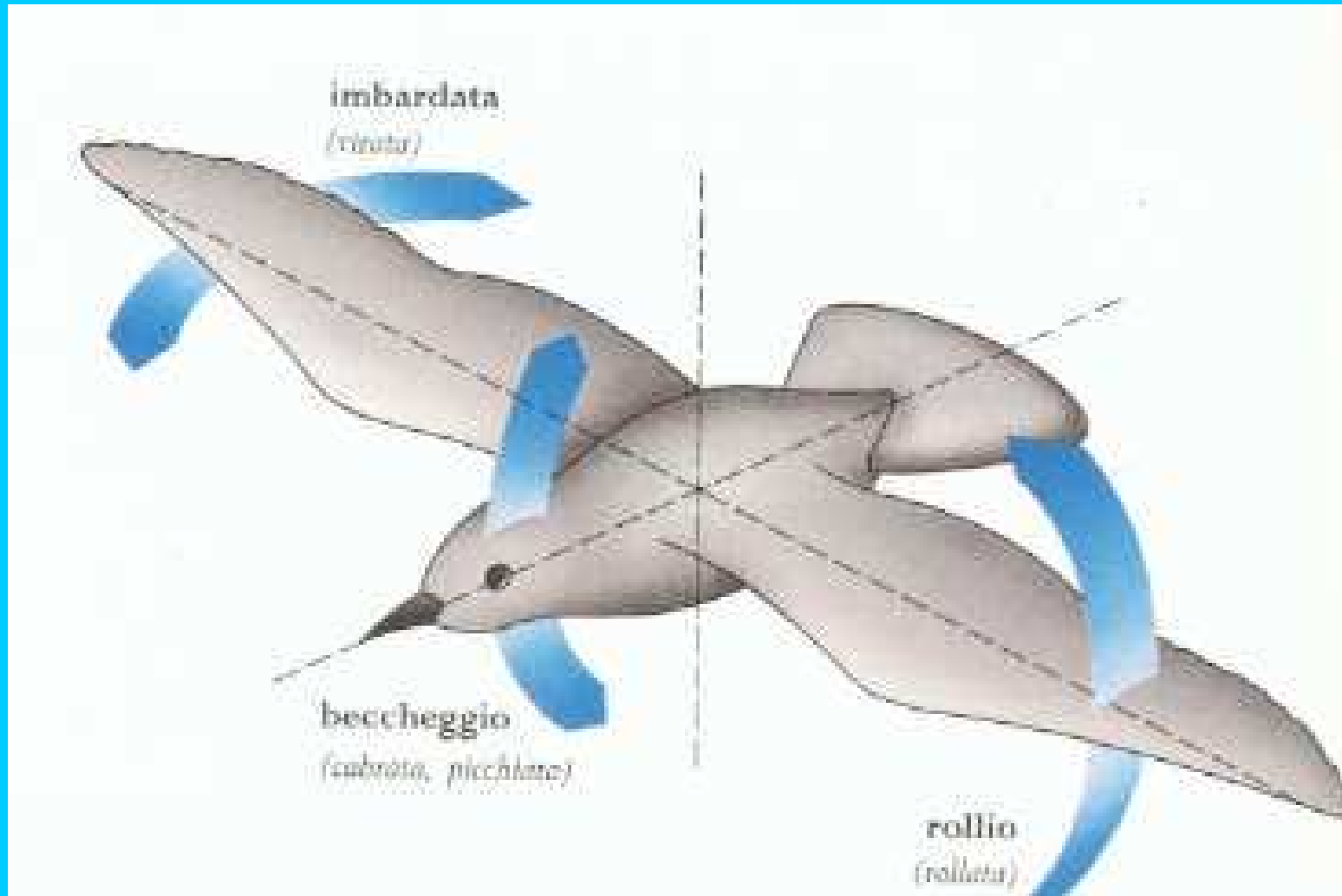






Ipersostentatori

## I movimenti del corpo in volo



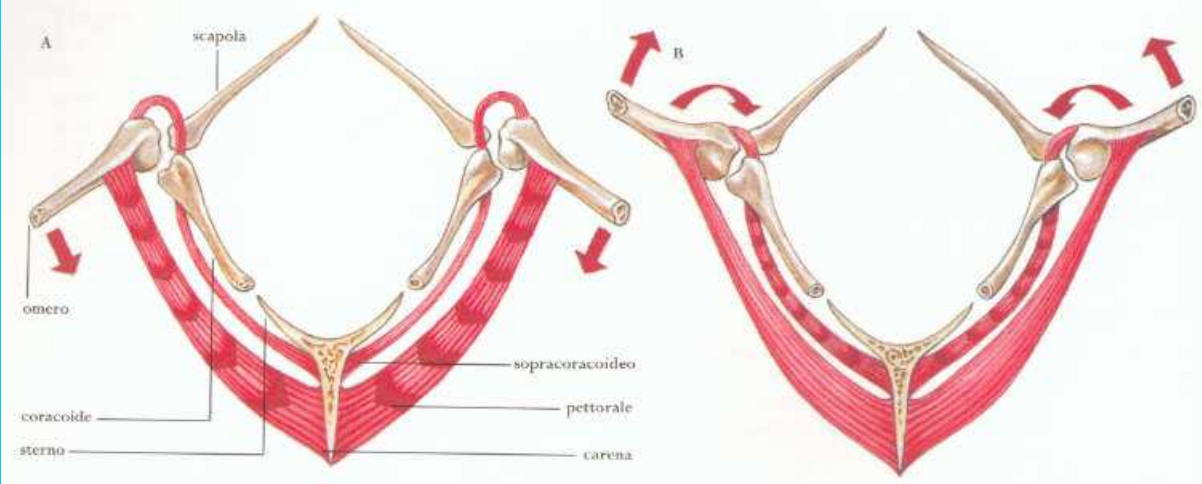
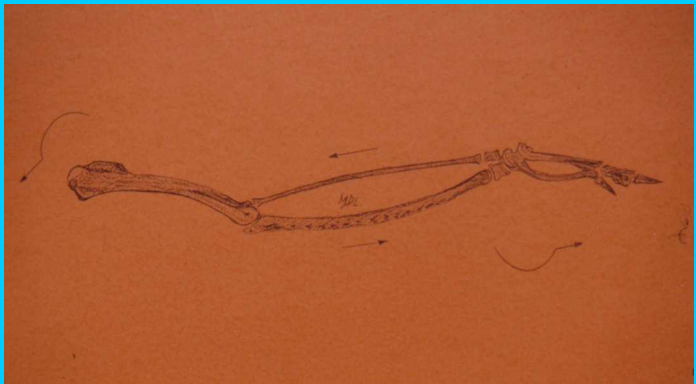
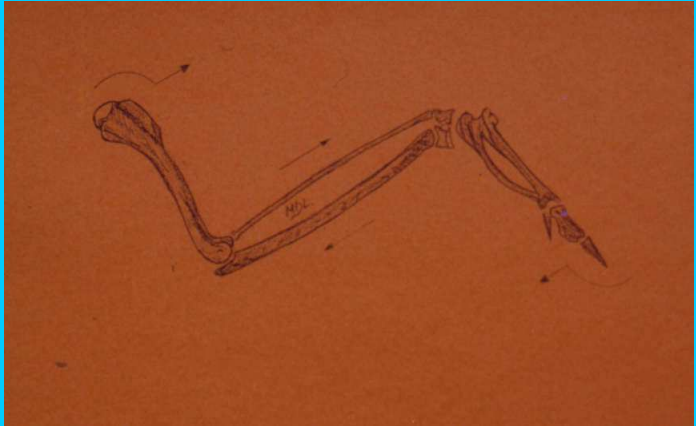
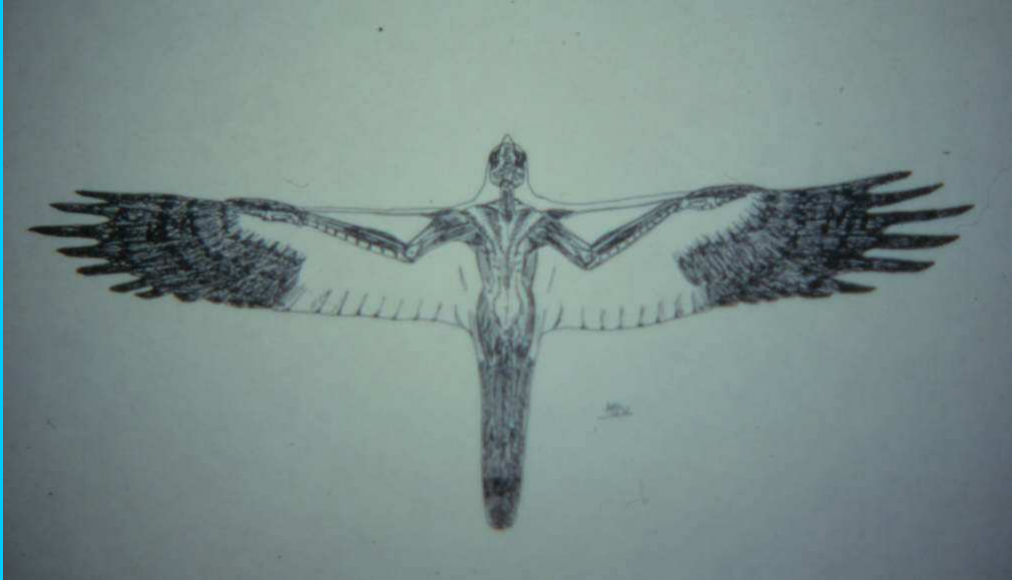




## Il carico alare

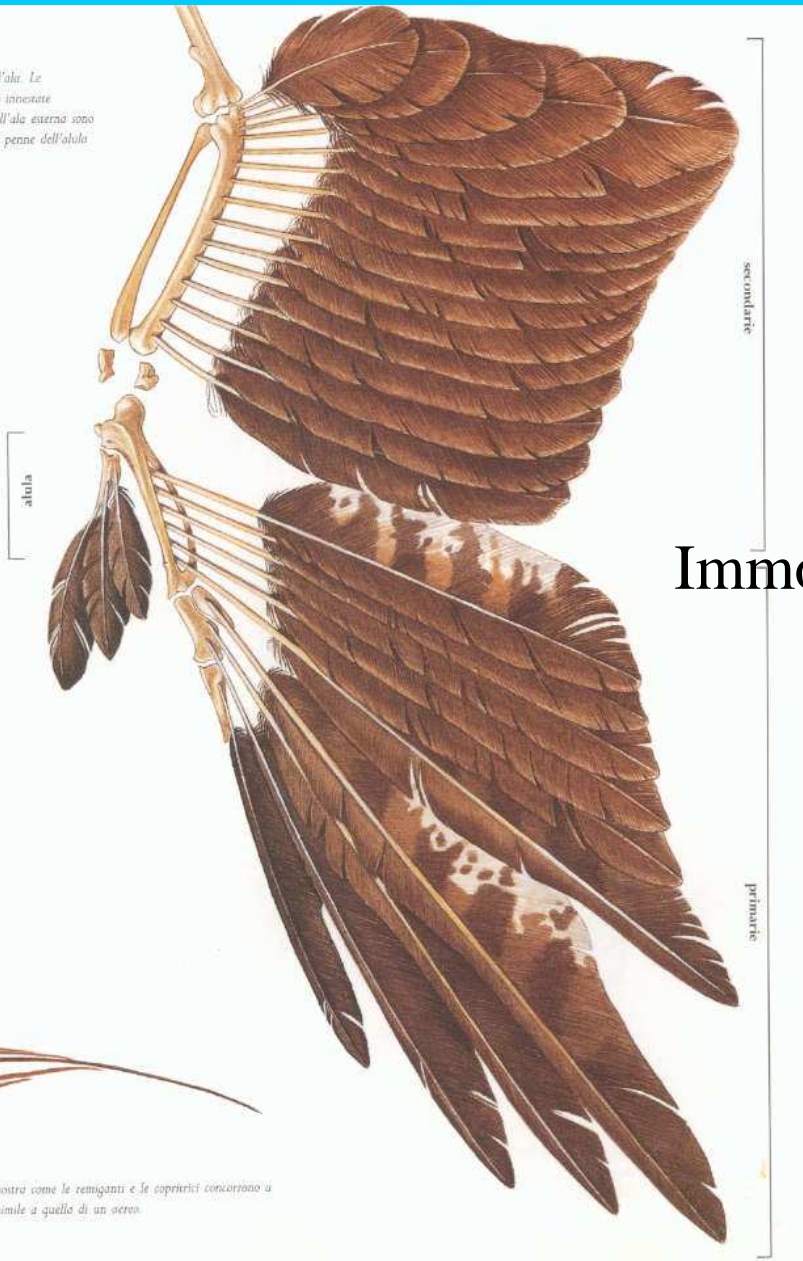


# Biomeccanica dell'ala





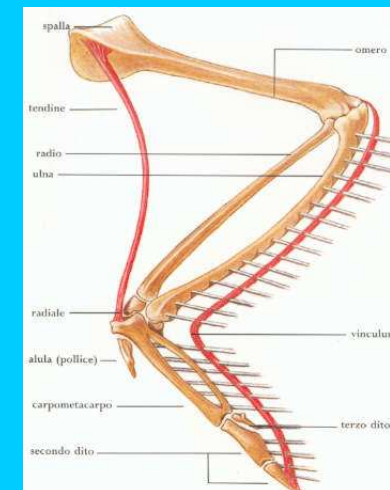
La disposizione delle penne sull'ala. Le secondarie dell'ala interna sono innestate sull'ulna mentre le primarie dell'ala esterna sono fissate alle ossa della mano. Le penne dell'alula sono impostate sul pollice.

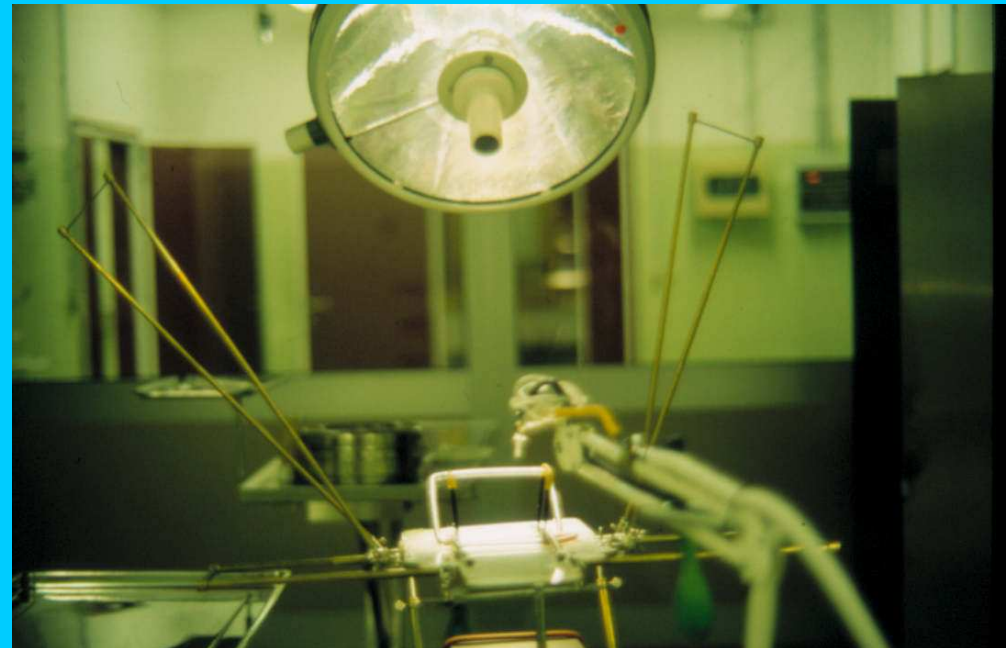

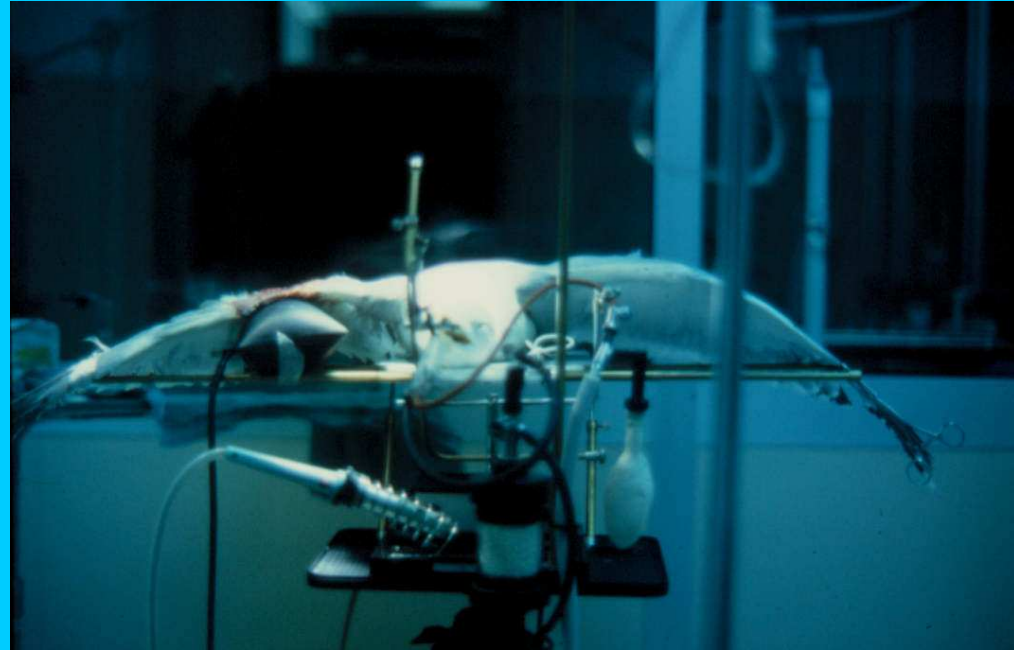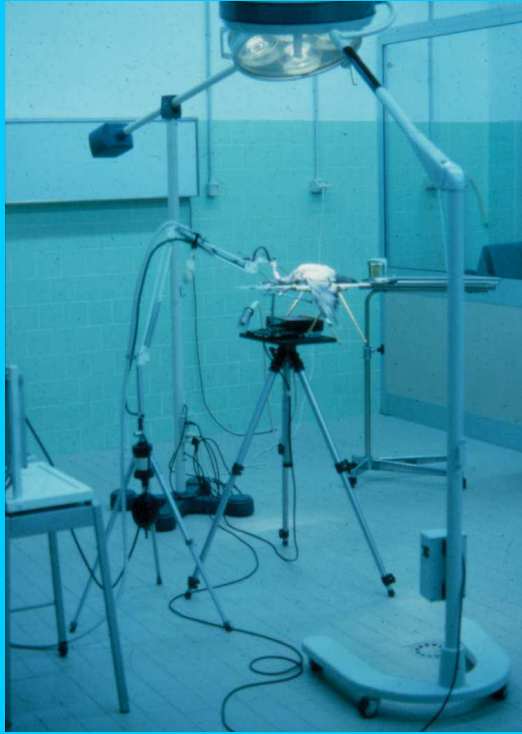


sopra La sezione di un'ala mostra come le remiganti e le copritrici concorrono a formare una superficie alare simile a quella di un aereo.



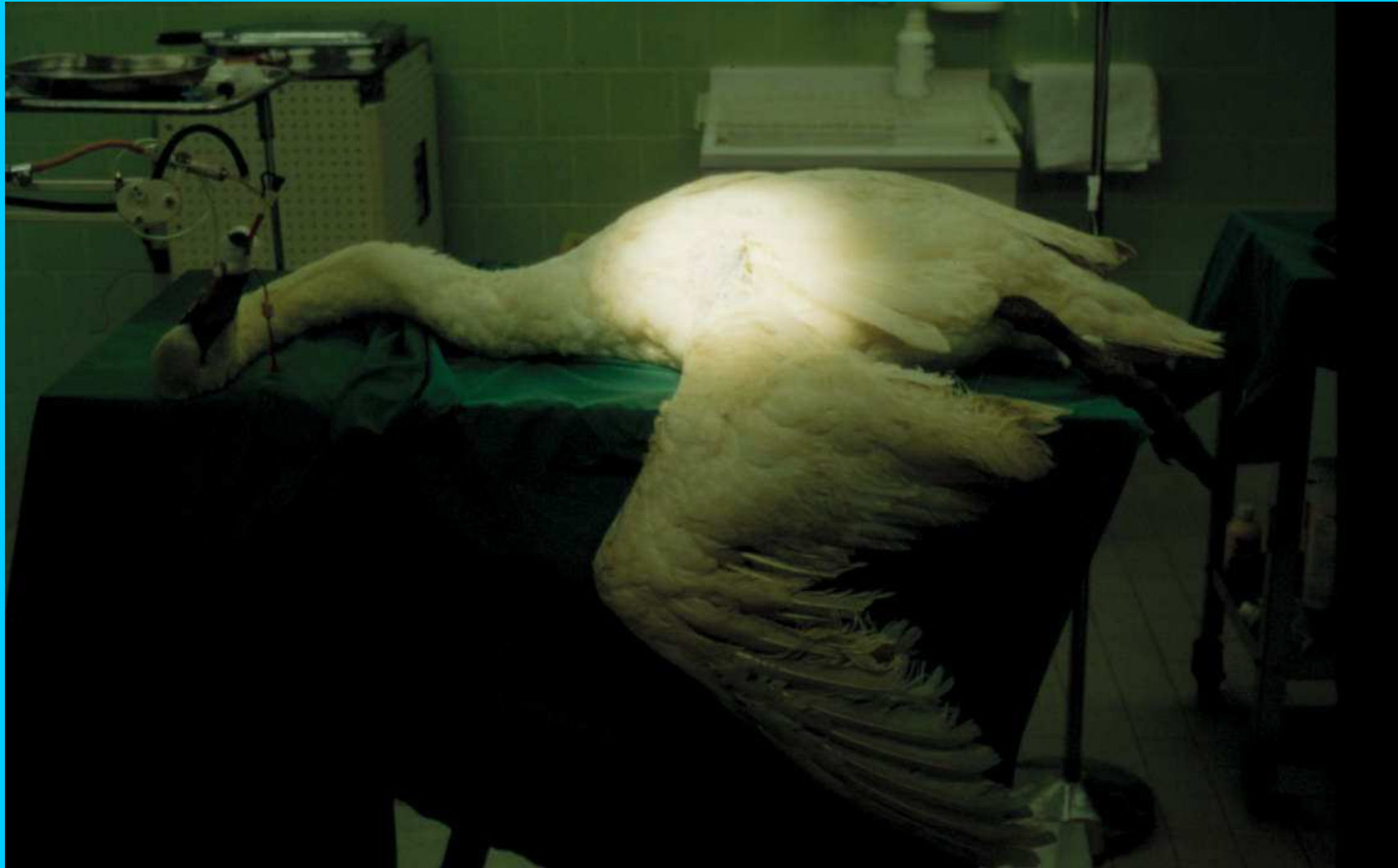## Immobilizzazione delle fratture





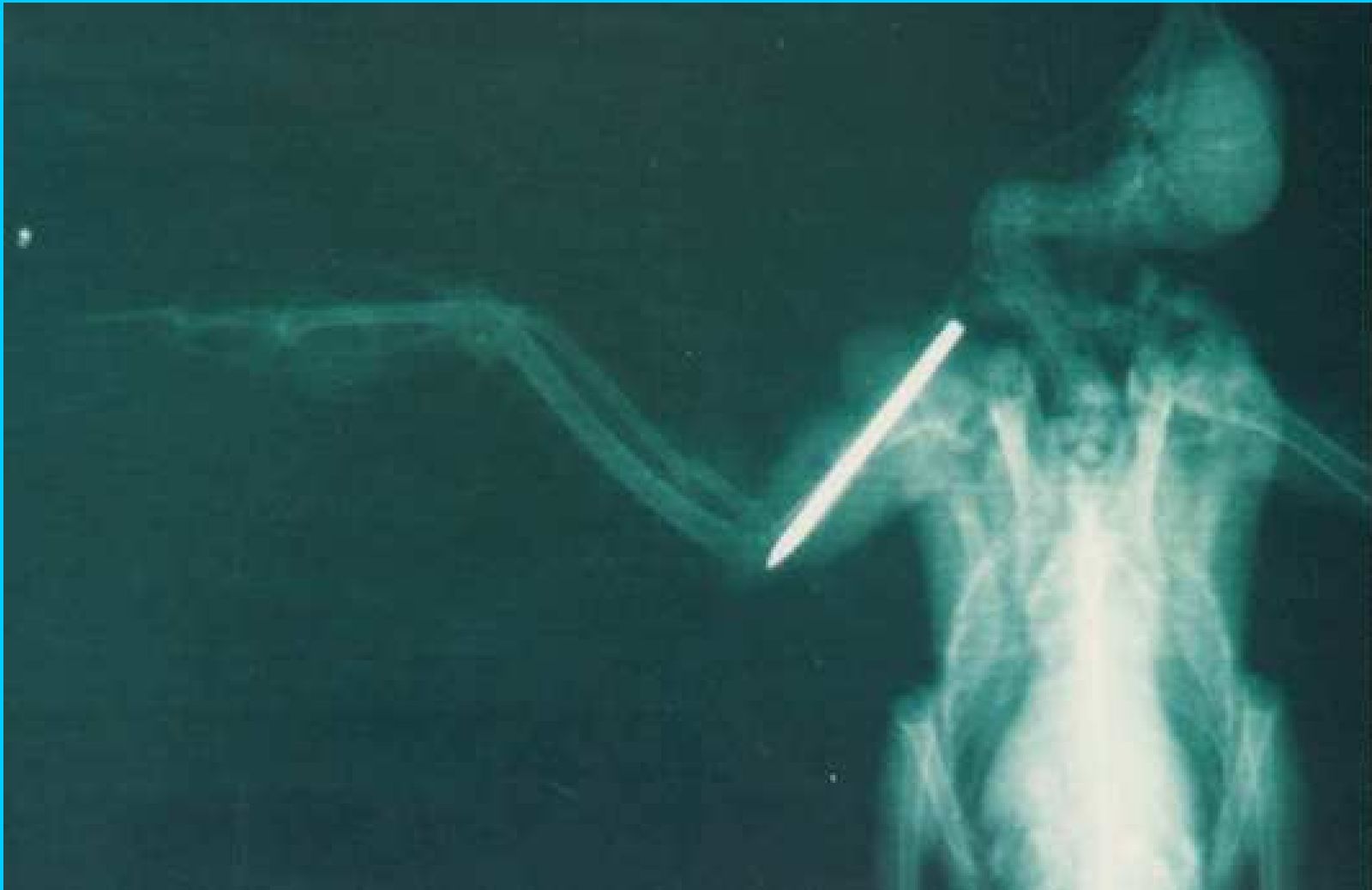Posizionamento dell'ala  
per la chirurgia

## Le vie chirurgiche di accesso


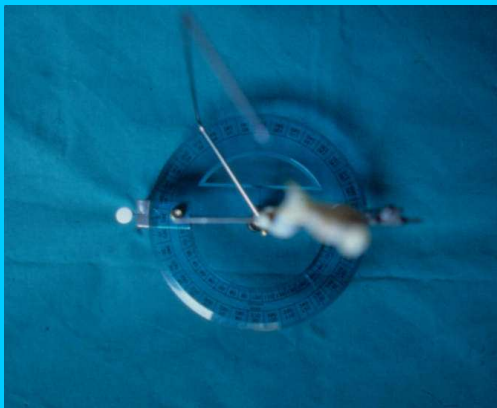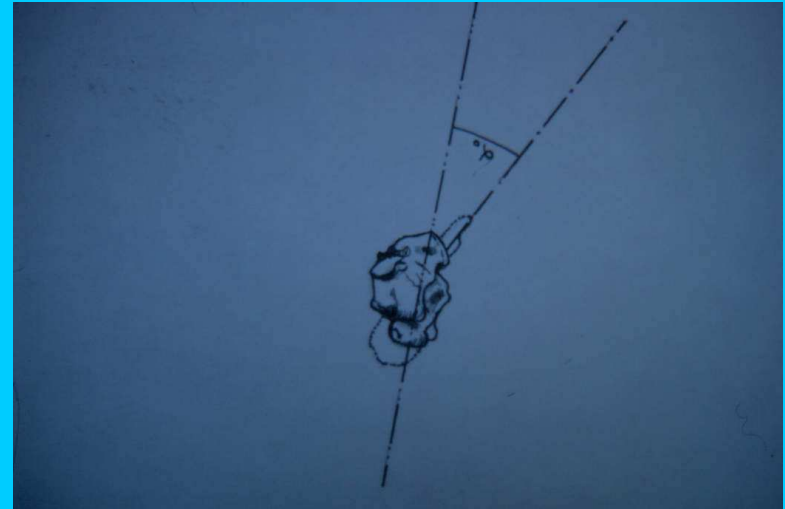


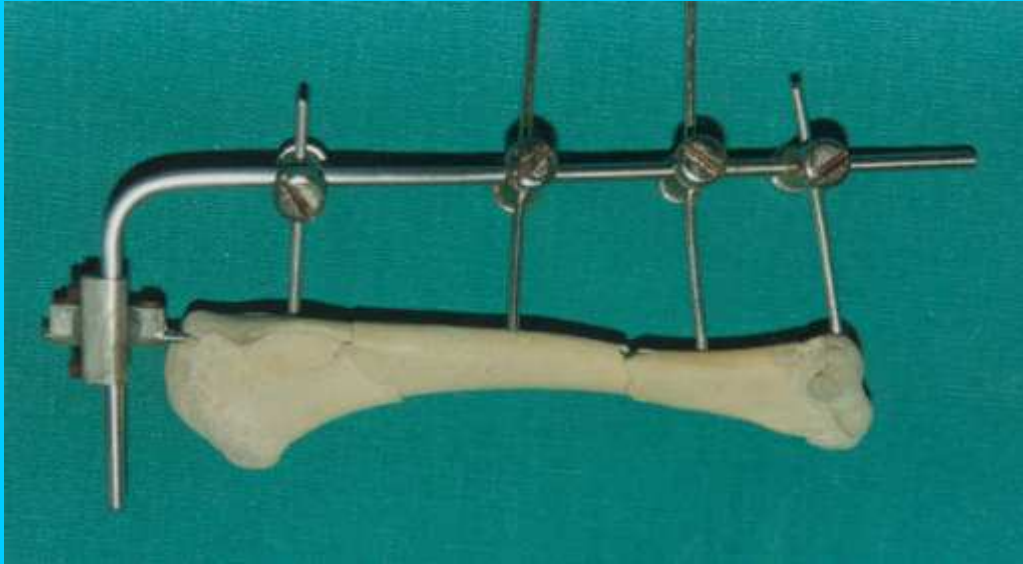


## Infibulazione centromidollare dell'omero

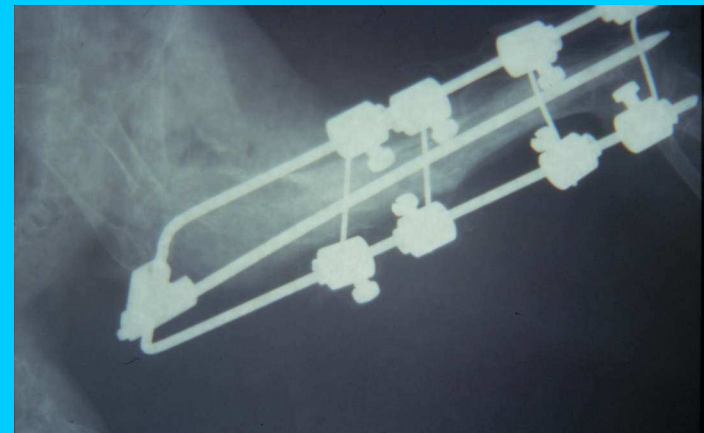
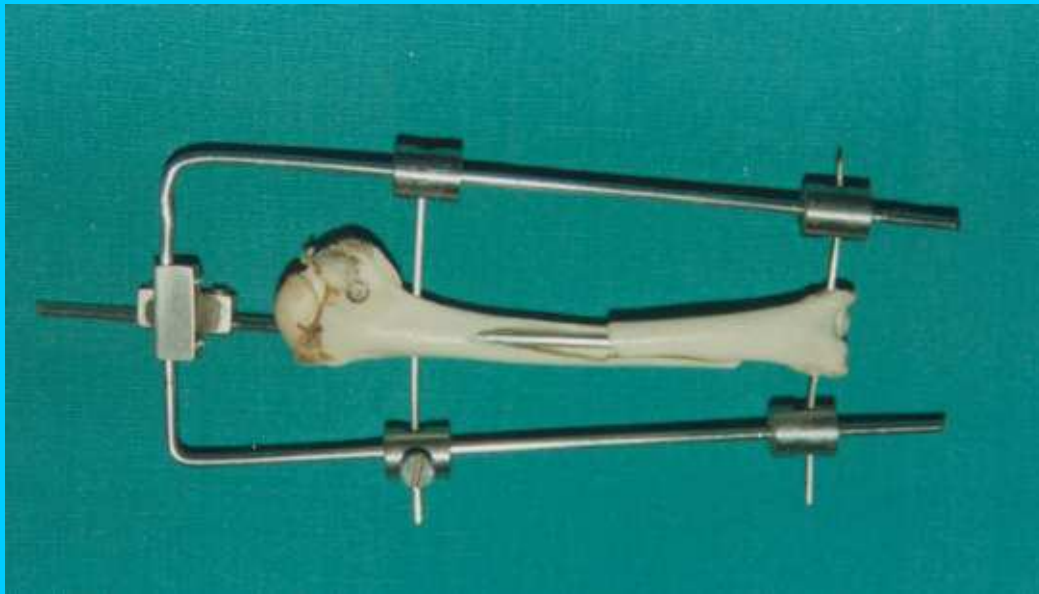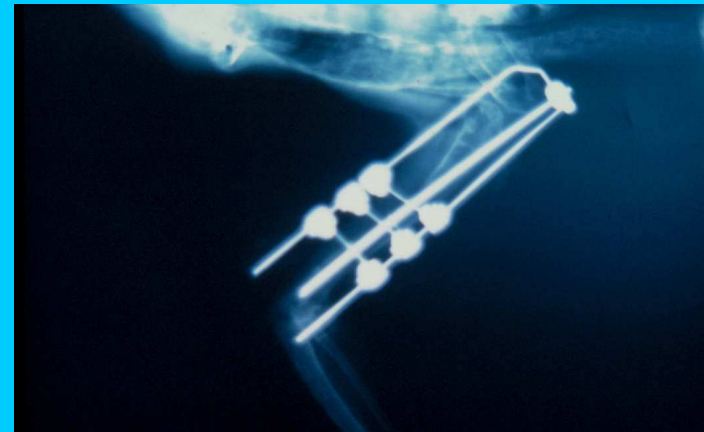
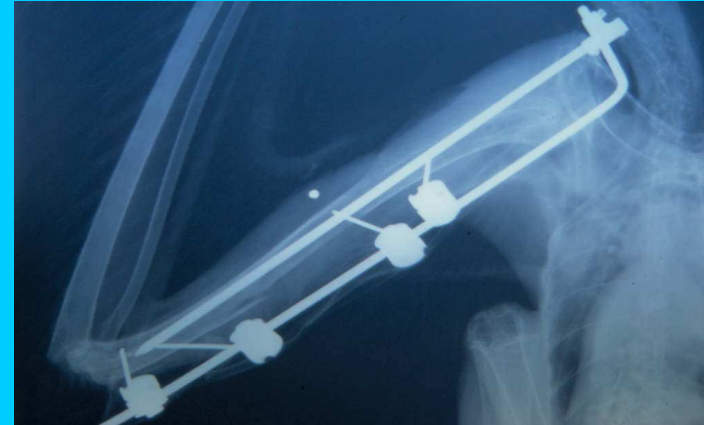


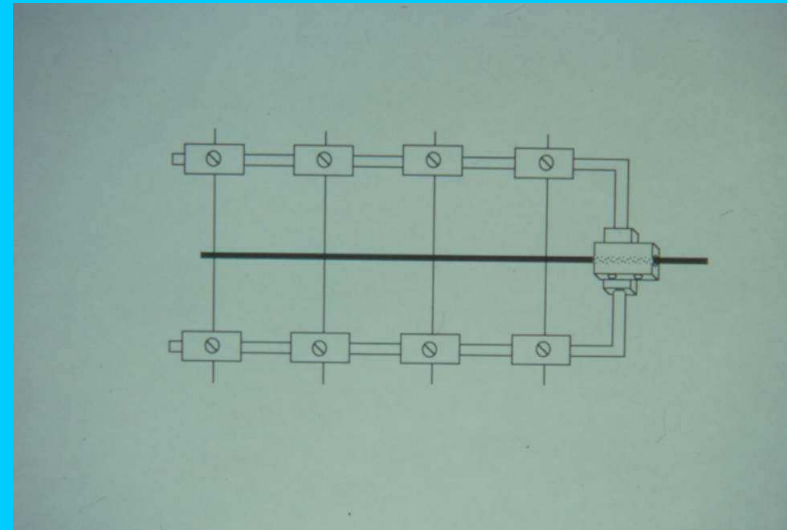
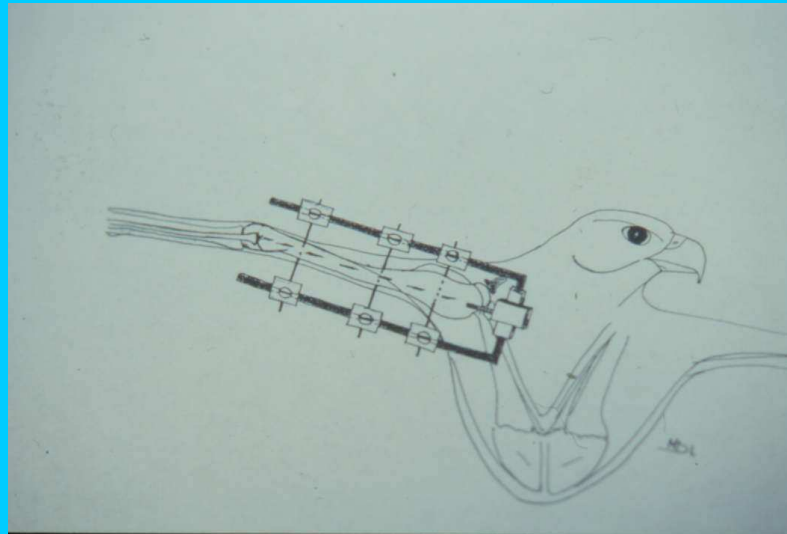
# Ripristino dell'angolo alare di incidenza




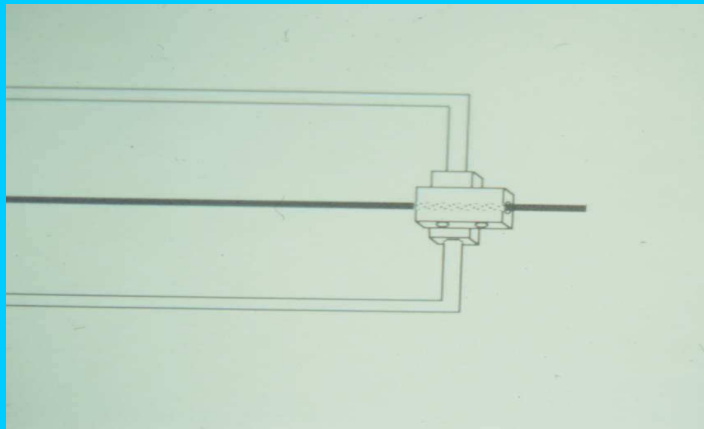


F E M




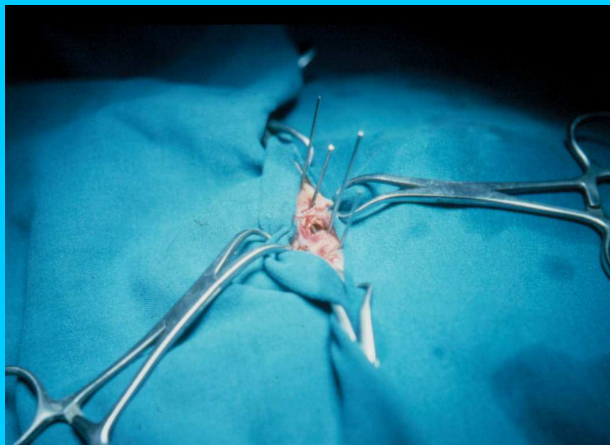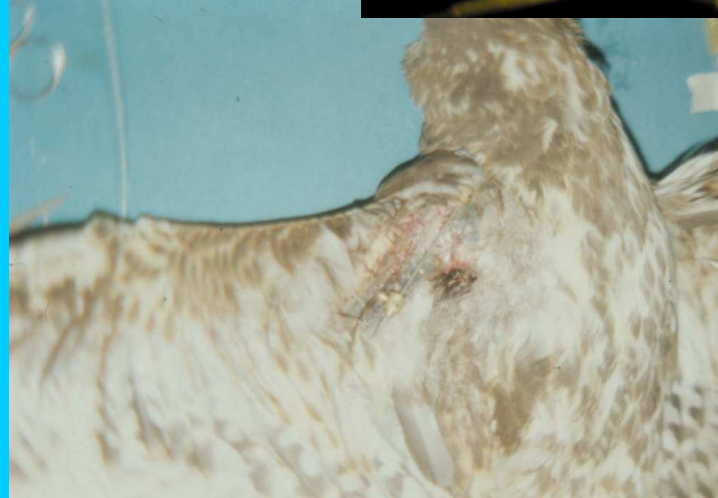
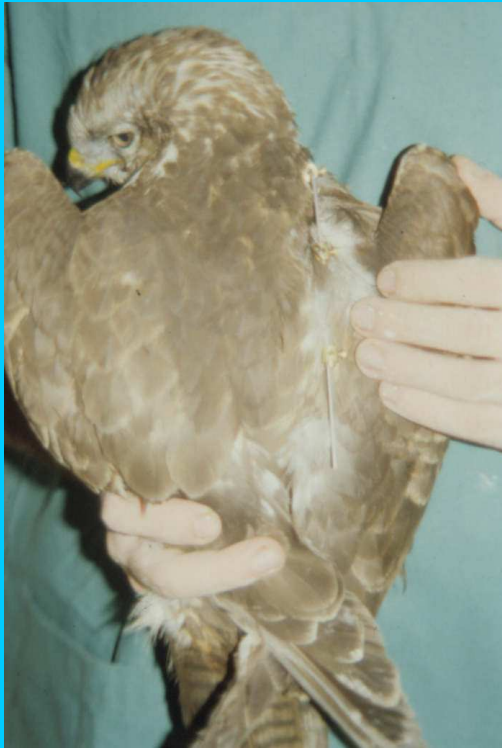

FEM

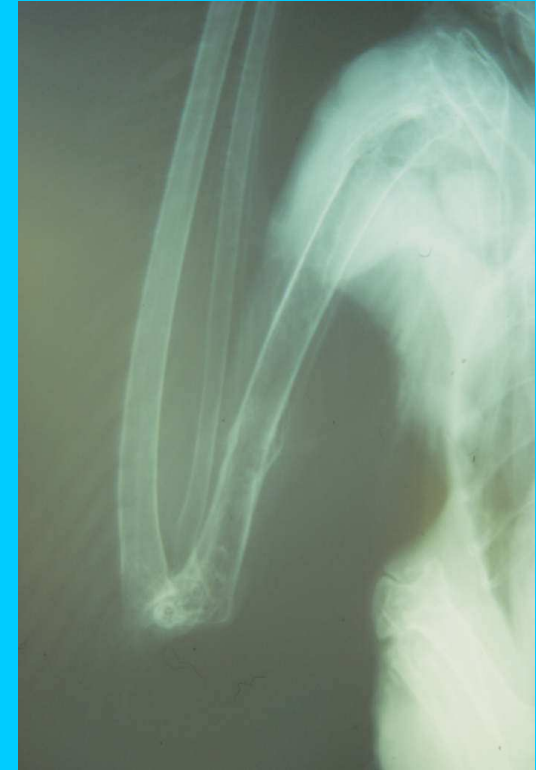
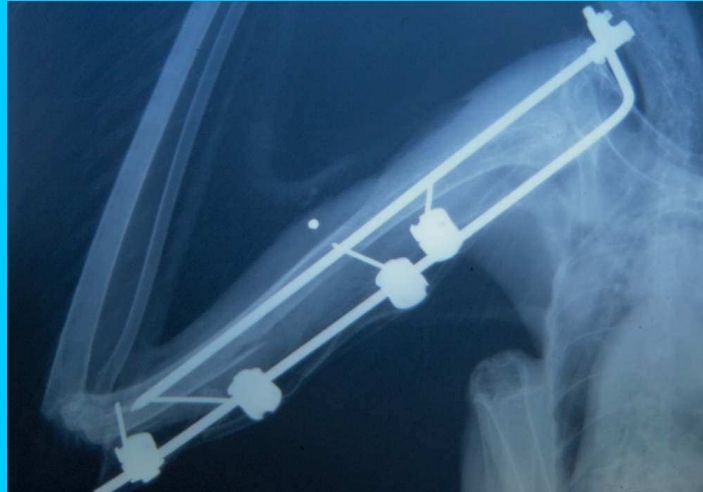
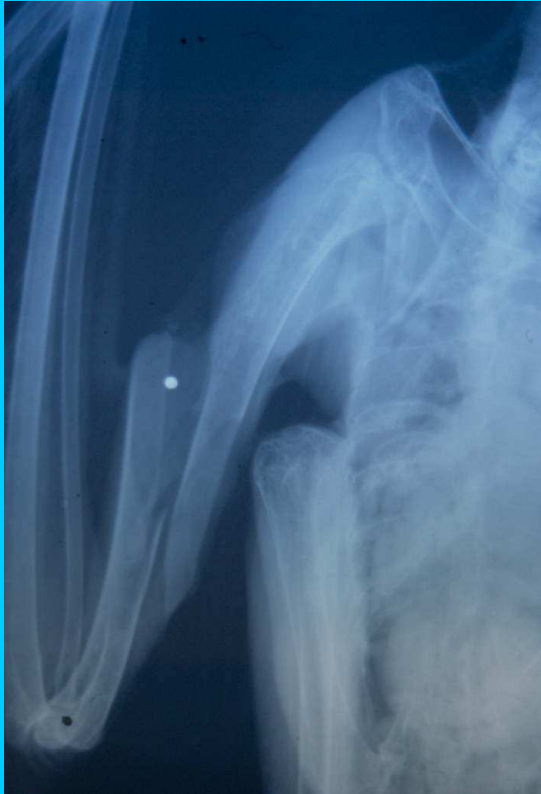



FEM



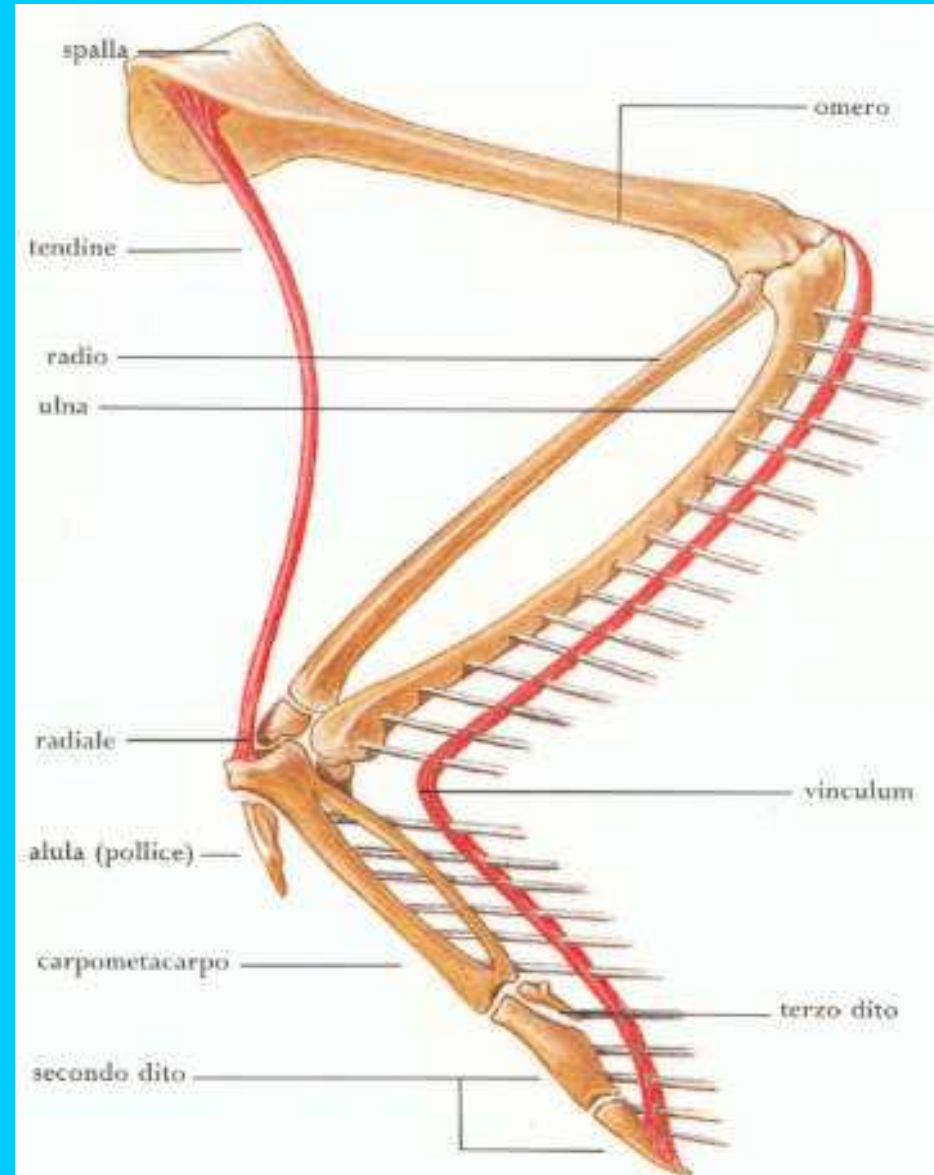
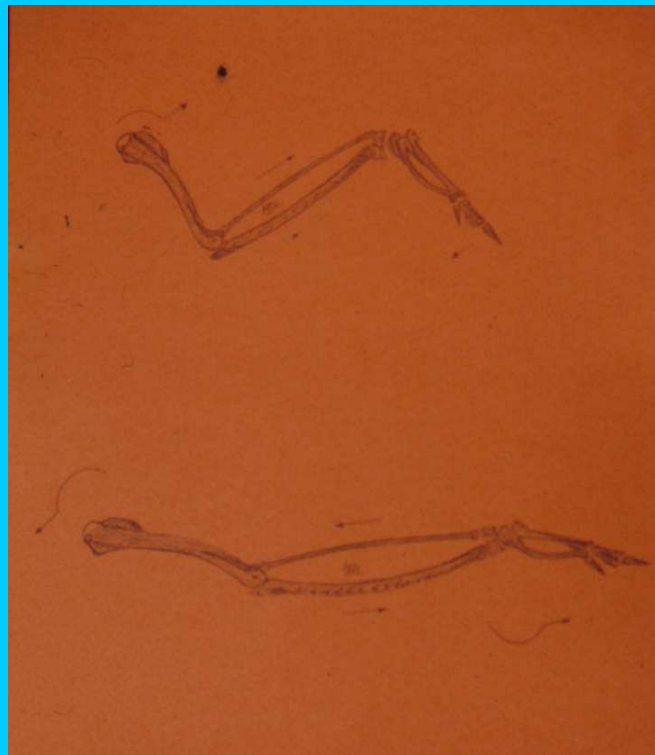
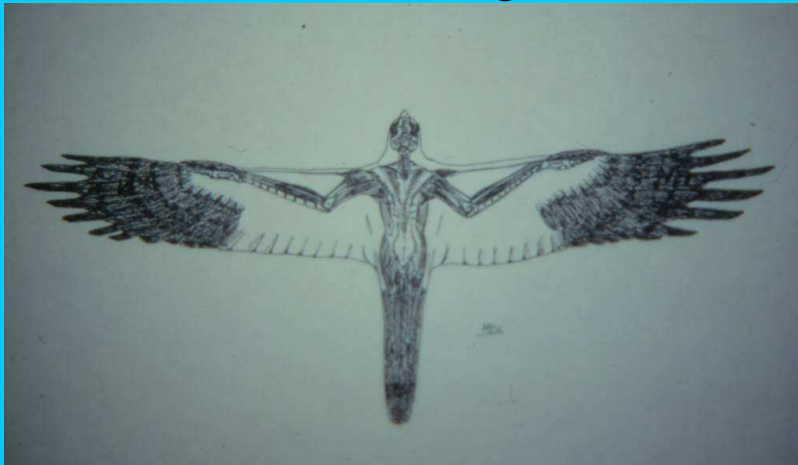



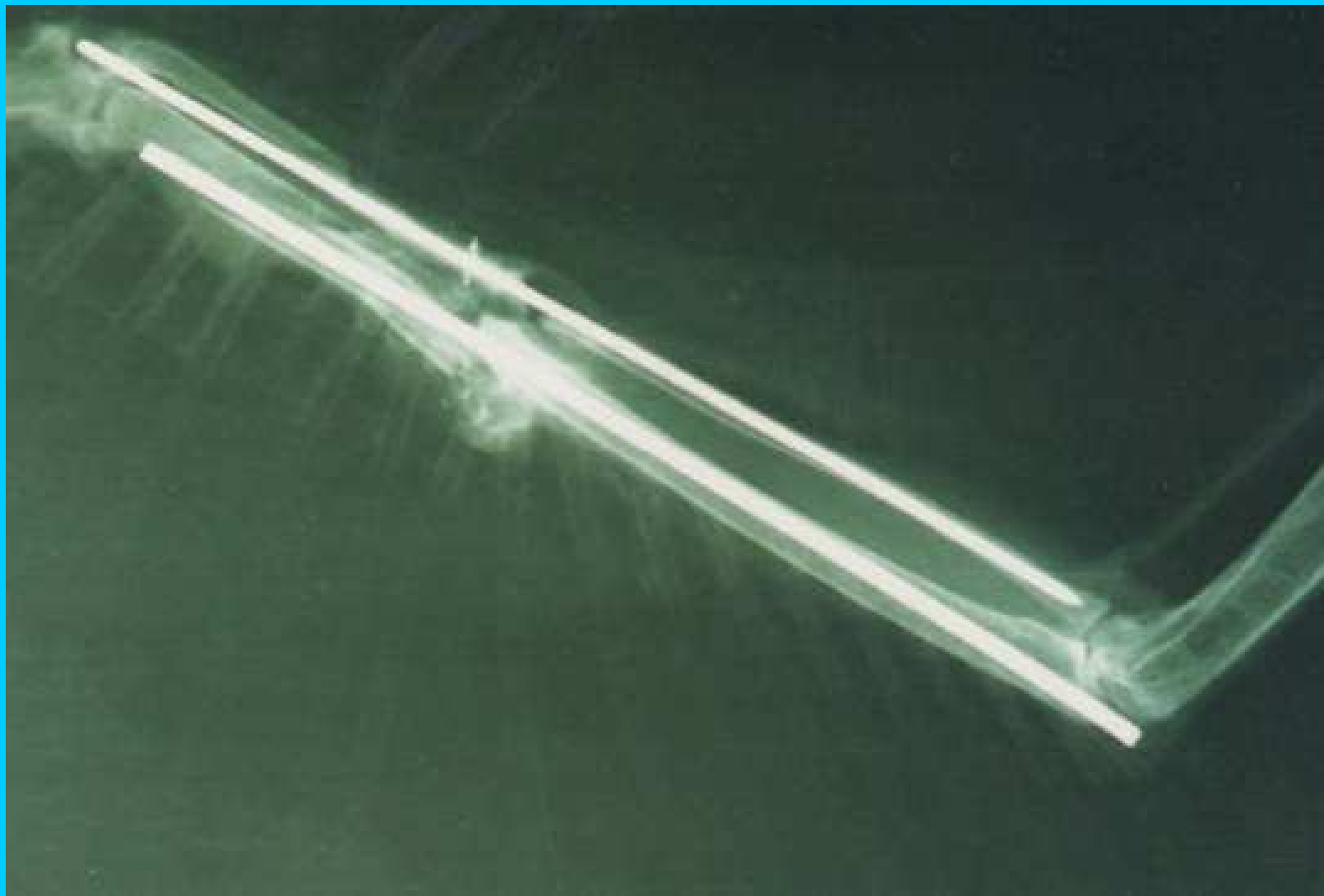
Riabilitazione nella  
chirurgia dell'omero

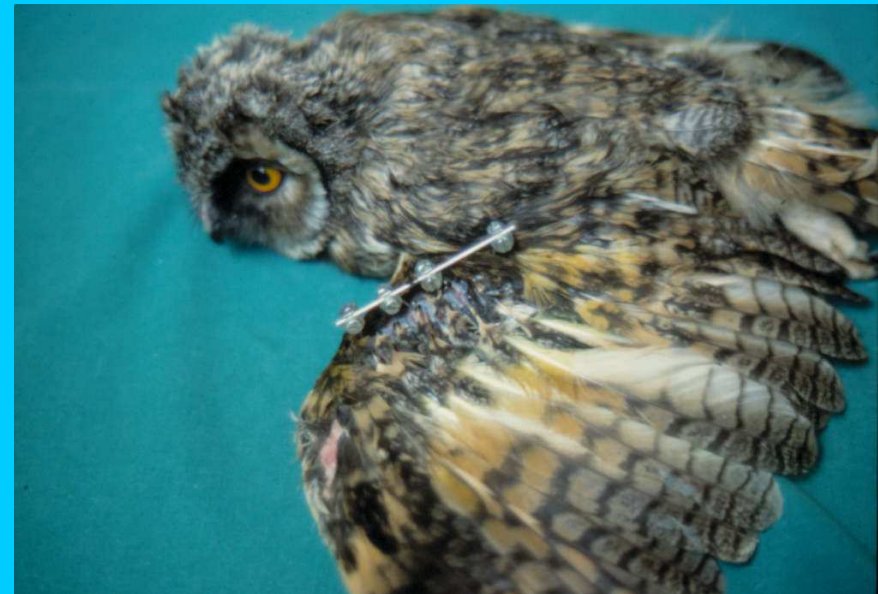
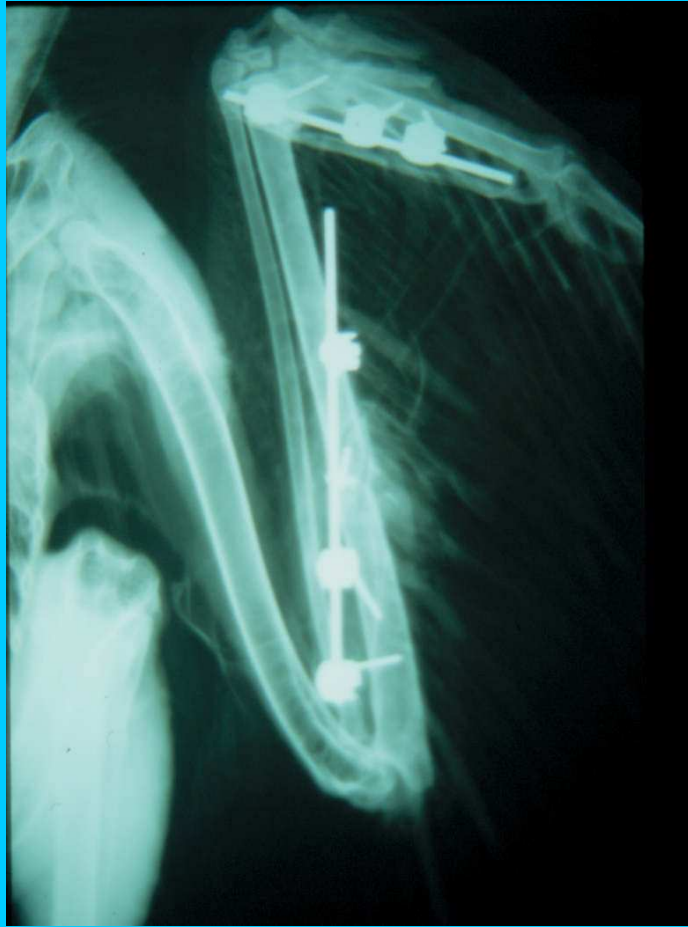


# Chirurgia dell'Avambraccio



## Infibulazione centromidollare di radio e ulna

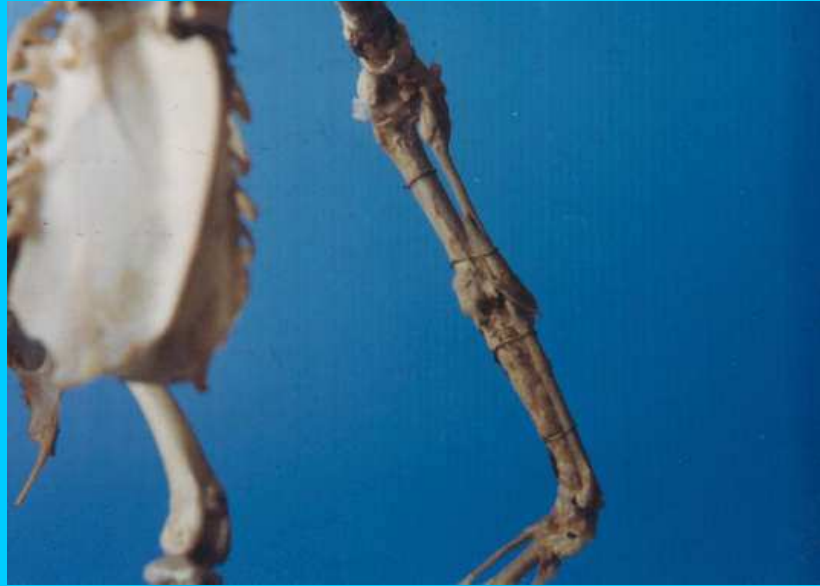




Chirurgia dell'avambraccio  
fissazione esterna

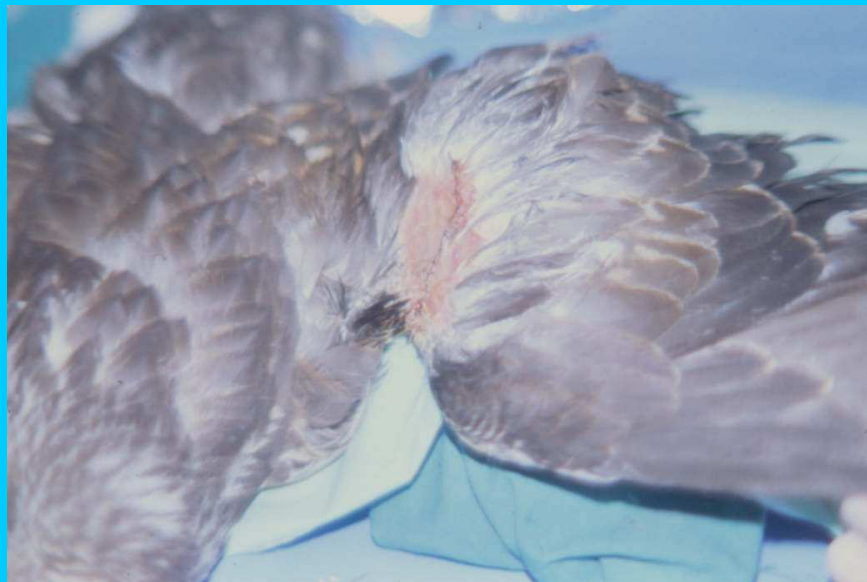
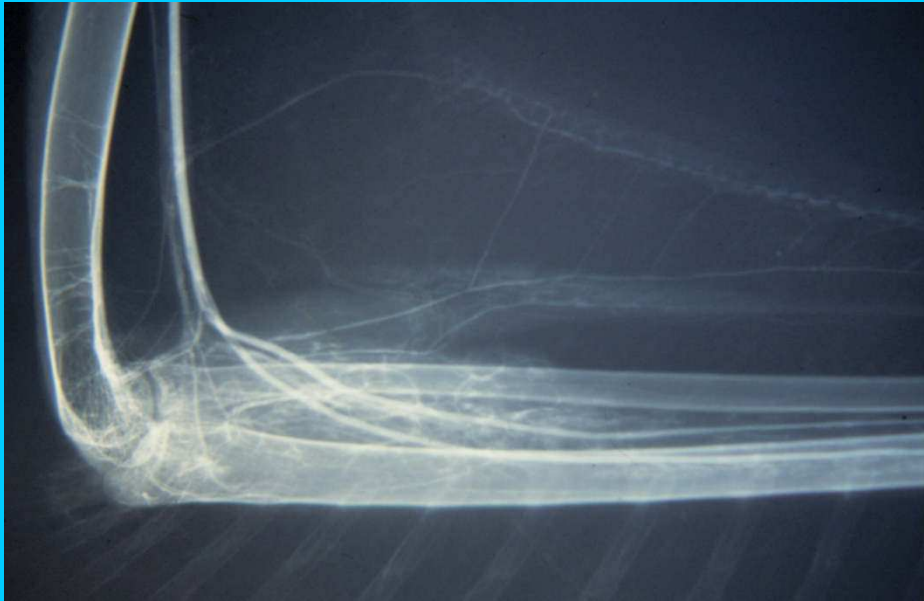
## Riabilitazione per l'avambraccio

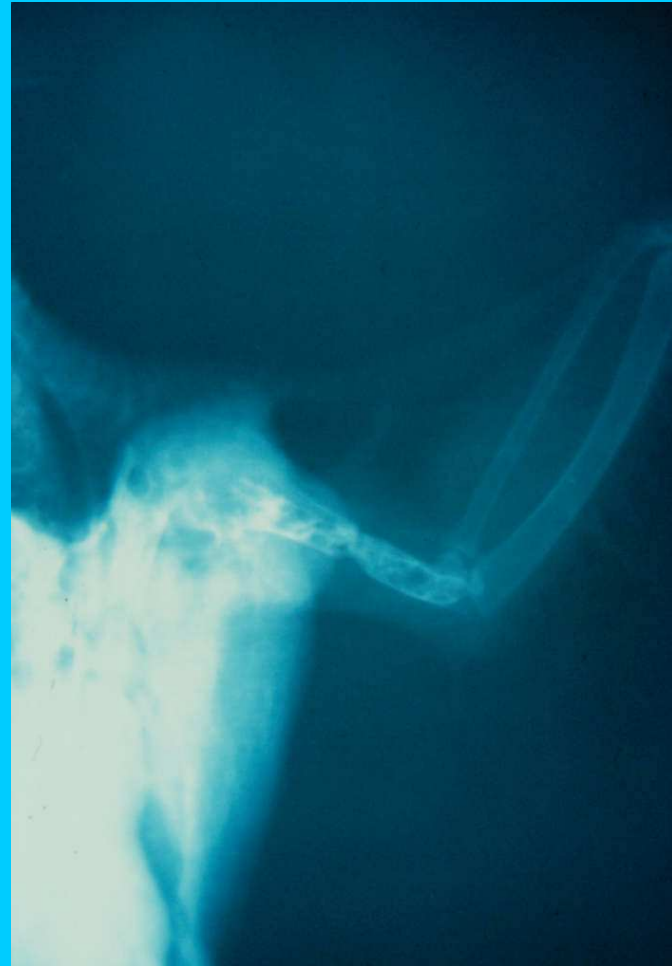
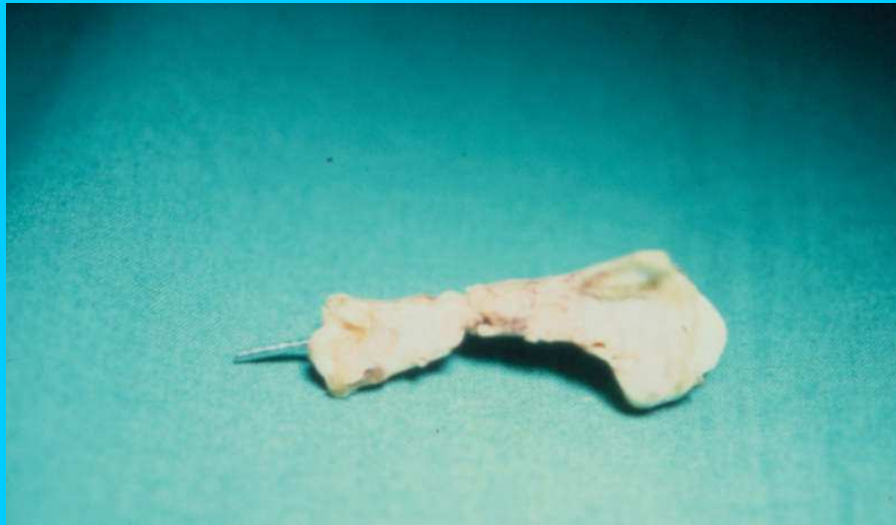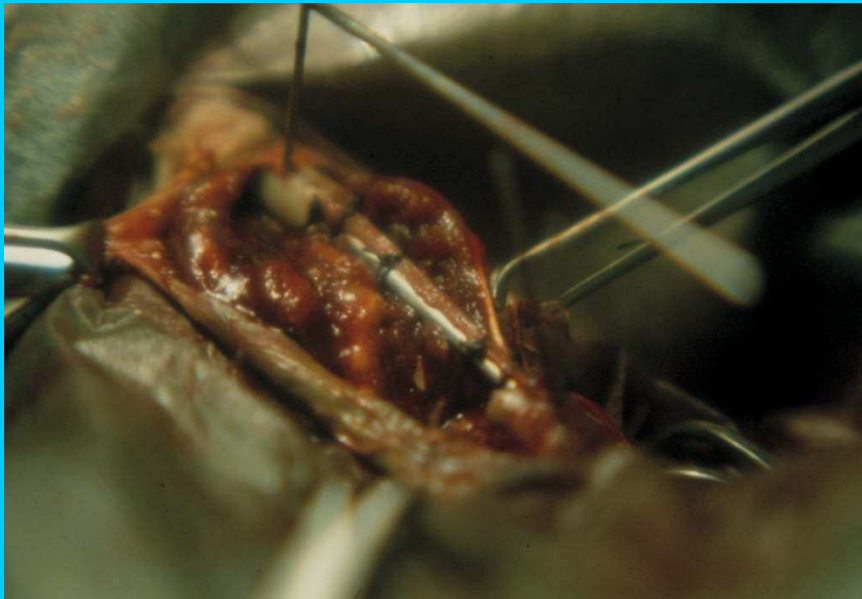


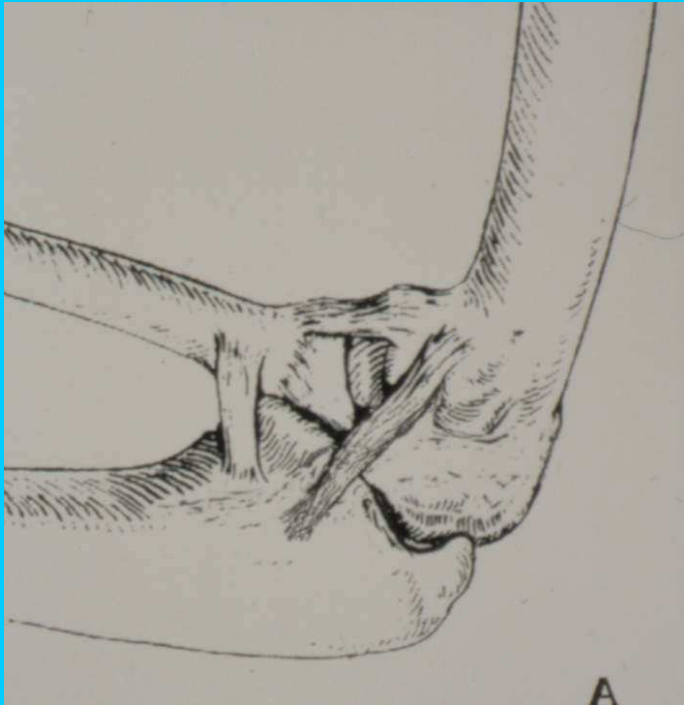


# Chirurgia del propatagio



## Rigenerazione Guidata Dei Tessuti





Chirurgia dei legamenti omero ulnari