



Contents lists available at ScienceDirect

Respiratory Medicine Case Reports

journal homepage: www.elsevier.com/locate/rmcr

Cytomegalovirus pneumonitis complicated by a central peribronchial pattern of organising pneumonia



Maria M. Cuadrado ^{a, *}, Asia Ahmed ^b, Ben Carpenter ^a, Jeremy S. Brown ^c

^a Clinical Haematology, University College Hospital, 235 Euston Road, London, NW1 2BU, United Kingdom

^b Imaging Department, University College Hospital, 235 Euston Road, London, NW1 2BU, United Kingdom

^c Centre for Inflammation and Tissue Repair, Division of Medicine, University College Medical School, Rayne Institute, London, WC1E 6JJ, United Kingdom

ARTICLE INFO

Article history:

Received 6 December 2016

Received in revised form

5 February 2017

Accepted 8 February 2017

Keywords:

Organising pneumonia

Cytomegalovirus pneumonitis

Allogeneic stem cells transplantation

(AlloHSCT)

ABSTRACT

We present five cases of cytomegalovirus (CMV) pneumonitis occurring in patients after recent T cell deplete allogeneic stem cell transplantation (AlloHSCT). These cases were complicated by an organising pneumonia (during the recovery period) with a predominantly central peribronchial pattern. All patients presented with evidence of active CMV pneumonitis which was treated successfully with anti-viral therapy but was followed by persistent severe dyspnoea, cough and hypoxia. High resolution computed tomography (HRCT) imaging showed widespread central peribronchial consolidation with traction bronchiectasis. There was a marked clinical and physiological improvement after treatment with systemic corticosteroids. However, in all patients the lung function remained abnormal and in some cases imaging revealed a fibrosing lung disease. These cases represent a previously undescribed central peribronchial pattern of organising pneumonia complicating CMV pneumonitis that can result in chronic lung damage.

© 2017 Published by Elsevier Ltd. This is an open access article under the CC BY-NC-ND license (<http://creativecommons.org/licenses/by-nc-nd/4.0/>).

1. Introduction

T cell deplete allogeneic stem cell transplantation (AlloHSCT) is frequently complicated by non-infective and infective lung complications. Infective lung complications include cytomegalovirus (CMV) pneumonitis, which usually presents with cough, dyspnoea and increasing hypoxia associated with systemic reactivation of CMV infection. The radiological pattern on high resolution computed tomography (HRCT) is variable but most commonly shows widespread bilateral ground glass infiltrates [1,2]. Organising pneumonia is an uncommon non-infective respiratory complication of T cell deplete AlloHSCT. It can be idiopathic or it can occur as a complication of infection, radiotherapy or drug therapy [3,4,5]. In organising pneumonia, HRCT usually demonstrates patchy subpleural consolidation with no particular lobar or zonal predominance [6]. Treatment with systemic corticosteroids is usually highly effective [7,8]. Here we describe five cases of CMV pneumonitis affecting AlloHSCT recipients (patient characteristics shown in Table 1) complicated by a probable organising pneumonia with a distinctive clinical and radiological course.

1.1. Case series

1.1.1. Patient 1

A 28 year old female non-smoker received a T deplete matched unrelated donor AlloHSCT for refractory Hodgkin's lymphoma. On day +25 post-AlloHSCT, serum polymerase chain reaction (PCR) indicated systemic reactivation of CMV with a blood viral load that reached a maximum of 55000 copies/ml by day +39 and a CRP of 50 mg/L (normal range 0–5). This was associated with progressive dyspnoea and an oxygen saturation of 86% on air. HRCT on day +39 showed a bilateral symmetrical ground glass infiltrate with interlobular septal thickening compatible with a viral pneumonitis [Fig. 1A(i)]. CMV PCR viral load in bronchoalveolar lavage (BAL) fluid obtained on day +43 was 3400 copies/ml; microbiological and cytology tests for other pathogens were negative. After treatment with intravenous foscarnet the patient became afebrile and the blood CMV viral load negative, with no clinical evidence of active infection. However, the patient remained dyspnoeic [Medical Research Council (MRC) dyspnoea scale grade 4] with an oxygen saturation of 88% on air. HRCT on day +57 showed dense central peribronchial consolidation with traction bronchiectasis and a perilobular pattern of consolidation in the periphery associated with pleuro-parenchymal distortion [Fig. 1A(ii)]. The patient was

* Corresponding author.

E-mail address: maria.cuadrado@uclh.nhs.uk (M.M. Cuadrado).

Table 1
Case demography and clinical characteristics CT scan was obtained.

Patient	Case 1	Case 2	Case 3	Case 4	Case 5
Age	28	60	15	19	65
Sex	Female	Female	Female	Female	Female
Underlying disease	Hodgkin's Lymphoma	Follicular Lymphoma	Acute Lymphoblastic Leukaemia	Fanconi Anaemia	Acute Myeloid Leukaemia
Transplant conditioning	Carmustine Cytarabine Etoposide Alemtuzumab Melphalan	Alemtuzumab Fludarabine Melphalan	Cyclophosphamide Alemtuzumab TBI	Fludarabine Melphalan Alemtuzumab	Fludarabine Melphalan Alemtuzumab
CMV serostatus patient/donor	Positive/Positive	Positive/Positive	Negative/Negative	Positive/Negative	Positive/Negative
Date of CMV reactivation	Day +25	Day +22	Day +23	Day +26	Day +74
Maximum viral titre (copies/ml)	55000	26000	69000	15000	1200000
Diagnostic criteria for pneumonia	Bilateral symmetrical ground glass infiltrates with interlobular septal thickening	Diffuse bilateral ground glass opacification with nodular septal thickening	Widespread bronchocentric consolidation with ground glass opacification and peripheral sparing	Diffuse bilateral ground infiltrates with interlobular septal thickening	Diffuse bilateral ground glass infiltrate with peripheral sparing and basal septal thickening
Date of HRCT showing organising pneumonia	Day +57	Day +136	Day +73	Day+108	Day +110
CMV titres changes (copies/ml)	457	Not detected	Not detected	Not detected	1000
Treatment for organising pneumonia, steroids dose reduction	500 mg methylprednisolone × 3 days and reducing dose × 9 months	40 mg/day prednisolone reducing dose × 6 months	500mg of intravenous methylprednisolone × 3 days, followed by a reducing course of oral prednisolone × 3 months. Patient died	40 mg/day prednisolone remaining on low dose (2mg) longterm (2 years)	500mg methylprednisolone × 3 days and a reducing course of oral prednisolone × 12 months

treated with 500 mg of intravenous methylprednisolone for three days followed by a prolonged reducing course of oral prednisolone over nine months, starting at 30 mg/day. Her dyspnoea improved and oxygen saturations increased to 96% on air. Allowing for breathing artefact, a Positron Emission Tomography (PET) CT on day +211 showed marked improvement in the bronchocentric and peripheral consolidation [Fig. 1A(iii)]. The patient's exercise tolerance returned to normal although pulmonary function tests (PFTs) on day +275 showed a persistent reduction in her transfer factor (Table 2).

1.1.2. Patient 2

A 60 year old female non-smoker received a T deplete matched unrelated donor AlloHSCT for relapsed stage 4 follicular lymphoma, complicated by severe mucositis and acute skin graft versus host disease (GvHD). On day +22, PCR indicated systemic reactivation of CMV with a blood viral load of 22000 copies/ml. The patient developed cough and dyspnoea with an oxygen saturation of 88% on air. HRCT on day +26 showed diffuse bilateral ground glass opacification with nodular septal thickening compatible with viral infection [Fig. 1B(i)]. Treatment with ganciclovir resulted in rapid clinical improvement and the serum CMV PCR became negative.

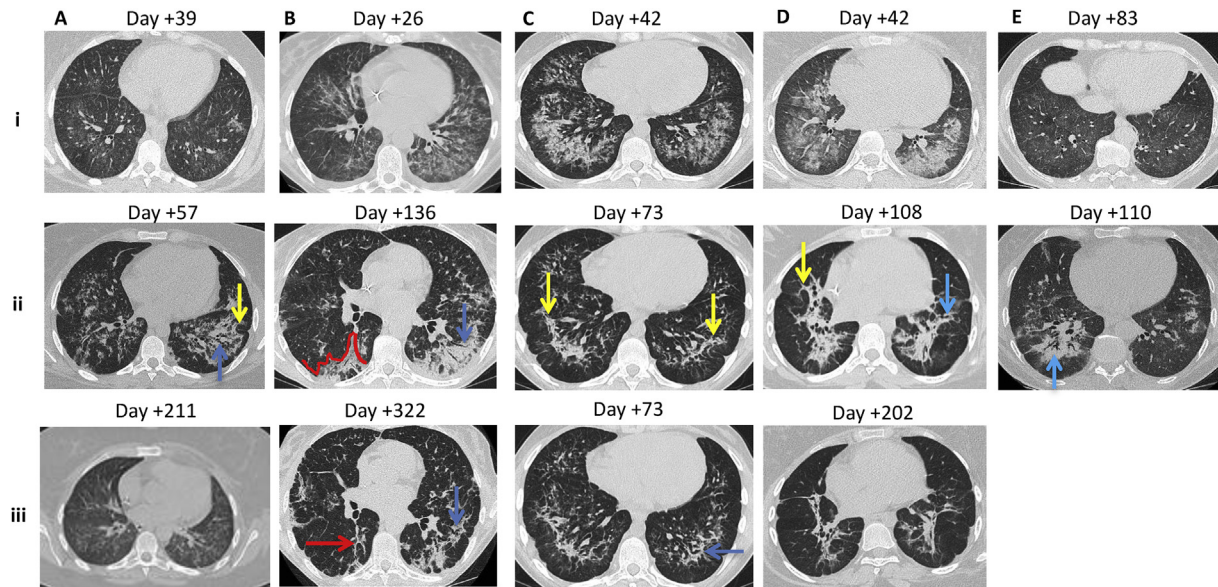
Table 2
Recovery lung function testing data (none available for case 3 as the patient died).

	Case 1	Case 2	Case 4	Case 5
Day tested	+275	+720	+730	+190
FEV ₁ (%predicted)	2.85 (95%)	2.25 (96%)	0.97 (33%)	2.01 (105%)
FVC (%predicted)	3.27 (95%)	2.64 (95%)	1.68 (50%)	2.42 (102%)
TLC (%predicted)	4.91 (103%)	4.53 (89%)	3.27 (74%)	4.64 (102%)
TLCO (% predicted)	4.70 (53%)	3.46 (45%)	3.67 (42%)	4.09 (58%)
KCO (% predicted)	1.29 (69%)	0.90 (60%)	1.75 (89%)	1.51 (75%)

However, CMV reactivation recurred on day +118 and treatment had to be restarted. On day +130, the patient deteriorated with cough, dyspnoea (MRC grade 4), and an oxygen saturation of 89% on air. CMV blood viral load reached 26000 copies/ml on day +134 which represented the peak viral load. HRCT on day +136 demonstrated bilateral central and subpleural consolidation (with some traction bronchiectasis) and peribronchovascular changes in the periphery consistent with an organising pneumonia [Fig. 1B(ii)]. The patient was commenced on a six month reducing course of prednisolone starting at 40 mg/day. Within three weeks her oxygen saturation returned to normal at rest, but she remained dyspnoeic on exertion (MRC grade 2) with a persistent defect in her transfer factor (Table 2). HRCT at day +322 showed residual band-like areas of consolidation, increased architectural distortion, traction bronchiectasis and volume loss consistent with a fibrosing organising pneumonia [Fig. 1B(iii)].

1.1.3. Patient 3

A 15 year old female non-smoker received a T deplete matched unrelated donor AlloHSCT for acute lymphoblastic leukaemia. Although both patient and donor were CMV negative, on day +23 she developed pyrexia and PCR demonstrated CMV viraemia reaching a maximum of 69000 copies/ml by day +35. This was associated with progressive dyspnoea and hypoxia and an oxygen saturation of 88% on air. HRCT on day +42 showed widespread peribronchovascular consolidation with ground glass opacification and peripheral sparing [Fig. 1C(i)] compatible with a CMV pneumonitis. Treatment with intravenous foscarnet and pooled immunoglobulins caused a rapid improvement in her condition and blood CMV PCR became negative by day +60. On day +73, the dyspnoea (MRC grade 3) and hypoxaemia recurred. Repeat HRCT demonstrated dense consolidation forming peribronchovascular bands, associated with pleuro-parenchymal distortion and traction bronchiectasis, consistent with a fibrosing organising pneumonia [Fig. 1C(ii)] &



Aii: traction bronchiectasis (blue arrow), peribulbar consolidation (yellow arrow)
 Bii: central consolidation extending out to the periphery (red line), traction bronchiectasis (blue arrow)
 Biii: band-like consolidation (red arrow), progressive traction bronchiectasis (blue arrow) and architectural distortion
 Cii: peribulbar bands of consolidation with pleuro-parenchymal distortion (yellow arrows)
 Ciii: traction bronchiectasis within the left lower lobe more inferiorly (blue arrow)
 Dii: peribulbar band-like consolidation (yellow arrow) with architectural distortion, traction bronchiectasis (blue arrow)
 Eii: dense peribronchial consolidation with traction bronchiectasis (blue arrow)

Fig. 1. HRCT appearances for cases 1 (A), 2 (B), 3 (C), 4 (D) and 5 (E). The number above each panel refers to how many days after ASCT the HRCT scan was performed.

C(iii)]. BAL was negative for bacteria, fungi and CMV-PCR. Trans-bronchial biopsy showed alveolar damage (likely infectious in origin) with mild interstitial fibrosis, focal fibroblastic reaction and congestion but no visible microorganisms or inclusion bodies. She was treated with 500mg of intravenous methylprednisolone for three days, followed by a reducing course of oral prednisolone starting at 30 mg/day. The dyspnoea improved with oxygen saturations increasing to 96% on air by day +95. The patient died on day +180 due to pulmonary haemorrhage complicating a probable bacterial pneumonia. A post-mortem was not performed.

1.1.4. Patient 4

A 19 year old female non-smoker was treated with a T deplete sibling AlloHSCT for Fanconi Anaemia. On day +26 PCR demonstrated systemic reactivation of CMV with a maximum viral load of 15000 copies/ml by day +39. On day +41 she became dyspnoeic with an oxygen saturation of 90% on air. HRCT on day +42 showed diffuse bilateral ground glass opacification (slightly more dense on the left) with interlobular septal thickening compatible with a CMV pneumonitis [Fig. 1D(i)]. After treatment with intravenous foscarnet the patient clinically improved and CMV viral load became negative by day +59. On day +90 she developed cough and dyspnoea (MRC grade 4). Repeat HRCT on day +108 demonstrated dense bilateral peribronchial consolidation with peribulbar changes in the periphery, traction bronchiectasis and architectural distortion consistent with a fibrosing organising pneumonia [Fig. 1D(ii)]. BAL on day +110 was negative for microorganisms including CMV, and transbronchial biopsy was not diagnostic showing minimal chronic inflammation with no CMV inclusions. The patient was treated with a reducing course of prednisolone starting at 40 mg daily remaining on low dose (2mg) long-term. Although her dyspnoea initially improved, she developed persistent exertional dyspnoea (MRC

grade 3) associated with a severe mixed obstructive/restrictive lung function defect (Table 2). HRCT on day +202 showed further scarring with linear bands, progressive volume loss and architectural distortion [Fig. 1D(iii)].

1.1.5. Patient 5

A 65 year old female non-smoker received a T deplete matched unrelated donor AlloHSCT for acute myeloid leukaemia. On day +74 she developed CMV reactivation with a maximum viral load of 1200000 copies/ml by day +88 and a CRP of 10.8 mg/L. This was associated with progressive dyspnoea and an oxygen saturation of 94% on air. HRCT on day +83 showed a diffuse bilateral ground glass infiltrate with thickening of the interlobular septa compatible with a CMV pneumonitis. [Fig. 1E(i)]. Treatment with intravenous foscarnet and ganciclovir reduced the CMV viral load to 740 copies/ml by day +100 and led to a slow clinical improvement. On day +104 her dyspnoea deteriorated (MRC grade 4), and repeat HRCT on day +110 demonstrated dense peribronchial consolidation with traction bronchiectasis and architectural distortion [Fig. 1E(ii)]. Treatment with three daily doses of 500mg intravenous methylprednisolone and a reducing course of oral prednisolone starting at 30 mg/day resulted in a normal oxygen saturation on air by day +124 and a normal exercise tolerance. Her transfer factor remained mildly reduced (Table 2).

2. Conclusion

We describe five similar cases of a biphasic illness complicating the early period after a T cell deplete AlloHSCT. The initial phase consisted of CMV pneumonitis characterised by clinical evidence of pneumonia, systemic CMV infection, HRCT findings compatible with a viral pneumonitis, and clinical improvement

following anti-CMV treatment. This was then followed by a second phase (57–136 days later) with clinical and radiological features consistent with a distinct form of organising pneumonia. The second phase was characterised by recurrence of severe dyspnoea and hypoxia, with a very different and distinct HRCT pattern comprised of central peribronchial consolidation, traction bronchiectasis and architectural distortion. When available, BAL showed no evidence of active infection. The clinical and radiological features during this phase resembled an atypical pattern of probable organising pneumonia. Diagnostic confirmation would have required a surgical lung biopsy, however this would have exposed the patients to excessive clinical risk. As expected with organising pneumonia, there was a significant clinical improvement following treatment with systemic corticosteroids. However, all surviving patients had evidence of at least some long term clinical, radiological and/or lung function abnormalities indicating chronic lung damage, with the expected restrictive pattern in three patients. The fourth patient had a mixed restrictive/obstructive lung function defect, a less common pattern for organising pneumonia. Unfortunately pre-transplant and pre-treatment for organising pneumonia lung function testing was not performed and therefore not available for comparison. The central peribronchial pattern of organising pneumonia described is an uncommon radiological pattern and the timing in these five cases would suggest a unique response to CMV pneumonitis. However, this is impossible to confirm and similar reactions could occur to other viral lung infections. Whether this complication is limited to allograft recipients remains unknown. It is also striking that all five cases were female, but the significance of this sex bias is unclear. Recognition that CMV pneumonitis can be complicated by a predominantly central

bronchocentric pattern of organising pneumonia will allow early identification of future cases.

Funding

JSB is supported by UCLH Biomedical Research Centre's which receives funding from the Department of Health's NIHR Biomedical Research Centre's scheme.

References

- [1] Jeung Hee Moon, Eun A. Kim, Cytomegalovirus pneumonia: high-resolution CT findings in ten non-AIDS immunocompromised patients, *Korean J. Radiol.* 1 (2) (2000 Apr-Jun) 73–78.
- [2] Tomás Franquet, S. Kyung, Thin-section CT findings in 32 immunocompromised patients with cytomegalovirus pneumonia who do not have AIDS, *Am. J. Roentgenol.* 181 (2003) 1059–1063.
- [3] Fotios Drakopanagiotakis, Koralia Paschalaki, Muhanned Abu-Hijleh, FCCP. Cryptogenic and secondary organizing pneumonia: clinical presentation, radiographic findings, treatment response, and prognosis, *Chest* 139 (4) (2011) 893–900.
- [4] Nakasone H, M. Onizuka, N. Suzuki, Pre-transplant risk factors for cryptogenic organizing pneumonia/bronchiolitis obliterans organizing pneumonia after hematopoietic cell transplantation, *Bone Marrow Transpl.* 48 (10) (2013 Oct) 1317–1323.
- [5] Yanal Alnimer, Samer Salah, Bashar Abuqayas, Kamal Alrabi, Azacitidine-induced cryptogenic organizing pneumonia: a case report and review of the literature, *J. Med. Case Rep.* 10 (2016) 15.
- [6] Ju Won Lee, Kyung Soo Lee, Ho Yun Lee, Cryptogenic organizing pneumonia: serial high-resolution CT findings in 22 patients, *Am. J. Roentgenol.* 195 (2010) 916–922.
- [7] Suparno Chakrabarti, Collingham, et al., Respiratory virus infections in adult T Cell – depleted transplant recipients: the role of cellular immunity, *Transplantation* 72 (2001) 1460–1463.
- [8] J.F. Cordier, Cryptogenetic organising pneumonia, *Eur. Respir. J.* 28 (2) (2006 Aug) 422–446.