

The endoscopist and malignant and non-malignant biliary obstruction

Pereira S P ^{1 2}, Goodchild G ², Webster G J M ²

¹ UCL Institute for Liver and Digestive Health, University College London and ² Department of Gastroenterology, University College London NHS Foundation Trust, London, UK.

*Corresponding author: Professor Stephen Pereira, UCL Institute for Liver and Digestive Health, Royal Free Campus, Pond Street, London, NW3 2PF, UK.

Email: stephen.pereira@ucl.ac.uk

Abstract

Patients with biliary strictures often represent a diagnostic and therapeutic challenge, due to the site and complexity of biliary obstruction and wide differential diagnosis. Multidisciplinary decision making is required to reach an accurate and timely diagnosis and to plan optimal care. Developments in endoscopic ultrasound and peroral cholangioscopy have advanced the diagnostic yield of biliary endoscopy, and novel optical imaging techniques are emerging. Endoscopic approaches to biliary drainage are preferred in most scenarios, and recent advances in therapeutic endoscopic ultrasound allow drainage where the previous alternatives would have only been percutaneous or surgical. Here we review recent advances in endoscopic practice for the diagnosis and management of biliary strictures.

Introduction

The accurate diagnosis of biliary strictures based on imaging alone is frequently challenging, as there is a wide range of benign and malignant aetiologies (Table 1). Due to different management algorithms, these conditions need to be diagnosed swiftly and accurately to guide appropriate therapy and optimise outcomes for patients. Because of the diagnostic difficulties sometimes encountered, definitive treatment such as surgery or chemotherapy may be delayed or given incorrectly, with potential consequences for patients. In one study of 238 patients undergoing surgical resection of suspected cholangiocarcinoma, 13% were found to have benign disease (1). Many of these patients have an autoimmune cholangiopathy (including IgG4-related disease) which can be effectively treated with steroids and other immunosuppressives. Pathologic confirmation of malignancy can also be challenging, and may require endoscopic techniques such as endoscopic ultrasound and single operator cholangioscopy. In those with unresectable malignant biliary obstruction, effective biliary decompression improves symptoms and enables patients to undergo palliative therapies, while in surgical candidates, routine preoperative biliary intervention may worsen outcomes. In this review, we outline latest innovations in endoscopic techniques for the diagnosis of indeterminate biliary strictures and the management of malignant and non-malignant biliary obstruction.

Diagnostics

ERCP with biliary brushings and endoluminal biopsy

Endoscopic retrograde cholangiopancreatography (ERCP) is a well-established technique, typically undertaken after cross-sectional imaging to provide therapy such as biliary stent insertion. It allows high-resolution fluoroscopic images to be obtained during therapeutic procedures, which provide information on stricture site, length and the presence of mucosal irregularity or shouldering (Fig 1). Fluoroscopic stricture imaging is able to distinguish malignant from benign strictures with an accuracy of at best 80%, so that tissue sampling by biliary brushings or endoluminal biopsies is also required (2). Standard ERCP and brush cytology has a variable sensitivity for malignancy of 26-73% (pooled sensitivity of 45% in a recent meta-analysis) (3),

although this may be improved by techniques such as Fluorescence In Situ Hybridisation (FISH) and digital image analysis (4). These techniques allow DNA analysis for chromosomal aneuploidy and nuclear DNA content - both of which are directly related to the risk of malignancy – and enhance tumour detection by up to 23% (5,6). A recent systematic review and meta-analysis (SRMA) of eight studies involving 828 patients demonstrated that the pooled sensitivity and specificity of FISH polysomy to detect cholangiocarcinoma was 51% and 93%, respectively. They concluded that whilst FISH was highly specific, the limited sensitivity highlights the need for better markers in the early detection of cholangiocarcinoma (4).

Novel imaging techniques, such as narrow-band imaging, autofluorescence, confocal laser endomicroscopy and elastic scattering spectroscopy allow augmented views of the visualised mucosa during ERCP (7,8). In cases where IgG4-related disease is suspected, ampullary biopsies may be diagnostically useful. In one study, ampullary biopsies stained positive for IgG4 in 18/27 (67%) symptomatic patients with autoimmune pancreatitis, compared with none from patients without the disease (9).

Additional endoscopic approaches to standard ERCP include endoscopic ultrasonography with fine-needle aspiration, intraductal ultrasound or single operator cholangioscopy systems (Spyglass, Boston Scientific Corp, Natick, Massachusetts, USA), as described below.

Endoscopic ultrasonography

Endoscopic ultrasound and fine needle aspiration (EUS-FNA) allows visualisation and sampling of the pancreas and biliary tree. EUS-FNA is a standard approach for evaluating solid pancreatic masses and is increasingly used in the evaluation of biliary strictures. A recent SRMA involving 957 patients reported a pooled sensitivity and specificity of 80% and 97% for the diagnosis of cholangiocarcinoma by EUS-FNA (10). Disadvantages of biliary EUS-FNA include a small risk of tumour seeding. In one retrospective study, patients undergoing EUS-FNA prior to liver transplantation for perihilar cholangiocarcinoma were more likely to have peritoneal metastases at the time of staging laparotomy (83% vs. 8%), although the number of patients who underwent EUS-FNA was small (n=16) (11). Peritoneal seeding has not

been reported after transduodenal EUS-FNA for distal extrahepatic cholangiocarcinoma, where the EUS-FNA tract is resected during pancreatoduodenectomy. There have also been isolated case reports of peritoneal seeding after EUS-FNA of pancreatic cystic lesions. The PIPE study evaluated the frequency of postoperative peritoneal seeding in patients with malignant and non-malignant intraductal papillary mucinous neoplasm (IPMN) who had undergone preoperative EUS-FNA ($n = 175$) and compared it with that of patients with IPMN who had surgery without preoperative EUS-FNA ($n = 68$). The frequency of postoperative peritoneal seeding was similar in the two groups (2.3% vs. 4.4%; $p = 0.403$) (12).

EUS-FNA can be combined with other techniques such as transient elastography and contrast agents when assessing pancreatic lesions and lymph nodes, which improve the diagnostic accuracy of the technique (13,14)

Intraductal ultrasound

Intraductal ultrasonography (IDUS) provides real-time, cross-sectional imaging of the bile ducts and surrounding structures using a high-frequency ultrasound transducer advanced at the time of ERCP. In a retrospective study of 379 patients with indeterminate biliary strictures undergoing ERCP, IDUS was able to differentiate cholangiocarcinoma from benign strictures with a both a sensitivity and a specificity of 98% (15). In a single centre study of 193 patients, IDUS more accurately diagnosed proximal than distal ductal strictures (98.1 vs 82.7%, $p = 0.006$) (16).

Peroral cholangioscopy

Peroral cholangioscopy with visually targeted biopsies has been reported to have a greater diagnostic accuracy than standard ERCP with non-targeted biopsies (17).

Recent improvements in cholangioscopes have led to a re-emergence of this technology. A single operator cholangioscopy system (Spyglass, Boston Scientific Corp, Natick, Massachusetts, USA) produces a 6000-pixel fibre optic image and enables visually directed intrabiliary biopsies via small disposable forceps. In a multicentre, prospective study of 105 patients, the sensitivity and specificity of the visual impression of malignancy at cholangioscopy was 90% and 96%, respectively.

The sensitivity and specificity of cholangioscopy-guided biopsies for diagnosis of malignancy was 85% and 100%, respectively (18). A subsequent SRMA (10 studies, n=456) reported a pooled sensitivity and specificity of 66% and 98% for the diagnosis of cholangiocarcinoma by cholangioscopic biopsy (19). In the four studies where patients had negative or inconclusive brush cytology or intraductal biopsy prior to cholangioscopy, the pooled sensitivity and specificity for the diagnosis of malignant biliary strictures was 75% and 93%, respectively. Cholangioscopy therefore has a particular role when ERCP alone fails to obtain confirmatory cytology and the diagnosis remains unclear.

Several ultra-slim endoscopes have also been developed for cholangioscopy but have not been fully validated in prospective trials. In comparison to single operator cholangioscopy they are usually placed following standard ERCP, sphincterotomy and guidewire cannulation. Procedure times are therefore longer but compared with single operator cholangioscopy they enable superior image quality and larger biopsy samples of the biliary mucosa (20).

Novel optical techniques

Chromoendoscopy, autofluorescence and narrow-band imaging

Several techniques have been employed to augment the visualised mucosa during cholangioscopy. Biliary narrow-band imaging may assist in delineating tumours and distinguishing benign from malignant surface vascular patterns (8). A prospective study of 21 patients concluded that narrow-band imaging was significantly better than white light at detecting the surface vascular pattern of strictures ($p < 0.05$) (21). Initial cholangioscopic studies with autofluorescence have been less promising; poor specificity and high rates of false positivity were observed (7).

Light scattering spectroscopy

Light scattering spectroscopy (LSS) is a real time *in vivo* optical technique which detects changes in cells, via a probe which is passed through the working channel of an endoscope. It enables a field assessment for malignancy via an “optical biopsy”, a

potential alternative to standard histology. Perelman *et al* developed a spatial gating fibre-optic probe that is able to rapidly take optical biopsies within pancreatic cysts during EUS. In a very recently reported double blind prospective study of 25 patients, this technique was able to accurately distinguish neoplastic, mucinous and serous lesions, thereby identifying the malignant potential in 21 out of 22 cystic lesions, achieving 95% accuracy in the detection of malignancy, compared to 58% accuracy for cytology (22).

Confocal laser endomicroscopy

Confocal laser endomicroscopy (CLE) provides real-time images at the cellular level during ERCP and EUS. A “cholangioflex” confocal probe (Mauna Kea Technologies, Paris, France) can be placed down a 1.2mm working channel of a cholangioscope or the standard channel of a duodenoscope. Following intravenous injection of fluorescein, a low-power laser directs light onto a single point on the biliary mucosa. Light emanating from this point is focused through a pinhole to a detector. This technique produces images which correlate with standard histology and differentiate between malignancy, inflammation and normal mucosa. A recent SRMA found CLE combined with ERCP demonstrated 90% sensitivity in the assessment of biliary strictures (vs 58% for ERCP with biliary brushings plus intraductal biopsies) (23), supporting the American Society for Gastrointestinal Endoscopy guidelines that CLE is a useful tool for differentiating benign from malignant biliary strictures in patients with biliary neoplasia. Small studies have combined CLE with cholangioscopy and shown the diagnostic accuracy of the technique can be improved from 78% to 82% (23,24).

Therapy

Endoscopic biliary decompression in malignant obstruction

Pre-operative stenting

The aims of pre-operative biliary decompression are to improve symptoms and hepatic function prior to definitive surgical resection or neo-adjuvant chemotherapy. The benefits of pre-operative biliary decompression in patients with resectable disease has been debated. In a multicentre trial of 202 patients with pancreatic cancer and obstructive jaundice randomised to either early surgery (<1 week from randomisation) or pre-operative biliary stenting, serious complications were reported in 39% of the early surgery group and 74% in the biliary drainage group ($p < 0.0001$). Overall mortality rates were similar in both groups. The authors concluded that pre-operative biliary drainage is not indicated in patients with a bilirubin $< 250 \mu\text{mol/l}$ (25). Other studies have tried to address the issue of whether deeply jaundiced patients should undergo pre-operative biliary drainage. In this setting biliary drainage has been shown to reduce perioperative and postoperative complications (26). The optimal type of stent remains controversial; one recent RCT found no significant difference between fully-covered self-expanding metal stents (FCSEMS) vs plastic stents (14.2% vs 16.3% re-intervention rate) although the mean interval from randomisation to surgery was only 13 days (27). In those patients with a longer interval to surgery, such as those receiving neo-adjuvant chemotherapy, FCSEMS provide longer patency than plastic stents therefore reducing the need for re-intervention and minimising interruptions to chemotherapy (28).

Palliative stenting

In general, self-expanding metal stents (SEMS) are superior to plastic stents in the palliative setting. Using SEMS for distal extrahepatic or hilar malignant biliary strictures results in significantly longer median patency and lower re-intervention rates when compared to plastic stents (29,30). In a recent meta-analysis of 19 studies involving 1989 patients, SEMS were associated with significantly lower occlusion rates, less therapeutic failure (7% vs 13%), less need for re-intervention and lower rates of cholangitis (8% vs 21%) than plastic stents (31). Whilst the unit cost of one SEMS exceeds that of a plastic stent, several studies looking into the overall cost-effectiveness of SEMS vs plastic stents have concluded that SEMS are more cost effective than plastic stents for patients with a life expectancy over four months (32). In distal malignant biliary obstruction there is a choice between FCSEMS and uncovered SEMS, each with their own advantages and

disadvantages. A recent meta-analysis comparing the two groups found the FCSEMS cohort to have a lower incidence of adverse events (OR: 0.74, 95% CI: 0.57 to 0.97, P = 0.03) with no difference in stent dysfunction, stent patency or patient survival (33).

Stenting of malignant hilar strictures

Intrinsic or extrinsic compression of the biliary tree at the liver hilum can lead to disconnection of the right and left systems. Hilar strictures are classified according to the Bismuth-Corlette classification. To relieve clinical jaundice, it is estimated that at least one third of the liver should be drained. Initial options for drainage include endoscopic, percutaneous or surgical approaches. Several studies have attempted to define optimal stenting practice based on cross sectional imaging in this setting. The majority of patients with malignant hilar strictures have non-resectable disease. In those with a predicted survival of greater than four months, uncovered SEMS are superior to plastic stents for palliation with respect to outcome and cost-effectiveness (34). Adequate biliary drainage can generally be achieved with unilateral, bilateral side-by-side or bilateral stent-in-stent approaches, with evidence currently lacking as to which of these approaches is optimal (Fig 2) (34). In patients with potentially resectable hilar cholangiocarcinoma, several RCTs and meta-analyses have evaluated the utility of pre-operative biliary drainage in this group (35), the results showing significantly higher post-operative morbidity in the drained vs undrained groups (OR 1.67: 95% CI), therefore routine pre-operative stenting in hilar cholangiocarcinoma is not recommended (34).

Endoscopic biliary decompression in benign obstruction

Important aetiologies of benign biliary strictures include post-surgical bile duct injury, chronic pancreatitis, primary sclerosing cholangitis (PSC) and IgG4-related disease. Of these, post-cholecystectomy bile duct injury (0.5% incidence) and post-liver transplant anastomotic strictures (10-40% incidence) are the most common aetiologies (36,37). The treatment goals in managing benign biliary strictures are to relieve obstruction, maintain ductal patency and restore liver function. Data suggests that endoscopic therapy for benign biliary strictures is safe, effective and less

invasive than surgical approaches (38), so that it is the first line therapeutic option in most patients with an accessible papilla (39).

Standard therapeutic approaches to benign strictures includes balloon dilation, insertion of multiple plastic stents with stent change each 3-4 months (up to 12 months) or remodelling the stricture through FCSEMS placement for 3-6 months. The last of these options has been shown to be safe, effective, technically straightforward and associated with fewer procedures (39). In a recent international prospective study of 177 patients with benign biliary strictures who underwent temporary FCSEMS placement, all stents were successfully removed without complication and stricture resolution was achieved in 76.3% of patients (40).

Biliary stricture dilatation can be performed with either a balloon or bougie, although early dilatation of post-surgical strictures (<4 weeks) may be associated with bile leak (41). Balloon dilatation alone without subsequent stenting is associated with a high rate of stricture recurrence in anastomotic strictures and chronic pancreatitis (41). The exception is dominant strictures in PSC where repeated balloon dilatations without stent placement is associated with improved long-term outcomes (42). Gotthardt *et al* prospectively studied 101 PSC patients with dominant strictures treated with either balloon dilatation or stenting. Long term follow-up showed excellent rates of bile duct patency with 5-year transplant-free and 10-year transplant-free survival rates of 81% and 52%, respectively (42). For patients with IgG4-related biliary strictures stenting is not recommended unless there is severe jaundice or cholangitis, in which case a stent may bridge the patient until steroid response (43).

Placement of uncovered SEMS in benign biliary strictures or indeterminate strictures is usually contraindicated due to the likelihood of tissue ingrowth and subsequent stent embedment (39).

Alternative biliary drainage options if ERCP fails

Percutaneous transhepatic drainage (PTD)

Endoscopic drainage, particularly of hilar strictures, can be challenging and PTD with stent placement provides an alternative method of biliary decompression. PTD is used for both hilar cholangiocarcinoma where it allows for selective duct drainage and in cases of failed endoscopic access due to gastric outlet obstruction, duodenal indwelling stents, or surgically altered anatomy such as Roux-en-Y hepaticojejunostomy (44).

Endoscopic ultrasound-guided biliary drainage

When ERCP fails, endoscopic ultrasound-guided biliary puncture from the duodenum or stomach is an alternative approach with outcomes similar to percutaneous drainage. Passage of a guidewire through the tract enables standard cannulation and stent placement via a 'rendezvous' technique, or alternatively a stent can be placed across the tract to allow bile to drain directly into the duodenum or stomach. EUS-guided biliary drainage (EUS-BD) is a novel technique for patients who have failed endoscopic biliary stenting and may be considered as an alternative to PTD. In expert hands, success rates have been shown to be above 90% with rates of adverse events 17% (45). A recent SRMA (9 studies, 483 patients) compared EUS-BD with PTD. They concluded that whilst there was no difference in technical success, EUS-BD was associated with higher rates of clinical success, less adverse events and lower rates of re-intervention. EUS-BD was also more cost effective (46).

Surgical bypass

Historically biliary decompression has been achieved through surgical biliary bypass procedures. A recent meta-analysis reported less recurrent biliary obstruction after surgical bypass when compared with endoscopic biliary stenting in the management of malignant biliary obstruction. Technical success rates and complication rates were also similar (47). Surgical bypass is only suitable for surgically fit candidates, limiting its use in advanced cancer.

Novel endoscopic approaches to therapy

Patients with inoperable cholangiocarcinoma and pancreatic cancer have an extremely poor prognosis. Meta-analyses have not shown significant improvement with standard chemoradiation regimens (48), likely due to an advanced tumour stage at presentation coupled with aggressive tumour biology. However, two novel endoscopic interventions have shown promise in early studies: Photodynamic therapy (PDT) and radiofrequency ablation (RFA).

Photodynamic therapy

Photodynamic therapy (PDT) is an ablative technique involving intravenous administration of a photosensitising agent followed by endoscopic intraluminal laser irradiation. The agent concentrates within the tumour cells and once activated by the light of the laser generates reactive oxygen species. These cause photodamage of intracellular structures and cell membranes leading to tumour cell apoptosis and necrosis. A previous randomised controlled trial of PDT when compared to biliary stenting alone showed a significant increase in survival time from 98 d to 493 d (49), with another RCT showing median survival increasing from 210 to 630 d (50). Retrospective data also contributes to the body of information supporting increased survival and quality of life when PDT is used in addition to biliary stents as well as chemotherapy (51,52). The high cost of PDT may be a factor preventing its widespread use for local control of unresectable cholangiocarcinoma.

Radiofrequency ablation

Endoscopic Radiofrequency Ablation (RFA) is a palliative locoregional treatment that can be used in malignant biliary obstruction either as a first line treatment to improve the bile duct diameter or to treat tumour ingrowth of uncovered stents (53). A catheter inserted into the biliary tree delivers a therapeutic heating zone leading to coagulation necrosis of the tumour. After treatment, a stent is usually placed. Evidence for the use of endoscopic RFA is restricted to retrospective analyses and small prospective cohort studies (54). A recent retrospective comparison of PDT vs RFA in the palliation of malignant biliary strictures compared

results in 48 patients (16 RFA, 32 PDT) demonstrating similar median survival (9.6 mo in RFA, 7.5 mo in PDT) (55).

Conclusion

The re-emergence of peroral cholangioscopy alongside several other novel diagnostic techniques has led to improvements in the diagnostic accuracy of endoscopic assessment of indeterminate biliary strictures. Further evaluation of these new techniques will define their place in diagnostic and management algorithms for patients with biliary strictures. Improvements in the range of biliary access techniques, endobiliary stents and novel ablative treatments along with local therapies have led to significant improvements in the palliation of pancreaticobiliary malignancy.

Abbreviations:

CC	Cholangiocarcinoma
CLE	Confocal Laser Endomicroscopy
ERCP	Endoscopic Retrograde Cholangiopancreatography
EUS-FNA	Endoscopic Ultrasound-Fine Needle Aspiration
FCSEMS	Fully-covered Self-expanding Metal Stent
FISH	Fluorescence <i>in situ</i> Hybridisation
IDUS	Intraductal Ultrasound
PDT	Photodynamic Therapy
PTD	Percutaneous Transhepatic Drainage
RFA	Radiofrequency Ablation
SEMS	Self-expanding Metal Stent
SRMA	Systematic Review and Meta-Analysis

Disclosures

The authors declare that they have no disclosures.

Acknowledgements

SPP is supported in part by NIH grant P01CA8420 and the National Institute for Health Research (NIHR) University College London Hospitals Biomedical Research Centre.

TABLES AND FIGURES

Table 1. Differential diagnosis of indeterminate biliary stricture.

Prognosis	Condition
Benign	Post-operative (following laparoscopic cholecystectomy or biliary anastomosis) Chronic pancreatitis Primary sclerosing cholangitis Autoimmune cholangiopathy, IgG4 sclerosing-cholangitis Post-radiotherapy Infections (TB, histoplasmosis, viral, parasitic, HIV cholangiopathy) Choledocholithiasis / Mirrizzi syndrome Vasculitis Trauma Ischaemia Post biliary sphincterotomy Extraluminal compression (lymph nodes, vascular)
Malignant	Cholangiocarcinoma Pancreatic cancer Metastatic disease

Figure 1. Endoscopic evaluation and treatment of an extra-hepatic biliary stricture due to a pancreatic mass lesion: A. Fluoroscopic view of distal common bile duct stricture with double-duct sign; B. Fluoroscopic view of fully-covered self-expanding metal biliary stent. C. Endoscopic view of biliary stent.

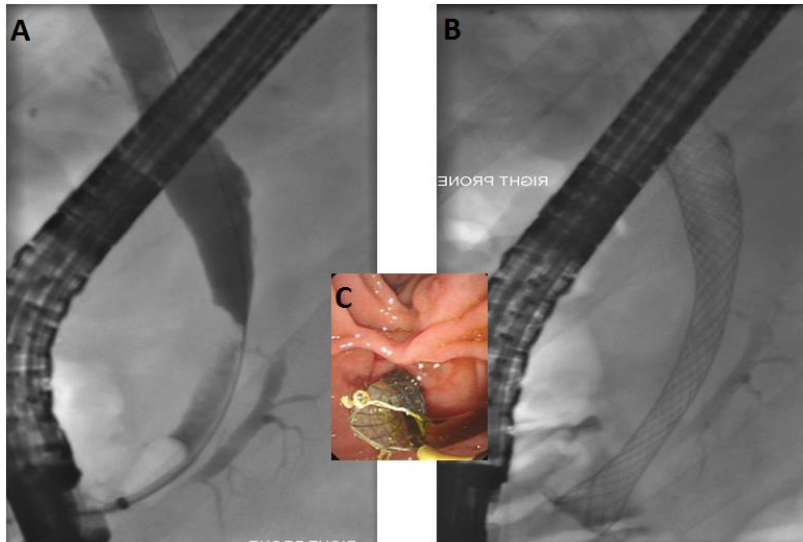
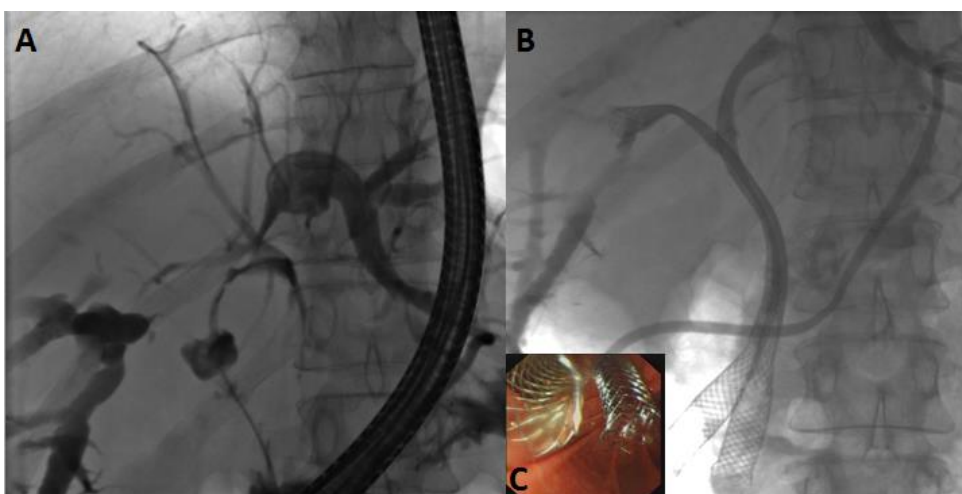


Figure 2. Endoscopic assessment and treatment of a malignant hilar stricture: A. Fluoroscopic view of malignant hilar stricture; B. Fluoroscopic image after insertion of bilateral uncovered metal biliary stents; C. Endoscopic view of the biliary stents.



References:

1. Scheuermann U, Widyaningsih R, Hoppe-Lotichius M, Heise M, Otto G. Detection of benign hilar bile duct stenoses – A retrospective analysis in 250 patients with suspicion of Klatskin tumour. *Ann Med Surg.* 2016 Jun;8:43–9.
2. Yoon WJ, Brugge WR. Endoscopic evaluation of bile duct strictures. *Gastrointest Endosc Clin N Am.* 2013 Apr;23(2):277–93.
3. Navaneethan U, Njei B, Lourdasamy V, Konjeti R, Vargo JJ, Parsi MA. Comparative effectiveness of biliary brush cytology and intraductal biopsy for detection of malignant biliary strictures: a systematic review and meta-analysis. *Gastrointest Endosc.* 2015 Jan;81(1):168–76.
4. Navaneethan U, Njei B, Venkatesh PGK, Vargo JJ, Parsi MA. Fluorescence in situ hybridization for diagnosis of cholangiocarcinoma in primary sclerosing cholangitis: a systematic review and meta-analysis. *Gastrointest Endosc.* 2014 Jun;79(6):943–950.e3.
5. Barr Fritcher EG, Voss JS, Brankley SM, Campion MB, Jenkins SM, Keeney ME, et al. An Optimized Set of Fluorescence In Situ Hybridization Probes for Detection of Pancreatobiliary Tract Cancer in Cytology Brush Samples. *Gastroenterology.* 2015 Dec;149(7):1813–1824.e1.
6. Kipp BR, Stadheim LM, Halling SA, Pochron NL, Harmsen S, Nagorney DM, et al. A Comparison of Routine Cytology and Fluorescence in situ Hybridization for the Detection of Malignant Bile Duct Strictures. *Am J Gastroenterol.* 2004 Sep;99(9):1675–81.
7. Ishida Y, Itoi T, Okabe Y. Can image-enhanced cholangioscopy distinguish benign from malignant lesions in the biliary duct? *Best Pract Res Clin Gastroenterol.* 2015 Aug;29(4):611–25.
8. Choi HJ, Moon JH, Lee YN. Advanced Imaging Technology in Biliary Tract Diseases:Narrow-Band Imaging of the Bile Duct. *Clin Endosc.* 2015 Nov 30;48(6):498–502.
9. Kubota K, Kato S, Akiyama T, Yoneda M, Fujita K, Ogawa M, et al. Differentiating sclerosing cholangitis caused by autoimmune pancreatitis and primary sclerosing cholangitis according to endoscopic duodenal papillary

- features. *Gastrointest Endosc.* 2008;68(6):1204–8.
10. Sadeghi A, Mohamadnejad M, Islami F, Keshtkar A, Biglari M, Malekzadeh R, et al. Diagnostic yield of EUS-guided FNA for malignant biliary stricture: a systematic review and meta-analysis. *Gastrointest Endosc.* 2016 Feb;83(2):290–298.e1.
 11. Heimbach JK, Sanchez W, Rosen CB, Gores GJ. Trans-peritoneal fine needle aspiration biopsy of hilar cholangiocarcinoma is associated with disease dissemination. *HPB (Oxford).* 2011 May;13(5):356–60.
 12. Yoon W, S. Daglilar E, Castillo C, Mino-Kenudson M, Pitman M, Brugge W. Peritoneal seeding in intraductal papillary mucinous neoplasm of the pancreas patients who underwent endoscopic ultrasound-guided fine-needle aspiration: The PIPE Study. *Endoscopy.* 2014 Mar;46(5):382–7.
 13. Choi J-H, Seo D-W. Applications of contrast-enhanced harmonic endoscopic ultrasound on biliary, focal liver lesions and vascular diseases. *Endosc Ultrasound.* 6(1):21–4.
 14. Seicean A, Mosteanu O, Seicean R. Maximizing the endosonography: The role of contrast harmonics, elastography and confocal endomicroscopy. *World J Gastroenterol.* 2017;23(1):25.
 15. Meister T. Intraductal ultrasound substantiates diagnostics of bile duct strictures of uncertain etiology. *World J Gastroenterol.* 2013;19(6):874.
 16. Chen L, Lu Y, Wu J-C, Bie L, Xia L, Gong B. Diagnostic Utility of Endoscopic Retrograde Cholangiography/Intraductal Ultrasound (ERC/IDUS) in Distinguishing Malignant from Benign Bile Duct Obstruction. *Dig Dis Sci.* 2016 Feb;61(2):610–7.
 17. Ramchandani M, Reddy DN, Gupta R, Lakhtakia S, Tandan M, Darisetty S, et al. Role of single-operator peroral cholangioscopy in the diagnosis of indeterminate biliary lesions: a single-center, prospective study. *Gastrointest Endosc.* 2011 Sep;74(3):511–9.
 18. Navaneethan U, Hasan MK, Kommaraju K, Zhu X, Hebert-Magee S, Hawes RH, et al. Digital, single-operator cholangiopancreatography in the diagnosis and management of pancreatobiliary disorders: a multicenter clinical

- experience (with video). *Gastrointest Endosc.* 2016 Oct;84(4):649–55.
19. Navaneethan U, Hasan MK, Lourdasamy V, Njei B, Varadarajulu S, Hawes RH. Single-operator cholangioscopy and targeted biopsies in the diagnosis of indeterminate biliary strictures: a systematic review. *Gastrointest Endosc.* 2015 Oct;82(4):608–614.e2.
 20. Sethi A, Doukides T, Sejal D V, Pleskow DK, Slivka A, Adler DG, et al. Interobserver agreement for single operator choledochoscopy imaging: can we do better? *Diagn Ther Endosc.* 2014;2014:730731.
 21. Itoi T, Sofuni A, Itokawa F, Tsuchiya T, Kurihara T, Ishii K, et al. Peroral cholangioscopic diagnosis of biliary-tract diseases by using narrow-band imaging (with videos). *Gastrointest Endosc.* 2007 Oct;66(4):730–6.
 22. Zhang L, Pleskow DK, Turzhitsky V, Yee EU, Berzin TM, Sawhney M, et al. Light scattering spectroscopy identifies the malignant potential of pancreatic cysts during endoscopy. *Nat Biomed Eng.* 2017 Mar;1(4):40.
 23. Fugazza A, Gaiani F, Carra MC, Brunetti F, Lévy M, Sobhani I, et al. Confocal Laser Endomicroscopy in Gastrointestinal and Pancreatobiliary Diseases: A Systematic Review and Meta-Analysis. *Biomed Res Int.* 2016;2016:1–31.
 24. Shieh FK, Drumm H, Nathanson MH, Jamidar PA. High-definition Confocal Endomicroscopy of the Common Bile Duct. *J Clin Gastroenterol.* 2012;46(5):401–6.
 25. van der Gaag N a, Rauws EAJ, van Eijck CHJ, Bruno MJ, van der Harst E, Kubben FJGM, et al. Preoperative biliary drainage for cancer of the head of the pancreas. *N Engl J Med.* 2010;362(2):129–37.
 26. Bonin EA, Baron TH. Preoperative biliary stents in pancreatic cancer. *J Hepatobiliary Pancreat Sci.* 2011 Sep;18(5):621–9. Available from: <http://doi.wiley.com/10.1007/s00534-011-0403-8>
 27. Song TJ, Lee JH, Lee SS, Jang JW, Kim JW, Ok TJ, et al. Metal versus plastic stents for drainage of malignant biliary obstruction before primary surgical resection. *Gastrointest Endosc.* 2016 Nov;84(5):814–21.
 28. Van Heek NT, Busch OR, Van Gulik TM, Gouma DJ. Preoperative biliary drainage for pancreatic cancer. *Minerva Med.* 2014 Apr;105(2):99–107.

29. Davids P, Groen A, Rauws E, Tytgat G, Huibregtse K. Randomised trial of self-expanding metal stents versus polyethylene stents for distal malignant biliary obstruction. *Lancet*. 1992;340(8834–8835):1488–92.
30. Mukai T, Yasuda I, Makashima M, Doi S, Iwashita T, Iwata K, et al. Metallic stents are more efficacious than plastic stents in unresectable malignant hilar biliary strictures: a randomized controlled trial. *J Hepatobiliary Pancreat Sci*. 2013;20:214–22.
31. Sawas T, Al Halabi S, Parsi MA, Vargo JJ. Self-expandable metal stents versus plastic stents for malignant biliary obstruction: a meta-analysis. *Gastrointest Endosc*. 2015 Aug;82(2):256–267.e7.
32. Martinez JM, Anene A, Bentley TGK, Cangelosi MJ, Meckley LM, Ortendahl JD, et al. Cost Effectiveness of Metal Stents in Relieving Obstructive Jaundice in Patients with Pancreatic Cancer. *J Gastrointest Cancer*. 2017 Mar 27;48(1):58–65.
33. Chen M-Y, Lin J-W, Zhu H-P, Zhang B, Jiang G-Y, Yan P-J, et al. Covered Stents versus Uncovered Stents for Unresectable Malignant Biliary Strictures: A Meta-Analysis. *Biomed Res Int*. 2016;2016:1–8.
34. Rerknimitr R, Angsuwatcharakon P, Ratanachu-ek T, Khor CJL, Ponnudurai R, Moon JH, et al. Asia-Pacific consensus recommendations for endoscopic and interventional management of hilar cholangiocarcinoma. *J Gastroenterol Hepatol*. 2013 Apr;28(4):593–607.
35. Liu F, Li Y, Wei Y, Li B. Preoperative Biliary Drainage Before Resection for Hilar Cholangiocarcinoma: Whether or Not? A Systematic Review. *Dig Dis Sci*. 2011 Mar 16;56(3):663–72.
36. Hildebrand T, Pannicke N, Dechene A, Gotthardt DN, Kirchner G, Reiter FP, et al. Biliary strictures and recurrence after liver transplantation for primary sclerosing cholangitis: A retrospective multicenter analysis. *Liver Transpl*. 2016 Jan;22(1):42–52.
37. Chan CHY, Donnellan F, Byrne MF, Coss A, Haque M, Wiesinger H, et al. Response to endoscopic therapy for biliary anastomotic strictures in deceased versus living donor liver transplantation. *Hepatobiliary Pancreat Dis Int*. 2013

- Oct;12(5):488–93.
38. Kuroda Y, Tsuyuguchi T, Sakai Y, K C S, Ishihara T, Yamaguchi T, et al. Long-term follow-up evaluation for more than 10 years after endoscopic treatment for postoperative bile duct strictures. *Surg Endosc.* 2010 Apr;24(4):834–40.
 39. Hu B, Sun B, Cai Q, Wong Lau JY, Ma S, Itoi T, et al. Asia-Pacific consensus guidelines for endoscopic management of benign biliary strictures. *Gastrointest Endosc.* 2017 Jul;86(1):44-58.
 40. Devière J, Nageshwar Reddy D, Püspök A, Ponchon T, Bruno MJ, Bourke MJ, et al. Successful management of benign biliary strictures with fully covered self-expanding metal stents. *Gastroenterology.* 2014 Aug;147(2):385–95; quiz e15.
 41. Zoepf T, Maldonado-Lopez EJ, Hilgard P, Malago M, Broelsch CE, Treichel U, et al. Balloon dilatation vs. balloon dilatation plus bile duct endoprotheses for treatment of anastomotic biliary strictures after liver transplantation. *Liver Transplant.* 2006 Jan;12(1):88–94.
 42. Gotthardt DN, Rudolph G, Klöters-Plachky P, Kulaksiz H, Stiehl A. Endoscopic dilation of dominant stenoses in primary sclerosing cholangitis: outcome after long-term treatment. *Gastrointest Endosc.* 2010 Mar;71(3):527–34.
 43. Zen Y, Kawakami H, Kim JH. IgG4-related sclerosing cholangitis: all we need to know. *J Gastroenterol.* 2016 Apr 27;51(4):295–312.
 44. Gwon D II, Ko G-Y, Ko HK, Yoon H-K, Sung K-B. Percutaneous Transhepatic Treatment Using Retrievable Covered Stents in Patients with Benign Biliary Strictures: Mid-term Outcomes in 68 Patients. *Dig Dis Sci.* 2013 Nov 17;58(11):3270–9.
 45. Khan MA, Akbar A, Baron TH, Khan S, Kocak M, Alastal Y, et al. Endoscopic Ultrasound-Guided Biliary Drainage: A Systematic Review and Meta-Analysis. *Dig Dis Sci.* 2016 Mar;61(3):684–703.
 46. Sharaiha RZ, Khan MA, Kamal F, Tyberg A, Tombazzi CR, Ali B, et al. Efficacy and safety of EUS-guided biliary drainage in comparison with percutaneous biliary drainage when ERCP fails: a systematic review and meta-analysis. *Gastrointest Endosc.* 2017 May;85(5):904–14.

47. Glazer ES, Hornbrook MC, Krouse RS. A meta-analysis of randomized trials: immediate stent placement vs. surgical bypass in the palliative management of malignant biliary obstruction. *J Pain Symptom Manage*. 2014 Feb;47(2):307–14.
48. Horgan AM, Amir E, Walter T, Knox JJ. Adjuvant therapy in the treatment of biliary tract cancer: a systematic review and meta-analysis. *J Clin Oncol*. 2012 Jun;30(16):1934–40.
49. Ortner MEJ, Caca K, Berr F, Liebetrueth J, Mansmann U, Huster D, et al. Successful photodynamic therapy for nonresectable cholangiocarcinoma: a randomized prospective study. *Gastroenterology*. 2003 Nov;125(5):1355–63.
50. Zoepf T, Jakobs R, Arnold JC, Apel D, Riemann JF. Palliation of nonresectable bile duct cancer: improved survival after photodynamic therapy. *Am J Gastroenterol*. 2005 Nov;100(11):2426–30.
51. Park DH, Lee SS, Park SE, Lee JL, Choi JH, Choi HJ, et al. Randomised phase II trial of photodynamic therapy plus oral fluoropyrimidine, S-1, versus photodynamic therapy alone for unresectable hilar cholangiocarcinoma. *Eur J Cancer*. 2014 May;50(7):1259–68.
52. Hong MJ, Cheon YK, Lee EJ, Lee TY, Shim CS. Long-term outcome of photodynamic therapy with systemic chemotherapy compared to photodynamic therapy alone in patients with advanced hilar cholangiocarcinoma. *Gut Liver*. 2014 May;8(3):318–23.
53. Pai M, Valek V, Tomas A, Doros A, Quaretti P, Golfieri R, et al. Percutaneous intraductal radiofrequency ablation for clearance of occluded metal stent in malignant biliary obstruction: feasibility and early results. *Cardiovasc Intervent Radiol*. 2014 Feb;37(1):235–40.
54. Dolak W, Schreiber F, Schwaighofer H, Gschwantler M, Plieschnegger W, Ziachehabi A, et al. Endoscopic radiofrequency ablation for malignant biliary obstruction: a nationwide retrospective study of 84 consecutive applications. *Surg Endosc*. 2014 Mar;28(3):854–60.
55. Strand DS, Cosgrove ND, Patrie JT, Cox DG, Bauer TW, Adams RB, et al. ERCP-directed radiofrequency ablation and photodynamic therapy are

associated with comparable survival in the treatment of unresectable cholangiocarcinoma. *Gastrointest Endosc.* 2014 Nov;80(5):794–804.