

Supratentorial lesions contribute to trigeminal neuralgia in multiple sclerosis

Kilian Fröhlich,^{1*} Klemens Winder,^{1*} Ralf A. Linker,¹ Tobias Engelhorn,² Arnd Dörfler,² De-Hyung Lee,¹ Max J. Hilz,^{1,3} Stefan Schwab,¹ and Frank Seifert¹

1 Department of Neurology, University Hospital Erlangen, Friedrich-Alexander-University Erlangen-Nürnberg, Germany

2 Department of Neuroradiology, University Hospital Erlangen, Friedrich-Alexander-University Erlangen-Nürnberg, Germany

3 Autonomic Unit, University College London, Institute of Neurology and National Hospital for Neurology and Neurosurgery, Queen Square, London, UK

***Equal contribution**

Running head: multiple sclerosis and headache

Number of characters in the title:	79
Number of characters in the running head:	31
Number of words in the abstract:	199
Number of words in the body of the manuscript without references:	3361
Number of color figures:	4
Number of tables:	2

Corresponding author:

Dr. med. Kilian Fröhlich

Department of Neurology

University Hospital Erlangen

Friedrich-Alexander-University Erlangen-Nürnberg (FAU)

Schwabachanlage 6

91054 Erlangen, Germany

Phone: +49-9131-8544520

Fax: +49-9131-8534846

E-mail: kilian.froehlich@uk-erlangen.de

Abstract

Background: It has been proposed that multiple sclerosis lesions afflicting the pontine trigeminal afferents contribute to trigeminal neuralgia in multiple sclerosis. So far, there are no imaging studies that evaluated interactions between supratentorial lesions and trigeminal neuralgia in multiple sclerosis patients.

Methods: We conducted a retrospective study and sought for multiple sclerosis patients with trigeminal neuralgia and controls in a local database. Multiple sclerosis lesions manually outlined and transformed into stereotaxic space. We determined the lesion overlap and performed a voxel-wise subtraction analysis. Second, we conducted a voxel-wise non-parametric analysis using the Lieberman test.

Results: From 12210 multiple sclerosis patient records screened, we identified 41 patients with trigeminal neuralgia. The voxel-wise subtraction analysis yielded associations between trigeminal neuralgia and multiple sclerosis lesions in the pontine trigeminal afferents, as well as larger supratentorial lesion clusters in the contralateral insula and hippocampus. The non-parametric statistical analysis using the Lieberman test yielded similar areas to be associated with multiple sclerosis-related trigeminal neuralgia.

Conclusions: Our study confirms previous data on associations between multiple sclerosis-related trigeminal neuralgia and pontine lesions, and showed for the first time an association with lesions in the insular region, a region involved in pain processing and endogenous pain modulation.

Key Words: voxel-based lesion symptom mapping, multiple sclerosis, trigeminal neuralgia, facial pain

Abbreviations:

VLSM = voxel-based lesion symptom mapping

TN = trigeminal neuralgia

MNI = Montreal Neurological Institute

FWE = family-wise error

EDSS = Expanded Disability Status Scale

Introduction

Trigeminal neuralgia (TN) affects 1-6.3% of patients with multiple sclerosis.¹ Compared to the general population, multiple sclerosis patients have a highly increased about 20-fold risk of developing TN.² According to the International Classification of Headache Disorders of the International Headache Society (IHS),³ TN can be distinguished in a classic form most often caused by a neurovascular contact and a symptomatic form like multiple sclerosis-related TN.³

The multiple sclerosis pathology has a predilection for the optic nerves and in the brain for the periventricular white matter including the callosal radiation and juxtacortical U-fibers. Multiple sclerosis lesions are also found in the brainstem and spinal cord.^{4,5} Because TN is far more frequent in multiple sclerosis patients than in the general population, TN might be associated with the multiple sclerosis-related pathology or specific multiple sclerosis lesion locations in the brain.^{2, 6-9} Yet, the relationship between TN in multiple sclerosis patients and multiple sclerosis-associated lesion sites is discussed controversially.^{2, 6-10} A few studies showed that multiple sclerosis lesions in brain stem areas are not associated with sensory trigeminal symptoms including paresthesia and pain.¹⁰ In contrast, other studies linked facial sensory symptoms or symptomatic TN in multiple sclerosis patients to inflammatory lesions of the brainstem.^{2, 6-9} However, these previous studies had the a priori hypothesis that multiple lesions in the brainstem are the primary cause of multiple sclerosis-related TN.^{2, 6-10} Lesion sites in other brain areas than the brainstem that contribute to integrating pain perception were not assessed in these studies.^{6, 9, 11}

We hypothesize that multiple sclerosis lesions in other brain areas than the brainstem that are involved in pain processing may contribute to the genesis of multiple sclerosis-related TN. Therefore, we performed a retrospective analysis of collected clinical data of multiple sclerosis patients with multiple sclerosis-related TN and compared their clinical data and lesion pattern to a matched sample of multiple sclerosis patients without TN. To determine associations between occurrence of multiple sclerosis-related TN and multiple sclerosis lesion location, we applied a voxel-based lesion symptom mapping (VLSM) analysis.¹²⁻¹⁶

Materials and Methods

Patients

This study was a retrospective analysis of multiple sclerosis patients seen between 2002 and 2015 by qualified neurologists at the Department of Neurology of the University Hospital Erlangen of the Friedrich-Alexander-University Erlangen-Nürnberg (Erlangen, Germany). Medical reports obtained after medical visits of multiple sclerosis patients are stored in a computerized database. All patients gave written informed consent to the use of their data. In this database, we performed a search for patients with multiple sclerosis and documented persistent or a past episode of TN by using the key words "multiple sclerosis" and "trigeminal neuralgia". We studied patients of the database who fulfilled the following inclusion criteria: 1) patients with relapsing-remitting, secondary progressive or primary progressive multiple sclerosis; 2) aged 18 to 75 years, and 3) available medical reports containing details of the medical history with particular emphasis on physical examination, disease course, disease duration and first manifestation of TN. Because in some patients pain paroxysms cross the midline and patients experience bilateral pain, definition of lateralization was applied to the dominant side of pain. We excluded patients with the following conditions: 1) imaging or MRI sequences not available or poor imaging quality, 2) structural cerebral diseases other than multiple sclerosis, 3) evidence of chronic or persistent facial pain. Additionally, we decided in favor of an exclusion of 4) patients with TN and an evident vascular contact of the trigeminal nerve to avoid a possible bias and interference in our results. Vascular contact was defined as a neurovascular contact in general, irrespective of morphological changes.

For diagnosis of TN, we applied the current guidelines of the International Headache Society (IHS) at the time of the visit.³ This guideline defines TN as sudden, usually unilateral, severe, brief, stabbing and recurrent episodes of pain in the distribution of branches of the trigeminal nerve.³

Diagnosis of relapsing–remitting multiple sclerosis was defined according to the current version of the McDonald criteria.¹⁷ The degree of physical disability was determined using the Expanded Disability Status Scale (EDSS) score.¹⁸

To compare the imaging characteristics of patients with and without multiple sclerosis-related TN, we established a control group of multiple sclerosis patients of the database without documented TN. We matched the control patients for gender, age, and EDSS score (variability of 1 year in age or 0.5 points in EDSS score was tolerated, if no exact match was available). Apart these criteria, patients of the control group were randomly selected.

MRI examination

All patients underwent 1.5 or 3 Tesla (T) MRI of the brain. MRI scans included axial T1-weighted and axial T2-weighted sequences with a slice thickness of 5 mm for detection of infratentorial multiple sclerosis- lesion load. Axial or 3D fluid-attenuated inversion recovery (FLAIR) sequences were obtained for detecting cortically located multiple sclerosis lesions or multiple sclerosis lesion afflicting the callosal radiation.^{14, 15} In addition, 3D constructive interference in steady state images or axial T2-weighted sequences were performed in patients with multiple sclerosis-related TN to screen for a vascular compression of the trigeminal nerve.⁹

Lesion mapping

Two experienced raters (K.F. and K.W) assessed the multiple sclerosis lesions on anonymized T2-weighted MRI sequences, the lesion boundaries were checked by a blinded third investigator (F.S.). Multiple sclerosis lesions were manually delineated on imaging scans using MRICron software.^{13, 19} Lesion location was controlled for consistency on axial or 3D FLAIR scans, but delineated only on axial T2-weighted MRI scans. To ensure that no perivascular spaces were scored as multiple sclerosis lesions, lesions were only delineated if they were detectable on T2-weighted as well as on FLAIR scans as a hyperintense lesion. The MRI scan and the lesion shape were transferred into stereotaxic space using the normalization algorithm of SPM8 and the Clinical Toolbox for SPM8.²⁰⁻²² Because TN is a lateralized pain disorder, multiple sclerosis lesions of patients with clinically left-sided trigeminal neuralgia were flipped by the mid-sagittal plane.^{23, 24}

Thus, using the MR-segment-normalize algorithm of the Clinical Toolbox, the MR images were transformed to the T1 template with resampled voxel size of 1 x 1 x 1 mm³.²⁰

Statistical analysis

As a first step, we performed a subtraction analysis where the lesion overlap of multiple sclerosis patients without TN was subtracted from the lesion overlap of patients with multiple sclerosis-related TN.^{23, 24} As a second analysis, dichotomous overlap values of multiple sclerosis lesion sites identified in the VLSM analysis were correlated with the dichotomous behavioral variable, i.e. whether or not the patient had trigeminal neuralgia using the Liebermeister test with 4000 permutations.²⁴ Only voxels that were damaged in at least 4 individuals were included in this Liebermeister analysis. To control for multiple comparisons, we applied a family-wise error (FWE) correction of $P < 0.05$.

Since increasing lesion volumes might be associated with an increased risk of afflicting brain areas that are involved in pain perception and endogenous pain modulation, we calculated volumes of multiple sclerosis lesions using nonparametric mapping (NPM) software implemented in the MRICron software package.¹³ To determine damaged brain regions, affected voxels were overlaid on the Automated Anatomical Labeling (AAL) atlas.²⁵ The peak coordinates of the involved regions are presented in Montreal Neurological Institute (MNI) space.

As a last step, a region-of-interest (ROI) based analysis was conducted. As ROIs served the areas for which the Liebermeister test showed a significant association with TN. ((i) ipsilateral pontine brainstem ROI and (ii) contralateral insular ROI). The binary variable was specified whether or not the patient had a lesion in the region of interest, the independent variable whether or not the patient had multiple sclerosis-related TN.

Demographic and clinical data were tested for normal distribution using the Shapiro-Wilk-test and are presented as mean and standard deviation or median and interquartile ranges. Non-normally

distributed data were compared using the Mann-Whitney U-test or chi-square test, as appropriate. Two-tailed p-values were calculated, statistical significance was assumed for $p < 0.05$. For statistical calculations, we used a commercially available statistic program (SPSS 20.0; IBM, Armonk, NY).

Results

Patient characteristics

Of 12210 patient records screened, 41 patients (0.3%) fulfilled the inclusion criteria and had multiple sclerosis-related TN and were therefore eligible to be included in the VLSM analysis. 21 patients were positively screened but not included in the analysis; in 19 patients no proper imaging could be obtained and in 2 patients imaging revealed a neurovascular contact. A total of 29 of the 41 patients (71.0%) were women and 12 (29.0%) were men. No cases of bilateral pain were reported. Clinical parameters and imaging characteristics of patients with multiple sclerosis-related TN and of the matched patients without TN are demonstrated in Table 1. A total 60% were classified as relapsing remitting multiple sclerosis, 33% secondary progressive multiple sclerosis and 4% primary progressive multiple sclerosis at the time of brain imaging. Patient age, disease duration, EDSS score did not differ between patient groups with or without multiple sclerosis-related TN. The total lesion volume of patients with trigeminal neuralgia was significantly lower than the lesion volume of the control patients. Figure 1 shows the lesion distribution and lesion overlap of all patients. The highest lesion overlap, i.e. highest prevalence of individuals with lesions in a given voxel, was seen in the periventricular region, especially the parietal white matter, both insular and subinsular regions, the bilateral callosal radiation, and the periaqueductal midbrain gray.

Voxel-based lesion symptom mapping

Figure 2 shows the subtraction map of lesion overlaps in patients without TN subtracted from the lesion overlap of patients with TN. In short, lesioned voxels in the intrapontine trigeminal afferents and in the contralateral anterior insular regions as well as contralateral hippocampus were associated with multiple sclerosis-related TN. Table 2 illustrates brain areas in which lesioned voxels were associated with TN in the subtraction analysis, the corresponding voxel count and the peak coordinates in MNI space.

The non-parametric voxel-wise analysis using Lieberman test statistics showed significant

associations between trigeminal neuralgia and a total of 178 lesioned voxels. Of these 15 voxels were located in the grey matter and 163 in the white matter. TN correlated significantly with multiple sclerosis lesions in ipsilateral pontine regions attributable to the trigeminal system, especially the region between the trigeminal root entry zone and the spinal trigeminal nucleus (thus, the intrapontine part of the trigeminal primary afferents). Furthermore, smaller sites of lesioned voxels remained associated with TN in the contralateral anterior insula (12 voxels; peak coordinates: $x = -26$; $y = 24$; $z = -3$) and the hippocampal region (2 voxels; peak coordinates: $x = -32$; $y = -24$; $z = -7$).

Region of interest analysis

Finally, we analyzed the relationship between multiple sclerosis lesions in the (i) brainstem and the (ii) anterior insula in the development of multiple sclerosis-related TN in a region of interest (ROI) analysis. As shown in Figure 4, a total of 19 patients (46.3%) with TN and 4 patients (9.8%) without TN had lesions both in the brainstem ROI and the insular ROI, 5 patients (12.2%) with TN and 2 patients (4.9%) without TN had lesions in the brainstem ROI but not the insular ROI, 13 patients (31.8%) with TN and 9 patients (22.0%) without TN had lesions in the insular ROI but not the brainstem ROI, 4 patients (9.8%) with TN and 26 patients (63.4%) without TN had no lesion in the brainstem ROI and no lesion in the insular ROI.

Discussion

Trigeminal neuralgia is a severe debilitating facial pain disorder and had a prevalence of 0.3% in our retrospectively analyzed multiple sclerosis patients. Our voxel-wise analysis indicates associations between multiple sclerosis-related TN and T2-hyperintense lesions most prominently in an ipsilateral brainstem area reaching from the pontine trigeminal root entry zone to the nucleus trigeminalis spinalis; but also lesion clusters in the contralateral anterior insular region and hippocampus seem to contribute to multiple sclerosis-related TN.

Previous imaging studies investigated possible associations between TN in multiple sclerosis patients and brainstem lesions but showed discrepant results.^{2, 6-10} Mills et al. showed that multiple sclerosis lesions in the brainstem affecting the trigeminal root entry zone were common but not necessarily associated with TN.¹⁰ In contrast, other imaging studies showed a correlation between sensory facial symptoms or facial pain and pontine brainstem multiple sclerosis lesions or multiple sclerosis-related structural changes of the intrapontine course of the trigeminal nerve.^{2, 6-9} Using multi-tensor tractography, Chen et al. recently showed different microstructural changes along the trigeminal nerve within the brainstem when they compared multiple sclerosis-related TN to the classic form of TN due to vascular compression.² In a multicenter study of 130 patients with multiple sclerosis, Cruccu et al. performed a voxel-based lesion analysis of brainstem lesions and found that multiple sclerosis lesions of the intrapontine trigeminal primary afferents were a strong predictor of TN.⁶ In another imaging study of 28 patients with multiple sclerosis and trigeminal sensory symptoms or TN, Truini et al. concluded that in addition to a pontine demyelinating multiple sclerosis lesion a vascular compression of the trigeminal nerve similar to the classic form of TN might contribute to multiple sclerosis-related TN by means of a double-crush mechanism.⁹ However, in all of these studies, multiple sclerosis lesions in other brain areas than the brainstem that contribute to integrating pain perception were not considered in the pathogenesis of multiple sclerosis-related TN.^{2, 6-10}

Therefore, in the present study, we performed a voxel-wise analysis of all T2-weighted multiple

sclerosis lesions throughout the brain in a cohort of multiple sclerosis patients with TN.¹⁴ We determined the voxel-wise lesion pattern in our entire sample of multiple sclerosis patients with TN and compared their lesion overlap to the lesion overlap of a matched cohort of multiple sclerosis patients without TN.

This rather specific approach towards identifying associations between circumscribed cerebral lesions and occurrence of TN confirms results of previous studies that pontine lesions of the intrapontine trigeminal primary afferents are associated with multiple sclerosis-related TN.^{2, 6-9} In our study, we observed a linear lesion pattern paramedian and intra-axial in the pons in continuity with the trigeminal nerve entering the pons. We propose that such a lesion pattern in the intrapontine trigeminal primary afferents is critical to develop multiple sclerosis-related TN.⁶⁻⁹ According to experimental studies, demyelinating lesions of the intrapontine trigeminal nerve fibers can increase susceptibility for ephaptic transmission.^{11, 26}

Surprisingly, our voxel-wise analysis showed that multiple sclerosis lesions in the contralateral insular region, most prominently in the anterior insula were associated significantly with multiple sclerosis-related TN. The insular cortex is a neural entity which contributes substantially to integrating painful nociceptive information.^{24, 27-30} Pain and temperature sensation can be considered as interoceptive stimuli that are conveyed through common neural pathways.^{27, 29} Nociceptive painful information from the trigeminal nerve is conveyed to the brainstem and relayed to thalamic nuclei.²⁷ Then interoceptive stimuli are further conveyed to the posterior insula, mid-insula and are finally integrated in the anterior insular cortex.^{27, 29, 31} According to functional imaging studies in healthy individuals, there are differential pain processing effects of the anterior and posterior portion of the insular cortex.^{27-29, 32} The posterior insular cortex is particularly involved in encoding pain intensity while the anterior insular cortex contributes more to the emotional or attentional components associated with painful sensation.^{27-29, 32, 33} In our study, we found an association between the occurrence of multiple sclerosis-related TN and lesions predominantly in the anterior insular cortex contralateral to the lesion in the pontine trigeminal root

entry zone. Several previous studies linked lesions of central nervous system structures that are involved in pain processing to alterations of pain sensation or centrally-mediated pain.^{23, 24, 27} It has been recognized that lesions of the thalamus can result in poststroke pain syndromes.²³ In a recent voxel-wise analysis of ischemic stroke patients, Seifert et al. linked stroke-associated headache to lesions of the insular cortex.²⁴ Seifert et al. concluded that ischemic lesions of the insula may lead to alterations in a functional connectivity network of the pain matrix.²⁴ The anterior insular cortex is involved in the cortical control of endogenous pain modulatory systems. A key brain region of the descending pain modulation pathway is the periaqueductal gray matter (PAG). The PAG receives input from anterior insular cortex as shown by animal studies.³⁴ There is also evidence of resting-state functional MRI-based functional connectivity of the human PAG with the insular cortex.³⁵ Disturbed or disrupted connectivity patterns between pain processing cortical areas and the pain modulatory system may contribute to the generation of episodic or chronic pain states.^{36, 37} Interestingly, a previous neuroimaging study has shown that the functional connectivity of the bilateral anterior insular cortex and the PAG as key areas of pain and pain modulatory networks relates to the susceptibility to pain.³⁸ In this study, Ploner et al. found that a stronger functional connectivity of the anterior insular cortex with the PAG had antinociceptive effects on the perception of noxious stimuli. Therefore, an altered connectivity profile of these brain areas due to an insular multiple sclerosis lesion may increase susceptibility to pathologic discharges arising from lesions in the intrapontine trigeminal primary afferents.

Thus, we suggest that the intact anterior insular cortex normally increases thresholds to nociceptive input for - or stabilizes the nociceptive system against - perceiving trigeminal neuralgic pain attacks. Thus, lesions of the insular cortex would thereby disinhibit neural structures of the pain-matrix which in turn could lead to disinhibition of central nervous system structures like the nucleus trigeminalis spinalis, the anterior cingulate cortex or the posterior insular cortex that are involved in perceiving and processing painful input.²⁷ The role of the hippocampus has been demonstrated during pain inhibition and it's importance in pain perception and modulation, especially involving

the cognitive-affective system, is widely accepted. The hippocampus has shown to be linked to other brain regions, including the insula. Our findings are congruent with previous, as well neuroimaging results that an affection of the hippocampus may impair pain inhibition and mechanisms involved in the emergence of persistent pain.³⁹

Limitations

Yet our study has limitations that require a careful interpretation of the results. The prevalence of MS-related TN was rather low, mainly resulting from underreporting in the retrospective setting, which could have influenced our results. Due to the retrospective study design, we did not have a standardized MRI protocol. Our intention was to exclude patients with a concomitant vascular contact of the trigeminal nerve by imaging to avoid bias or interference in our analysis. Because of the lack of suitable imaging, e.g. in high-resolution or adequate slice thickness in all patients, an underreporting of neurovascular contact is very likely. Besides, even if there is no evidence of vascular contact on imaging, a vessel-nerve contact cannot be ruled out completely. Patients were not contacted for the study, so it is possible that some patients in the study group experienced bilateral pain or patients in the control group experienced TN that was not taken into account in the analysis. Matching was performed for age, sex and EDSS. The implementation of further matching criteria, e.g. timing of imaging, would have been of additional value but was not possible due to the retrospective setting. In conclusion, we cannot rule out that disparities between the study and control groups, especially the lower lesion volume in the study group, could have affected the analysis. We assessed the multiple sclerosis lesions in our sample using T2-weighted MRI sequences. Hyperintense T2-lesions are unspecific and may represent lesions with possible regenerative potential. In contrast, T1-weighted hypointense lesions are more likely to represent persistent damage and axonal loss.⁴⁰ Our hypothesis was that inflammatory MS lesions are associated with pain, but in fact we cannot exclude a different pathophysiology of the lesions, e.g.

as a consequence of pain. Although preliminary analysis showed similar results, the examination of T1-lesion load was beyond the scope of the present study. A higher sample size might have produced different, maybe more clear results.

Conclusion

In conclusion our data show associations between multiple sclerosis-related TN and intrapontine brainstem lesions affecting the trigeminal root entry zone. In addition, multiple sclerosis lesions of the contralateral insula and hippocampus may contribute to the pathogenesis of multiple sclerosis-related TN possibly by attenuating thresholds for pain nociception.

Article highlights

- Brainstem lesions in the trigeminal root entry zone were associated with multiple sclerosis-related TN
- Supratentorial multiple sclerosis lesions of the contralateral insula and hippocampus may contribute to multiple sclerosis-related TN

Conflict of interest

Nothing to declare.

References

1. Mohammad-Mohammadi A, Recinos and *al. e.* Surgical outcomes of trigeminal neuralgia in patients with multiple sclerosis. *Neurosurgery*. 2013; 73: 941-50; discussion 50.
2. Chen D, DeSouza D, Hayes D, Davis K, O'Connor P and Hodaie M. Diffusivity signatures characterize trigeminal neuralgia associated with multiple sclerosis. *Multiple Sclerosis Journal*. 2016.
3. IHS. The International Classification of Headache Disorders, 3rd edition (beta version). *Cephalalgia : an international journal of headache*. 2013; 33: 629-808.
4. Vigeveno RM, Wiebenga OT, Wattjes MP, Geurts JJ and Barkhof F. Shifting imaging targets in multiple sclerosis: from inflammation to neurodegeneration. *Journal of magnetic resonance imaging : JMRI*. 2012; 36: 1-19.
5. Ge Y. Multiple sclerosis: the role of MR imaging. *Am J Neuroradiol*. 2006; 27: 1165-76.
6. Cruccu G, Biasiotto A, Di Rezze S, et al. Trigeminal neuralgia and pain related to multiple sclerosis. *Pain*. 2009; 143: 186-91.
7. Gass A, Kitchen N, MacManus D, Moseley I, Hennerici M and Miller D. Trigeminal neuralgia in patients with multiple sclerosis: lesion localization with magnetic resonance imaging. *Neurology*. 1997; 49: 1142-4.
8. Nakashima I, Fujihara K, Kimpara T, Okita N, Takase S and Itoyama Y. Linear pontine trigeminal root lesions in multiple sclerosis: clinical and magnetic resonance imaging studies in 5 cases. *Arch Neurol* 2001. 2001: 101-4.
9. Truini A, L. P, V. C, et al. A dual concurrent mechanism explains trigeminal neuralgia in patients with multiple sclerosis. *Neurology*. 2016.
10. Mills RJ, Young CA and Smith ET. Central trigeminal involvement in multiple sclerosis using high-resolution MRI at 3 T. *Br J Radiol*. 2010; 83: 493-8.
11. Love S and Coakham H. Trigeminal neuralgia: Pathology and pathogenesis. *Brain*. 2001: 2347-60.
12. Bates E, Wilson SM, Saygin AP, et al. Voxel-based lesion-symptom mapping. *Nature neuroscience*. 2003; 6: 448-50.
13. Rorden C, Karnath H and Bonilha L. Improving lesion-symptom mapping. *J Cogn Neurosci*. 2007; 19: 1081-8.
14. Winder K, Linker RA, Seifert F, et al. Neuroanatomic correlates of female sexual dysfunction in multiple sclerosis. *Annals of neurology*. 2016; 80: 490-8.
15. Winder K, Seifert F, Koehn J, et al. Site and size of multiple sclerosis lesions predict enhanced or decreased female orgasmic function. *Journal of neurology*. 2015; 262: 2731-8.
16. Winder K, Seifert F, Köhrmann M, et al. Lesion mapping in stroke-related erectile dysfunction. *Brain*. 2017; 140: 1706-17.
17. Polman CH, Reingold SC, Banwell B, et al. Diagnostic criteria for multiple sclerosis: 2010 revisions to the McDonald criteria. *Annals of neurology*. 2011; 69: 292-302.
18. Kurtzke J. Rating neurologic impairment in multiple sclerosis: an expanded disability status scale (EDSS). *Neurology*. 1983; 11: 1444-52.
19. McCausland Center for Brain Imaging. MRICron software, <http://www.mccauslandcenter.sc.edu/micro/mricron> (2007, accessed 04 June 2016).
20. Rorden C, Bonilha L, Fridriksson J, Bender B and Karnath HO. Age-specific CT and MRI templates for spatial normalization. *NeuroImage*. 2012; 61: 957-65.
21. Wellcome Department of Cognitive Neuroscience, University College London. Statistical Parametric Mapping (SPM), <http://www.fil.ion.ucl.ac.uk> (2012, accessed 04 June 2017).
22. McCausland Center for Brain Imaging. Clinical Toolbox for SPM8, http://www.nitrc.org/frs/?group_id=881 (2012, accessed 04 June 2017).
23. Sprenger T, Seifert CL, Valet M, et al. Assessing the risk of central post-stroke pain of thalamic origin by lesion mapping. *Brain*. 2012; 135: 2536-45.

24. Seifert CL, Schonbach EM, Magon S, et al. Headache in acute ischaemic stroke: a lesion mapping study. *Brain*. 2016; 139: 217-26.
25. Tzourio-Mazoyer N, Landeau B, Papathanassiou D, et al. Automated anatomical labeling of activations in SPM using a macroscopic anatomical parcellation of the MNI MRI single-subject brain. *NeuroImage*. 2002; 15: 273-89.
26. Love S, Gradidge T and Coakham HB. Trigeminal neuralgia due to multiple sclerosis: ultrastructural findings in trigeminal rhizotomy specimens. *Neuropathol Appl Neurobiol*. 2001; 27: 238-44.
27. Craig A, Chen K, Bandy D and Reiman E. Thermosensory activation of insular cortex. *Nature neuroscience*. 2000; 3: 184-90.
28. Mazzola L, Isnard J, Peyron R and Mauguiere F. Stimulation of the human cortex and the experience of pain: Wilder Penfield's observations revisited. *Brain*. 2012; 135: 631-40.
29. Craig AD. How do you feel--now? The anterior insula and human awareness. *Nature reviews Neuroscience*. 2009; 10: 59-70.
30. Seifert F. Brain aging in female migraineurs: differences in the insula. *PAIN*. 2015; 156: 1180-1.
31. Critchley HD, Wiens S, Rotshtein P, Ohman A and Dolan RJ. Neural systems supporting interoceptive awareness. *Nature neuroscience*. 2004; 7: 189-95.
32. Bornhövd K, Quante M, Glauche V, Bromm B, Weiller C and Büchel C. Painful stimuli evoke different stimulus-response functions in the amygdala, prefrontal, insula and somatosensory cortex: a single-trial fMRI study. *Brain*. 2002; 125: 1326-36.
33. Lorenz R, Gleich T, Kuehn S, et al. *Subjective illusion of control modulates striatal reward anticipation in adolescence*. . 2015.
34. Leichnetz G, Spencer R and Hardy S. The prefrontal corticotectal projection in the monkey; an anterograde and retrograde horseradish peroxidase study. *Neuroscience*. 1981; 6: 1023-41.
35. Coulombe MA, Erpelding N, Kucyi A and Davis KD. Intrinsic functional connectivity of periaqueductal gray subregions in humans. *Hum Brain Mapp*. 2016; 37: 1514-30.
36. Edwards R. Individual differences in endogenous pain modulation as a risk factor for chronic pain. *Neurology*. 2005; 65: 437-43.
37. Seifert F, Kiefer G, DeCol R, Schmelz M and Maihofner C. Differential endogenous pain modulation in complex-regional pain syndrome. *Brain*. 2009; 132: 788-800.
38. Ploner M, Lee MC, Wiech K, Bingel U and Tracey I. Prestimulus functional connectivity determines pain perception in humans. *Proceedings of the National Academy of Sciences of the United States of America*. 2010; 107: 355-60.
39. Tian T, Guo L, Xu J, et al. Brain white matter plasticity and functional reorganization underlying the central pathogenesis of trigeminal neuralgia. *Sci Rep*. 2016; 6: 36030.
40. Stefano N, Matthews P, Fu L, et al. Axonal damage correlates with disability in patients with relapsing-remitting multiple sclerosis. *Brain*. 1998; 121: 1469-77.

Table legends

Table 1: Demographic and clinical parameters of multiple sclerosis patients with and without TN.

	Trigeminus neuralgia (n=41)	No trigeminus neuralgia (n=41)	<i>P</i> <i>(two-tailed)</i>
Age, yr; median (IQR)	47 (35-58)	47.5 (35-53.5)	0.93*
Disease duration, months; median (IQR)	84 (14.0-204)	145 (93.3-228.5)	0.16*
EDSS; median (IQR)	3 (2-6)	5 (3-7)	0.87*
Female/male	29/12	29/12	1.00†
Lesion volume T2; voxels; median (IQR)	24322 (15393- 75971)	56720.5 (32775- 115783)	0.012*
MS type (PPMS/RRMS/SPMS)	2/24/15	1/25/15	0.92*

IQR, interquartile range; EDSS, Expanded Disability Status Scale; PPMS, primary progressive multiple sclerosis; RRMS, relapsing-remitting multiple sclerosis; SPMS, secondary progressive multiple sclerosis.

* p-value (two-tailed) derived from Mann-Whitney U-test

† p-value (two-tailed) derived from Chi square-test

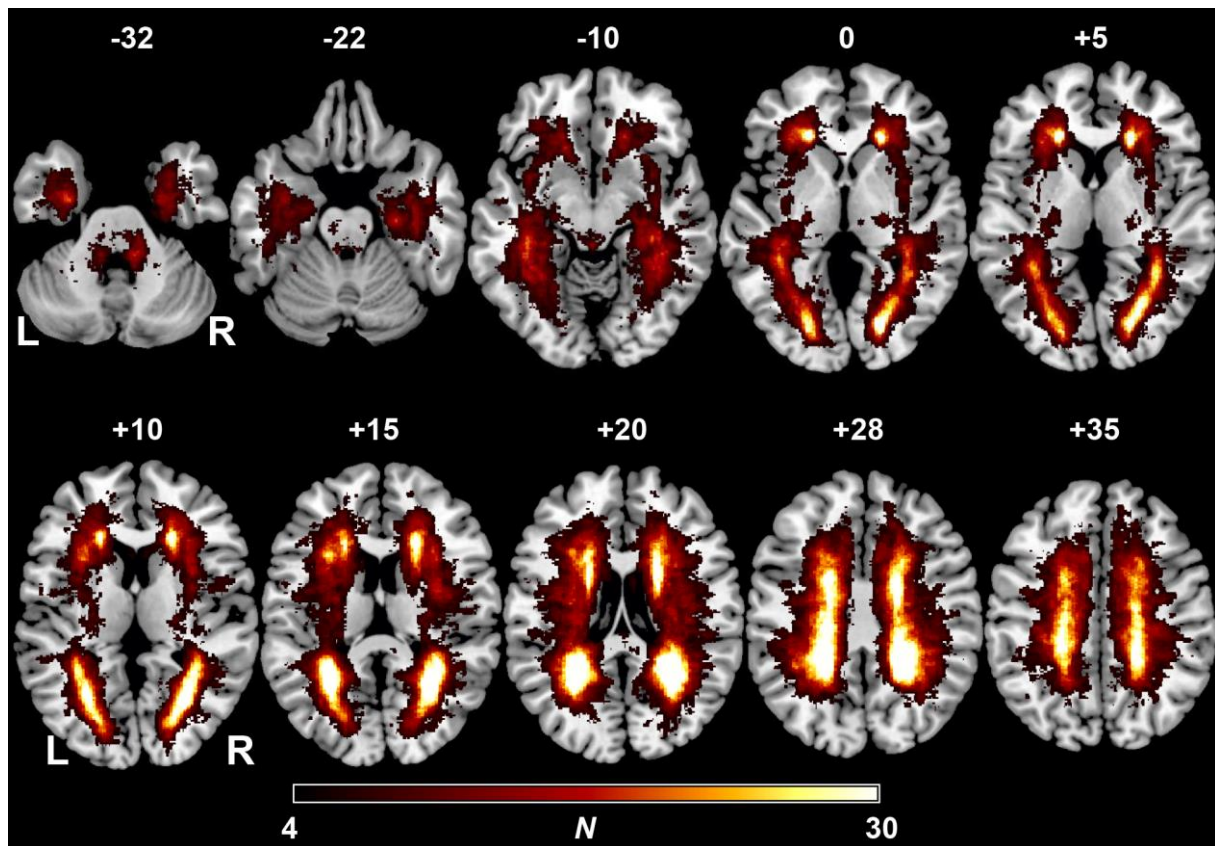
Table 2. Results from the voxel-wise subtraction analysis.

Lesion site	voxels	x	y	z
Insula (l)	210	-32	19	-10
Insula (r)	14	38	8	-9
Hippocampus (l)	112	-33	-30	-8
Hippocampus (r)	52	27	-35	0
Calcarine (l)	7	-25	-63	12
Calcarine (r)	57	16	-87	3
Fusiform (l)	2	-35	-36	-15
Fusiform (r)	26	28	-42	-10
Caudate (l)	4	-15	1	18
Caudate (r)	16	21	23	16
Cerebellum (l)	13	-10	-44	-38
Cerebellum (r)	11	10	-43	-35

Brain areas according the areas defined in AAL atlas in which lesioned voxels were associated with TN, as well as corresponding voxel counts and peak coordinates in MNI space are shown.

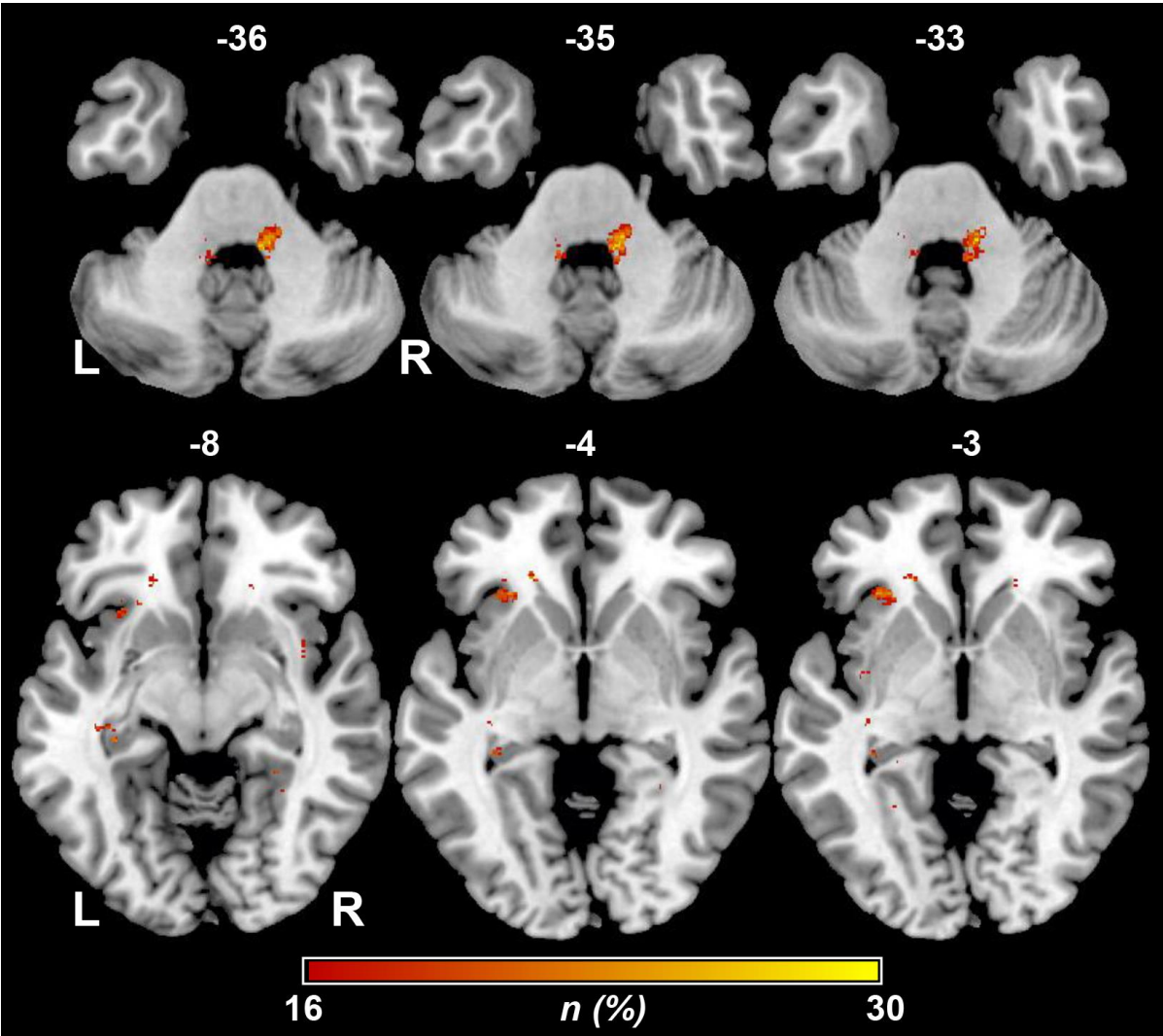
Figure legends

Figure 1. Overlap and distribution of T2 lesions of all patients thresholded to include only voxels that were lesioned in at least 4 individuals.



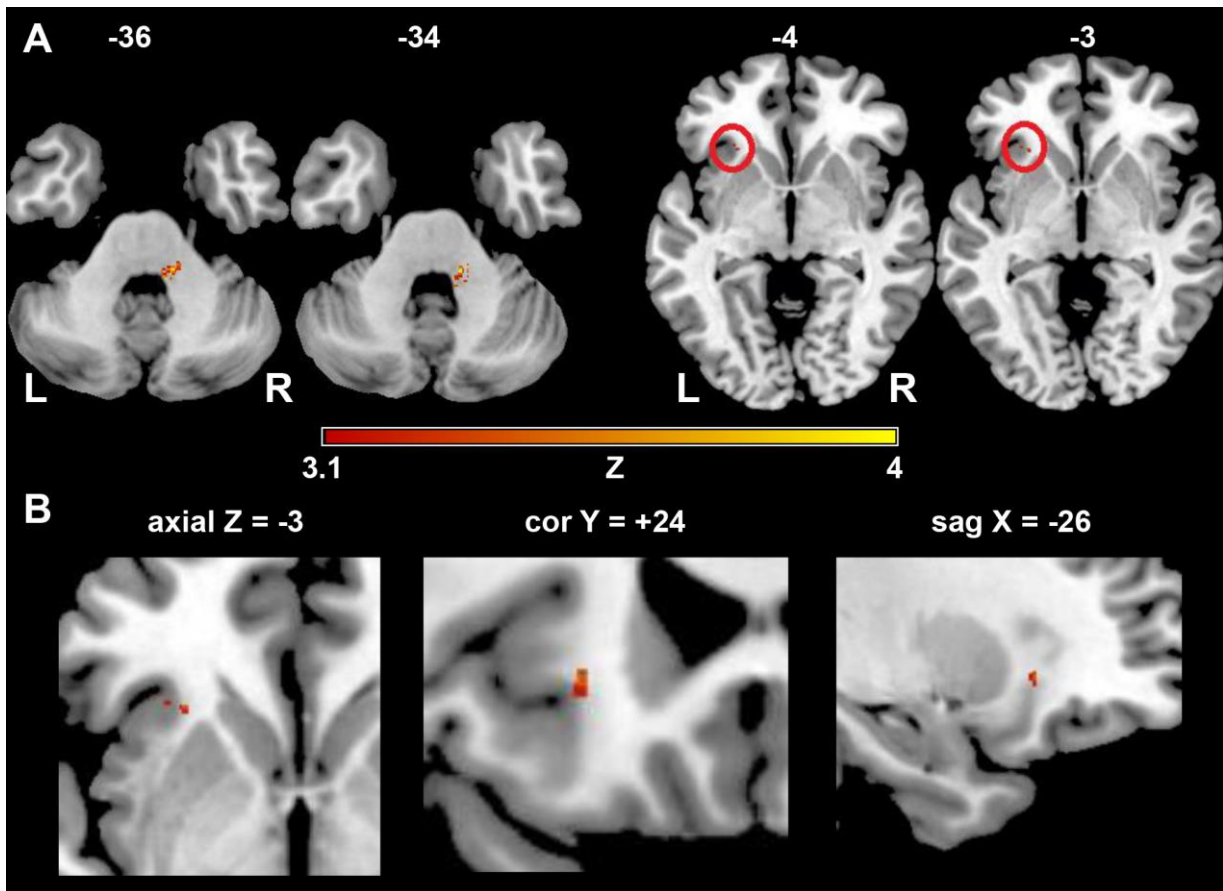
The number of overlapping lesions is illustrated by different colours coding increasing frequencies from dark red to yellow. Supratentorial lesion pattern shows the highest overlay in subcortical and periventricular regions, especially in the parietal periventricular white matter. Infratentorially summed lesion probability mapping indicates markable involvement of paramedian pontine regions. L = left; N = number of individuals with a lesion in a given voxel; R = right

Figure 2. Subtraction map of lesion overlap of multiple sclerosis patients without TN subtracted from the lesion overlap of patients with TN.



Lesioned voxels in the intrapontine trigeminal afferents but also in the contralateral insular region and contralateral hippocampus were associated with TN. The color bar indicates the number of patients in percent in whom a lesion in a given voxel remained associated with TN after subtraction. To reduce noise, only lesioned voxels that were affected in at least 16% of the individuals after subtraction are shown. L = left; n = number of individuals in percent; R = right

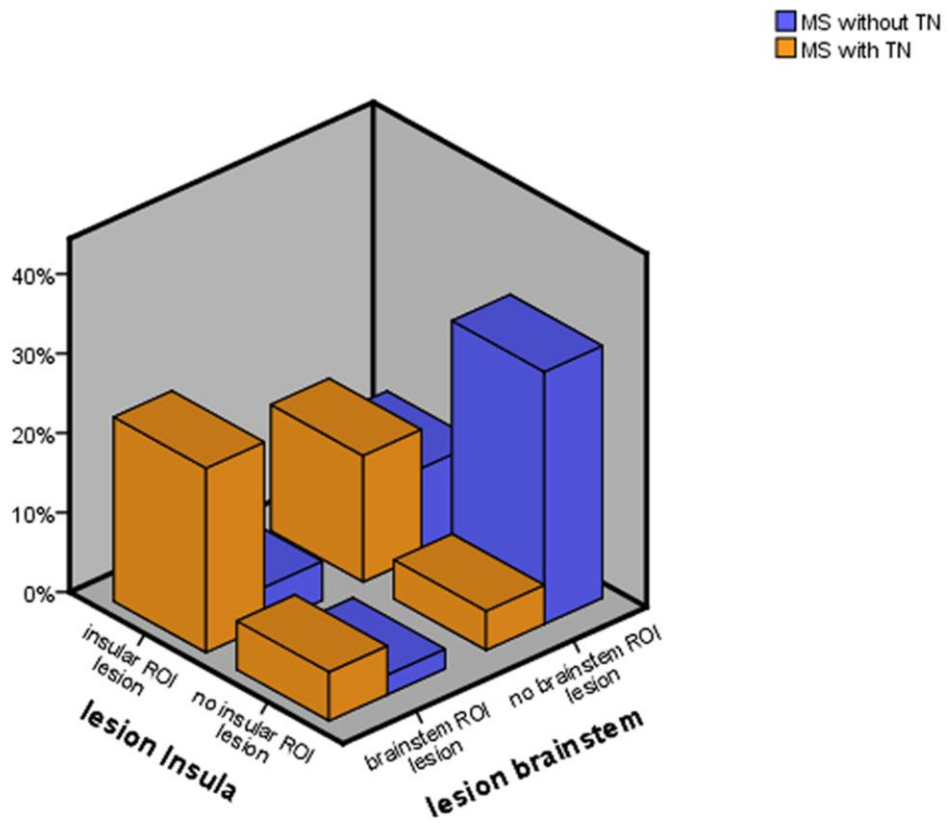
Figure 3. Results of the nonparametric Liebermeister test statistics.



Lesioned voxels to be associated with TN are mainly found in the pons of the brainstem, in a region known to be part of the trigeminal nuclear system. Furthermore, smaller sites with significant lesioning associated with TN in multiple sclerosis were located in the insular region (A). In the lower row we show the zoomed images in axial, coronar and sagittal planes illustrating lesioned voxels in the contralateral insular region (B).

Only voxels that were damaged in at least 4 patients were included in the Liebermeister test analysis. A family wise error (FWE) correction of $P < 0.05$ was applied. L = left; z = z-score; R= right

Figure 4. Overview of the lesion location of patients with and without trigeminal neuralgia in multiple sclerosis.



The prevalence of multiple sclerosis patients with a lesion in the trigeminal root entry zone, in the the contralateral insular region, as well as patients with lesions in both of these regions of interest are demonstrated. % = percentage of the study population